

Ridge Preservation after tooth extraction as a standard treatment of choice for obtaining stable peri-implant tissues after implant-restorations procedures. Case Report

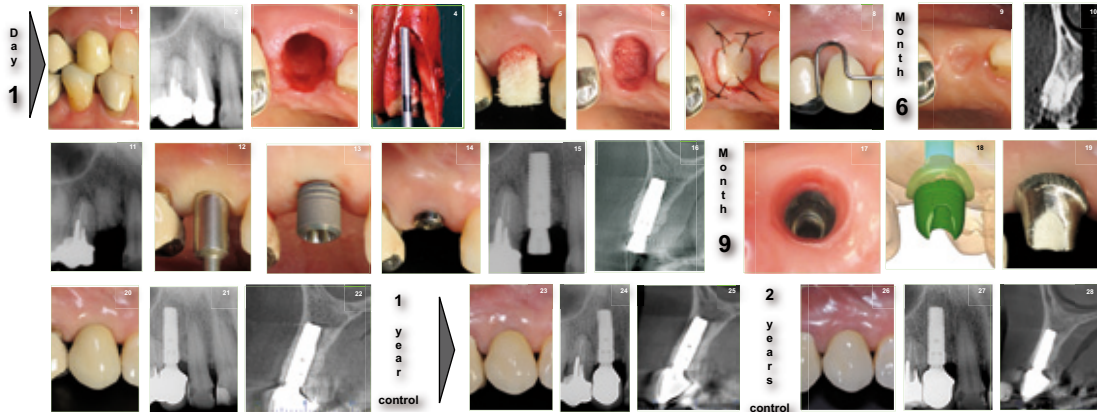
López F* DDS;Robledo J** DDS

Abstract:

Tooth extraction today need to be handle carefully in order to preserve the remaining tissues left (bone/gingiva) . Confused criteria of the management of extraction sockets should be better reviewed understanding the bone physiology and considering the changes after tooth extraction. An anorganic bovine bone matrix appear to meet the expectations for implant placement with very low morbidity and long-term stability.

Materials and methods:

Tooth extraction (Nr.6) after being diagnosed with longitudinal fracture has been performed in a healthy systemic patient without any contraindication for the procedure. Gentle extraction of the fractured tooth followed by the placement of an Anorganic Bovine Bone Matrix (Bio-Oss collagen) and covered with a free gingival graft from the palate was carried out.



Conclusions:

Ridge preservation with an anorganic bovine bone matrix appear to be a very feasible procedure to compensate changes after tooth loss in patients for prosthodontic procedures , generating enough and stable bone (quality/quantity) volume site for the implant placement and patient comfort post operatively at the first surgical stage.