

208 Vestibuloplasty: Porcine Collagen Matrix Versus Free Gingival Graft. A Clinical and Histological Study

Schmitt CM, Tudor C, Kiener K, Wehrhan F, Eitner S, Agaimy A, Schlegel KA

Osteology Foundation: (No. AZ 08-014)

Objectives

A free gingival graft (FGG) is currently the gold standard for augmenting small areas of keratinized mucosa. As of yet, no satisfactory results were found with synthetic transplants or autologous transplants derived from tissues other than palatal mucosa. Nonetheless, disadvantages include the inability to harvest larger grafts, high morbidity rate after surgery and poor aesthetics, due to differences in texture and color from adjacent areas. Thus, the optimal transplant for the regeneration of keratinized mucosa is still needed with low morbidity, immediate availability, adequate size, low contraction and sufficient thickness and immobility.

The porcine collagen matrix (CM, Mucograft®) was proclaimed to serve as alternative to autologous tissue harvesting for the augmentation of keratinized mucosa. It is fabricated as a 3D- matrix of pure type I and type III collagen with two functional layers supporting clot formation, cell adhesion and ingrowth, and therefore tissue formation.

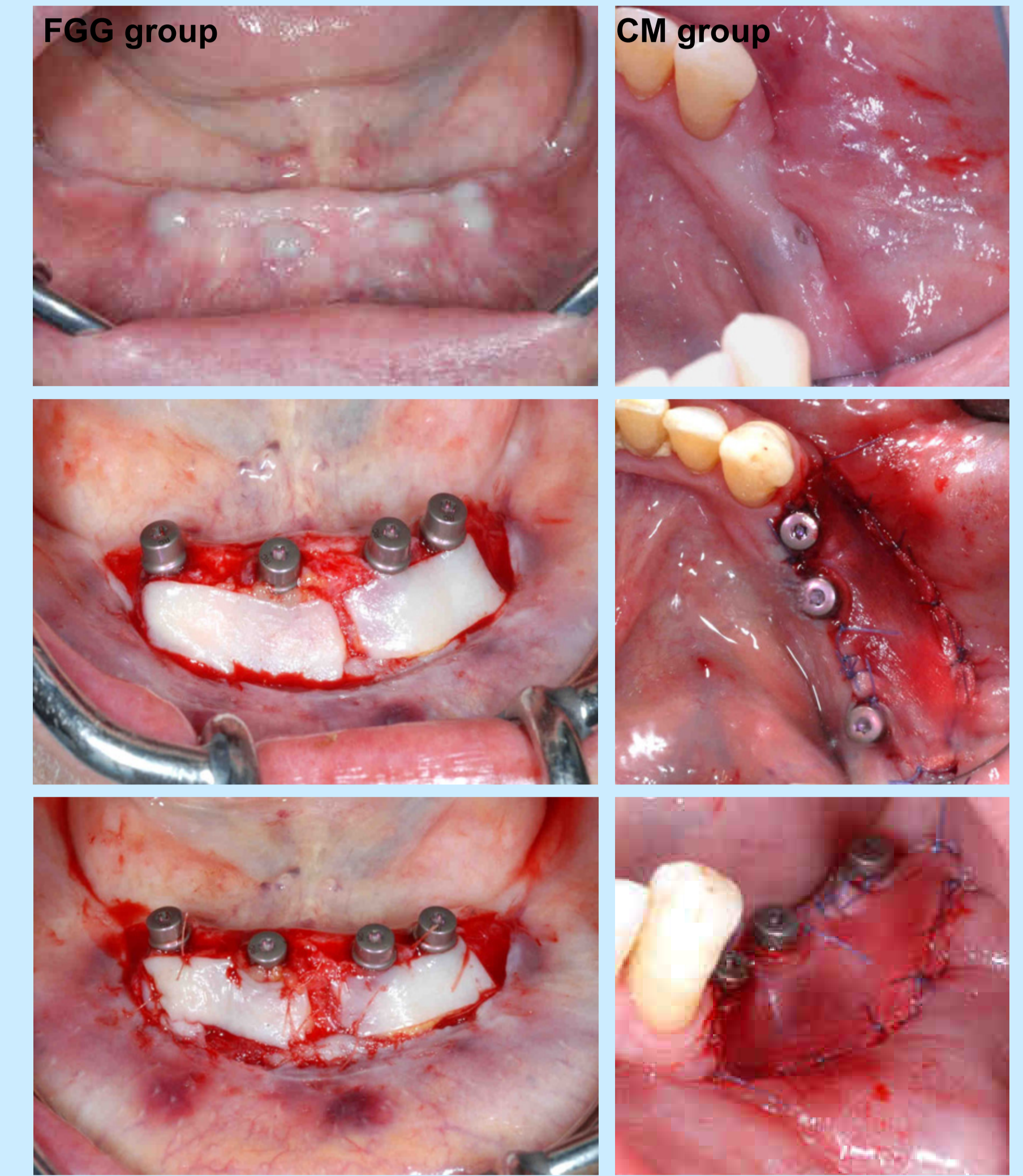
This clinical study aimed to compare the CM versus FGGs for augmenting keratinized peri-implant mucosa, based on clinical and histological evaluations.

Materials and Methods

The study included 14 patients that underwent a vestibuloplasty either in the anterior or posterior region of the lower jaw. In the context of implant exposure, a FGG from the palate (n=7) or the CM (n=7) was randomized used for grafting. Surgery time was recorded and width of keratinized mucosa was measured in the region of each implant before and after surgery, and 10, 30 and 90 days post surgery. After 90 days, a biopsy was harvested for histological and immunohistological analyses to stain for tissue and differentiation-specific markers, cytokeratin (CK) 5/6, 13, and 14, to detect presence or absence of keratinization.

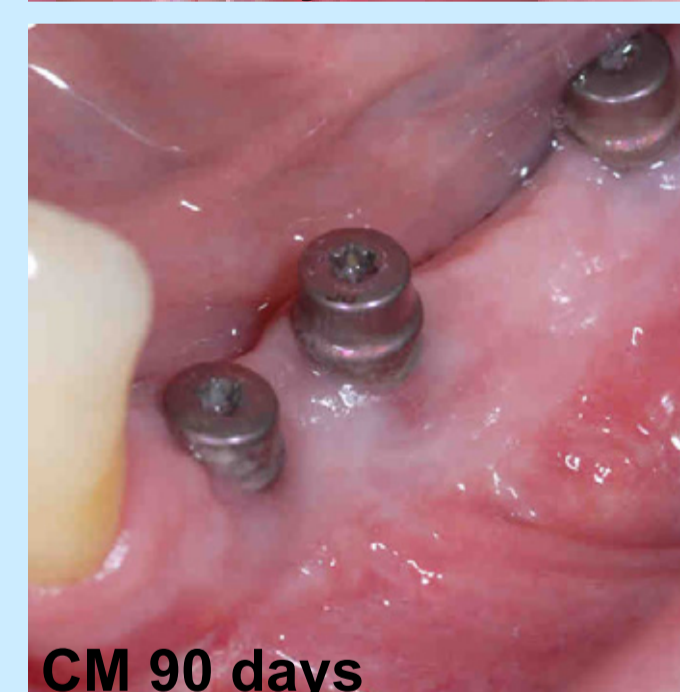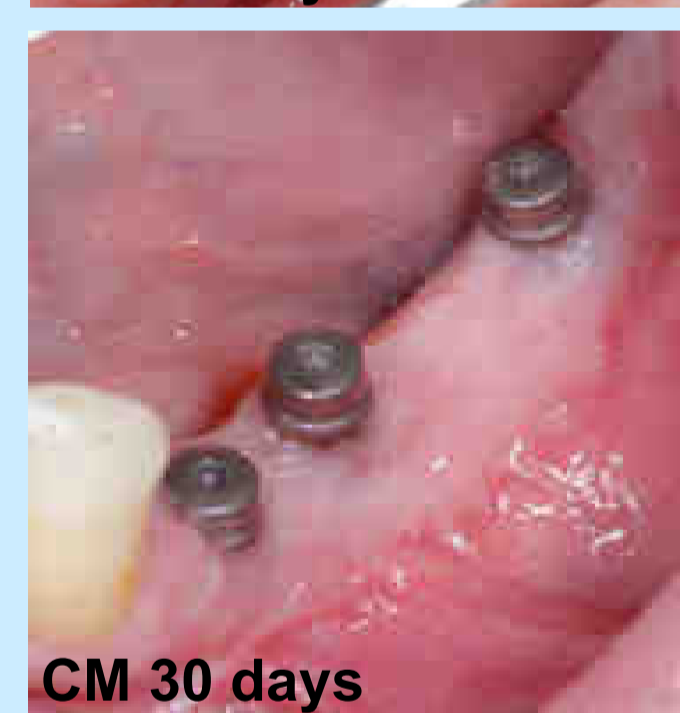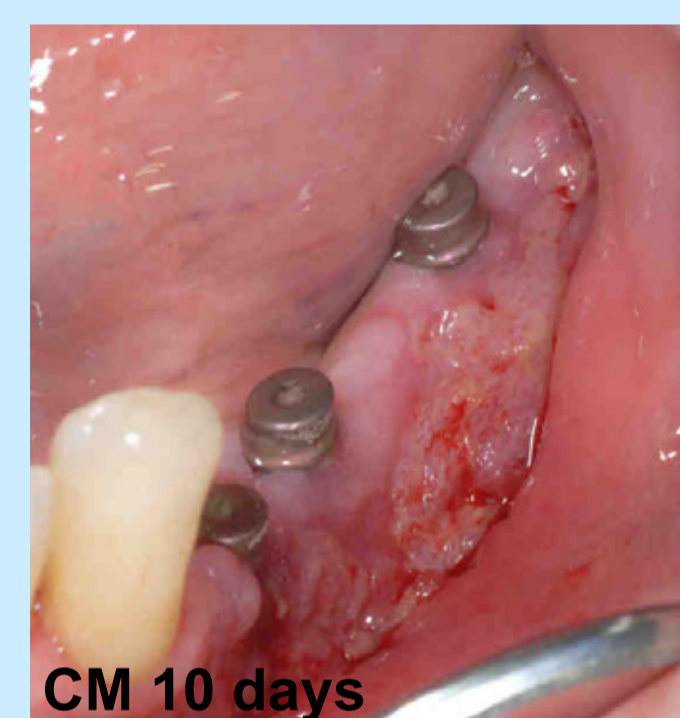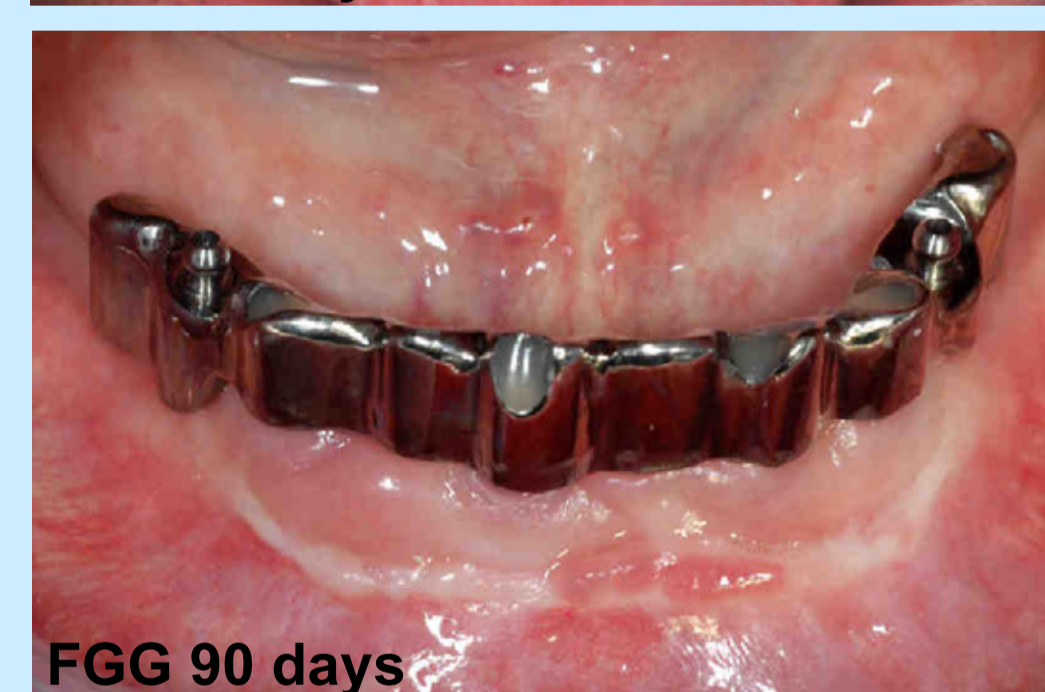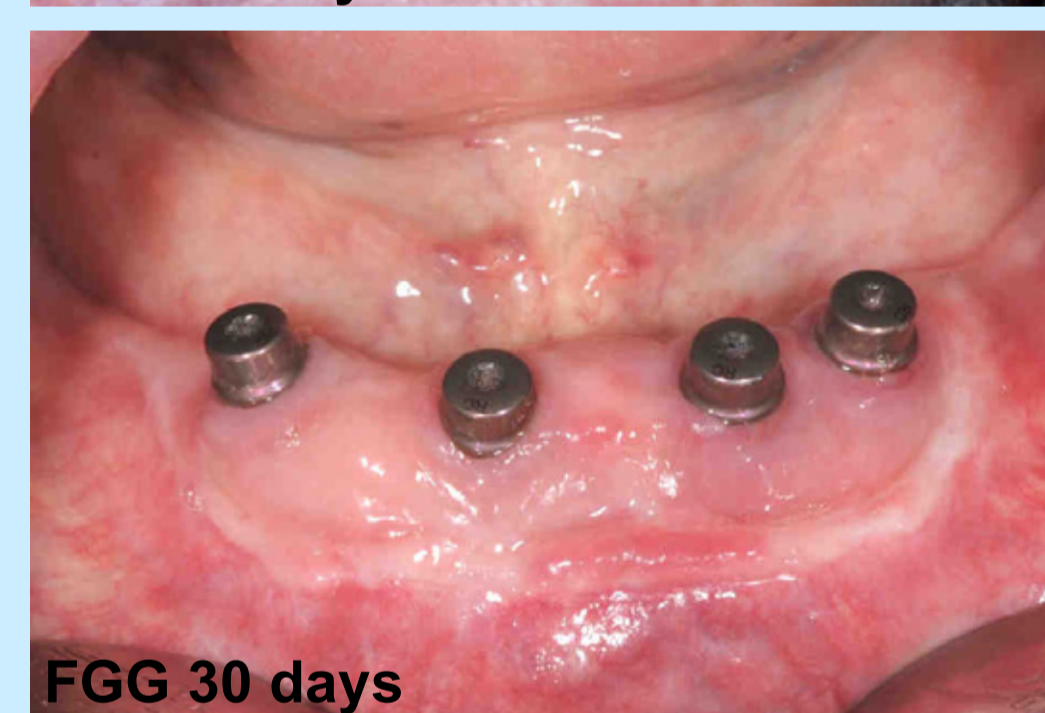
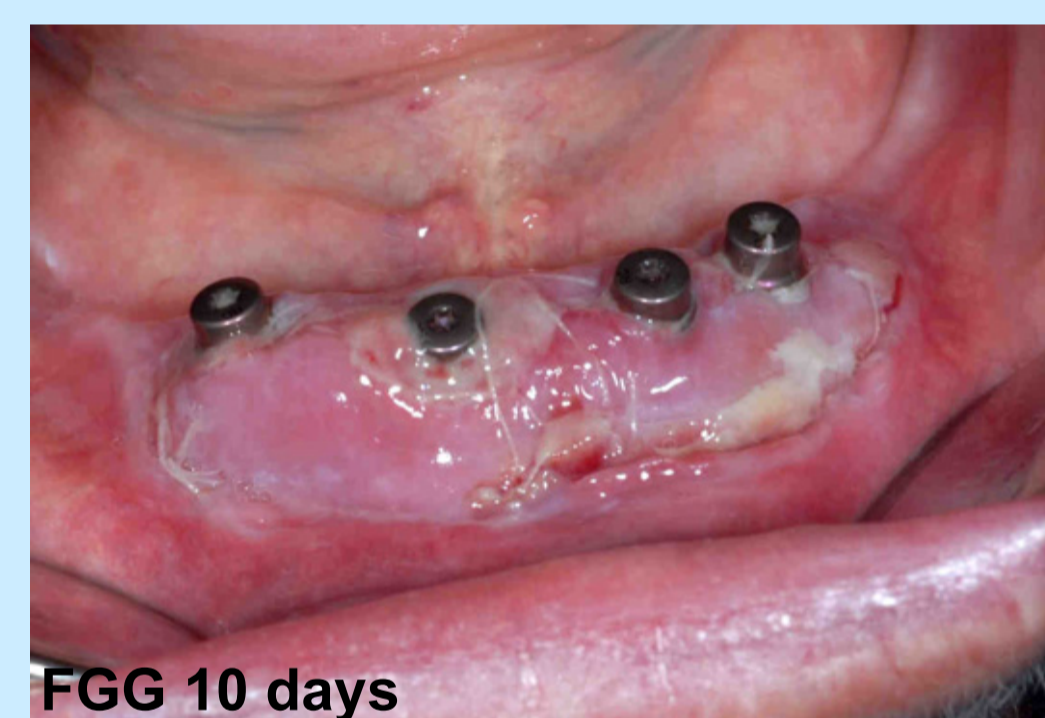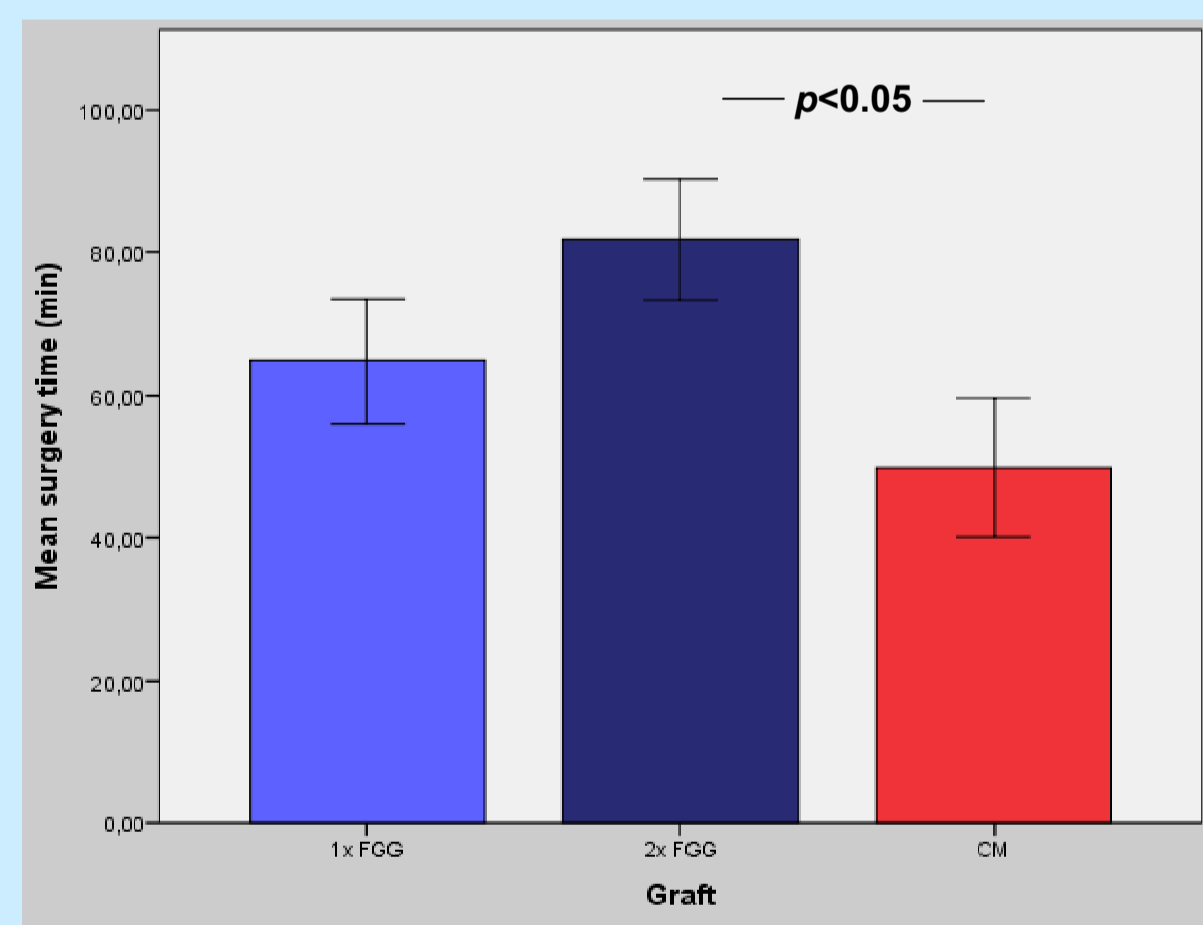
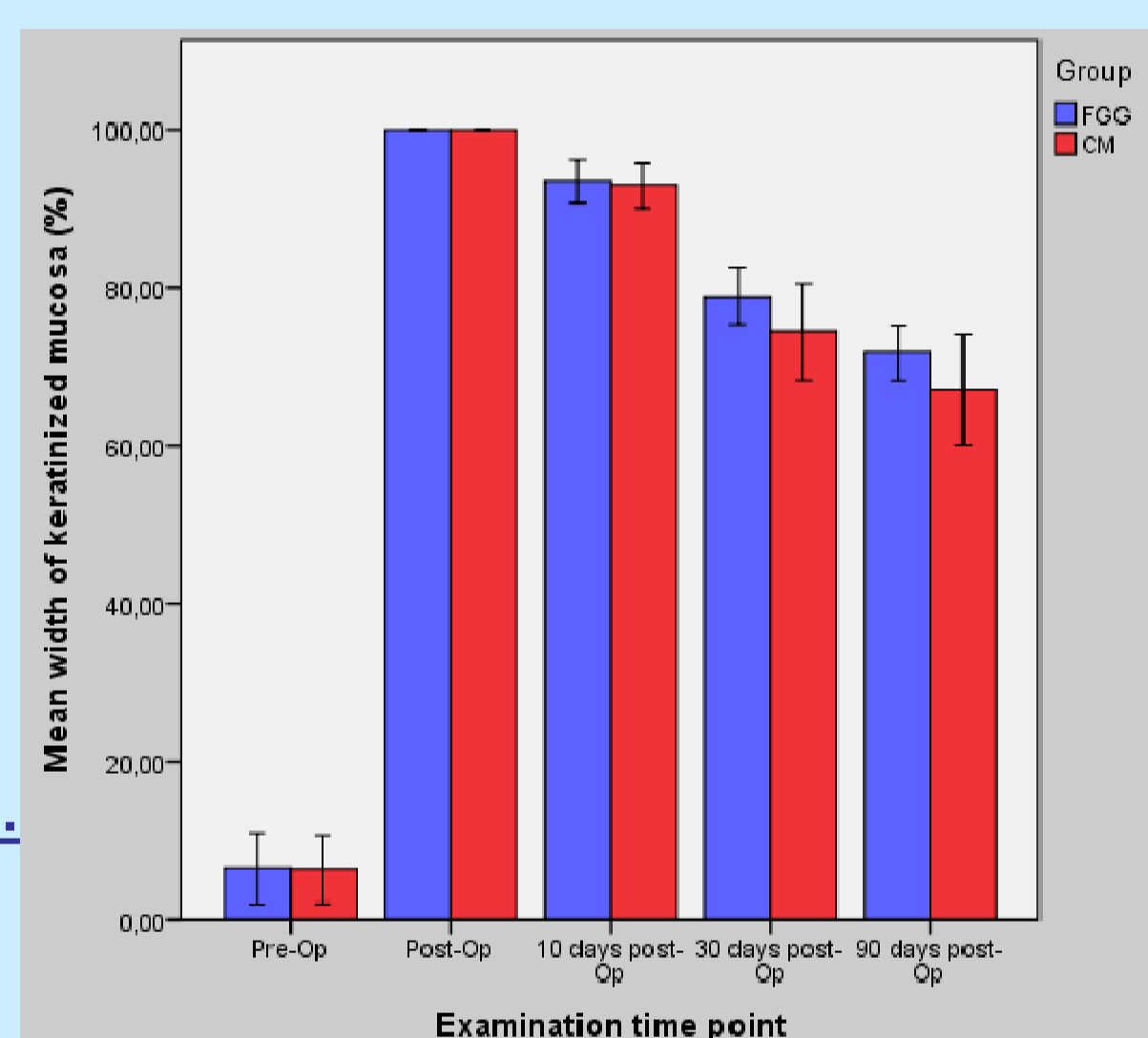


Collagen Matrix (CM, Mucograft®)



Clinical outcome

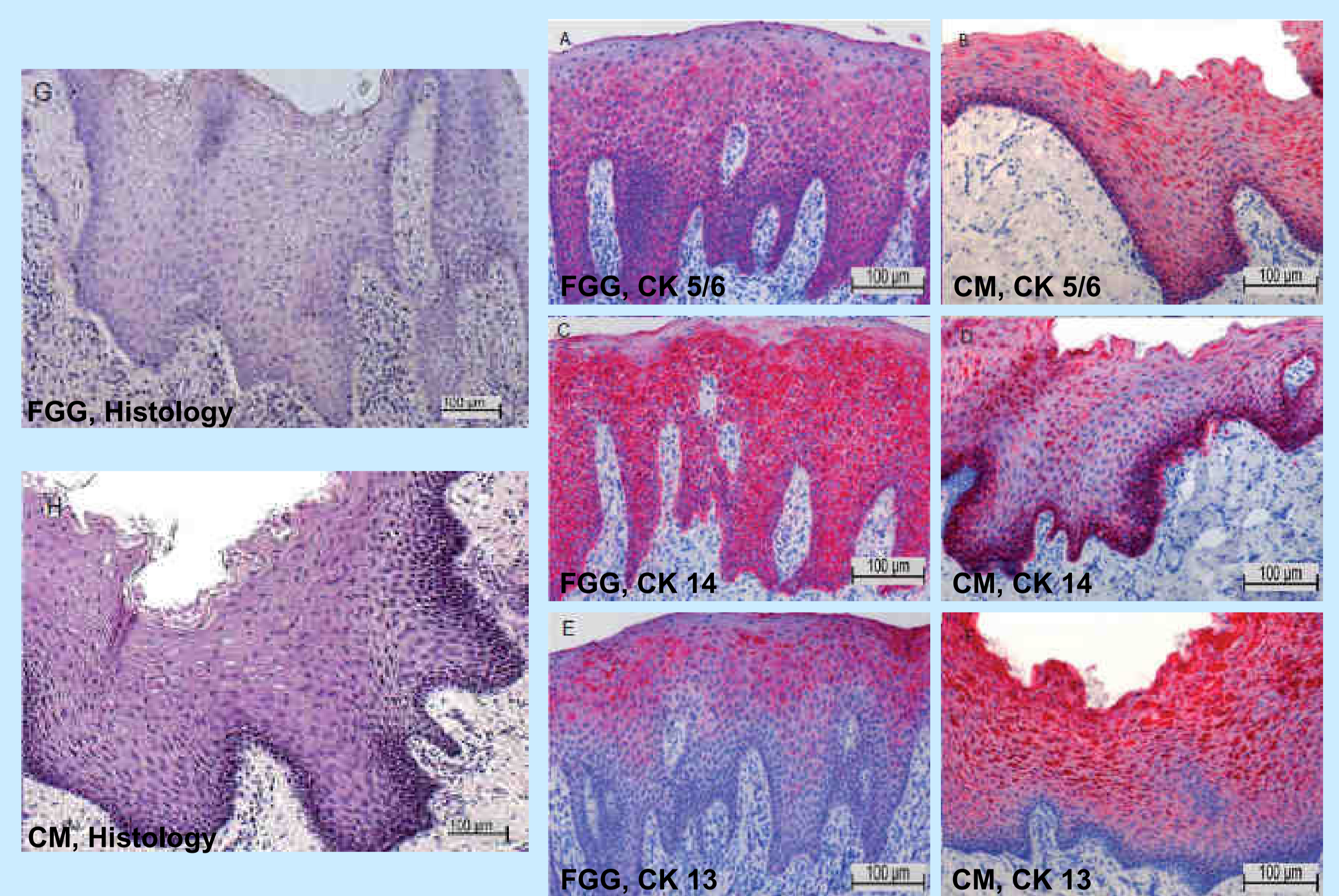
The groups showed similar healing, with increased peri-implant keratinized mucosa. The CM group had overall significantly shorter operation times than the FGG group. Both groups showed non significant overall shrinkage (CM 32.98% vs. FGG 28.35%) after 90 days.



Results

Histological outcome

All biopsies showed a multilayered, keratinized, squamous epithelium. Cytokeratins (CK) 5/6 and 14 were detected in the basal and suprabasal layers, and spots of cytokeratin 13 were detected in the suprabasal layers. CK expressions in both groups were similar to cytokeratin expression patterns of keratinized gingiva.



Summary

During the whole observation period, both groups showed comparable clinical and histologic outcomes:

- Increased peri-implant keratinized mucosa after surgery
- Comparable non significant graft shrinkage up to 90 days
- Multilayered keratinized squamous epithelium/ proof of keratinization

With the use of CM surgery time was reduced significantly.

In the CM group new mucosa was similar to adjacent soft tissues.

Summary and Conclusion

Conclusion

Within the limitations of the present study, CM seems to be a promising alternative for the regeneration of keratinized mucosa and is comparable to the gold standard of care, the free gingival graft (FGG). Importantly, the collagen matrix obviates painful tissue harvesting procedures, is immediate available in adequate size and reduces surgery time. Comparative long-term studies are needed to investigate changes over time.

Literature

1. Schmitt CM, Tudor C, Kiener K, Wehrhan F, Schmitt J, Eitner S, Agaimy A, Schlegel KA. (2012) Vestibuloplasty: Porcine Collagen Matrix Versus Free Gingival Graft. A Clinical and Histological Study. J Periodontol. DOI 10.1902/jop.2012.120084
2. Sanz M, Lorenzo R, Aranda JJ, Martin C, Orsini M. (2009) Clinical evaluation of a new collagen matrix (Mucograft prototype) to enhance the width of keratinized tissue in patients with fixed prosthetic restorations: a randomized prospective clinical trial. J Clin Periodontol. 36(10):868-876.
3. Dale BA, Salonen J, Jones AH. (1990) New approaches and concepts in the study of differentiation of oral epithelia. Crit Rev Oral Biol Med. 1(3):167-190.