

Katiuska Gómez, Gisbeli Brea, José Francisco Gómez Sosa

Root canal treatment of a mandibular first premolar with a category 3 C-shaped root canal anatomy: a case report



Katiuska Gómez, DDS
Postgraduate student,
Department of Endodontics,
Universidad Central de Ven-
ezuela, Caracas, Venezuela

Gisbeli Brea, DDS
Postgraduate student,
Department of Endodontics,
Universidad Central de Ven-
ezuela, Caracas, Venezuela

José Francisco Gómez Sosa, DDS, PhD
Postgraduate Department
of Endodontics, Universidad
Central de Venezuela, Cara-
cas, Venezuela

Key words *anatomical variation, C-shaped root, C-shaped root canal, cone beam computed tomography, dental anomalies, mandibular premolar, tomography, tooth morphology*

The C-shaped configuration of the root and root canal system is an unusual anatomical variation in mandibular first and second premolars. It is categorised as a 'C' due to the transverse morphology of the root and the root canal. The main anatomical characteristic is the presence of an invagination groove caused by Hertwig epithelial sheath faults during root development. This case report describes the root canal treatment of a C-shaped configuration of a mandibular first premolar, identified by means of cone beam computed tomography.

■ Introduction

Mandibular premolars are considered one of the most difficult teeth for root canal treatment due to the presence of multiple root canals, apical deltas, lateral canals and possible anatomic root variations in the form of a 'C'^{1,2}.

A detailed evaluation of the tooth and its root morphology is a prerequisite for the success of endodontic therapy³. For a successful result in root canal treatment the main objective is to achieve an adequate chemical and mechanical disinfection of the root canal system, followed by a three-dimensional obturation with an inert filling material and the subsequent restoration that prevents access to microorganisms⁴.

The main cause of the appearance of roots in the form of a 'C' is caused by a failure in the epithelial Hertwig sheath during dental development; the C-shape appears when the vestibular or lingual area of the roots fuse irregularly, and only stays connected by an interradicular groove^{7,8}. The root canals with C-shaped configurations in their cross-section have the shape of the letter 'C'. However, these are not

always continuous from the entrance of the canal to the apical foramen¹. The main anatomical characteristic is the presence of isthmuses that connect the individual canals, and that can vary along the root in their cross-sections⁵.

Fan et al⁵ classify the C-shaped lower premolars according to their cross-section obtained by micro-CT scanning in the following categories:

- Category I (C1): the shape was a continuous 'C' with no separation or division;
- Category II (C2): the canal shape resembled a semicolon resulting from a discontinuation in the 'C' outline;
- Category III (C3): two separate round, oval, or flat canals;
- Category IV (C4): only one round, oval, or flat canal in that cross-section, which was further classified into three subdivisions:
 - C4a (round canal): the long canal diameter was almost equal to the short diameter;
 - C4b (oval canal): the long canal diameter was at least twice as short as the short diameter;
 - C4c (flat canal): the long canal diameter was at least twice as long as the short diameter.

Correspondence to:
Katiuska Gómez
Calle la Joya, Edificio
Cosmos, Piso 1,
Oficina 1C, Chacao,
1060 Caracas-Venezuela
E-mail: kati_09@hotmail.com

- Category V (C5): three or more separate canals in the cross-section;
- Category VI (C6): no canal lumen or no intact canal could be observed (usually only seen near the apex).

The prevalence of C-shaped root canals in the first mandibular premolar varies between different ethnic groups. Lu et al⁹ evaluated the morphology of the canal in 82 mandibular first premolars in a Chinese population using the cross-sectional method and reported that 18% of the teeth had the C-shaped configuration.

Baisden et al¹⁰ studied the cross-sections of 106 mandibular first premolars in a population in the United States and found that the prevalence of C-shaped canals was 14%. Sikri and Sikri¹¹ investigated the variations of pulp cavity morphology in 112 samples using the same method and reported that the prevalence of the C-shape in an Indian population was 10.7%. Fan et al⁵ evaluated 358 mandibular premolars in a Chinese population with cross-sectional tomography and reported that 24% of teeth had a C-shaped configuration. Due to its challenging morphology, the C-shaped anatomy increases the difficulty in endodontic therapy and may explain the frequent appearance of treatment failures associated with these teeth⁹.

For root canal procedures on teeth with roots with C-shaped configurations the conventional radiographs used for the evaluation of the root anatomy do not provide sufficient data for the analysis of the case. Therefore, the best method for an accurate determination of the root canal morphology is the use of computed tomography (CT) to analyse three-dimensionally the unusual anatomy of the mandibular premolars with these configurations in axial, sagittal and coronal slices⁶.

In terms of medication, calcium hydroxide [Ca(OH)₂] paste is used for C-shaped root canals in order to disinfect the areas that instruments and irrigants cannot reach¹. With regard to root canal obturation, Kim et al¹⁶ compared warm gutta-percha filling techniques with conventional cold lateral condensation using simulated C-shaped root canals embedded in resin blocks. They concluded that warm gutta-percha condensation techniques can be expected to result in favourable canal filling in C-shaped root canals¹.

The purpose of this article is to present the root canal management of a first mandibular left premolar with a category 3 C-shaped configuration, using CT as a diagnostic and planning tool.

■ Case report

A 50-year-old Colombian woman with a non-contributory medical history was referred by the undergraduate clinic of endodontics to the postgraduate clinic of endodontics of the Universidad Central de Venezuela for root canal treatment of the left mandibular first premolar. At the time of the first examination, there was no spontaneous pain. The patient had a negative history of pain in tooth 34. She also reported no history of trauma.

Clinical examination revealed that the coronal morphology of the dimensions of tooth 34 and its anatomy were within normal limits and showed that the tooth had a deep defective temporary restoration at the occlusal aspect. There was no mobility, swelling or sinus tract, and periodontal probing depths were within normal limits. In addition, the tooth was not tender to percussion, and pulp sensitivity tests showed no response to cold or to electric pulp testing.

The radiographic evaluation of the premolar revealed an unusual and complex root canal anatomy with a distal curvature of the root (Fig 1). Due to the abnormal anatomy suggested by the radiograph, it was decided to perform a cone beam computed tomography (CBCT) (CS 9000:3D; Kodak, Rochester, NY, USA), which confirmed the presence of a lingual groove in the root.

Regarding the root canal, the CBCT showed a main ribbon-shaped canal that split at the mid-root level into two canals – one buccal and one lingual (Fig 2). In an axial section at the level of the middle third and in a sagittal section, a groove of invagination was observed at the level of the mesial surface of the root, being the main anatomical characteristic of teeth with a C-shaped canal (Fig 3). The length of the tooth was measured (Fig 4), and the distance was measured from the buccal cusp to the furcation level (14.3 mm) and used to locate the canals (Fig 5).

Based on the above clinical, radiographic and CBCT findings, a necrotic pulp was diagnosed in

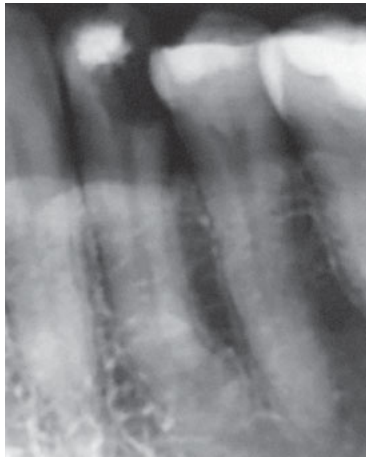


Fig 1 Preoperative radiograph of tooth 34.

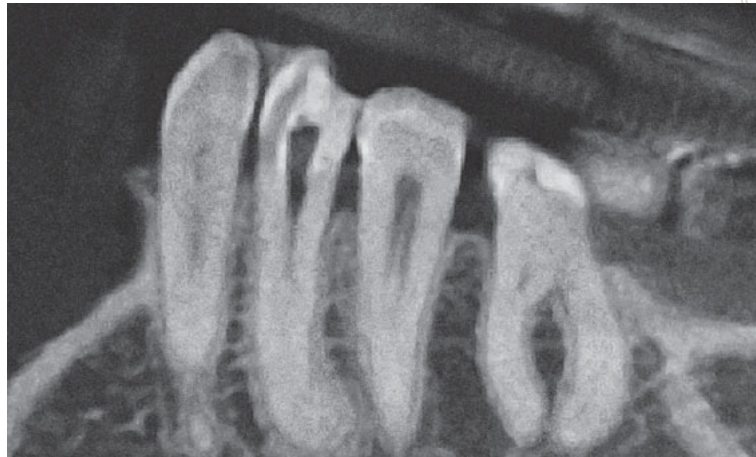


Fig 2 CBCT image showing the presence of a canal in a coronal section of tooth 34. The canal starts from the coronal third of the root and divides at the level of the middle third into two canals – one buccal and one lingual – thus continuing to the root apex.

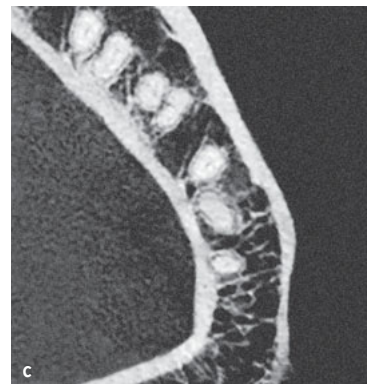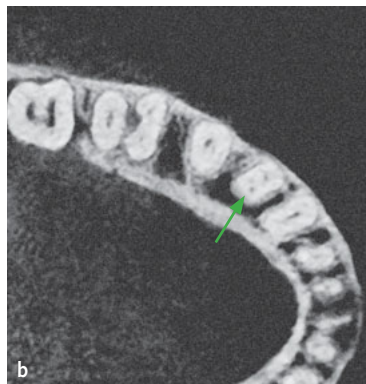
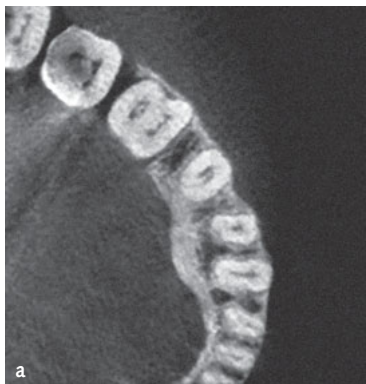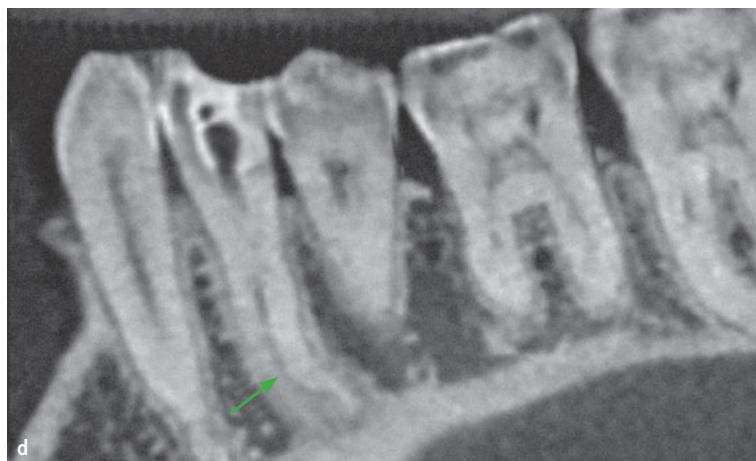


Fig 3 CBCT images. (a) Coronal third axial section of the root. (b and d) The green arrow indicates the lingual invagination groove in axial (b) and sagittal section (d). (c) Axial section of the apical third of the root.



tooth 34 revealing a C3 C-shaped canal classification, according to Fan et al⁵, and a nonsurgical root canal treatment was planned for the tooth over two visits.

At the first appointment, access to the root canal system was reached after anaesthetising the area

with 1.8 ml of 2% lidocaine with 1:100,000 epinephrine, and the use of rubber dam. Although a necrotic pulp was diagnosed, anaesthesia was used in order to avoid gingival discomfort when the rubber dam clamp was placed. By using an operative microscope (DF Vasconcellos, Rio de Janeiro, Brazil),

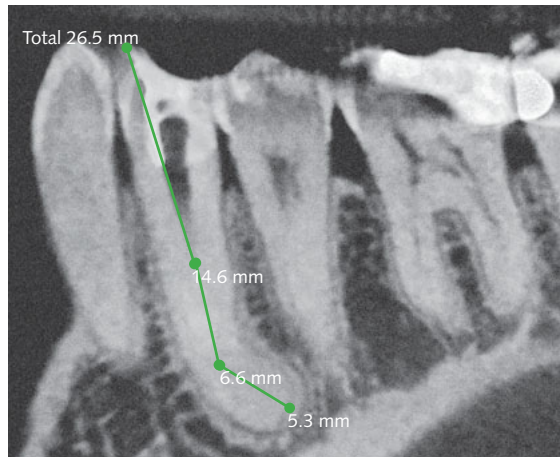


Fig 4 CBCT image. In a coronal section, the length of the tooth was measured from the buccal cusp to the root apex and was 26.5 mm.

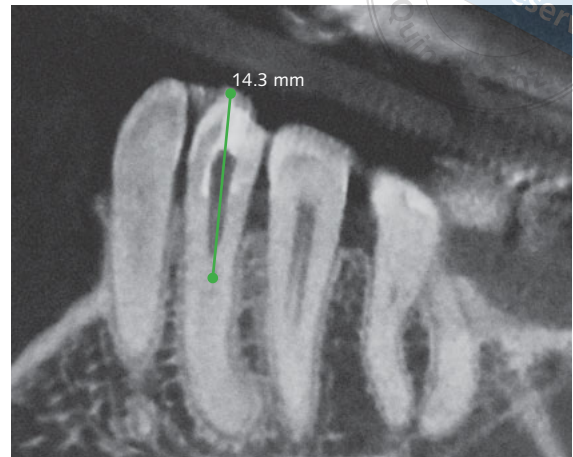


Fig 5 CBCT image. In a coronal section, the length was measured from the buccal cusp to the furcation level and was 14.3 mm.

the ribbon-shaped pulp chamber was found and enlarged with an ET 20D ultrasonic tip (Satelec, Mergnac, France). This root canal split into two narrow canals to the apex, at 14.3 mm to the buccal cusp tip, as stated above. The first of the two orifices was buccal and the other lingual. A working length radiograph was taken (Fig 6) when the apex locator indicated the appropriate length (Root ZX Mini; Morita, Osaka, Japan). Stainless steel hand K-files up to size 20 (K-Flexofiles, Dentsply Maillefer, Ballaigues, Switzerland) were first used to enlarge the canals. Next, rotary files (BioRace; FKG Dentaire, La Chaux-de-Fonds, Switzerland) were used to clean and shape the canals up to size BR4 35/04. The irrigant used during canal enlargement was 5.25% sodium hypochlorite (NaOCl) with a 27-gauge irrigation needle (Endo-Eze; Ultradent, South Jordan, Utah, USA).

Patency was achieved in all the root canals and was maintained with a size 10 K-file. After drying the canals with paper points, calcium hydroxide (Calsecure-P, Secure, Caracas, Venezuela) was used as an intracanal medicament with a lentulo size 30 (Maillefer, Ballaigues, Switzerland), and finally the access cavity was sealed with glass ionomer cement (Meron, Voco, Cuxhaven, Germany).

The patient returned to the clinic after 3 weeks, without any signs or symptoms of sinus tract, and after anaesthesia and rubber dam placement, the calcium hydroxide was removed from the root canals by means of EDT1 (Woodpecker DTE,

Guangxi, China) with a size 15 file placed in it and copious irrigation with 5.25% sodium hypochlorite solution until the irrigant solution was crystal clear. After drying the canals with paper points, the fitting of the greater taper gutta-percha cones was checked (Autofit, Analytic Endodontics Glendora, CA, USA) (Fig 7). Each canal was obturated using the continuous wave obturation technique with warm gutta-percha (E&Q Master META Biomed, Chungbuk, Korea) and AH Plus sealer (Dentsply, Konstanz, Germany). A composite restoration (Tetric Ceram, Ivoclar Vivadent, Germany) was placed and a radiograph taken (Fig 8).

After 6 months, the patient returned to the clinic. Radiographic control findings were satisfactory, tooth 34 was asymptomatic, and a control radiograph showed no evidence of periapical pathology (Fig 9).

■ Discussion

C-shaped root canals have an unusual root configuration due to the complexity of their structure (isthmuses, multiple root canals, apical deltas, lateral canals). Clinical and instrumental experience are required during the treatment of these cases in order to avoid complications.

Dental practitioners who regularly treat populations of different origins should be aware of the differences that could arise in certain ethnic groups and their

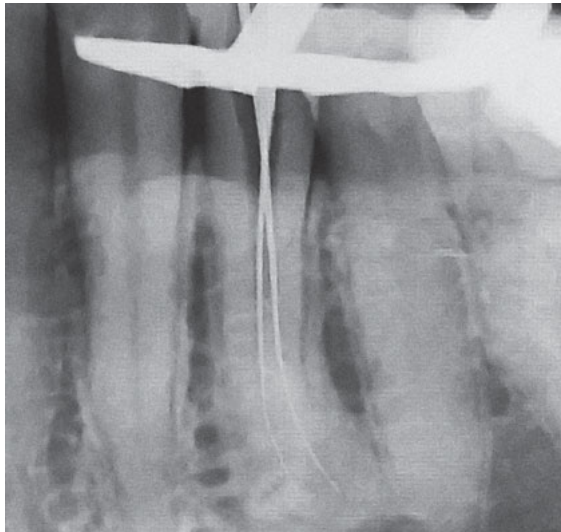


Fig 6 Working length radiograph.

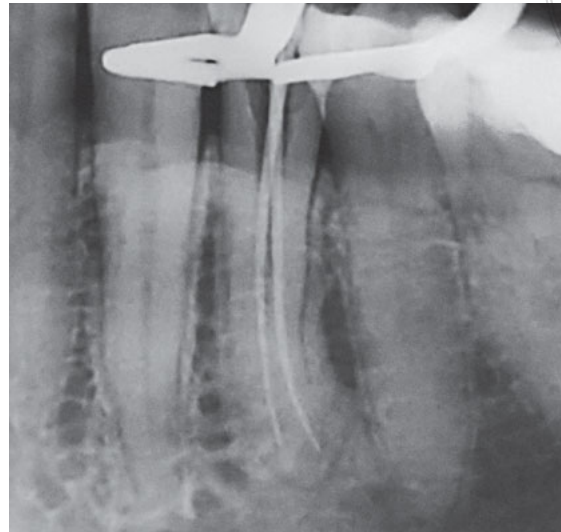


Fig 7 Gutta-percha master cones radiograph.

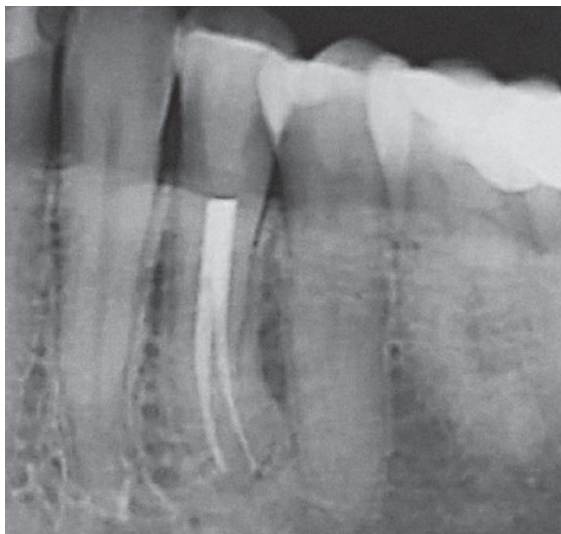

Fig 8 Immediate postoperative radiograph.

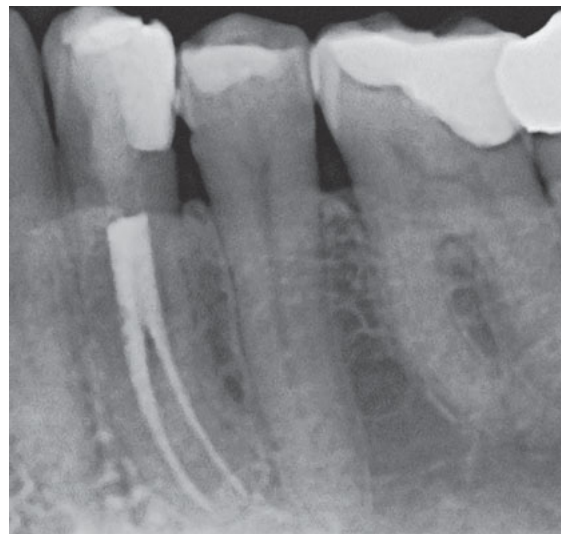

Fig 9 6-month follow up indicating healthy apical bone structure with no radiographic sign of periapical pathology.

possible influence on the anatomy of the pulp space, such as that reported by Baisden et al¹⁰, Sikri and Sikri¹¹ and Fan et al⁵. Since in Venezuela no related statistic is handled in mandibular premolars with 'C' configurations, it is very important to bear in mind that there is a prevalence of this anatomical variation in the population. Having this knowledge would guarantee a better prognosis in the handling of such cases.

A thorough understanding of the morphology of the root canal system is essential, as well as the careful interpretation of angulated radiographs, and the use of CT to evaluate the root canal system in

more detail and accuracy, including planification of an access cavity, a thorough initial exploration with pre-curved and low-gauge files, and the use of magnification and illumination throughout the treatment to achieve an adequate diagnosis and successful treatment^{1,4,12,13}.

In mandibular premolars, coronally, it is a single oval canal and the C-shaped anatomy that is located at the apical 3.0 mm and/or 6.0 mm level cross-sections, making identification of C-shaped anatomy in mandibular premolars more challenging^{3,4}. Thus, C-shaped canals would be difficult to detect from

the coronal approach, reinforcing the importance of coronal enlargement with ultrasonic tips under enhanced illumination and magnification using an operative microscope and with careful planning aided by CBCT¹.

The root canal treatment of the C-shaped mandibular second premolar required a careful instrumentation strategy due to the difficulty of disinfecting the canals in the thin root area around a concavity without compromising the root structure. This is why CBCT was used in the present case to analyse the aberrant anatomy prior to chemomechanical preparation^{1,5,14}.

The clinicians who carry out the treatment of complex cases related to the morphology of the root canal system must be patient, since appointments can be prolonged and may increase in number. The time involved in the treatment of such complex cases depends mainly on the clinical skill, experience and competence of the endodontist and the availability of specialised instruments and equipment¹⁵⁻¹⁷.

■ Conclusion

Although the occurrence of mandibular first premolars with C-shaped canals is rare, clinicians should be aware of the anatomical variations of this tooth. CBCT imaging is advantageous and an essential diagnostic tool in detecting complex variants compared with conventional routine radiography. A well-scanned image will portray all the details and anomalies present, if any, and lead to successful root canal treatment. However, it is every clinician's responsibility to weigh the benefits and risks for each patient before recommending CBCT imaging.

■ Disclosure statement

The authors declare that there are no conflicts of interest.

■ References

1. Kato A, Ziegler A, Higuchi N, Nakata K, Nakamura H, Ohno N. Aetiology, incidence and morphology of the C-shaped root canal system and its impact on clinical endodontics. *Int Endod J* 2014;47:1012–1033.
2. Sert S, Bayirli GS. Evaluation of the root canal configurations of the mandibular and maxillary permanent teeth by gender in the Turkish population. *J Endod* 2004;30:391–398.
3. Kato A, Ohno N. Construction of three-dimensional tooth model by micro-computed tomography and application for data sharing. *Clin Oral Investig* 2009;13:43–46.
4. Rödiger T, Hülsmann M. Diagnosis and root canal treatment of a mandibular second premolar with three root canals. *Int Endod J* 2003;36:912–919.
5. Fan B, Yang J, Gutmann JL, Fan M. Root canal systems in mandibular first premolars with C-shaped root configurations. Part I: Microcomputed tomography mapping of the radicular groove and associated root canal cross-sections. *J Endod* 2008;34:1337–1341.
6. Park JB, Kim N, Park S, Kim Y, Ko Y. Evaluation of root anatomy of permanent mandibular premolars and molars in a Korean population with cone-beam computed tomography. *Eur J Dent* 2013;7:94–101.
7. Manning SA. Root canal anatomy of mandibular second molars. Part II. C-shaped canals. *Int Endod J* 1990;23:40–45.
8. Jafarzadeh H, Wu YN. The C-shaped root canal configuration: a review. *J Endod* 2007;33:517–523.
9. Lu TY, Yang SF, Pai SF. Complicated root canal morphology of mandibular first premolar in a Chinese population using the cross section method. *J Endod* 2006;32:932–936.
10. Baisden MK, Kulild JC, Weller RN. Root canal configuration of the mandibular first premolar. *J Endod* 1992;18:505–508.
11. Sikri VK, Sikri P. Mandibular premolars: aberrations in pulp space morphology. *Indian J Dent Res* 1994;5:9–14.
12. Vertucci FJ. Root canal morphology and its relationship to endodontic procedures. *Endodontic Topics* 2005;10:3–29.
13. Albuquerque D, Kottoor J, Hammo M. Endodontic and clinical considerations in the management of variable anatomy in mandibular premolars: a literature review. *Biomed Res Int* 2014;512574. doi: 10.1155/2014/512574. [Epub ahead of print 8 May 2014].
14. Gomez-Sosa JF, Caviedes-Buchelli J, Goncalves-Pereira J. Root canal treatment of a mandibular second premolar with a category 3 C-shaped root canal anatomy: a case report. *ENDO (Lond Engl)* 2018;12:21–28.
15. Kim HH, Cho KM, Kim JW. Comparison of warm gutta-percha condensation techniques in ribbon shaped canal: weight of filled gutta-percha. *J Korean Acad Conserv Dent* 2002;27: 277–283.
16. Shetty A, Hegde MN, Tahiliani D, Shetty H, Bhat GT, Shetty S. A three-dimensional study of variations in root canal morphology using cone-beam computed tomography of mandibular premolars in a South Indian population. *J Clin Diagn Res* 2014;8:ZC22–ZC24.
17. Bertrand T, Kim SG. Endodontic treatment of a C-shaped mandibular second premolar with four root canals and three apical foramina: a case report. *Restor Dent Endod* 2016;41:68–73.