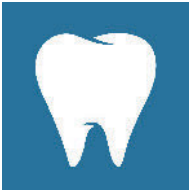

Pulpotomy in permanent teeth



Background

Pulpotomies are primarily carried out as a measure to maintain vitality of juvenile permanent teeth whose roots have not yet fully developed. The indications range from partial pulpitis to complex crown fractures to pulp polyps [7]. This therapy is usually not applied in permanent teeth with fully developed roots and irreversible pulpitis, due to the alleged poor regenerative capacity of the pulp. In this case, a pulpectomy is the treatment of choice. In the last few years, several studies were published that investigated the success rates of pulpotomies as a measure to maintain vitality of permanent teeth, specifically that of teeth with carious-exposed pulps and pain symptoms.

A new therapy approach pursued by some authors is the conservation of vitality of teeth with pulpitis. The following provides a short overview of the up-to-date literature on this topic. Though, currently, only very few studies exist on the therapeutic success of a pulpotomy as an alternative to a pulpectomy in permanent teeth with fully developed roots.

Statement

Reviews

Aguiar et al. [1] compared the success rate of partial pulpotomies, coronal pulpotomies and direct capping. They were able to show that direct capping is inferior in therapeutic effect to both types of pulpotomy due to its large variations of success rate. The partial pulpotomy showed success rates of 94,6 % in teeth with open root apices and

90,6 % in teeth with closed root apices. This was higher than the success rates in teeth treated with a coronal pulpotomy, which were 91,4 % and 85,9 %, respectively.

In 2014, Yazdani et al. [10] published a “Health technology assessment” on pulpotomies with calcium enriched mixture (CEM) in permanent teeth with irreversible pulpitis. They assessed the shortterm and longterm success of the treatment, as well as the organizational and economical aspects of the procedure. In addition, the reliability of the method was examined in comparison to a root canal treatment. In summary, authors evaluated the pulpotomy as a valid method with high therapeutic success similar to a root canal procedure. Therefore, from a socio-economic viewpoint, the authors concluded that pulpotomy is preferable to a pulpectomy.

Akhlaghi et al. [2] investigated the therapeutic success of 4 different approaches of maintaining pulp vitality: indirect capping, direct capping, partial pulpotomy and coronal pulpotomy. No inclusion or exclusion criteria were defined for the studies selected. The partial pulpotomy with subsequent pulp capping using calcium hydroxide presented a success rate of 91–100 % after 2 years. With regard to the clinical outcome, the results did not differ significantly to those of the partial pulpotomy with mineral trioxide aggregate (MTA; 95,2–99,8 %). The 2-year success rate of the coronal pulpotomy was similar at 87,5–100 % (calcium hydroxide) and 90–100 % (MTA).

Alqaderi et al. [3] examined the success rate of coronal pulpotomies

in vital permanent teeth with fully developed roots and carious-exposed pulp. On average, the success rates were over 90 %. In addition, the impact of direct capping materials and restorative materials on treatment success was analyzed. The results showed higher success rates for MTA (95 % after 1 year; 93 % after 2 years) than for calcium hydroxide (92 % after 1 year; 88 % after 2 years). Teeth that were treated with amalgam fillings showed better results after 1 year (success rate of 95 %) but worse results after 2 years (success rate of 92 %) in comparison to teeth that were treated with composite fillings (success rates of 91 % after 1 year and 93 % after 2 years).

Clinical studies

Asgary et al. [4] published a retrospective study on pulpotomies with subsequent calcium hydroxide pulp capping as an alternative to root canal treatment. Pulpotomies were performed in 567 permanent teeth with symptomatic or asymptomatic pulpitis (carious-exposed pulp, no pain symptoms). 273 cases were evaluated with a follow-up after 1, 2, 3, 4, 5 and 10 years. The success rates were 89 % after 1 year, 75 % after 5 years and 63 % after 10 years.

Asgary et al. [6] investigated the impact of various capping materials on the success rate of pulpotomies. A coronal pulpotomy with subsequent pulp capping using MTA or calcium-enriched mixture (CEM) was performed in 244 permanent molars that showed the clinical signs of an irreversible pulpitis (patients aged 9–65 years). Following treatment, the teeth were sealed tempo-

rarily. After 7 days, they were restored with amalgam fillings. The clinical success rate of teeth restored with MTA was 98,9 % after 2 years and 98,1 % after 5 years.

Taha et al. [9] treated 50 vital permanent molars (patient age < 20 years) with fully developed roots, deep carious lesions and clinical signs of irreversible pulpitis (provided that hemostasis was possible within 6 minutes after pulp exposure). 27 teeth were treated with white ProRoot MTA (Dentsply, Tulsa OK) and 23 teeth were treated with a calcium hydroxide compound (Dycal, Dentsply Caulk, Milford, DE). The success rates of MTA after 6 months, 1 year and 2 years were at 84 %, 83 % and 85 %, respectively. The success rates of calcium hydroxide compound (Dycal) after 6 months, 1 year and 2 years were 62 %, 55 % and 43 %, respectively. Therefore, the authors recommend MTA as suitable capping material.

Qudeimat et al. [8] achieved a success rate of 100 % in their study of pulpotomy in permanent molars of children and teenagers (medium age: $10,7 \pm 1,7$ years). All teeth treated showed clinical signs of irreversible pulpitis. According to the authors, 78 % of teeth showed radiographic periapical lesions.

Case report

Asgary et al. [5] performed a pulpotomy with CEM on two maxillary molars (14 and 15; Universal Numbering System) of a 36-year old patient with irreversible pulpitis instead of pulpectomy and subsequent root canal treatment. Afterwards, the teeth were restored with amalgam restorations. After 2 years both teeth were asymptomatic and showed neither clinical nor radiographic signs of inflammation.

Conclusion

Summarising the results of the present studies, it can be stated that pulpotomies in permanent teeth with carious-exposed pulp might be a valid alternative treatment option. From the perspective of restorative dentistry, maintaining vitality of such teeth would be desirable considering the anticipated clinical

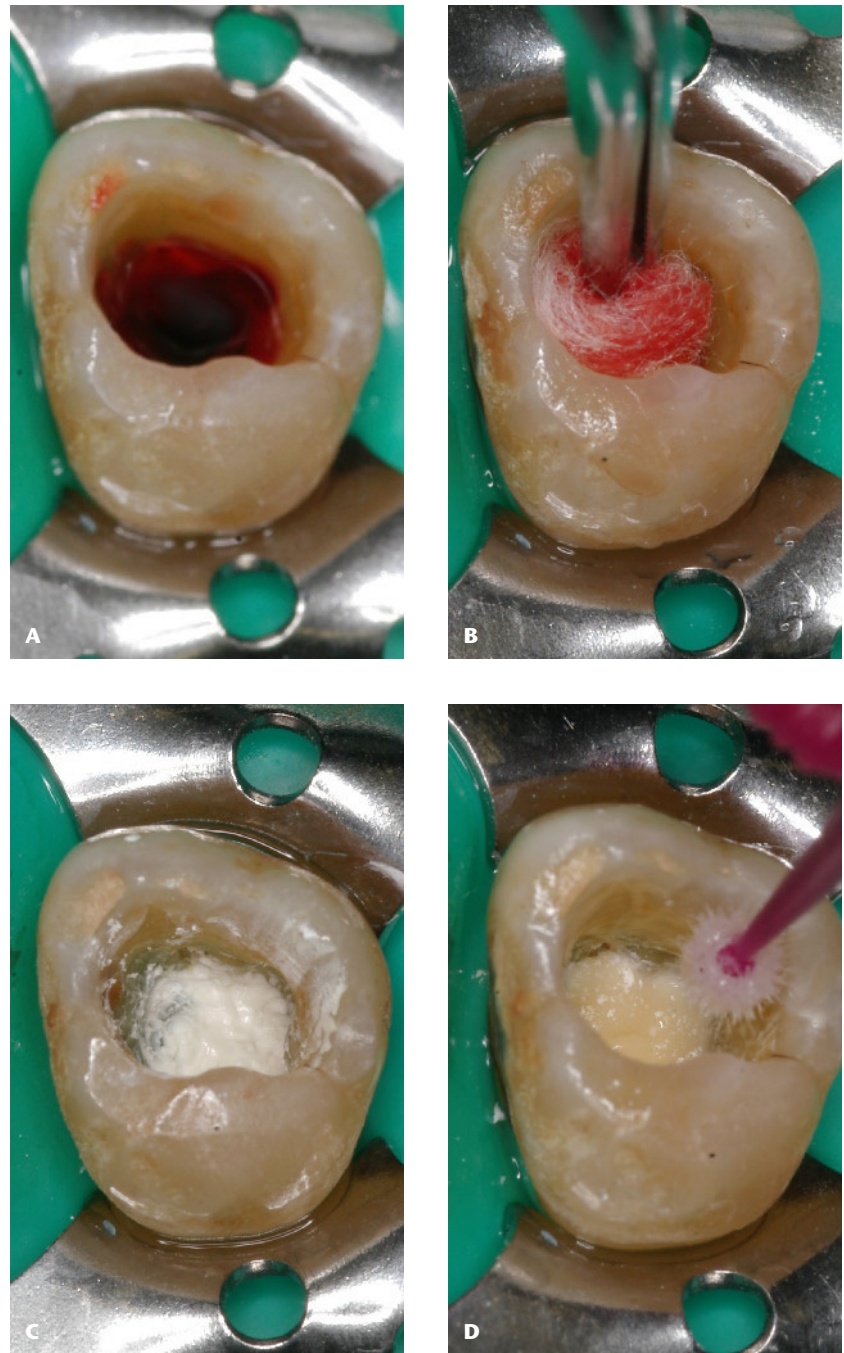


Figure 1A–D Exemplary clinical procedure; **A:** Bleeding after pulpotomy under rubber dam; **B:** Hemostasis; **C:** Cover with calcium hydroxide-containing mixture; **D:** Cover with glass ionomer cement and application of adhesive

(Fig. 1A–D: V. Becker)

benefit (preservation of structural integrity). Nevertheless, the valid clinical assessment of the pulp condition, or rather the extent of inflammation is a methodical difficulty that affects the possibility of success. Furthermore, the endodontic treatment after failure could be made difficult due to new formation of dentin in the area of root canal orifices.

Literature

1. Aguilar P, Linsuwanont P: Vital pulp therapy in vital permanent teeth with cariously exposed pulp: A systematic review. *J Endod* 2011; 37: 581–587
2. Akhlaghi N, Khademi A: Outcomes of vital pulp therapy in permanent teeth with different medicaments based on review of the literature. *Dent Res J* 2015; 12: 406–417

3. Alqaderi H, Lee C-T, Borzangy S, Pagonis TC: Coronal pulpotomy for cariously exposed permanent posterior teeth with closed apices: A systematic review and meta-analysis. *J Dent* 2016; 44: 1–7
4. Asgary S, Shirvai A: Pulpotomy with calcium hydroxide may be an effective alternative to root canal therapy in vital teeth. *J Evid Based Dent Pract* 2016; 16: 64–66
5. Asgary S, Verma P, Nosrat A: Treatment outcomes of full pulpotomy as an alternative to tooth extraction in molars with hyperplastic/irreversible pulpitis: a case report. *Iran Endod J* 2017; 12: 261–265
6. Asgary S, Hassanizadeh R, Torabzadeh H, Eghbal MJ: Treatment outcomes of 4 vital pulp therapies in mature molars. *J Endod* 2018; 44: 529–535
7. Koçkapan C: *Curriculum Endodontie*. Quintessenz Verlag, Berlin 2003, 151–152
8. Qudeimat MA, Alyahya A, Hasan AA: Mineral trioxide aggregate pulpotomy

for permanent molars with clinical signs indicative of irreversible pulpitis: A preliminary study. *Int Endod J* 2017; 50: 126–134

9. Taha NA, Khazali MA: Partial pulpotomy in mature permanent teeth with clinical signs indicative of irreversible

pulpitis: a randomized clinical trial. *J Endod* 2017; 43: 1417–1421

10. Yazdani S, Jadidfard M-P, Tahani B, Kazemian A, Dianat O, Marvasti LA: Health technology assessment of CEM pulpotomy in permanent molars with irreversible pulpitis. *Iran Endod J* 2014; 9: 23–29



(Photo: privat)

VALERIA BECKER
 University Medicine Rostock
 Polyclinic for Dental Preservation
 and Periodontology
 Stempelstr. 13, 18057 Rostock
 Valeria.Becker@med.uni-rostock.de



(Photo: privat)

PROF. DR. HERMANN LANG
 University Medicine Rostock
 Polyclinic for Dental Preservation
 and Periodontology
 Stempelstr. 13, 18057 Rostock
 Hermann.Lang@med.uni-rostock.de