

# Influence of low-intensity pulsed ultrasound on bone repair upon irradiation: a histomorphometric study in rabbits

Bob Biewer <sup>1,5</sup>, Felix Kleine Borgmann <sup>2,3</sup>, Eric Rompen <sup>1</sup>, Michel Mittelbronn <sup>2-5</sup>, Pascale Quatresooz <sup>6</sup>

1 School of Dental Medicine - University of Liège, Belgium  
 2 Luxembourg Center of Neuropathology (LCNP), Luxembourg  
 3 Department of Oncology (DONC), Luxembourg Institute of Health (LIH), Luxembourg  
 4 Luxembourg Centre for Systems Biomedicine (LCSB), University of Luxembourg, Luxembourg  
 5 National Center of Pathology (NCP), Laboratoire national de santé (LNS), Dudelange, Luxembourg  
 6 University Hospital, Dept. of Human Histology and Dermatopathology - University of Liège, Belgium

## Background:

Radiotherapy damages cancer cells but can also harm healthy cells in the treated area. Rapidly dividing cells such as skin cells or hematopoietic cells in the bone marrow are the most affected. The mandible is a frequently affected bone, since in the majority of head and neck cancer treatments it is inevitably exposed to radiation, and osteoradionecrosis is therefore a serious complication. Different previous studies have suggested that the use of low-intensity pulsed ultrasound (LIPUS) may have beneficial effects in the healing dynamics of bone tissue.

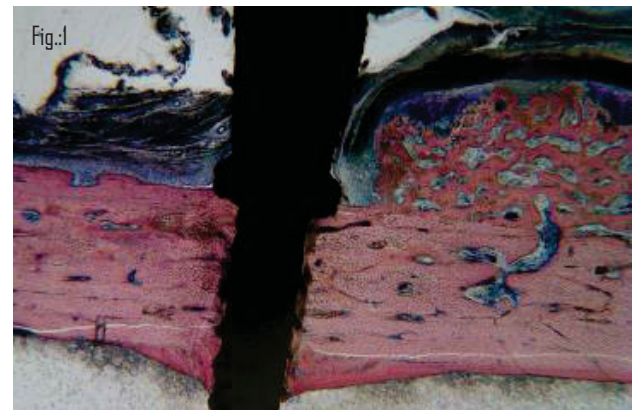
## Aim/Hypothesis:

The present study evaluated the influence of low-intensity pulsed ultrasound on regeneration processes of bone defects below the critical size in irradiated and non-irradiated rabbit tibia.

## Material and methods:

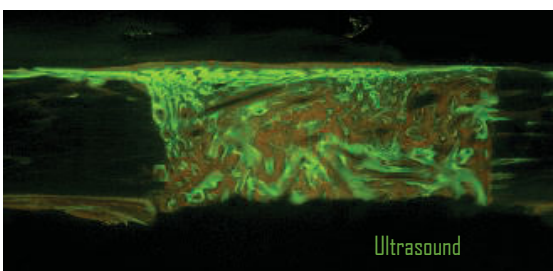
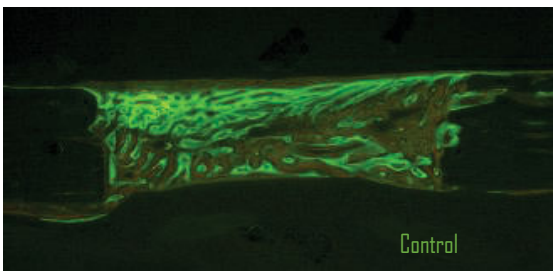
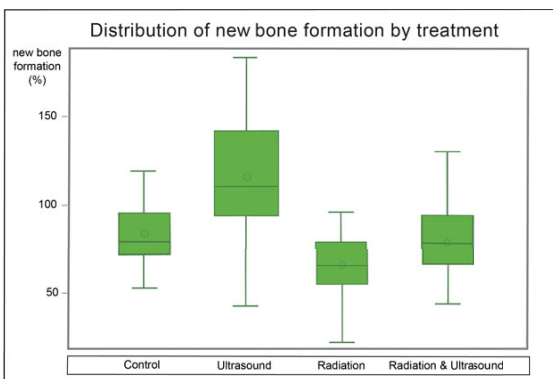
The study was based on a total of six white New-Zealand adult female rabbits. Apart from surgery to create bone defects on all tibiae, the following four treatments were randomly added on: (1) C group: only the surgical procedure was applied with no additional treatment, serving as the control, (2) R group, the irradiated side received 15 Gy in single dose, (3) US group, treated with LIPUS, and (4) R+US, irradiated with 15 Gy and treated with LIPUS (n=6 defects per group). Tibiae were irradiated under general anesthesia applying a single dose of 15 Gy three days prior to the surgery. The surgery was done under strict aseptic conditions with gentle atraumatic techniques. A titanium pin (fig.1) was placed into the cortical bone of the medial part of the proximal tibial metaphysis in order to keep a surgical guide in place when drilling two holes of 3mm in diameter under continuous saline irrigation into the bone. This allowed a standardized treatment procedure and a correct relocation of the experimental area after healing processes. Four different fluorochrome dyes were injected at two-week intervals in order to have a sequential follow up of the tissue growth. The LIPUS stimulation in all concerned group sides started 48h after surgery under sedation. Ultrasounds were applied daily for 20 min, and the skin was shaved once a week to ensure close transducer contact and a no-air proliferation of the ultrasound waves. All rabbits were sacrificed after eight weeks with an overdose of pentobarbital under general anesthesia. The fixed biopsies were embedded in methylmethacrylate resin.

80-100 µm thick serial sections were prepared with a sawing microtome and then ground and polished to yield undecalcified sections with a final thickness of 20 to 40 µm. Some sections were stained for bright field analysis with Stevenel's blue and van Gieson's picrofuchsin, where osteoid tissue appears in green, and mineralized bone in red color, while others were left unstained for quantitative confocal analyses.



## Results:

No complications were seen in the postoperative healing periods, and all rabbits (n=6) could be included for statistical analysis. Quantitative histomorphometric evaluation results are shown in the table below. An ANOVA analysis was performed to show the variance among and between groups. If the p-value is less than 0.05, the H0 (null) hypothesis can be accepted: at least two of the subgroups differ significantly. The surgery control samples showed 83.10% ± 17.79% of bone repair after 9 weeks while the irradiated bone had significantly (p < 0.5) less regenerated during the same period (66.42% ± 29.36%). LIPUS treatment on irradiated bones performed a 79.21% ± 21.07% bone fill and could not significantly (p > 0.05) improve the response compared to the non-treated irradiated specimens. In the irradiated bones, ultrasound treatment produced only 3.89% less new bone compared to the untreated control group; this repair is insignificantly lower than the natural bone healing in the untreated control group. LIPUS treatment on non-irradiated bone, however, showed bone formations beyond the size defect (115.91% ± 33.69%), highly significantly different when compared to the control group or any irradiated group. It is noteworthy that the application of ultrasound to healthy bone, produced highly significantly enhanced bone formations, with 36.70% more regenerated bone when comparing the same application on irradiated bone (79.21% ± 21.07%). New bone appositions were also observed under the periosteum, around the pin holding the surgical guide (fig.1). This confirms that maintaining a secluded space is sufficient for bone formation even outside of the skeletal boundaries.



## Conclusions and clinical implications:

Low Intensity Pulsed Ultrasound may be considered as a promising complementary treatment approach in bone regeneration procedures of non-irradiated bone defects. LIPUS vibration stimuli may give possibilities to shorten the treatment and to enhance bone healing. In irradiated bones, however, the effect of ultrasound application is less apparent and further studies are needed to refine the dynamics of the present results.

	Percentage of new tissue formation			
	Control	Ultrasound	Radiation	Radiation + Ultrasound
Max	120.82	183.46	169.37	130.17
Q3	95.72	141.75	79.11	94.25
Mean	83.10	115.91**	66.42*	79.21
Median	78.94	110.55	65.62	78.11
Q1	71.73	93.87	55.15	66.58
Min	52.89	42.91	22.26	44.12

(\*\*) significantly different from control (p<0.05)      (\*\*\*) highly significantly different from control (p<0.001)