

Authors: Dr Jayashree K, Dr Aishwarya R, Dr Karthikeya Patil
 Department of Pathology, JSS Medical College, Department of Oral Medicine and Radiology, JSS Dental College and Hospital, JSS AHER, Mysuru

Introduction:

Squamous cell carcinoma (SCC) accounts for almost 90% of head and neck cancers. Currently the most important prognostic factor is TNM staging but the poor survivability of a cohort of patients with low TNM staging has emphasized the need of new grading schemes. Recently, the WHO has considered tumour budding as a novel grading scheme with a high impact on patient outcome in squamous cell carcinoma of the lung. This study was undertaken to probe whether tumour budding could be applied to head and neck squamous cell carcinoma as a novel grading scheme.

Objective:

The purpose of this study was to assess the correlation of tumour budding with the clinicopathologic features and to evaluate its prognostic significance for head and neck squamous cell carcinoma (HNSCC).

Methodology:

30 cases of HNSCC were examined for tumour characteristics, grade, and tumour budding. Statistical analyses were carried out to assess the correlation of tumour budding with clinicopathologic parameters and patient survival.

TABLE 1. Algorithm for Determining Tumour Grade from Tumour Budding Activity and Cell Nest Size Scores in HNSCC

Grading Proposal for Head and Neck Squamous Cell Carcinoma

Tumour budding activity/10HPF	Score
1. No budding	1
2. <15 budding foci	2
3. >15 budding foci	3
Smallest cell nest size within tumour core	
1. >15 cells	1
2. 5-15 cells	2
3. 2-4 cells	3
4. Single cell invasion	4
Tumour grading	Total score (Tumour budding score + Cell nest size score)
1. Well differentiated (G1)	2-3
2. Moderately differentiated (G2)	4-5
3. Poorly differentiated (G3)	6-7

TABLE 2. Correlation of Prognostic Factors with Tumour Budding

		No budding	Tumour budding	
			Low Intensity	High Intensity
Tumour Size	≤5	2	5	3
	≥5	-	5	15
Differentiation	Well	2	2	0
	Mod		8	10
	Poor		0	8
Stage	T-1	2	2	2
	T-2		5	5
	T-3		2	6
	T-4		1	5
Lymph node Metastasis	Neg	2	6	1
	Pos		4	17

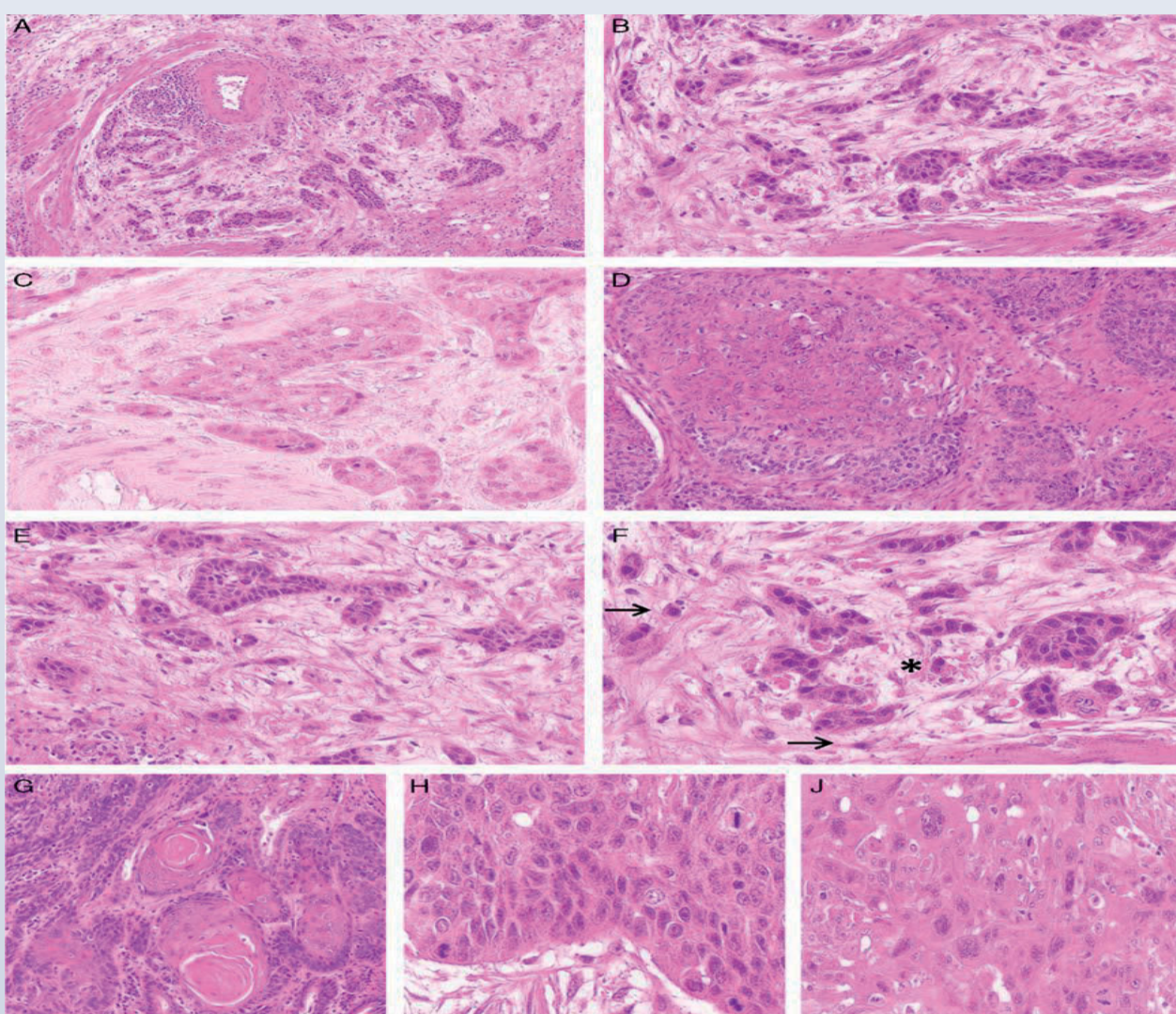


FIGURE 1. Histomorphologic characteristics of HNSCC (HE). A–C, Tumour budding: overview (A) and (B) HNSCC with high tumour budding activity, indicated by the branching of numerous small tumour clusters of <5 cells into the surrounding tissue; (C) low tumour budding activity with a single tumour cluster <5 cells budding into the tumour stroma. D–F, Cell nest size: (D) large and medium-sized cell nests. (E) small cell nests (F) single-cell invasion.

Discussion and Conclusions:

Tumour budding was observed in 90.33% of cases, with a mean tumour bud count of 8.5 (range from 1 to 32 buds). High intensity budding (>5 tumour buds) was observed in 18 cases (60%). Statistical analysis revealed that tumour budding was associated with tumour size, differentiation, clinical stage, and lymph node metastasis, which correlated with reduced overall survival.

In conclusion, the significant association of "Tumour Budding" with the various morphological parameters verifies the almost perfect transferability of this highly prognostic, easily applicable Novel Grading Scheme as a strong predictor of patient outcomes in Head and Neck SCC.

References:

1. Arnold M, Soerjomataram I, Ferlay J, et al. Global incidence of oesophageal cancer by histological subtype in 2012. *Gut*. 2015;64:381–387.
2. Sobin LH, Gospodarowicz MK, Wittekind C. *TNM Classification of Malignant Tumours*. Hoboken, New Jersey: JohnWiley & Sons; 2011.
3. Ohashi S, Miyamoto S, Kikuchi O, et al. Recent advances from basic and clinical studies of esophageal squamous cell carcinoma. *Gastroenterology*. 2015;149:1700–1715.
4. Pennathur A, Gibson MK, Jobe BA, et al. Oesophageal carcinoma. *Lancet*. 2013;381:400–412.
5. Teramoto H, Koike M, Tanaka C, et al. Tumor budding as a useful prognostic marker in T1-stage squamous cell carcinoma of the esophagus. *J Surg Oncol*. 2013;108:42–46.
6. Weichert W, Kossakowski C, Harms A, et al. Proposal of a prognostically relevant grading scheme for pulmonary squamous cell carcinoma. *Eur Respir J*. 2016;47:938–946.
7. Kadota K, Nitadori J, Woo KM, et al. Comprehensive pathological analyses in lung squamous cell carcinoma: single cell invasion, nuclear diameter, and tumor budding are independent prognostic factors for worse outcomes. *J Thorac Oncol*. 2014;9:1126–1139.