

Bucco-lingual orientation of the inferior alveolar nerve as adjunct information for implant planning amongst the three ethnicities of Malaysians

Koh Wen Jiong, Michelle Chua Kher Wei, Pravinkumar G. Patil

School of Dentistry, International Medical University, Malaysia



Introduction

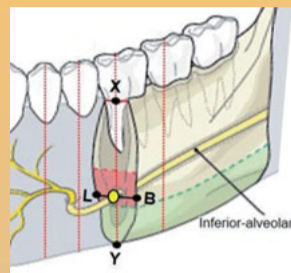
Information on the bucco-lingual orientation of the inferior alveolar nerve (IAN) can reduce the risk of iatrogenic injury to the nerve during implant placement, especially in settings where cone-beam computed tomography (CBCT) is not available.¹

The general course of the IAN progresses from the lingual to the buccal side.² 70% of IANs appear as an S-shaped curve, where it approaches the lingual surface of the mandible in the molar regions stretching forward in a buccal direction.³

Due to the tortuous and variable nature of the mandibular canal, this study is important to serve as a adjunct guide in estimating the location of the IAN prior to implant procedure.

The inferior alveolar nerve was traced and highlighted in pink from its entry at the lingula to the mental foramen. At the cross section of molars (36, 37, 46, 47 regions), the canal size, buccal and lingual bone-width at the canal level were measured.

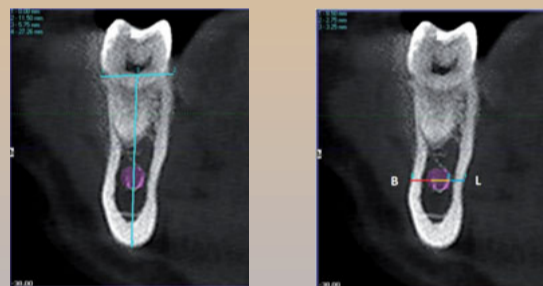
Measurement and Analysis



Landmarks:

X: Crest of ridge
Y: Lower border of mandible
L, B: Points of intersection between level of IAN and outer lingual, buccal cortical layer

First, a horizontal line is drawn along the crest of the ridge. At the midpoint (**X**), a vertical line is drawn from the ridge to the lowermost tip of the lower border of the mandible (**Y**). This vertical line is line **XY**. The buccal, central, and lingual location of the IAN is identified at the canal level (along the line **LB**) in relation to the line **XY**.

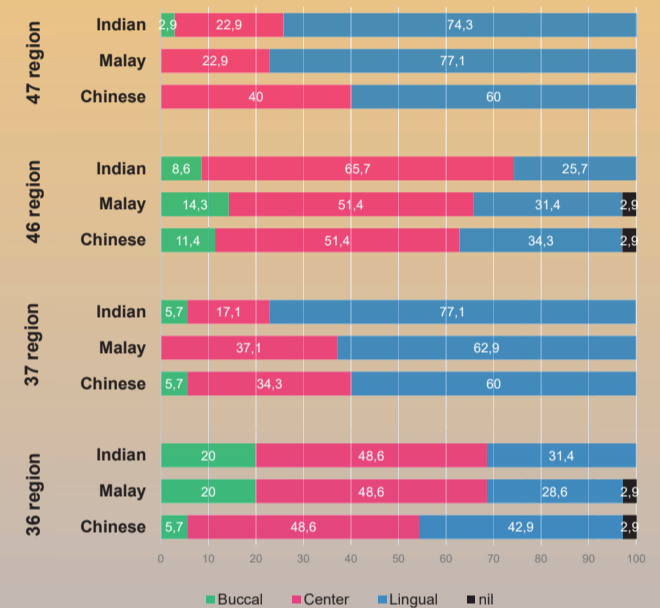


In the Malay population, 48.6% (36 region) and 51.4% (46 region) of IANs were located at the center; 62.9% (37 region) and 77.1% (47 region) were placed lingually.

In the Chinese-Malaysian population, 48.6% (36 region) and 51.4% (46 region) of IANs were located at the center; 60% (37 region) and 60% (47 region) were placed lingually.

In the Indian-Malaysian population, 48.6% (36 region) and 65.7% (46 region) of IANs were located at the center; 77.1% (37 region) and 74.3% (47 region) were placed lingually.

Bucco-lingual orientation of the IAN in molar regions among three ethnic groups



Objective

- To estimate the bucco-lingual orientation of the IAN in the mandibular molar region on both sides of the mandible.
- To evaluate side- and ethnicity-related variations in the bucco-lingual orientation of the IAN in mandibular molars in the study population.

Methods

A total of 105 CBCT-DICOM files (n=35 per ethnic group) selected with stratified sampling followed by a simple random method using registration numbers from the IMU-dental clinic were examined to determine the bucco-lingual orientation of the IAN in the 1st and 2nd molar regions.

Inclusion criteria

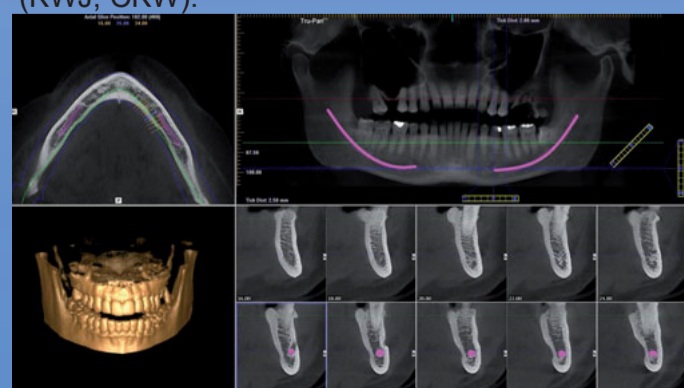- Dentate or edentulous Malaysian patients.
- Between the ages of 18 and 80 years.
- Healthy, medically compromised or even those previously radiated patients but not involving the interforaminal mandible region.

Exclusion criteria

- History of trauma or pathology to the mandible.
- History of surgical intervention to the interforaminal region.
- Patients of mixed racial origins.
- Patients with existing pathological disorder at mandible.
- Unclear CBCT images.

Consent was obtained from patients who qualified to participate prior to the measurement.

By viewing DICOM data in iCAT software, the anatomy of the entire mandible was assessed in axial, coronal cross-sectional, and panoramic views. Visibility rating and dimensional measurements were performed by researchers (KWJ, CKW).

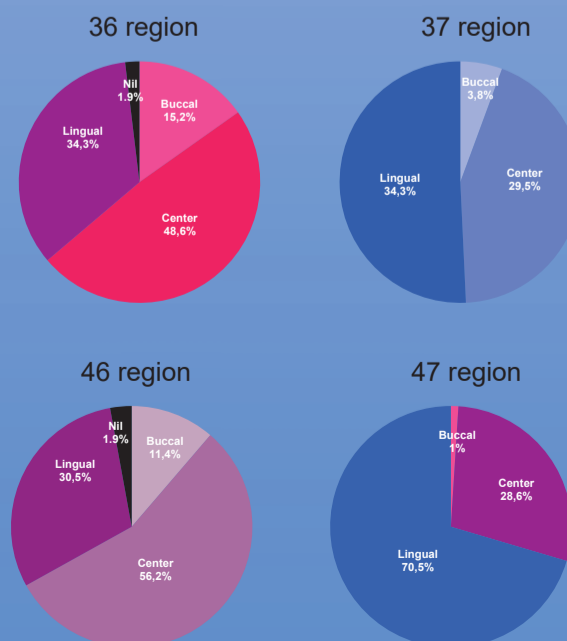


To determine the buccal, lingual bone width at canal level, a horizontal line was drawn at the canal level (**line LB**). The thicknesses of the buccal, lingual bone width and canal size were measured by plotting the points from the buccal cortical layer – buccal canal wall – lingual canal wall – lingual cortical layer.

This measurement was used to determine the variations between both sides and ethnicities. A one-way analysis of variance (ANOVA) test was performed using SPSS Version 24 software.

Results

The bucco-lingual orientation of the IAN in molar regions among this Malaysian population presented in the pie charts below.



A statistically significant ($P < .05$) difference was found between the left and right sides of all measurements in the 2nd molar region, and buccal bone width and canal size of the IAN in the 1st molar region. A statistically significant difference was found in buccal bone width and IAN canal size in the 37 region between Malaysian-Indian and Malay populations.

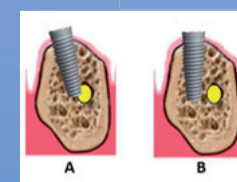
Conclusion

The IAN was located at the center in the 1st molar region and on the lingual side in the 2nd molar region.

There are significant variations in buccal, lingual bone width and canal size on both sides.

Ethnicity-associated variations were identified between Indian-Malaysian and Malay populations.

Clinical Implications



Understanding the position of the IAN is crucial in performing a successful implant placement. By knowing its bucco-lingual location, the angle of entry of

the implant can be planned prior to the treatment to prevent iatrogenic injury to the nerve (Picture A). This allows safe treatment (Picture B) and a high success rate.

References

- Wang JC, Gui L, Zhang ZY, Niu F, Cai JL. Significance of location of mandibular canal by 3-dimensional CT in the mandibular angle osteotomy. Zhonghua Zheng Xing Wai Ke Za Zhi 2008;24:360-2.
- Mirbeigi S, Safaee A, Ezoddini F, Khojastepour L, Navab-Azam A. Buccolingual course of the inferior alveolar canal in different mental foramen locations: A CBCT study of an Iranian population. Int J Appl Basic Med Res 2016;6(4):262.
- Juodzbalys G, Wang HL, Sabalys G. Anatomy of Mandibular Vital Structures. J Oral Maxillofac Res 2010;1(1);e2: 1-8.