

MORAWIEC T.<sup>1</sup>, KOWNACKI P.<sup>1</sup>, RÓJ R.<sup>2</sup>, WRZOŁ M.<sup>1</sup>, ŚMIESZEK-WILCZEWSKA J.<sup>1</sup>, SKROK-WOLSKI G.<sup>3</sup>, NIEDZIELSKA I.<sup>4</sup>

1- Department of Oral Surgery, Chair of Cranio-Maxillo-Facial Surgery, School of Medicine with the Division of Dentistry in Zabrze, Medical University of Silesia in Katowice, Plac Akademicki 17, 41-902 Bytom, Poland  
 2- Department of Prosthetic Dentistry, Chair of Prosthetics and Dental Materials, School of Medicine with the Division of Dentistry in Zabrze, Medical University of Silesia in Katowice, Plac Akademicki 17, 41-902 Bytom, Poland  
 3 -Laboratory of Dental Prosthetics „Skrok-Wolski” os. Władysława Sikorskiego 16, 44-240 Żory  
 4- Department of Cranio-Maxillo-Facial Surgery, Chair of Cranio-Maxillo-Facial and Oral Surgery, School of Medicine with the Division of Dentistry in Zabrze, Medical University of Silesia in Katowice, Plac Akademicki 17, 41-902 Bytom, Poland

**Introduction:** The implant-prosthetic treatment of the severely atrophied maxilla requires an accurate radiological CBCT evaluation. In order to obtain success of implant therapy in the preliminary stages it is essential to assess the amount of available bone.

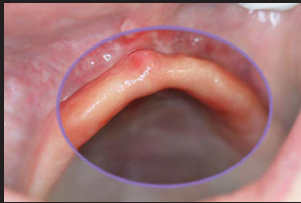

Fig. 1a

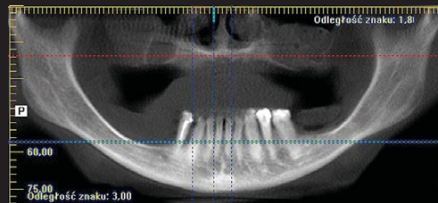


Fig. 1b

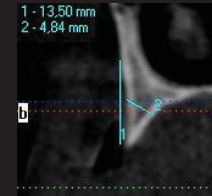


Fig. 1c

**The aim of the work:** The purpose of this presentation is to show the result of implant-prosthetic treatment obtained with procedure for reconstruction that involved the use of autogenous bone grafts, short dental implants and the evaluation of masticatory function in this individual conditions analyzed by static and dynamic occlusion in new restoration.

**Methods and materials:** The surgical procedure was performed using piezosurgery technique on an outpatient basis utilizing intravenous sedation and local anesthesia. In this particular case in order to manage the site of vertical and horizontal atrophy (Fig. 1a, Fig. 1b, Fig. 1c) it was decided to use the bone blocks grafts (Fig. 2a, Fig. 2b, Fig. 2c) harvested from the mandibular anterior symphysis. Once the revascularization and integration was obtained the implant therapy was performed. Implant receptor sites were evaluated by CBCT (Fig. 3a, Fig. 3b). Implant bed preparation was performed by using Piezosurgery device and conventional bone surgical drill (Fig. 3c). 4 short Camlog (Conelog) implants were inserted in the augmented maxillary ridge. The primary stability of the implants was confirmed by ISQ (Ostell) examination and the value was about 70-74 ISQ (Fig. 3d). Quality of augmented bone was assessed by histomorphometric and fractal analysis (Fig. 3e, Fig. 3f).

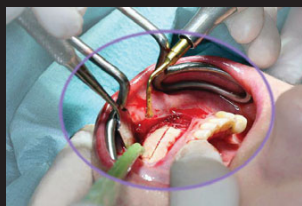


Fig. 2a

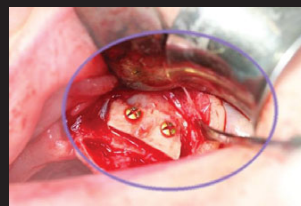


Fig. 2b

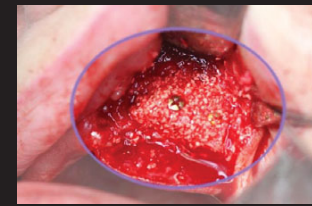

Fig. 2c

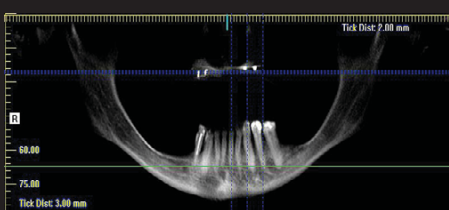


Fig. 3a

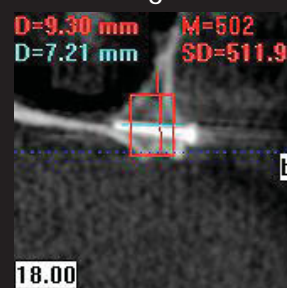

Fig. 3b

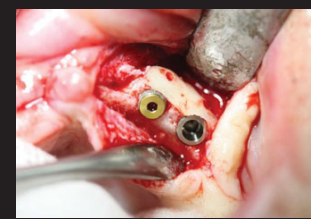


Fig. 3c

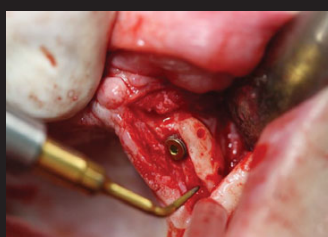


Fig. 3d

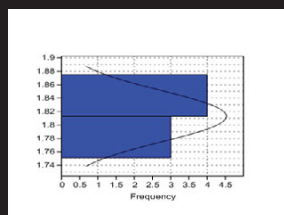


Fig. 3e

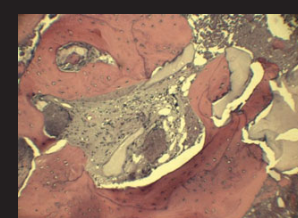


Fig. 3f

The next stage was to create removable prosthetic reconstruction supported by four short dental implants with the use of locator prosthetic solution (Fig. 4a, Fig. 4b). In the course of the prosthetic treatment the patient survey was conducted using electromyographic BioEMG III (Bioresearch, Milwaukee, USA) for analysing the temporal muscle and masseter tension (Fig.4c), axiography analysis (Fig.4d), vibroacoustic analysis (Fig. 4e) as well as static and dynamic evaluation of occlusion in order to monitor potential changes in new restoration.

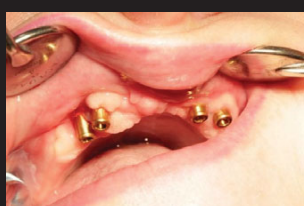

Fig. 4a

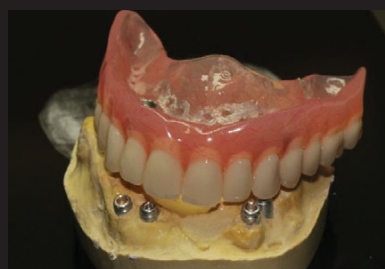

Fig. 4b

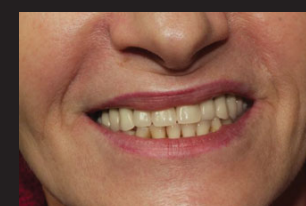

Fig. 5

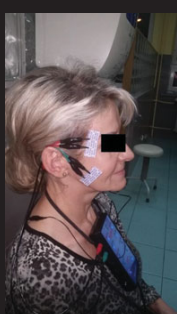

Fig. 4c

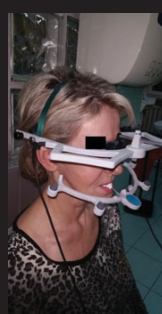

Fig.4d



Fig. 4e

**Conclusions:** The coordination of prosthetic and surgical treatment guarantees optimal surgical and prosthetic effect of the therapy, including both anatomical structures and prosthetic functional requirements. The implant-prosthetic rehabilitation is a current practice in clinic dentistry and it's characterized by safe and predictable result in long term (Fig.5).