



# Rehabilitation protocol of an edentulous patient with atrophic ridges after osteoradionecrosis



Luis Carvalho Alves, Filipe Moreira, Rita Reis, Nuno Sampaio, Pedro Nicolau

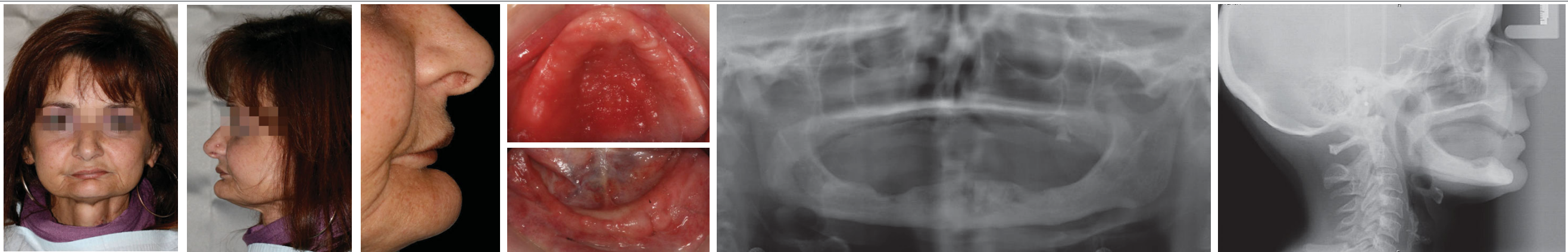
Area of Dentistry – Faculty of Medicine, University of Coimbra

## Introduction

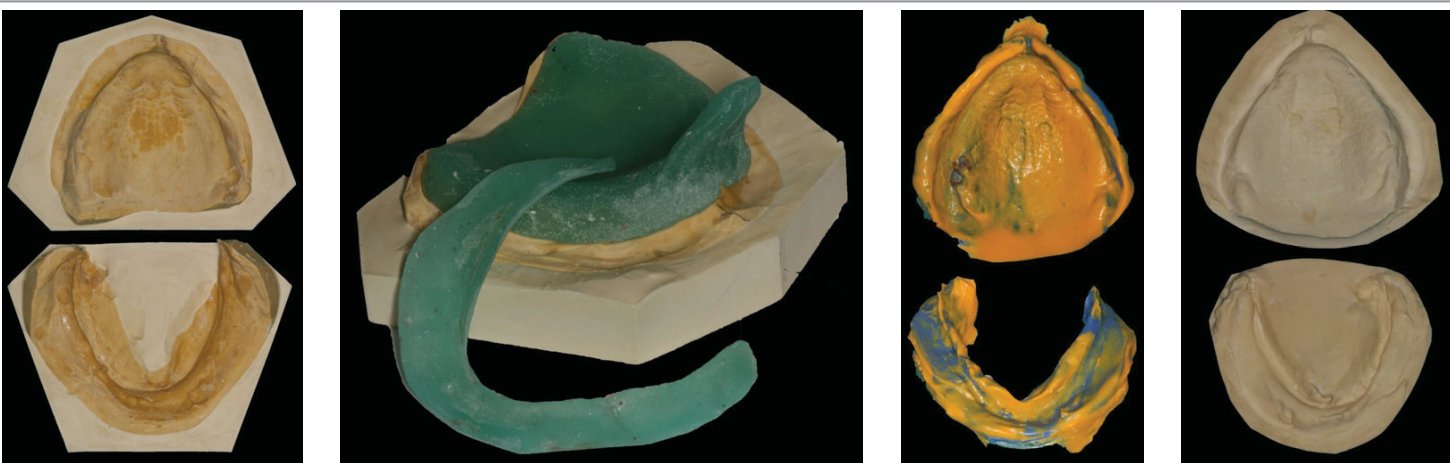
Patients undergoing radiation therapy for treatment cancer of the oral cavity are at risk of developing bone post-extraction radionecrosis. When this occurs in a patient with atrophy of the alveolar ridge, the probability of the existence of serious defects is high with obvious anatomical, functional and aesthetic commitment. The use of implants in these cases can be addressed but it is always a risk, as such, in situations of a total edentulous patient a protocol available will be the rehabilitation with conventional total mucous-supported prosthesis.

## Clinical case description

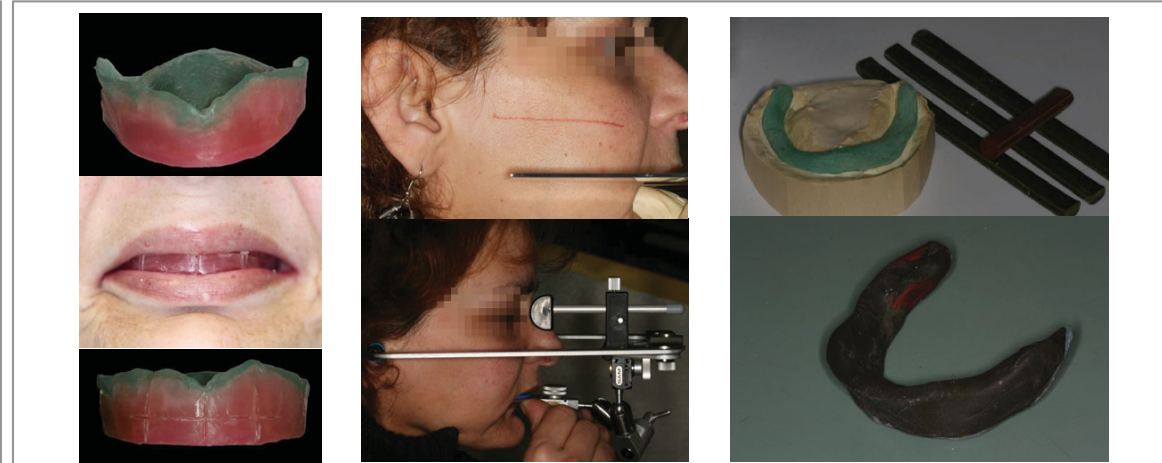Female patient, 40 years-old, total edentulous with residual atrophic ridges and bearer of complete upper mucus-supported denture. Previous history of carcinoma of the oral cavity with consequent partial right glossectomy. Subsequently suffered an episode of post-extraction osteoradionecrosis in the 4th quadrant which resulted in significant loss of mandibular structure. Rehabilitation according to a conventional complete mucous-supported prosthesis protocol.



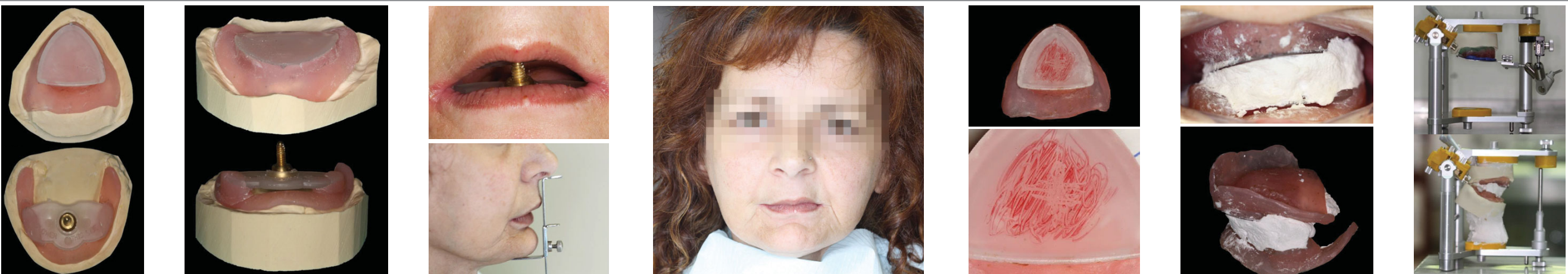
1. Initial photographs: extra e intra oral. Orthopantomography and teleradiography



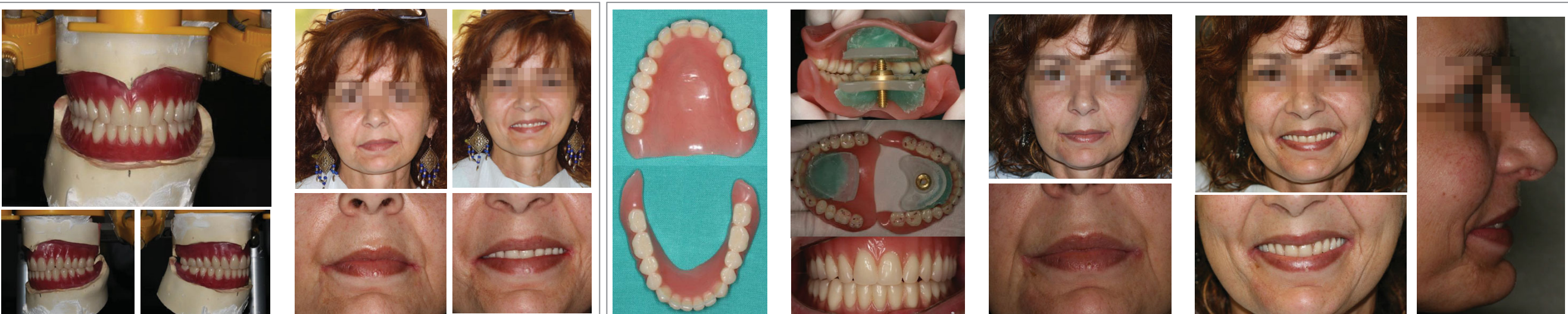2. Study casts; individual trays; master impression and master casts



3. Functional and aesthetic analysis, facial arch transference and neutral zone determination



4. Intermaxillary dynamic record and mounted master casts in the articulator



5. Teeth trial

6. Insertion and occlusal balance

## Conclusion

Atrophic ridges constitute a challenge in oral rehabilitation. In cases of bone radionecrosis in addition to the atrophy of the ridge, this presents considerable defects that affect the stability/retention of the rehab. However, through a careful clinical protocol, namely: determination of the neutral zone and realization of dynamic intermaxillary record based on gothic arch tracing, health, function and aesthetics can be restored. Despite anatomical constraints has been possible to improve patient quality of life and wellness without the use of implants.

### Bibliography

Schoen PJ et al. The use of implant retained mandibular prostheses in the oral rehabilitation of head and neck cancer patients. A review and rationale for treatment planning. Oral Oncology (2004)40862-871 ; Otto S et al. Bisphosphonate-related osteonecrosis of the jaws. Characteristics, risk factors, clinical features, localization and impact on oncological treatment. Journal of Cranio-Maxillo-Facial Surgery 40 (2012) 303-309 ; Pitak-Arnop P et al. Management of osteoradionecrosis of the jaws : Ananalysis of evidence. EJSO 34 (2008) 1123-1134 ; Lyons A et al. Osteoradionecrosis of the jaws: current understanding of its pathophysiology and treatment.

British Journal of Oral and Maxillofacial Surgery 46 (2008) 653-660 ; Lozza L et al. Analysis of risk factors for mandibular bone radionecrosis after exclusive low dose-rate brachytherapy for oral cancer. Radiotherapy and Oncology 44 (1997) 143-147 ; Koga DH et al. Dental extractions related to head and neck radiotherapy: ten-year experience of a single institution. Oral Surg Oral Med Oral Pathol Oral Radiol Endod 2008;105:e1-e6