

Stavros Kiliaridis, Margarita Sidira, Yvoni Kirmanidou, Konstantinos Michalakis

# Treatment options for congenitally missing lateral incisors



**Stavros Kiliaridis, DMD, PhD**

Stavros Kiliaridis, Professor and Chair, Department of Orthodontics, University of Geneva, Faculty of Medicine-Section of Dental Medicine, Rue Barthélemy-Menn 19, CH-1205 Geneva, Switzerland

**Margarita Sidira, DDS**

Graduate Prosthodontics resident, Aristotle University School of Dentistry, Faculty of Health Sciences, Thessaloniki, Greece

**Yvoni Kirmanidou, DDS**

Graduate Prosthodontics resident, Aristotle University School of Dentistry, Faculty of Health Sciences, Thessaloniki, Greece

**Konstantinos Michalakis, DDS, MSc, PhD**

Associate Professor and Clinical Director of Graduate Prosthodontics, Department of Prosthodontics, Aristotle University School of Dentistry, Faculty of Health Sciences, Thessaloniki, Greece; Adjunct Associate Professor, Division of Graduate Prosthodontics, Department of Prosthodontics and Operative Dentistry, Tufts University School of Dental Medicine, Boston, Massachusetts, USA

**Correspondence to:**

Stavros Kiliaridis, DMD, PhD  
Department of Orthodontics, Université de Genève, Faculté de Médecine, Rue Barthélemy-Menn 19, CH-1205 Geneva, Switzerland.  
Email: stavros.kiliaridis@unige.ch

**Key words** *agenesis of maxillary lateral incisors, orthodontic space closure, prosthetic rehabilitation, systematic review*

**Aim:** The aim of this systematic review was to identify studies that examined maxillary lateral incisor agenesis treatment, by either orthodontic space closure by canine mesial repositioning and reshaping, or by a prosthodontic intervention, in order to compare the biological, functional and aesthetic outcomes of these two approaches.

**Materials and methods:** An electronic MEDLINE search was conducted by two independent reviewers in order to isolate English language articles, published in scientific journals between January 1975 and March 2015, reporting on treatment of agenesis of maxillary lateral incisors, accomplished either by canine orthodontic repositioning or prosthodontic intervention. The search terms were categorised into the four groups comprising the PICO (problem, intervention, comparison and outcome) question. Supplementary manual searches of published reviews and other full-text articles were also performed.

**Results:** The initial database search produced 8,453 titles. After careful examination and discussion, 12 articles were selected for inclusion, where 5 of them compared the two therapeutic options directly. No randomised controlled trials were identified.

**Conclusions:** Definitive conclusions cannot be drawn, since randomised controlled trials and more prospective and retrospective studies directly comparing the two therapeutic options are required. According to this systematic review, both therapeutic options are effective. However, it seems that the orthodontic space closure, whenever this is possible, is advantageous over the prosthodontic rehabilitation.

## Introduction

Congenitally missing tooth or tooth agenesis describes one of the most frequent developmental anomalies in human dentition<sup>1-4</sup>. Maxillary lateral incisor agenesis is, according to some researchers, the second most common agenesis, after that of the third molar<sup>5-10</sup>. However, there is some published evidence showing that the second premolars have a higher incidence of agenesis than that of lateral incisors<sup>11-13</sup>. A clinical study by Muller et al has concluded that, while premolars are the most frequently missing teeth when more than two teeth

are absent, lateral incisors are the ones which are most frequently missing, when less than two teeth are absent, with a range between 1% and 4%<sup>8,14</sup>. Nevertheless, it has been demonstrated that there are large variations in the prevalence of dental agenesis amongst different races<sup>15-27</sup>.

The genetics of tooth agenesis has recently been the focus of research<sup>3</sup>. A recent article has demonstrated the involvement of five genes, namely PAX9, EDA, SPRY2, SPRY4 and WNT10A, as risk factors for maxillary lateral incisor agenesis. Furthermore, the same research group has proven that there are three synergistic interactions between maxillary lateral

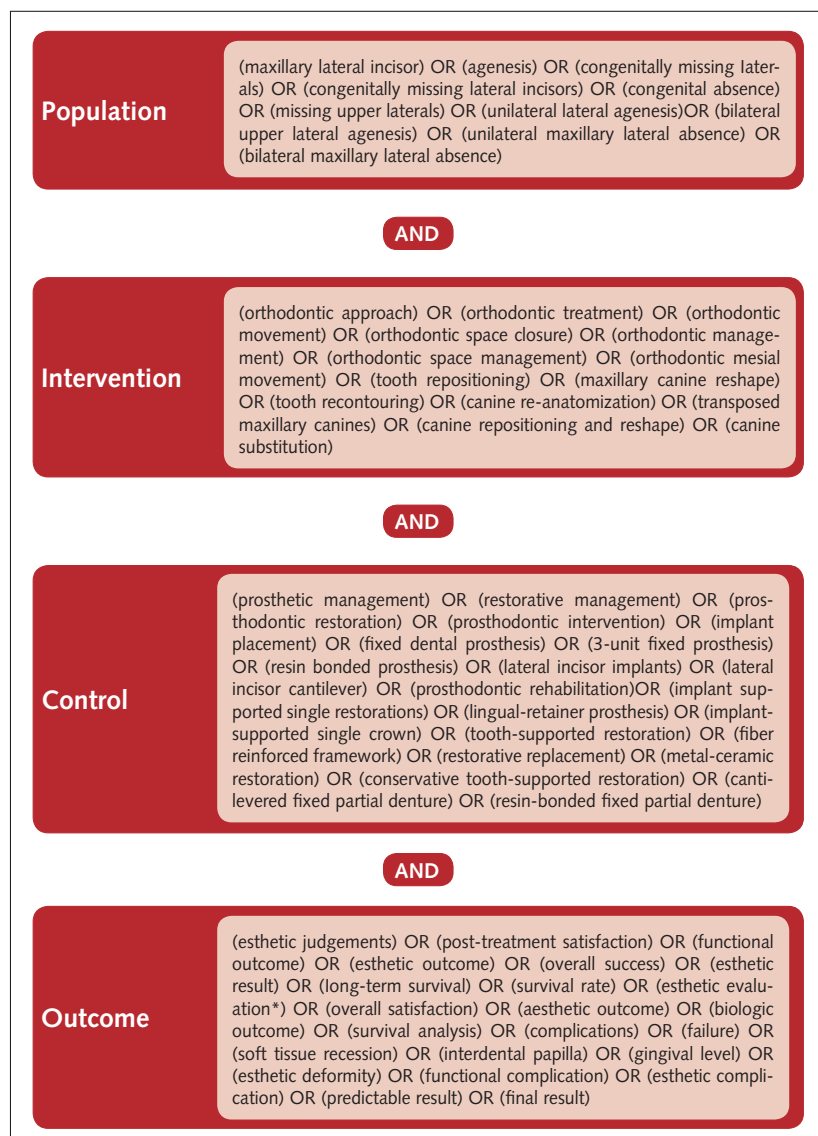
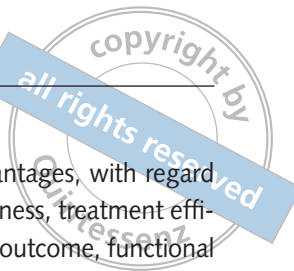

Fig 1 Focused PICO question.

incisor agenesis liability and MSX1-TGFA, AXIN2-TGFA and SPRY2-SPRY4 gene pairs<sup>28</sup>.

Besides the basic research taking place in this field, the agenesis of lateral incisors has also drawn the attention of both patients and clinicians due to their location in the aesthetic zone of the dental arch. The treatment approaches for this clinical situation can consist of: I) orthodontic space closure by mesial repositioning of the canine, followed by reshaping in order to resemble a lateral incisor; II) endosseous implant placement, with or without orthodontic movement, for space requirements or site development; III) two- (cantilever) or 3-unit resin-bonded prostheses; IV) full coverage 2- (cantilever) or 3-unit fixed dental prostheses. Each one of these therapeutic approaches

present advantages and disadvantages, with regard to treatment time, cost, invasiveness, treatment efficacy, biologic outcome, esthetic outcome, functional outcome and patient satisfaction.

All of the above-mentioned treatment approaches have, in the past, been employed to restore the missing maxillary lateral incisor. However, these modalities have not been thoroughly evaluated, making the decision of which approach to adopt difficult, and often the procedure is a personal preference. Nevertheless, the treatment is better to be based on solid scientific criteria, if these exist. The purpose of this systematic review, therefore, was to identify studies that examined maxillary lateral incisor agenesis treatment by either orthodontic space closure, by canine mesial repositioning and reshaping, or by a prosthodontic intervention, in order to compare all the available published outcomes of these approaches.

## ■ Materials and methods

The focused PICO (population, intervention, comparison and outcome) question of the present systematic review was whether the treatment time, invasiveness, treatment efficacy, biological outcome, aesthetic outcome, functional outcome and patient satisfaction of orthodontic mesial canine repositioning are similar to those obtained by the prosthodontic intervention (implant placement, resin-bonded or conventional fixed prosthesis). It was the intention of the authors to determine whether or not the available literature offers enough scientific data on which therapeutic approach to follow or to when the orthodontic treatment is preferred over the prosthodontic one.

## ■ Search strategy and study selection

An electronic MEDLINE search was conducted by two independent reviewers in order to isolate English language articles, published in dental journals between January 1975 and March 2015, and to report on treatment of agenesis of maxillary lateral incisors, accomplished either by canine orthodontic repositioning or prosthodontic intervention. The search terms were categorised into the four groups comprising the PICO question, after the following

limits were activated: human; clinical trial; meta-analysis; randomised controlled trial; review; case reports; clinical trial phases I, II, III and IV; comparative study; controlled clinical study; and multicenter study. The search strategy consisted of free-text words, as illustrated in Figure 1.

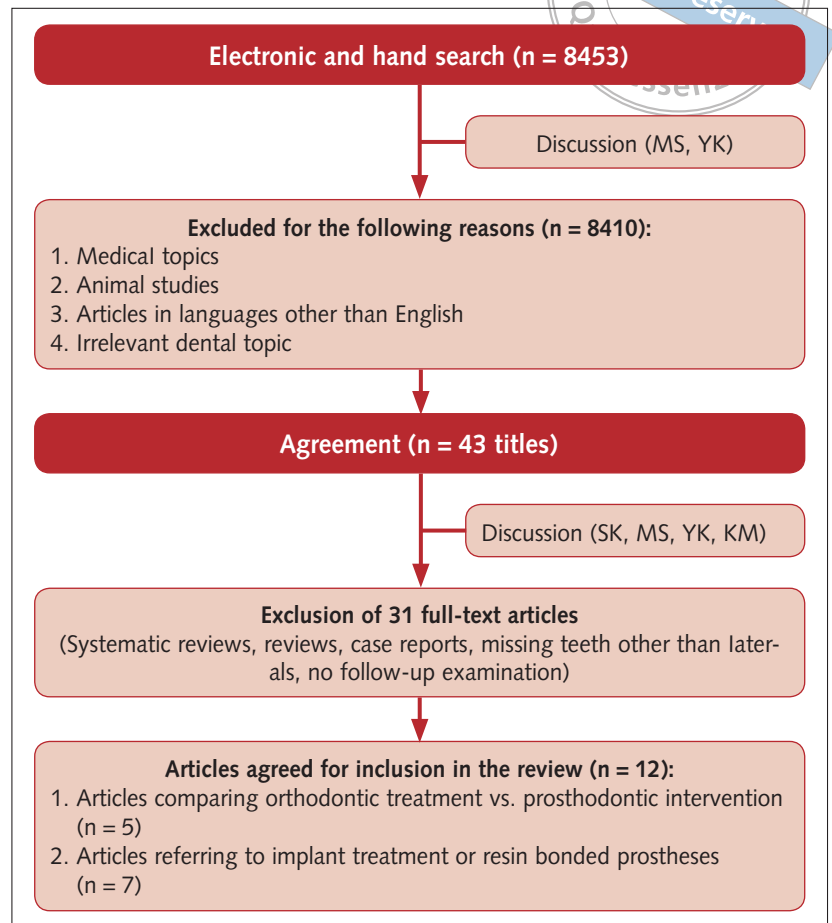
The search was supplemented with manual searches of published reviews and other full-text articles, which were identified from the electronic-search. In addition, a hand-search was conducted by the reviewers in the following journals published between January 2010 and March 2015: *Angle Orthodontist*, *American Journal of Orthodontics and Dentofacial Orthopedics*, *Clinical Implant Dentistry and Related Research*, *Clinical Oral Implants Research*, *European Journal of Oral Implantology*, *European Journal of Orthodontics*, *Journal of Oral and Maxillofacial Implants*, *Journal of Prosthetic Dentistry*, *Journal of Prosthodontics*, *International Journal of Prosthodontics*.

Prospective, retrospective, cross-sectional and case series studies retrieved through the electronic and hand-searches were the basis of this systematic review, as no randomised controlled trials could be identified. The additional criteria set for inclusion in this study were:

- report on treatment of maxillary lateral incisor agenesis of one or both sides;
- inclusion of detailed information on treatment procedures;
- inclusion of a clinical evaluation of the treatment outcome;
- report of the presence or absence of biological, functional and/or aesthetic complications at follow-up appointments.

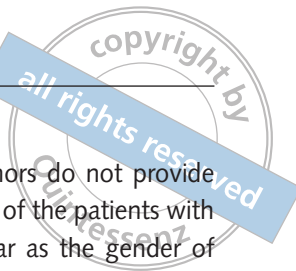All studies that did not satisfy the above-set criteria, including *in vitro* studies, *in silico* studies, animal studies, reviews, systematic reviews, as well as clinical studies reporting on tooth agenesis in other locations, were excluded.

The titles and abstracts retrieved from the advanced search were initially evaluated by two reviewers (MS and YK) for possible inclusion in this systematic review, based on the aforementioned set criteria. A discussion with all four authors resolved any disagreement during the search. After this procedure, abstracts of all approved titles were down-



**Fig 2** Flow chart of article selection for inclusion in the systematic review.

loaded and evaluated individually. Full texts were obtained, if the abstracts met the inclusion criteria. Furthermore, if inadequate information was included in either the title or the abstract, the full-text was retrieved in order not to exclude any articles relevant to the topic of this systematic review. Moreover, on many occasions the authors of the articles were contacted for additional information, when this was necessary and this complementary information was taken into consideration<sup>63,64,66,68-70</sup>. Following the collection of all full-text articles, the inclusion/exclusion criteria were used to focus on those that would be included in this systematic review. The two reviewers (MS and YK), who conducted electronic-searches (PICO question) and hand-searches independently, generated 40 and 41 studies, respectively. Of the above, 38 studies (88.37%) were overlapping with each other. As a result, a total of 43 studies were included in the discussion for the final study selection. All four reviewers approved the selected articles (Fig 2).



## ■ Extraction of data

Information regarding the following parameters were extracted from each article: study design; setting of study; patient number; gender; age; treatment option; tooth agenesis; orthodontic space opening; time of evaluation; periodontal soft tissue assessment; gingival biotype; temporomandibular disorders; occlusal assessment; and aesthetic assessment. Additional parameters extracted from the articles on implants vs resin-bonded prostheses, included the following categories: implant brand; loading (months); prostheses; follow-up time; survival rate; success rate; complications; and hard tissue assessment.

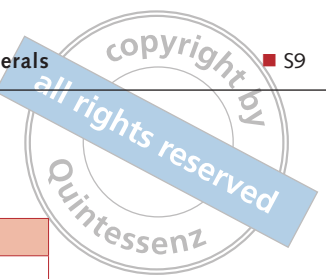
## ■ Results

The two reviewers (MS and YK), who conducted the electronic-search (PICO question) and hand-search independently, concluded in 40 and 41 studies, respectively. Of the above, 38 studies (88.37%) were overlapping with each other. As a result, a total of 43 studies were included in the discussion for the final study selection, from an initial yield of 8,453 studies. All four reviewers approved the selected articles. A second discussion amongst the reviewers took place for evaluation of these articles (Fig 2). Of the 43 full-text articles obtained and studied, 31 were excluded and were not analysed further (Table 1)<sup>4,29-58</sup>. Five studies comparing orthodontic treatment and prosthodontic intervention<sup>59-63</sup> (Table 2) and seven studies referring to implant treatment or resin-bonded prostheses<sup>64-70</sup> (Table 3) were included in the review.

Four retrospective clinical studies<sup>59,60,62,63</sup> and one cross-sectional study<sup>61</sup> on the direct comparison of orthodontic space closure and prosthodontic intervention (direct comparison group) were included in this review (Table 2). No randomised controlled studies comparing the two different therapeutic options were available in the literature. Three of the included studies were conducted in a university<sup>59,60,62</sup>, one in a private dental office<sup>63</sup>, while no information was given about one study<sup>61</sup>. One hundred and thirty-seven patients were included in the direct comparison group of studies<sup>59-63</sup>, aged between 14 and 54, with a mean age of 23.94

years. In one study<sup>61</sup>, the authors do not provide information concerning the age of the patients with maxillary lateral agenesis. As far as the gender of the patients is concerned, four studies reported on this subject. Specifically, there were 28 males (27%) and 76 females (73%). Furthermore, the agenesis appears to be bilateral in 94 cases (68.61%) and unilateral in 43 cases (31.38%). Regarding the gingival biotype, it was reported to be thin for 25 cases (54.35%), thick for 21 cases (45.65%), while no information was provided for the majority of the patients. Treatment approach included orthodontic space closure and canine recontouring for 142 sites (61.47%) and prosthodontic rehabilitation in 89 sites (38.57%). The latter 34 sites (14.71%) received by implant placement and 55 sites (23.86%) received a conventional prosthodontic approach (fixed or removable partial denture or resin-bonded prostheses). The time of evaluation ranged from 0.42 to 25.50 years. The prosthodontic rehabilitation took place after orthodontic space opening and/or maintenance in 85 sites (95.50%), whereas for four sites (4.50%), no information was provided concerning whether orthodontic space opening pretreatment took place or not.

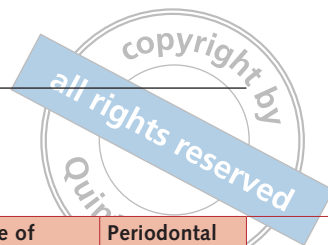
Furthermore, one prospective clinical study<sup>70</sup>, five retrospective clinical studies<sup>64-66,68,69</sup> and one case series<sup>67</sup>, examining two different prosthodontic approaches, were also identified and included in this review (Table 3). The therapeutic options in the above studies include implant and resin-bonded prostheses. Unfortunately, no randomised controlled studies directly comparing different prosthodontic approaches, were available in the literature. Five of the studies<sup>64-66,68,70</sup> took place in a university, one<sup>68</sup> in a private dental office, while no information was given for one study<sup>67</sup>. One hundred and forty-nine patients were treated with one of the above prosthodontic interventions. The age of these patients ranged from 13 to 45 years. It should be mentioned however that in two studies<sup>68,69</sup> information concerning the age of the sample is not reported or cannot be extracted from the given data. As far as the gender of the patients is concerned, one study<sup>68</sup> did not report on the patient's sex, while another one<sup>69</sup> did not give information regarding the gender of the patients with a congenitally missing lateral incisor. In the remaining five studies, 84

**Table 1** Studies excluded from the systematic review.

First author	Year	Study	Reason for exclusion
Andrade et al <sup>45</sup>	2013	Systematic review	Systematic review
Balshi <sup>40</sup>	1993	Case report	Case report
Benzos <sup>37</sup>	1996	Case report	Case report
Bidra <sup>44</sup>	2012	Case report	Case report/bilateral cleft palate
Cakan et al <sup>29</sup>	2009	Case report	Case report
De Marchi et al <sup>57</sup>	2012	Cross-sectional	Same cohort with De Marchi et al <sup>59</sup>
Fisher and Jones <sup>41</sup>	1990	Case report	Case report
Duarte et al <sup>30</sup>	2010	Case report	Case report
Jackson and Slavin <sup>47</sup>	2012	Case report	Case report
Jackson and Slavin <sup>46</sup>	2013	Case report	Case report
Kinzer and Kokich <sup>33</sup>	2005	Review	Review
Kinzer and Kokich <sup>34</sup>	2005	Review	Review
Kokich and Kinzer <sup>35</sup>	2005	Review	Review
Krassnig and Fickl <sup>4</sup>	2011	Review	Review
Mummidi et al <sup>55</sup>	2013	Case report	Case report
Nissan et al <sup>54</sup>	2011	Prospective	Data extraction could not be performed
Oliveira et al <sup>53</sup>	2013	Case report	Case report
Oosterkamp et al <sup>42</sup>	2010	Retrospective	Bilateral cleft lip and palate
Paduano et al <sup>52</sup>	2014	Case report	Case report
Park et al <sup>51</sup>	2010	Case report	Case report
Piero et al <sup>32</sup>	2007	Case report	Case report
Pini et al <sup>58</sup>	2013	Cross-sectional	Same cohort with De Marchi et al <sup>60</sup>
Robertsson et al <sup>56</sup>	2010	Cross-sectional	Data extraction could not be performed
Savarrio and McIntyre <sup>36</sup>	2005	Review	Review
Slutsky and Greenberg <sup>43</sup>	2011	Case report	Case report
Small <sup>38</sup>	1996	Case report	Case report
Strong <sup>31</sup>	2008	Case report	Case report
Trushkowsky RD <sup>39</sup>	1995	Case report	Case report
Tuna et al <sup>50</sup>	2009	Case report	Case report
Uribe et al <sup>49</sup>	2013	Retrospective	Data extraction could not be performed
Zachrisson et al <sup>48</sup>	2011	Review	Review

patients (61.3%) were women and 53 (38.7%) were men. Moreover, 54 patients (36.24%) had bilateral agenesis, while 95 patients (63.75%) presented with unilateral agenesis. Regarding the treatment options, 116 patients (57.14%) were treated with a single implant crown, while 87 patients (42.85%) received resin-bonded prostheses. One hundred and eighty-three sites (96.8%) were treated by opening lateral incisor spaces prior to the prosthodontic rehabilitation, 6 sites (3.1%) did not receive orthodontic treatment prior to prosthetic intervention, whereas no information was given in two studies. As far as the implant dimensions are concerned, the

diameter ranged from 3.3 mm to 4.8 mm, while the length ranged from 10.0 mm to 16.0 mm. Twenty-eight implants (45.1%) were immediately loaded, 34 (54.9%) were loaded 4 months after the surgical procedure, whereas four studies did not report on the time of loading. In 52 cases (59%), titanium abutments were used; in 36 cases (41%) zirconium abutments; while in two studies no information was given regarding the type of abutment. Regarding the type of the implant restoration, 55 crowns were metal-ceramic (50.9%), 53 crowns (49.1%) were all-ceramic, while no information was given in one study. Concerning the construction of the


**Table 2** Orthodontic space closure versus space opening/ retention and prosthodontics.

Study	Study design	Setting	Patient no	Gender	Age	Treatment Option (n: sites)	Tooth agenesis (n: patients)	Orthodontic space opening	Time of evaluative (years)	Periodontal Biotype
DeMarchi et al (2012) and DeMarchi et al (2014)	Cross	Univ	46	9M, 37F	14-45, Mean: 25	OSC (n = 43)	9 Uni and 17 Bi		3.90 ± 3.48	19 thin and 7 thick
						Impl (n = 30)	10 Uni and 10 Bi	YES	3.54 ± 2.39	6 thin and 14 thick
Nordquist and McNeil (1975)	Cross	NR	33	NR	NR	OSC (n = 39)	8 Uni and 25 Bi		2.3-25.5	NR
						FDP (n = 13) RPD (n = 6) (n = 19)		YES		
Robertsson and Mohlin (2000)	Retro	Univ	50	14M, 36F	19.4-54.9 Mean 25.8	OSC (n = 53)	7 Uni and 23 Bi		7.1 ± 3.3	NR
						FPD, RBP (n = 36)	4 Uni and 16 Bi	YES	7.2 ± 3.8	
Jamilian et al (2015)	Retro	PO	8	5M,3F	19.4-22.8 Mean 21.02	OSC (n = 7)	5 Uni and 3 Bi		5.6 ± 0.4	NR
						Impl (n = 4)				

AL: abfraction lesions; Av: average; Bi: bilateral; BI: bleeding index; Cross: cross-sectional study; CS: case series; DCNBE: data cannot be extracted; EEI: Eastman Esthetic Index; F: females; FPD: fixed partial denture; Gd: Good; Impl: Implant; M: males; NA: not applicable; NR: not reported; NS: not significant; Nss: not statistically significant; OT: orthodontic treatment; PO: Private practice; Pr: poor; OSC: orthodontic space closure; RPD: removable partial denture; RBP: resin-bonded prostheses; PI: plaque index; PD: probing depth; Ppl: papilla index; Retro: retrospective; RI: retention index; Ss: statistically significant; Univ: university; Uni: unilateral; VAS: Visual Analogue Scale.

resin-bonded prosthesis, 73 restorations (83,90%) were made of nickel-chromium alloy retainers, sandblasted with 50 to 250 µm alumina and luted with adhesive resin, while 14 resin-bonded prostheses (16.10%) were all-ceramic. Reported follow-up periods ranged from 1.30 to 8.33 years in five studies<sup>64-67,70</sup>; two studies did not specify the follow-up period for patients with lateral agenesis, from the whole sample of patients<sup>68,69</sup>. The implant-crown survival rate ranged from 97.06% to 100% for 108

sites (93.10%), whereas eight sites (6.89%) demonstrated a 87.5% survival rate. As for the implant-crown success rate, it ranged from 94.12% to 100% for 108 cases (93.10%); one study<sup>67</sup> did not report on implant-crown success rate. Furthermore, 14 resin-bonded prostheses (16.09%) have reported a 100% survival rate, while one study<sup>65</sup> did not give any information regarding the survival rate. Finally, none of the studies<sup>65,67-69</sup> reported on the success rate of this type of prosthesis.




Perio soft tissue assessment	TMDs	Occlusal assessment	Aesthetic assessment
PI: Nss, [OSC:61 ± 13% Impl:52±11%] P > 0.5 BI: Nss [OSC:11 ± 18% Impl:7 ± 6%], P > 0.5 PD: Nss [> 3mm OSC:1% Impl:1.7%] Ppl: Ss mesially OSC >Impl [OSC: 2.98 Impl: 2.72] P ≤ 0.5 Nss distally [OSC: 2,98 Impl: 2,97] P > 0.5	Nss difference based on Research Diagnostic Criteria (RDC/TMD) and Helkimo Dysfunction Index, P > 0.5	NR	<b>Patient's satisfaction (VAS):</b> Nss difference, but the OSC were more satisfied P > 0.002 <b>Smile attractiveness (VAS):</b> Nss differences between laypersons and dentists, P = 0.64
PI: Nss FPD and OSC, P > 0.01 GI/BI: Ss FPD > OSC, P ≤ 0.01 PD:Ss in FPD > OSC, P ≤ 0.01	NR	OSC: 100% Group function FDP/RPD: 89% Group Function, 11% Canine rise NS difference in the presence of unilateral contacts in CR and non-working side interferences	NR
PI: Ss ,PR>OSC [OSC: 1.36 PR: 2.81] P ≤ 0.001 BI: Ss ,PR>OSC [OSC: 1.51 PR : 2.61] , P ≤ 0 .001 PD: Nss, P > 0.001	Nss difference based on Helkimo Dysfunction Index, P > 0.001	Ss difference in the presence of canine rise on laterotrusion in the PFM/RBP group, P ≤ 0.0001 Nss difference in the presence of unilateral contacts in CR and non-working side interferences.	Patient's satisfaction General dental appearance (EEI): Ss [OSC: 93% very or mildly satisfied PR:65% very or mildly satisfied] P ≤ 0.05 Tooth shape: Nss Tooth colour: PFM/RBP ss more satisfied, P ≤ 0.001 Space condition: Nss Symmetry of the maxillary anterior segment: Nss Examiner/panel evaluation: NR
PI:Nss [OSC:3.0 ± 1.1 Impl:3.7 ± 1.0] P > 0.632 PD: SS Impl > OSC [ PD > 3mm OSC:1 tooth Impl:3 implants] P < 0.001	Nss difference based on anamnestic questionnaire, P > 0,605	Presence of infraocclusion: [OSC:0, Impl:4]	DCNBE Patient's satisfaction (VAS): Nss difference [Impl: 8.7 ± 1.3 OSC: 8.8 ± 1.2] P > 0.857 (Similar well accepted aesthetic results) Examiner/panel evaluation: NR

## ■ Side effects and complications

In the first group of studies<sup>59-63</sup>, in which a direct comparison of the two treatment options took place, no occlusal assessment and side effects related to temporomandibular joint dysfunction (TMDs) were reported. More specifically, there were no statistically significant differences between the two treatment approaches in 104 patients<sup>59,62</sup>, concerning the temporomandibular joint dysfunction status, based on the Helkimo Dysfunction Index. No information was reported regarding the status of the TMD for the remaining 33 patients<sup>61,63</sup>. On the subject of the presence of unilateral contacts in centric relation and non-working side (mediotrusive) interferences, there

were no statistically significant differences in 83 of the patients between the group that received orthodontic space closure and the group that received prosthodontic rehabilitation, while no information was available for the remaining 54 patients. In addition, the presence of infraocclusion was reported for 4 implants in one study<sup>63</sup>.

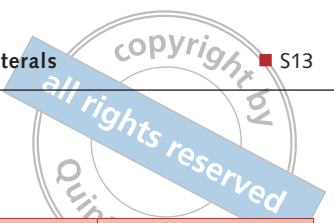
In the second group of studies<sup>64-70</sup>, which deals with the two different prosthodontic approaches, the reported complications were different for each intervention. With regard to implant restorations, one technical complication was reported which consisted of porcelain chipping. Two biological complications were reported and included one implant loss<sup>67</sup> and a 0.2 mm neck exposure in one implant<sup>70</sup>.

**Table 3** Orthodontic space closure versus space opening/ retention and prosthodontics.

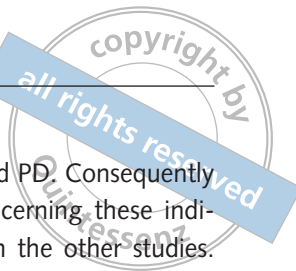
Study	Study type	Setting	Patient No	Age (years)	Gender	Agenesis	Orthodontic Space Opening	Treatment option (n: sites)	Implant	Loading (months)
Branzen et al (2014)	Retro	Univ	36	Range: 14,3-26,7	17M 19F	18 Uni and 18Bi	YES	Impl (n = 54)	Branemark system MKIII, Nobel Biocare, Dimensions: 3.3 mm x 15.0 mm (n = 45) 3.75 mm x 13.0 mm (n =9)	NR
Garnett et al (2006)	Retro	Uni	45	Range: 13-44, Mean: 17	14M 31 F	17 Uni and 28 Bi	YES	RBP (n =73): Canine Cantilevered (n = 38); Central Incisor Cantilevered (n = 24); Conventional (n = 9); Canine+Premolar Cantilevered (n = 2)	NA	NA
Man-gano et al (2014)	Retro	Uni	20	Range: 19.75-24.25	9M 11F	20 Uni	YES	Impl (n = 20)	Cone Morse Taper, Leone Implant System Diameter: 3.3 mm, 4.1 mm and 4.8 mm	Immediate
Penar-rocha et al (2008)	C.S	NR	6	Range: 17-32 Mean:22	2M 4F	4 Uni and 2 Bi	YES only in two cases	Impl (n=8)	Defcon (Impladent, Sentmenat, Barcelona, Spain) titanium surface acid, Avantblast surface implants; Dimensions: 3.6 mm X 13.0 mm (n = 3) 3.6 mm X 14.5 mm (n = 1) 3.6 mm X 16.0 mm (n = 2) 4.2 mm X 14.5 mm (n = 1) 4.2 mm X 16.0 mm (n = 1)	Immediate
Sailer et al (2013)	Retro	PO	5(out of 28)	NR	DCNBE	3 Uni and 2 Bi	NR	RBP: single retainer cantilever (n = 7)	NA	NA
Sailer et al (2014)	Retro	Uni	7(out of 15)	DCNBE (13.1-75.1)	DCNBE (6M9F)	7 Uni	NR	RBP: single retainer cantilever (n = 7)	NA	NA
Zarone et al (2006)	Pros	Univ	30	Range: 21-45	11M 19F	26 Uni and 4 Bi	YES	Impl (n = 34)	Straumann ITI, Dimensions: 3.3 mm X 10.0 mm (n = 9) 3.3 X 12.0 mm (n = 17) 3.3 mm X 14.0 mm (n = 8)	4

AL: abfraction lesions; Av: average; Bi: bilateral; BI: bleeding index; Cross: cross-sectional study; CS: case series; DCNBE: data cannot be extracted; EEI: Eastman Esthetic Index; F: females; FPD: fixed partial denture; Gd: Good; Impl: Implant; M: males; NA: not applicable; NR: not reported; NS: not significant; Nss: not statistically significant; OT: orthodontic treatment; PO: Private practice; Pr: poor; OSC: orthodontic space closure; RPD: removable partial denture; RBP: resin-bonded prostheses; PI: plaque index; PD: probing depth; Ppl: papilla index; Retro: retrospective; RI: retention index; Ss: statistically significant; Univ: university; Uni: unilateral; VAS: Visual Analogue Scale.





Prostheses	Follow-up (years)	Survival Rate	Success Rate	Complications	Hard tissue assessment	Soft tissue assessment	Aesthetic assessment
Abutments: 44 Custom-made: 36 ZR, 8 Ti 10 Prefabricated Restoration: 53 all-ceramic, cemented, 1 metal-ceramic, cemented	5	100%	100%	Aesthetic: Porcelain fracture in one crown	Marginal Bone Level (distance from the IAJ): Mean: 1.1 ± 0.8 mm 32% ≤ 0.6mm 17% ≥ 1.8mm Bone loss: Mean: 0.6 ± 0.7 mm	Ppl: 0 (n = 2, 4%) 1 (n = 7, 13%) 2 (n = 15, 28%) 3 (n = 30, 56%)	Patients' satisfaction: 32.43% desired a crown replacement 56.75% completely satisfied CDA Evaluation: 70% excellent 30% acceptable
Nickel Chromium Retainer alumina sand-blasted (50-250 µm) Panavia cemented	8.33	NR	NR	30 Debonded at least one No significant difference between cantilever design, one vs two retainer Porcelain Fracture: in one pontic	NA	NR	NR
Metal-Ceramic restoration, cemented	3	100%	100%	-	Distance implant shoulder-Bone: Mean: 0.49 ± 0.18mm Bone loss: NR	NR	Patient's satisfaction:NR Independent calibrated examiner evaluation (PES/WES) High aesthetic outcome PES Index: Mean: 8.15 ± 1.69 WES Index: Mean 8.70 ± 0.92
Abutment: NR Restoration: cemented	1.3-2.5 Mean: 1.96	87.5%	NR	One implant failed 3 weeks after implantation	Bone level: NR Mesial bone loss: 0.23-0.63 Mean: 0.48 Distal bone loss: 0.35-0.78 Mean: 0.662	NR	Patient's satisfaction (VAS) High degree of satisfaction Examiner/panel evaluation: NR
All-ceramic restoration (IPS e.max Press/IPS Empress, Ivoclar Vivadent) Hydrofluoric acid etched (Pulpdent), Silanized (Monobond, Ivoclar Vivadent)	DCNBE (0.31-13.5) Mean: 6	100%	NR	DCNBE (chipping of the incisal edge of one pontic (unnoticed by the patient)	NA	DCNBE (no differences in biological outcomes compared to the control teeth.)	DCNBE (High aesthetic outcome)
All-ceramic restoration (IPS e.max Zir CAD, Ivoclar Vivadent and Cerion, Straumann)	DCNBE (1-7.6) Mean: 4	100%	NR	DCNBE (2 debondings)	NA	DCNBE (no differences in biological outcomes compared to the control teeth)	DCNBE (High aesthetic outcome)
Abutments: 34Ti Restoration: 34 metal-ceramic restorations, cemented(zinc-phosphate luting agent)	2-3.3	97.06%	94.12%	Aesthetic: Exposure of 0.2 mm implant neck in one implant.	Bone level: NR Marginal Bone Resorption: 1.20 ± 0.61 mm	PI: 0 (n = 27) 1 (n = 6) GI: 0 (n = 31) 1 (n = 2) BI: 0 (N = 33) Ppl: 0 (n = 0); 1 (n = 2); 2 (n = 4); 3 (n = 27); PD: Nss after 0.5, 1 and 2 years of function P > 0.05	Patient's satisfaction: NR Author's evaluation: Optimal aesthetic outcome



No complications were present for the remaining 113 implants. In the cases treated with resin-bonded prostheses, the main complication was the reported debonding, which occurred at least on one occasion for each prosthesis.

### ■ Periodontal/peri-implant assessment

In the first group of studies comparing the orthodontic space closure and prosthodontic intervention<sup>59-63</sup>, the status of the soft tissues was evaluated by five indices: plaque index (PI), bleeding index (BI), gingival index (GI), probing depth (PD) and papilla index (Ppl). As far as the PI is concerned, statistically significant differences were found in 50 patients treated by either orthodontic space closure or prosthodontic intervention. The greatest plaque accumulation was noted in patients who received prosthodontic treatment. In the remaining 87 patients no statistically significance difference was found regarding the PI. Concerning the BI/GI, there was a statistically significant difference in the presence of bleeding on probing in 83 patients, with patients treated by prosthodontic intervention exhibiting the greatest values. In 46 patients, no statistically significant difference was found in the BI, whereas one study<sup>63</sup> did not report on this issue. With regard to the PD, a statistically significant difference was found in 41 patients, with the highest index value in prosthodontic patients compared to the orthodontic ones. Conversely, in 96 patients, no statistically significance difference was found in PD between the orthodontic and prosthodontic treatments. As for the Ppl, only one study reported on this index and revealed statistically significant differences between the orthodontic and implant patients, with regard to the mesial papilla of the maxillary lateral incisors; the mesial papilla filling was higher in the interdental embrasure, in patients where the orthodontic space was closed.


The distance between the implant shoulder and marginal bone ranged from 0.49 to 1.10 mm for 74 implants, while no information was given for 40 implants. Regarding the bone loss between examinations, 94 implants exhibited bone resorption from 0.48 to 1.20 mm, whereas no information was provided for 20 implants. As for the implant soft tissue assessment, the following indices were evaluated: PI, GI, PD and Ppl. Unfortunately, only one implant

study<sup>70</sup> examined the PI, GI and PD. Consequently no information was given concerning these indices for 81 implants included in the other studies. Regarding the PI for the remaining 33 implants, 27 implants scored 0 and six scored 1. Similarly, as for the GI, 31 implants scored 0 while two scored 1. Furthermore, in the same study, PD values did not show statistically significant differences 6 months, 1 year and 2 years after function. Concerning the Ppl, only two studies reported on this index. Specifically, two implants (2.30%) scored 0, nine (10.34%) scored 1, 19 (21.85%) scored 2 and 57 (65.51%) scored 3, which represented the optimal interdental papilla fill. Lastly, in the articles examining the resin-bonded prostheses, information concerning the soft tissue evaluation cannot be extracted from the published data.

### ■ Aesthetic assessment

In all included articles<sup>59-70</sup>, the aesthetic assessment was based on either the patient's satisfaction or examiner/panel evaluation. Regarding the patient's satisfaction, in the group of studies comparing the two different therapeutic options, a statistically significant difference was found amongst 50 patients, those who received orthodontic treatment appeared to be more satisfied than those who received prosthodontic treatment. However, in another study on 46 patients, no statistically significant difference was found regarding the patient's satisfaction and the jury evaluation, either after orthodontic space closure or prosthodontic intervention. In two studies, in 41 patients, no information regarding patient satisfaction could be obtained or could be extracted from the given data<sup>61,63</sup>.

In the group of articles referring to the implant treatment<sup>64,66,67,70</sup>, only two studies reported on the patient's satisfaction. Specifically, 26 patients (62%) were highly/completely satisfied with the aesthetic outcome, while 16 (38%) were not completely satisfied. The examiner evaluation revealed aesthetic results ranging from acceptable to high for 85 patients, whereas no information was given for five patients. Information regarding the aesthetic assessment was either not reported or could not be extracted from the presented data in articles on resin-bonded prostheses<sup>65,68,69</sup>.



## ■ Discussion

The purpose of this study was to evaluate the biological, functional and aesthetic outcomes of two different therapeutic approaches in the treatment of maxillary lateral incisor agenesis. The management of patients with congenitally missing maxillary lateral incisors involves two therapeutic options: orthodontic space closure by canine mesial repositioning and reshaping or space opening and prosthodontic intervention (i.e. implant-supported restorations, resin bonded prostheses and fixed partial dentures). A systematic search of the literature was conducted to identify studies that examined maxillary lateral incisor agenesis treatment by either orthodontic or prosthodontic approach, so as to identify high-level evidence. Only 5 articles comparing the two different therapeutic options were extracted from the literature, while no randomised controlled trials could be found. Therefore, it was not possible to draw definitive conclusions about the superiority of one treatment option over the other regarding the biological, functional and aesthetic outcomes.

Our results suggest that the frequency of the congenitally missing lateral incisor in females was higher than in males at a ratio of 2:1. This finding is in agreement with the results of other authors who found that the prevalence of dental agenesis in females was 1.5 to 2.0 times higher than in males<sup>71,72,73</sup>. Concerning the type of lateral agenesis (i.e. bilateral or unilateral), the frequency of absence of one maxillary lateral incisor in the same patient, does not differ from the frequency of agenesis of both laterals in the same patient, which is in agreement with the study of Celikoglu et al<sup>74</sup>, although, other studies found that there are differences in the distribution of the agenesis type in the surveyed population<sup>72,73</sup>. Moreover, the unilateral incisor agenesis is associated with the contralateral incisor microdontia (peg-shaped teeth). The explanation of this association is that both dental anomalies (peg-shaped teeth and lateral agenesis) have the same genetic origin with different phenotypic expression<sup>75</sup>.

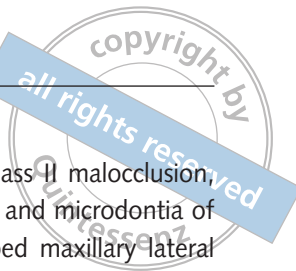Concerning the therapeutic option, the percentage of the sites in the direct comparison group which received orthodontic space closure and canine recontouring was higher than that of the sites which were treated with a prosthodontic intervention. This

finding is in agreement with the results of Fekonja et al, who found that 87.5% of the patients with tooth agenesis had been treated by orthodontic space closure<sup>76</sup>.

The majority of the patients who were treated with the prosthodontic approach had received orthodontic treatment to open or maintain the space prior to the prosthodontic rehabilitation. This is a reasonable finding, since in most cases the permanent canine inclines and moves mesially due to the absence of the laterals. In the present study, the results demonstrated that the frequency of the implant therapy did not exceed that of the conventional prosthodontic treatment. Regarding the surface characteristics of the implants and the type of the connection, information was extracted from the brand names of the implants. In the majority of the studies, implants with a rough surface were used. Clinical studies have shown that the rough surface implants presented higher survival rates than machined ones<sup>77,78</sup>. Concerning the type of connection, in the majority of the studies, implants with an external connection were used. Additionally, the implant-crown survival and success rate was high, which is in agreement with previous studies<sup>79-86</sup>.

In the direct comparison group, none of the studies revealed signs and symptoms of the temporomandibular joint disorders, associated with the orthodontic or prosthodontic intervention. Earlier studies agree with this finding and it has been shown that the occlusal condition did not correlate with signs and symptoms of mandibular dysfunction<sup>87,88</sup>. Regarding the occlusal scheme established after the treatment of lateral agenesis, only two studies mentioned that there were no significant differences in the number of centric interferences and excursive contacts between the orthodontic space closure and the prosthodontic intervention.

The space closure patients in the direct comparison group showed a healthier periodontium than the patients with prosthetic appliances. Regarding the plaque index and bleeding index, greatest plaque accumulation and bleeding on probing scores were noted in patients who received prosthodontic treatment. Similarly, the probing depth was higher in implant patients. As for the papilla index, one study reported on this index and found that the mesial papilla filling in the interdental space was higher in



the space closure patients than in the prosthodontic patients<sup>59</sup>.

In the prosthodontic treatment group, the majority of the implants exhibited a bone loss range from 0.48 to 1.20 mm. This finding is in agreement with Thilander et al who found a 0.75 mm marginal bone loss at implants in the upper lateral incisor area<sup>89</sup>. Regarding the condition of the interdental papilla, 65% of the implants showed optimal papilla filling of the interdental space. The prosthodontic intervention showed complications both in the implant and the rehabilitation of the resin-bonded prostheses. The reported complications were both biological and technical and included implant infraocclusion, thread exposure, implant loss, porcelain chipping in implant crowns and resin-bonded debondings.

Concerning the aesthetic assessment, in the direct comparison group, two studies reported on the patients' satisfaction and demonstrated that 52% of the patients showed a significant difference, with greater satisfaction amongst the space closure patients. Although a direct conclusion could not be drawn regarding the patients' preference, it seems that the patients tended to be more satisfied with the orthodontic approach, since they kept their own teeth. In the purely prosthodontic approach group, only two implant studies reported on the patients' satisfaction and found that the majority of the patients were highly satisfied with the implant aesthetic outcome.

Early diagnosis of the agenesis of the laterals at 8 to 9 years of the child's age, is often linked to the kind of suitable intervention that should be followed amongst the various treatment options. However, Hobkirk et al found that more than half of the patients referred to a clinic in the UK, for the rehabilitation of tooth agenesis, were over 12 years old<sup>90</sup>. Clinicians should be aware of clinical signs that indicate maxillary lateral incisor agenesis. Delayed eruption of the permanent tooth, more than 1 year beyond the expected time, or more than 6 months after the eruption of the contralateral tooth, should suggest that the permanent tooth is absent, with subsequent radiographic examination. Similarly, the persistence of a primary tooth may denote developmental absence of the permanent successor<sup>73,91</sup>. Other signs of a congenitally missing lateral incisor include the deviation of the maxillary dental

midline, a molar and canine Class II malocclusion, palatal displacement of canines and microdontia of contralateral incisors (peg-shaped maxillary lateral incisors)<sup>92,93,94</sup>. In addition, patients with congenitally missing lateral incisors have narrower teeth than patients without any dental anomalies<sup>95,96</sup>.

### ■ Orthodontic space closure

Several studies have reported on the advantages of the orthodontic space closure<sup>4,48,97,98</sup>. The main advantage is the longevity of the therapeutic result and the completion of the treatment in early adolescence. Moreover, the early mesial movement of the canine into the edentulous space of the lateral incisor maintains a normal gingival and alveolar architecture which is very important in patients with a high smile line<sup>48,98,99</sup>. Furthermore, the avoidance of demanding prosthodontic procedures, limits the potential risk of complications involved in the prosthodontic intervention. Also, the orthodontic space closure is less costly compared to the implant intervention, often after orthodontic space opening, and it gives the patient the impression that there is no missing tooth<sup>4,98</sup>.

Clear indications for orthodontic space closure and canine substitution, in cases of congenitally missing lateral incisors, include two types of malocclusions<sup>35,97,98,100,101</sup>. The first concerns patients exhibiting severe crowding in the mandibular anterior segment and Class I molar relationship. In these cases, orthodontic space closure by canine mesial repositioning, along with mandibular extractions, usually of the mandibular first premolar leads to a predictable final result. The second malocclusion that favours canine substitution in the position of the lateral incisor is an end-to-end or Class II molar relationship, without crowding and dental protrusion in the mandibular anterior segment.

Certain factors that clinicians should consider in the decision-making of whether or not to close the space are the facial profile, the canine dimensions, the colour of these teeth and the gingival height<sup>35,98</sup>. Regarding the facial profile, a straight or slight convex profile is suitable for space closure unlike a serious convex profile with a retrusive mandible<sup>35</sup>. This is to avoid an optimal occlusion with compromised facial aesthetics, where a combination of orthog-



nathic surgery to correct the facial discrepancy and prosthodontic replacement of the laterals should be considered. As far as the size of canine is concerned, an average canine is 1.5 mm broader than the lateral incisor and after recontouring, should be slender than the central incisor. Specifically, canine recontouring should be done so as to eliminate the labial and proximal convexities, the lingual cingulum, and to form the mesioincisal and distoincisal edges. Unfortunately, in many cases, when canines are relatively large compared to the central incisor dimension, canine recontouring requires a significant amount of tooth reduction so as to resemble a lateral incisor, resulting inevitably in a restorative intervention on the shape of the canines and in order to increase the size of the central incisors. The canine width at the cemento-enamel junction is decisive on the required interventions, since it determines the amount of possible mesiodistal reduction.

Another point to be considered is the colour difference of the canines that are darker than incisors, a shade that becomes even more yellowish with extensive tooth recontouring<sup>4</sup>. This may be a reason to avoid the labial recontouring, by increasing the palatal root torque of the canine and decreasing occlusally the canine cusp length, which leads to a reduction in the extension of the labial canine convexity. Another approach to overcome the colour difference between canines and incisors is the tooth bleaching or the restorative treatment consisting of composite build-ups, veneers or all-ceramic crowns<sup>102</sup>.

Regarding the soft tissue architecture, the gingival zenith of the lateral incisor should be ideally 0.5 to 1.0 mm lower than the central incisors and canines<sup>4</sup>. To achieve an aesthetic gingival contour, the gingival margin of the central incisor and the first premolar should be at the same level, while the gingival zenith of the canine should be slightly incisal, by extrusion of the canine, balanced by grinding of the tip of the cusp and intrusion of the first premolar, with a compensatory reconstructive increase of the crown length, parallel to its palatal cusp reduction. Additionally, during the orthodontic space closure, attention should be given to provide a slight mesial tilting of the crown of the canine so as to imitate the tilting of the lateral; which can occur by full uprighting of the mesially displaced and tilted

canine, through extensive mesial root displacement. Moreover, the clinician should bear in mind that after the completion of the mesial movement of the maxillary canine, group function is usually established since the tip of the canine occludes with the mandibular lateral incisor. Last but not least, the stability of the space closure demands long-term retention with direct-bonded lingual retainers<sup>48,98</sup>.

### ■ Prosthodontic intervention

The second therapeutic option in the treatment of the congenitally missing lateral incisor includes the prosthodontic intervention. Space distribution of the edentulous regions, mesial and distal to the canines and the central incisors, respectively; occlusion; and aesthetics determine whether or not orthodontic space opening is needed prior to the prosthodontic rehabilitation. Canines should allow posterior disclusion during eccentric excursions, while central incisors should be placed in a position dictated by aesthetic and phonetic demands. Regarding the determination of the appropriate spacing needed for the lateral incisor, three methods are described in the literature<sup>33,34</sup>. The first method is based on the golden proportion. According to this, aesthetics and harmony are achieved in the maxillary anterior segment, when the width of each anterior tooth is 61.8% wider than the tooth distal to it, in the facial view. However, Pini et al observed that while the golden proportion was not found in the majority of patients with lateral agenesis, the smiles were still pleasing<sup>103</sup>. This finding demonstrates that the golden proportion may be a useful diagnostic guide, while a certain range of tolerance exists to achieve a high aesthetic outcome. The second method includes the determination of the space needed according to the contralateral incisor, whenever this is present and has a normal size. The third method refers to the Bolton analysis, where in order to obtain the proper interdigitation and arch coordination when the molars are in a Class I relationship, the dimension of the upper teeth has to be proportional to the dimension of the lower teeth. Regardless of the method that will be used, a diagnostic wax-up still remains a useful tool for the evaluation of the space distribution. According to Kinzer et al, the usual remaining space for a lateral incisor restoration should be 5 to 7 mm<sup>33</sup>.



Space opening and prosthodontic intervention is indicated in cases of Class I molar relationship without malocclusion, Class III malocclusion with a concave facial profile, and in cases in which the canine recontouring is not recommended<sup>98,104</sup> (see previous chapter). The prosthodontic intervention includes the following therapeutic options: i) single-tooth implant; ii) resin-bonded fixed partial denture; and iii) full-coverage fixed partial denture.

(i) The single-tooth implant option is considered to be the most conservative approach in cases of sound adjacent teeth. However, the clinician should consider several parameters regarding a) the time of implant placement; and b) the time of orthodontic space opening, with respect to the amount of bone available for implant insertion<sup>4,35</sup>.

a) The time of implant placement: numerous studies have reported the risk of infraocclusion of the implant crown if the implant is placed before the completion of the facial growth and the dental eruption. As a rule of thumb, females complete their facial growth by 17 years old, whereas males demonstrate a facial growth up to 25 years old<sup>105</sup>. However, large variations exist amongst individuals, therefore different methods are proposed to determine the patient's skeletal maturation. Hand-wrist radiographs and more recently, the cervical vertebral maturation method, have been used to estimate the amount of remaining craniofacial growth<sup>106,107</sup>. However, the reliability of growth prediction with these methods is not high<sup>108</sup>. Moreover, the superimposing of serial lateral cephalometric radiographs obtained 6 months to 1 year apart has been proposed to be useful in the evaluation of the completion of the facial growth. Facial growth could be considered as completed when the distance between the cephalometric points nasion and menton is stable<sup>4</sup>. However, this method is not recommended either, since the patient is exposed to radiation in an accumulative manner, while it has been shown that the facial dimensions are changing also during mature adulthood<sup>109</sup>. The most 'innocent' and inexpensive method is the standardised recording

of the body height obtained every 6 months. In general, most of the facial growth could be considered to be completed 1 year after stagnation of the body height increase. Attention should be paid to the fact that the risk of infraocclusion of the implant crown 5 to 10 years after the treatment may happen also during mature adulthood, due to continuous eruption of the teeth long after the completion of the facial growth<sup>110</sup>.

b) The time of the orthodontic space opening with respect to the amount of bone available for implant insertion: the procedure to obtain the adequate mesiodistal distance between the central incisor and the canine was linked to the available bone volume of the edentulous space, in patients with congenitally missing lateral incisors, as well as the best time when orthodontic treatment should occur prior to implant placement<sup>111</sup>.

Early diagnosis is very important particularly in patients scheduled for future implant therapy. This allows for planned extraction of the primary lateral incisor and the guided eruption of the canine adjacent to the permanent central incisor, avoiding bone loss and ensuring a proper implant site is established in the region of lateral agenesis<sup>33,99</sup>. Few studies have measured and compared changes in the alveolar ridge dimension at the beginning and the end of the orthodontic therapy<sup>49,111,112,113</sup>. In most of these studies, the information was obtained by measuring these changes on plaster models, which may provide indications on the alveolar bone changes only<sup>49,111,113</sup>. Novackova et al found a 4% reduction in the alveolar ridge width and a 0.26 mm reduction in the ridge height at the end of the orthodontic treatment, that was further reduced some years later by 2% and 0.38 mm, respectively. The results of this study showed minimal changes in the ridge width and height, indicating a stable and well preserved alveolar ridge<sup>113</sup>. In contrast, Beyer et al estimated an increase in bone deficiency from 0.26 mm<sup>2</sup>, at the beginning of the orthodontic treatment, to 1.92 mm<sup>2</sup> and 3.77 mm<sup>2</sup>, at the completion of the orthodontic treatment and implant insertion, respectively. Additionally, the same study has shown that patients who received orthodontic space open-



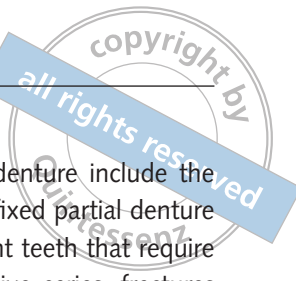ing after the age of 13 years, demonstrated more extensive reduction of the alveolar ridge dimensions, than the reduction observed in patients who received orthodontic space opening before the age of 13 years old<sup>111</sup>. Another study on dental cast measurements has also demonstrated a 13% to 15% decrease in the ridge width after orthodontic space opening and a 6% to 12% loss of the ridge height. These authors found an 0.5 mm increase in depth of the labial concavity between the maxillary central incisor and the canine<sup>49</sup>. Similar results were found on a smaller number of patients, using cone-beam computed tomography. Although more invasive than measuring dental casts, this method was more reliable and presented an alveolar bone width reduction by 17% to 25%, and a significant increase in the labial concavity, after the completion of the orthodontic space opening<sup>112</sup>. In cases where the bone width and height have undergone severe reduction, a bone graft may be necessary to establish the appropriate implant site.

Other factors that the clinician should take into consideration are the interradicular spacing and the retention of the space after the completion of the orthodontic treatment<sup>33,114</sup>. During the orthodontic space opening, the coronal mesiodistal space is achieved earlier than the interradicular mesiodistal distance, that is indispensable for the implant placement<sup>4</sup>. Therefore, radiographically evaluating the root distance before the removal of the orthodontic appliance is recommended. Regarding the postorthodontic root approximation after space opening, Olsen et al found that 11% of the patients presented with an inadequate space between roots, preventing the implant placement. According to the author's recommendation, an interradicular distance of 5.7 mm between the central incisor and the canine is considered sufficient for implant placement<sup>114</sup>. Moreover, the use of a fixed bonded lingual wire or a resin-bonded prosthesis is suggested for the retention period, while Krassnig et al recommended the use of a removable retainer such as a Hawley or an Essix retainer, when the retention period is anticipated to be short<sup>4</sup>.

Several studies have reported on the successful osseointegration of the single implants placed in the anterior maxilla<sup>79-86</sup>. Despite successful osseointegration, various studies have shown that resorp-

tion of the facial bone wall, recession of the mid-facial soft tissue, thread exposure and infraocclusion might occur<sup>86,89,110,115-117</sup>. According to den Hartog, Cosyn and Mangano, 40%, 26% and 11% of cases displayed unacceptable aesthetic results, due to the incomplete papilla filling, the facial recession and alveolar bone deficiencies<sup>84,117,118</sup>. Another side effect demonstrated by Bernard et al refers to vertical discrepancies that develop some years later, both in adolescent and adult patients, between adjacent teeth and implants, ranging from 0.10 mm to 1.86 mm<sup>110</sup>. This confirmed and completed the previous findings of Thilander et al, who detected the risk of development of infraocclusion amongst the adolescents<sup>89</sup>. Additional biological complications include fistulas, peri-implant mucositis and peri-implantitis, while the most frequent technical complications were screw loosening and porcelain chipping<sup>80,82,86</sup>.

(ii) Amongst the solely prosthodontic interventions, the resin-bonded prostheses are considered to be the most conservative option, since the adjacent teeth are subject to minimal tooth preparation. Except for the conservative nature of the preparation, other advantages include the avoidance of pulpal trauma, the supragingival preparation, the simplicity of the clinical procedures and the reduced cost and chair time, in comparison with the conventional fixed prostheses<sup>119</sup>. To achieve predictable and optimal aesthetic outcomes using resin-bonded prostheses, the clinician should take into consideration specific requirements of each treatment option<sup>34</sup>. The first requirement is related to the vertical position of the abutment teeth. Regarding the vertical position, the shallow overbite is considered to be the ideal interincisal relationship, since it reduces the excessive lateral forces on the abutments and permits sufficient tooth surface for bonding. The second requirement concerns the incisors' inclination. The upright incisors' relationship with an increased interincisal angle leads to the development of shear forces in the abutment teeth, which are more favourable than the tensile forces exerted when incisors are proclined with a smaller interincisal angle<sup>4</sup>. The third requirement is the absence of the teeth mobility. Specifically, the mobility



of the abutments leads to the development of different force vectors under the occlusal load, resulting in increased stress on the prosthesis. Excessive forces are placed on the prosthesis even when only one abutment is mobile<sup>34</sup>. The fourth requirement is related to the labiolingual thickness of the abutments and the translucency of the enamel. When the incisors are too thin, with a high degree of translucency, the extension of the metal retainer on the incisal third leads to an undesirable gray shade abutment<sup>4,34</sup>. To overcome this problem, all-ceramic and/or zirconia restorations can be used, which have high aesthetic outcomes. Furthermore, parafunction activities such as bruxism negatively influence the long-term success of resin-bonded prostheses<sup>120</sup>. Consequently, the patient selection is the most critical aspect when the clinician considers the resin-bonded prostheses as a possible therapeutic option.

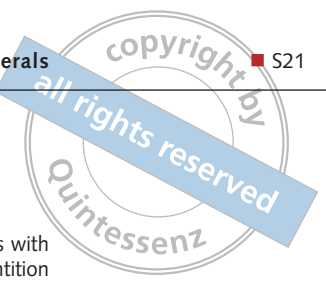Various studies have been published in the literature, regarding the longevity of the resin-bonded prostheses<sup>121-125</sup>. A systematic review conducted by Pjetursson et al on earlier types of resin-bonded prostheses demonstrated a 5-year survival rate of 87.7%. The most frequent complication was debonding<sup>126</sup>. All the included studies except that by Kern et al<sup>127</sup> examined metal-ceramic resin-bonded prostheses. Other reported complications were fractures and slight grayness of the abutments<sup>127,128,129</sup>. However, the change in the prosthesis design from two retainers to a single retainer, as well as the use of all-ceramic restorations, with more recent cementation systems, have decreased the high frequency of debondings and fractures leading to increased survival rates. This is supported by literature on cantilevered all-ceramic resin-bonded prostheses, which exhibited survival rates ranging from 94.4% to 100%<sup>68,69,130,131</sup>.

(iii) The full-coverage fixed partial denture is the last prosthodontic therapeutic option in the treatment of congenitally missing lateral incisors. This approach is considered as the least conservative of all tooth-supported restorations and its use is quite rare in the treatment of tooth agenesis in the anterior region. The indications for the

full-coverage fixed partial denture include the replacement of an existing fixed partial denture and the presence of adjacent teeth that require rehabilitation due to extensive caries, fractures and/or discolourations. One of the basic principles in the preparation of abutment teeth for fabrication of a full-coverage restoration is the alignment of the abutment teeth along a common pathway. This can lead to extensive tooth reduction, in cases in which one of the two abutment teeth is malpositioned, increasing the risk of pulpal trauma, especially in young patients. This problem can be overcome by orthodontic correction of the proclined abutments<sup>132</sup>. A systematic review conducted by Sailer et al reported a 5-year survival rate of metal-ceramic restorations to be 94.4% and of all-ceramic restorations to be 88.6%. As for the all-ceramic restorations, the most frequent technical complications were marginal discolouration (15.3%) and porcelain chipping (13.6%), while the most serious complication was the framework fracture. Additionally, loss of retention and biological complications (i.e. caries and pulpal necrosis) were frequent for both types of restorations<sup>133</sup>.

The treatment choice is based on a complex decision-making procedure. Except for the biological, aesthetic and functional outcomes, financial issues should also influence the final decision-making. Antonarakis et al compared the long-term cost-effectiveness of the different prosthodontic therapeutic options in patients with congenitally missing lateral incisors and found that the least cost-effective therapeutic modality was the full-coverage fixed partial denture, while the resin-bonded prostheses were considered as more cost-effective than the single implant crowns<sup>134</sup>. Other studies demonstrated the superiority of the implant approach over the fixed partial dentures, regarding cost-effectiveness<sup>135,136,137</sup>. However, in most cases of lateral agenesis, an orthodontic space opening is required prior to the implant therapy. Thus, the combination of orthodontic and prosthodontic therapy should be taken into consideration when evaluating the cost-effectiveness of different therapeutic modalities in the rehabilitation of lateral agenesis.





The absence of randomised controlled trials and the limited number of prospective and retrospective studies comparing the two different therapeutic options make it difficult to draw definitive conclusions about the superiority of one treatment option over the other, regarding the biological, functional and aesthetic outcomes. According to this systematic review, both therapeutic options are acceptable. However, it seems that in cases where both the therapeutic approaches are applicable, the orthodontic space closure is advantageous over the prosthodontic rehabilitation, regarding the periodontal health and the aesthetic outcome. Moreover, the main advantage of the orthodontic treatment is the longevity of the therapeutic result and the completion of the definitive treatment during early adolescence, without the risk of long-term biological and technical complications accompanying the prosthodontic rehabilitation. Well-designed randomised clinical trials and multicenter studies are required to compare these different therapeutic options.

In conclusion, early diagnosis of the congenitally missing lateral incisor is important, since it allows for planned extraction of the deciduous lateral incisor and the guided eruption of the canine adjacent to the permanent central incisor, either to proceed to later space closure or to open space for prosthodontic rehabilitation. Consequently, the bone loss is avoided and the alveolar ridge thickness is maintained. Lastly, when both orthodontic and prosthodontic intervention are possible, therapeutic options, the orthodontic space closure is more preferable than space opening, due to its superiority in the periodontal health and aesthetic outcome. Moreover, the early completion of the definitive treatment and the absence of the long-term biological and technical complications make the orthodontic space closure the treatment of choice, in cases where both therapeutic options are indicated.

## References

- Shapiro SD, Farrington FH. A potpourri of syndromes with anomalies of dentition. In: Jorgenson RJ (ed). *Dentition genetic effects. Birth Defects: Original Article Series*. New York: March of Dimes Birth Defects Foundation; 1983, 129–140.
- Kumar GS. *Orban's Oral histology and Embryology*. St Louis: Elsevier; 2014.
- Vastardis H. The genetics of human tooth agenesis: new discoveries for understanding dental anomalies. *Am J Orthod Dentofacial Orthop* 2000;117:650–656.
- Krassnig M, Fickl S. Congenitally missing lateral incisors-A comparison between restorative, implant, and orthodontic approaches. *Dent Clin North Am* 2011;55:283–299.
- Clayton JM. Congenital dental anomalies occurring in 3,557 children. *J Dent Child* 1956;23:206–218.
- Lavelle CL, Ashton EH, Flinn RM. Cusp pattern, tooth size and molar agenesis in the human mandibular dentition. *Arch Oral Biol* 1970;15:227–237.
- Brekhus P, Oliver C, Montelius G. A study of the pattern and combination of congenitally missing teeth in man. *J Dent Res* 1944;23:117–131.
- Muller TP, Hill IN, Peterson AC, Blayney JR. A survey of congenitally missing permanent teeth. *J Am Dent Assoc* 1970;81:101–107.
- Baum BJ, Cohen MM. Studies on agenesis in the permanent dentition. *Am J Phys Anthropol* 1971;35:125–128.
- Malik SA. Missing and rudimentary upper lateral incisors: A statistical survey. *J Dent* 1972;1:25–27.
- Glenn FB. Incidence of congenitally missing permanent teeth in a private pedodontic practice. *J Dent Child* 1961;28:317–20.
- Serrano J. Oligodontia and fusion. *Oral Surg Oral Med Oral Pathol* 1972;34:691–692.
- Hundstadbraten K. Hypodontia in the permanent dentition. *ASDC J Dent Child* 1973;40:115–117.
- Arte S, Nieminen P, Apajalahti S, Haavikko K, Thesleff I, Pirinen S. Characteristics of incisor-premolar hypodontia in families. *J Dent Res* 2001;80:1445–1450.
- Niswander JD, Sujaku C. Congenital anomalies of teeth in Japanese children. *Am J Phys Anthropol* 1963;21:569–574.
- Rose JS. A survey of congenitally missing teeth, excluding third molars, in 6000 orthodontic patients. *Dent Pract Dent Rec* 1966;17:107–114.
- Bergström K. An orthopantomographic study of hypodontia, supernumeraries and other anomalies in school children between the ages of 8-9 years. An epidemiological study. *Swed Dent J* 1977;1:145–157.
- Magnússon TE. Prevalence of hypodontia and malformations of permanent teeth in Iceland. *Community Dent Oral Epidemiol* 1977;5:173–178.
- Rolling S. Hypodontia of permanent teeth in Danish schoolchildren. *Scand J Dent Res* 1980;88:365–369.
- Davis PJ. Hypodontia and hyperdontia of permanent teeth in Hong-Kong schoolchildren. *Community Dent Oral Epidemiol* 1987;15:218–220.
- Nik-Hussein NN. Hypodontia in the permanent dentition: a study of its prevalence in Malaysian children. *Aust Orthod J* 1989;11:93–95.
- O'Dowling IB, McNamara TG. Congenital absence of permanent teeth among Irish school-children. *J Ir Dent Assoc* 1990;36:136–138.
- Aasheim B, Ogaard B. Hypodontia in 9-year-old Norwegians related to need of orthodontic treatment. *Scand J Dent Res* 1993;101:257–260.
- Nordgarden H, Jensen JL, Storhaug K. Reported prevalence of congenitally missing teeth in two Norwegian counties. *Community Dent Health* 2002;19:258–261.

25. Albashaireh ZS, Khader YS. The prevalence and pattern of hypodontia of the permanent teeth and crown size and shape deformity affecting upper lateral incisors in a sample of Jordanian dental patients. *Community Dent Health* 2006;23:239–243.
26. Goya HA, Tanaka S, Maeda T, Akimoto Y. An orthopantomographic study of hypodontia in permanent teeth of Japanese pediatric patients. *J Oral Sci* 2008;50:143–150.
27. Shimizu T, Maeda T. Prevalence and genetic basis of tooth agenesis. *Jpn Dent Sci Rev* 2009;45:52–58.
28. Alves-Ferreira M, Pinho T, Sousa A, Sequeiros J, Lemos C, Alonso I. Identification of genetic risk factors for maxillary lateral incisor agenesis. *J Dent Res* 2014;93:452–458.
29. Cakan U, Demiralp B, Aksu M, Taner T. Clinical showcase. Replacement of congenitally missing lateral incisor using a metal-free, resin-bonded fixed partial denture: case report. *J Can Dent Assoc* 2009;75:509–512.
30. Millet C, Viennot S, Duprez JP. Case report: Rehabilitation of a child with dentinogenesis imperfecta and congenitally missing lateral incisors. *Eur Arch Paediatr Dent* 2010;11:256–260.
31. Strong SM. Replacement of congenitally missing lateral incisors with implant crowns. *Gen Dent* 2008;56:516–519.
32. Simeone P, De Paoli C, De Paoli S, Leofreddi G, Sgro S. Interdisciplinary treatment planning for single-tooth restorations in the esthetic zone. *J Esthet Restor Dent* 2007;19:79–89.
33. Kinzer GA, Kokich VO Jr. Managing congenitally missing lateral incisors. Part III: single-tooth implants. *J Esthet Restor Dent* 2005;17:202–210.
34. Kinzer GA, Kokich VO Jr. Managing congenitally missing lateral incisors. Part II: tooth-supported restorations. *J Esthet Restor Dent* 2005;17:76–84.
35. Kokich VO Jr, Kinzer GA. Managing congenitally missing lateral incisors. Part I: Canine substitution. *J Esthet Restor Dent* 2005;17:5–10.
36. Savarrio L, McIntyre GT. To open or to close space—that is the missing lateral incisor question. *Dent Update* 2005;32:16–8, 20–22, 24–25.
37. Beznos C. An alternative approach to replacement of a congenitally missing maxillary central incisor: a case report. *Quintessence Int* 1996;27:759–762.
38. Small BW. Esthetic management of congenitally missing lateral incisors with single-tooth implants: a case report. *Quintessence Int* 1996;27:585–590.
39. Trushkowsky RD. Replacement of congenitally missing lateral incisors with ceramic resin-bonded fixed partial dentures. *J Prosthet Dent* 1995;73:12–16.
40. Balshi TJ. Osseointegration and orthodontics: modern treatment for congenitally missing teeth. *Int J Periodontics Restorative Dent* 1993;13:494–505.
41. Fisher FJ, Jones SA. Replacement of missing maxillary canines by resin-bonded bridgework. *Dent Update* 1990;17:168–169.
42. Oosterkamp BC, Dijkstra PU, Rimmelink HJ, van Oort RP, Sandham A. Orthodontic space closure versus prosthetic replacement of missing upper lateral incisors in patients with bilateral cleft lip and palate. *Cleft Palate Craniofac J* 2010;47:591–596.
43. Slutsky H, Greenberg JR. Orthodontic and prosthetic treatment of a patient with cystic fibrosis and agenesis of maxillary lateral incisors. *Compend Contin Educ Dent* 2011;32:E80–E85.
44. Bidra AS. Esthetic and functional rehabilitation of a bilateral cleft palate patient with fixed prosthodontic therapy. *J Esthet Restor Dent* 2012;24:236–244.
45. Andrade DC, Loureiro CA, Araújo VE, Riera R, Atallah AN. Treatment for agenesis of maxillary lateral incisors: a systematic review. *Orthod Craniofac Res* 2013;16:129–136.
46. Jackson BJ, Slavin MR. Treatment of congenitally missing maxillary lateral incisors: an interdisciplinary approach. *J Oral Implantol* 2013;39:187–192.
47. Jackson BJ, Slavin MR. Treatment of congenitally missing maxillary lateral incisors: an interdisciplinary approach [epub ahead of print 12 Mar 2012]. *J Oral Implantol*.
48. Zachrisson BU, Rosa M, Toreskog S. Congenitally missing maxillary lateral incisors: canine substitution. *Point. Am J Orthod Dentofacial Orthop* 2011;139:434, 436, 438.
49. Uribe F, Chau V, Padala S, Neace WP, Cutrera A, Nanda R. Alveolar ridge width and height changes after orthodontic space opening in patients congenitally missing maxillary lateral incisors. *Eur J Orthod* 2013;35:87–92.
50. Tuna SH, Keyf F, Pekkan G. The Single-tooth Implant Treatment of Congenitally Missing Maxillary Lateral Incisors Using Angled Abutments: A Clinical Report. *Dent Res J (Isfahan)* 2009;6:93–98.
51. Park JH, Okadake S, Sato Y, Akamatsu Y, Tai K. Orthodontic treatment of a congenitally missing maxillary lateral incisor. *J Esthet Restor Dent* 2010;22:297–312.
52. Paduano S, Cioffi I, Rongo R, Cupo A, Bucci R, Valletta R. Orthodontic management of congenitally missing maxillary lateral incisors: a case report. *Case Rep Dent* 2014;2014:731074.
53. Oliveira DD, de Oliveira BF, da Mata Cid Pinto LS, Figueiredo DS, Pithon MM, Seraidarian PI. Interdisciplinary treatment of a class III patient with congenitally absent maxillary lateral incisors. *J Esthet Restor Dent* 2013;25:242–253.
54. Nissan J, Mardinger O, Strauss M, Peleg M, Sacco R, Chaushu G. Implant-supported restoration of congenitally missing teeth using cancellous bone block-allografts. *Oral Surg Oral Med Oral Pathol Oral Radiol Endod* 2011;111:286–291.
55. Mummid B, Rao CH, Prasanna AL, Vijay M, Reddy KV, Raju MA. Esthetic dentistry in patients with bilaterally missing maxillary lateral incisors: a multidisciplinary case report. *J Contemp Dent Pract* 2013;14:348–354.
56. Robertsson S, Mohlin B, Thilander B. Aesthetic evaluation in subjects treated due to congenitally missing maxillary laterals. A comparison of perception in patients, parents and dentists. *Swed Dent J* 2010;34:177–186.
57. De Marchi LM, Pini NI, Pascotto RC. The relationship between smile attractiveness and esthetic parameters of patients with lateral agenesis treated with tooth recontouring or implants. *Clin Cosmet Investig Dent* 2012;4:43–49.
58. Pini NP, De Marchi LM, Gribel BF, Pascotto RC. Digital analysis of anterior dental esthetic parameters in patients with bilateral maxillary incisor agenesis. *J Esthet Restor Dent* 2013;25:189–200.
59. Marchi LM, Pini NI, Hayacibara RM, Silva RS, Pascotto C. Congenitally missing maxillary lateral incisors: functional and periodontal aspects in patients treated with implants or space closure and tooth re-contouring. *Open Dent J* 2012;6:248–254.
60. De Marchi LM, Pini NI, Ramos AL, Pascotto RC. Smile attractiveness of patients treated for congenitally missing maxillary lateral incisors as rated by dentists, laypersons, and the patients themselves. *J Prosthet Dent* 2014;112:540–546.
61. Nordquist G, McNeil RW. Orthodontic vs. restorative treatment of the congenitally absent lateral incisor—long term periodontal and occlusal evaluation. *J Periodontol* 1975;46:139–143.
62. Robertsson S, Mohlin B. The congenitally missing upper lateral incisor. A retrospective study of orthodontic space closure versus restorative treatment. *Eur J Orthod* 2000;22:697–710.
63. Jamilian A, Perillo L, Rosa M. Missing upper incisors: a retrospective study of orthodontic space closure versus implant. *Prog Orthod* 2015;16:2.

64. Branzen M, Eliasson A, Arnrup K, Bazargani F. Implant-Supported Single Crowns Replacing Congenitally Missing Maxillary Lateral Incisors: A 5 Year Follow-Up. *Clin Implant Dent Relat Res* 2014;17:1134–1140.
65. Garnett MJ, Wassell RW, Jepson NJ, Nohl FS. Survival of resin-bonded bridgework provided for post-orthodontic hypodontia patients with missing maxillary lateral incisors. *Br Dent J* 2006;201:527–534.
66. Mangano C, Levrini L, Mangano A, Mangano F, Macchi A, Caprioglio A. Esthetic evaluation of implants placed after orthodontic treatment in patients with congenitally missing lateral incisors. *J Esthet Restor Dent* 2014;26:61–71.
67. Peñarocha M, Lamas J, Peñarocha M, Garcia B. Immediate maxillary lateral incisor implants with nonocclusal loading provisional crowns. *J Prosthodont* 2008;17:55–59.
68. Sailer I, Bonani T, Brodbeck U, Hämmerle CH. Retrospective clinical study of single-retainer cantilever anterior and posterior glass-ceramic resin-bonded fixed dental prostheses at a mean follow-up of 6 years. *Int J Prosthodont* 2013;26:443–450.
69. Sailer I, Hämmerle CH. Zirconia ceramic single-retainer resin-bonded fixed dental prostheses (RBFDPs) after 4 years of clinical service: a retrospective clinical and volumetric study. *Int J Periodontics Restorative Dent* 2014;34:333–343.
70. Zarone F, Sorrentino R, Vaccaro F, Russo S. Prosthetic treatment of maxillary lateral incisor agenesis with osseointegrated implants: a 24–39-month prospective clinical study. *Clin Oral Impl Res* 2006;17:94–101.
71. Stamatou J, Symons AL. Agenesis of the permanent lateral incisor: distribution, number and sites. *J Clin Pediatr Dent* 1991;15:244–246.
72. Polder BJ, Van't Hof MA, Van der Linden FP, Kuijpers-Jagtman AM. A meta-analysis of the prevalence of dental agenesis of permanent teeth. *Community Dent Oral Epidemiol* 2004;32:217–226.
73. Pinho T, Tavares P, Maciel P, Pollmann C. Developmental absence of maxillary lateral incisors in the Portuguese population. *Eur J Orthod* 2005;27:443–449.
74. Celikoglu M, Kamak H, Yildirim H, Ceylan I. Investigation of the maxillary lateral incisor agenesis and associated dental anomalies in an orthodontic patient population. *Med Oral Patol Oral Cir Bucal* 2012;17:e1068–1073.
75. Svinhufvud E, Myllarniemi S, Norio R. Dominant inheritance of tooth malpositions and their association to hypodontia. *Clin Genet* 1988;34:373–381.
76. Fekonja A. Hypodontia in orthodontically treated children. *Eur J Orthod* 2005;27:457–460.
77. Pinholt EM. Branemark and ITI dental implants in the human bone-grafted maxilla: a comparative evaluation. *Clin Oral Implants Res* 2003;14:584–592.
78. Al Nawas B, Hangen U, Duschner H, Krummenauer F, Wagner W. Turned, machined versus double-etched dental implants in vivo. *Clin Implant Dent Relat Res* 2007;9:71–78.
79. Polizzi G, Fabbro S, Furri M, Herrmann I, Squarzone S. Clinical application of narrow Brånemark System implants for single-tooth restorations. *Int J Oral Maxillofac Implants* 1999;14:496–503.
80. Andersen E, Saxegaard E, Knutsen BM, Haanæs HR. A prospective clinical study evaluating the safety and effectiveness of narrow-diameter threaded implants in the anterior region of the maxilla. *Int J Oral Maxillofac Implants* 2001;16:217–224.
81. Glauser R, Sailer I, Wohlwend A, Studer S, Schibli M, Schärer P. Experimental zirconia abutments for implant-supported single-tooth restorations in esthetically demanding regions: 4-year results of a prospective clinical study. *Int J Prosthodont* 2004;17:285–290.
82. Jemt T. Single implants in the anterior maxilla after 15 Years of follow-up: comparison with central implants in the edentulous maxilla. *Int J Prosthodont* 2008;21:400–408.
83. Santing HJ, Raghoebar GM, Vissink A, den Hartog L, Meijer HJ. Performance of the Straumann Bone Level Implant system for anterior single-tooth replacements in augmented and nonaugmented sites: a prospective cohort study with 60 consecutive patients. *Clin Oral Implants Res* 2013;24:941–948.
84. Mangano FG, Mangano C, Ricci M, Sammons RL, Shibli JA, Piattelli A. Esthetic evaluation of single-tooth Morse taper connection implants placed in fresh extraction sockets or healed sites. *J Oral Implantol* 2013;39:172–181.
85. Vanlıoğlu BA, Kahramanoğlu E, Yıldız C, Ozkan Y, Kulak-Özkan Y. Esthetic outcome evaluation of maxillary anterior single-tooth bone-level implants with metal or ceramic abutments and ceramic crowns. *Int J Oral Maxillofac Implants* 2014;29:1130–1136.
86. Zhao X, Qiao SC, Shi JY, Uemura N, Arai K, Lai HC. Evaluation of the clinical and aesthetic outcomes of Straumann Standard Plus implants supported single crowns placed in non-augmented healed sites in the anterior maxilla: a 5–8 years retrospective study. *Clin Oral Implants Res* 2016;27:106–112.
87. Droukas B, Lindée C, Carlsson GE. Relationship between occlusal factors and signs and symptoms of mandibular dysfunction. A clinical study of 48 dental students. *Acta Odontol Scand* 1984;42:277–283.
88. Pilley JR, Mohlin B, Shaw WC, Kingdon A. A survey of craniomandibular disorders in five-hundred 19-year-olds. *Eur J Orthod* 1997;19:57–70.
89. Thilander B, Odman J, Lekholm U. Orthodontic aspects of the use of the oral implants in adolescents: a 10-year follow-up study. *Eur J Orthod* 2001;23:715–731.
90. Hobkirk JA, Goodman JR, Jones SP. Presenting complaints and findings in a group of patients attending a hypodontia clinic. *Br Dent J* 1994;177:337–339.
91. Robinson S, Chan MF. New teeth from old: treatment options for retained primary teeth. *Br Dent J* 2009;207:315–320.
92. Pinho T, Lemos C. Dental repercussions of maxillary lateral incisor agenesis. *Eur J Orthod* 2012;34:698–703.
93. Pinho T, Maciel P, Pollmann C. Developmental disturbances associated with agenesis of the permanent maxillary lateral incisor. *Br Dent J* 2009;207:E25.
94. Garib DG, Alencar BM, Lauris JR, Baccetti T. Agenesis of maxillary lateral incisors and associated dental anomalies. *Am J Orthod Dentofacial Orthop* 2010;137:732–733.
95. Yaqoob O, DiBiase AT, Garvey T, Fleming PS. Relationship between bilateral congenital absence of maxillary lateral incisors and anterior tooth width. *Am J Orthod Dentofacial Orthop* 2011;139:e229–e233.
96. Mirabella AD, Kokich VG, Rosa M. Analysis of crown widths in subjects with congenitally missing maxillary lateral incisors. *Eur J Orthod* 2012;34:783–787.
97. Tuverson DL. Orthodontic treatment using canines in place of missing maxillary lateral incisors. *Am J Orthod* 1970;58:109–127.
98. Rosa M, Zachrisson B. Integrating esthetic dentistry and space closure in patients with missing maxillary lateral incisors. *J Clin Orthod* 2001;35:221–234.
99. Kokich V Jr. Early Management of Congenitally Missing Teeth. *Semin Orthod* 2005;11:146–151.
100. McNeill RW, Joondeph DR. Congenitally absent maxillary lateral incisors: treatment planning considerations. *Angle Orthod* 1973;43:24–29.
101. Zachrisson BU. Improving orthodontic results in cases with maxillary incisors missing. *Am J Orthod* 1978;73:274–289.
102. Sabri R. Management of missing maxillary lateral incisors. *J Am Dent Assoc* 1999;130:80–84.
103. Pini NP, de-Marchi LM, Gribel BF, Ubaldini AL, Pascotto RC. Analysis of the golden proportion and width/height ratios of maxillary anterior dentition in patients with lateral incisor agenesis. *J Esthet Restor Dent* 2012;24:402–414.

104. Naretto S (ed). Principles in Contemporary Orthodontics. InTech: Croatia, 2011:596.
105. Oesterle LJ, Cronin RJ Jr. Adult growth, aging, and the single-tooth implant. *Int J Oral Maxillofac Implants* 2000;15:252–260.
106. Verma D, Peltomäki T, Jäger A. Reliability of growth prediction with hand-wrist radiographs. *Eur J Orthod* 2009;31:438–442.
107. Baccetti T, Franchi L, McNamara JA Jr. The cervical vertebral maturation (CVM) method for the assessment of optimal treatment timing in dentofacial orthopedics. *Semin Orthod* 2005;11:119–129.
108. Beit P, Peltomäki T, Schätzle M, Signorelli L, Patcas R. Evaluating the agreement of skeletal age assessment based on hand-wrist and cervical vertebrae radiography. *Am J Orthod Dentofacial Orthop* 2013;144:838–847.
109. Behrents RG. The biological basis for understanding craniofacial growth during adulthood. *Prog Clin Biol Res* 1985;187:307–319.
110. Bernard JP, Schatz JP, Christou P, Belser U, Kiliaridis S. Long-term vertical changes of the anterior maxillary teeth adjacent to single implants in young and mature adults. A retrospective study. *J Clin Periodontol* 2004;31:1024–1028.
111. Beyer A, Tausche E, Boening K, Harzer W. Orthodontic space opening in patients with congenitally missing lateral incisors. *Angle Orthod* 2007;77:404–409.
112. Uribe F, Padala S, Allareddy V, Nanda R. Cone-beam computed tomography evaluation of alveolar ridge width and height changes after orthodontic space opening in patients with congenitally missing maxillary lateral incisors. *Am J Orthod Dentofacial Orthop* 2013;144:848–859.
113. Nováčková S, Marek I, Kamínek M. Orthodontic tooth movement: bone formation and its stability over time. *Am J Orthod Dentofacial Orthop* 2011;139:37–43.
114. Olsen TM, Kokich VG Sr. Postorthodontic root approximation after opening space for maxillary lateral incisor implants. *Am J Orthod Dentofacial Orthop* 2010;137:158–159.
115. Gallucci GO, Grutter L, Chuang SK, Belser UC. Dimensional changes of peri-implant soft tissue over 2 years with single-implant crowns in the anterior maxilla. *J Clin Periodontol* 2011;38:293–299.
116. Gallucci GO, Grutter L, Nedir R, Bischof M, Belser UC. Esthetic outcomes with porcelain-fused to-ceramic and all-ceramic single-implant crowns: a randomized clinical trial. *Clin Oral Implants Res* 2011;22:62–69.
117. Cosyn J, Eghbali A, De Bruyn H, Dierens M, De Rouck T. Single implant treatment in healing versus healed sites of the anterior maxilla: an aesthetic evaluation. *Clin Implant Dent Relat Res* 2012;14:517–526.
118. den Hartog L, Raghoobar GM, Slater JJ, Stellingsma K, Vis-sink A, Meijer HJ. Single-Tooth implants with different neck designs: A randomized clinical trial evaluating the aesthetic outcome. *Clin Implant Dent Relat Res* 2013;15:311–321.
119. Rosentiel S, Land M, Fujimoto J. Contemporary fixed prosthodontics. St Louis: Elsevier, 2006: 812.
120. el-Mowafy O, Rubo MH. Resin-bonded fixed partial dentures—a literature review with presentation of a novel approach. *Int J Prosthodont* 2000;13:460–467.
121. Wood M, Thompson VP, Romberg E, Morrison G. Resin-bonded fixed partial dentures. II. Clinical findings re-lated to prosthodontic characteristics after approximately 10 years. *J Prosthet Dent* 1996;76:368–373.
122. Hansson O. Clinical results with resin-bonded prostheses and an adhesive cement. *Quintessence Int* 1994;25:125–132.
123. Hansson O, Bergstrom B. A longitudinal study of resin-bonded prostheses. *J Prosthet Dent* 1996;76:132–139.
124. Botelho MG, Ma X, Cheung GJ, Law RK, Tai MT, Lam WY. Long term clinical evaluation of 211 two-unit cantilevered resin-bonded fixed partial dentures. *J Dent* 2014;42:778–784.
125. Galiatsatos AA, Bergou D. Clinical evaluation of anterior all-ceramic resin-bonded fixed dental prostheses. *Quintessence Int* 2014;45:9–14.
126. Pjetursson BE, Tan WC, Tan K, Bragger U, Zwahlen M, Lang NP. A systematic review of the survival and complication rates of resin-bonded bridges after an observation period of at least 5 years. *Clin Oral Implants Res* 2008;19:131–141.
127. Kern M. Clinical long-term survival of two-retainer and single-retainer all-ceramic resin-bonded fixed partial dentures. *Quintessence Int* 2005;36:141–147.
128. Saker S, El-Fallal A, Abo-Madina M, Ghazy M, Ozcan M. Clinical survival of anterior metal-ceramic and all-ceramic cantilever resin-bonded fixed dental prostheses over a period of 60 months. *Int J Prosthodont* 2014;27:422–424.
129. Gilmour AS, Ali A. Clinical performance of resin-retained fixed partial dentures bonded with a chemically active luting cement. *J Prosthet Dent* 1995;73:569–573.
130. Kern M, Sasse M. Ten-year survival of anterior all-ceramic resin-bonded fixed dental prostheses. *J Adhes Dent* 2011;13:407–410.
131. Sasse M, Kern M. Survival of anterior cantilevered all-ceramic resin-bonded fixed dental prostheses made from zirconia ceramic. *J Dent* 2014;42:660–663.
132. Rosentiel S, Land M, Fujimoto J. Contemporary fixed prosthodontics. St. Louis: Mosby, Elsevier, 2015: 888.
133. Sailer I, Pjetursson BE, Zwahlen M, Hammerle CH. A systematic review of the survival and complication rates of all-ceramic and metal-ceramic reconstructions after an observation period of at least 3 years. Part II: Fixed dental prostheses. *Clin Oral Implants Res* 2007;18(Suppl 3):86–96.
134. Antonarakis GS, Prevezanos P, Gavric J, Christou P. Agensis of maxillary lateral incisor and tooth replacement: cost-effectiveness of different treatment alternatives. *Int J Prosthodont* 2014;27:257–263.
135. Bragger U, Krenander P, Lang NP. Economic aspects of single-tooth replacement. *Clin Oral Implants Res* 2005;16:335–341.
136. Bouchard P, Renouard F, Bourgeois D, Fromentin O, Jeaneret MH, Beresniak A. Cost-effectiveness modeling of dental implant vs. bridge. *Clin Oral Implants Res* 2009;20:583–587.
137. Scheuber S, Hicklin S, Bragger U. Implants versus short-span fixed bridges: survival, complications, patients' benefits. A systematic review on economic aspects. *Clin Oral Implants Res* 2012;23(suppl 6):50–62.