

Marco Furri, Carlo Tocchio, Antonio Bonaccorso, Teresa Roberta Tripi, Giuseppe Cantatore

## Apical canal confluency in mandibular molars



### Marco Furri

Via Casara n.6  
37017 Lazise (VR)  
mafurri@tin.it  
Tel. + 393355974855

### Carlo Tocchio

Via XX Settembre, n.165  
45021 Badia Polesine  
Rovigo  
studio.beto@libero.it

### Antonio Bonaccorso

Private Practice,  
Viale Africa n.46,  
95127 Catania,  
Italy  
Tel: +39 095388612  
Fax: +39 095388612  
Email: endomaterials@fast-  
webnet.it

### Teresa Roberta Tripi

Department of Operative  
Dentistry,  
University of Catania,  
Catania,  
Italy

### Giuseppe Cantatore

Department of Operative  
Dentistry,  
University of Verona,  
Verona,  
Italy

**Key words** *endodontic anatomy, NiTi instrument failure, root canals*

Accurate knowledge of canal anatomy is one of the keys to success when performing root canal treatment. A successful outcome depends on three-dimensional debridement and obturation of the root canal system, maintained by a good coronal seal. Intimate knowledge of canal confluency is very important in order to shape the root canal system in the best possible way, and appreciation of uncommon anatomy allows the endodontist to conserve dental tissue. Moreover, using nickel-titanium (NiTi) rotary files, apical confluences and the acute angles of root curvatures often carries a high risk of instrument separation. The aim of this paper is to describe the root canal anatomy of mandibular molars.

### ■ Introduction

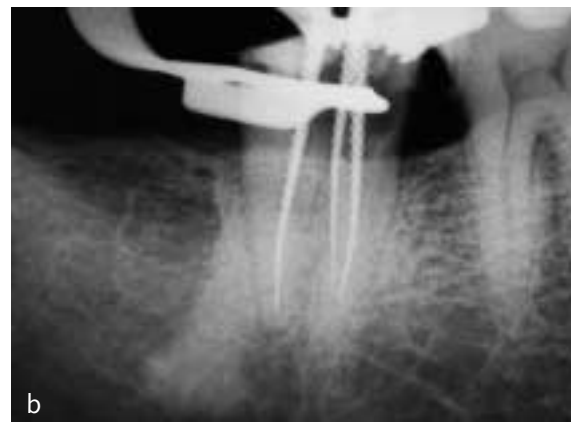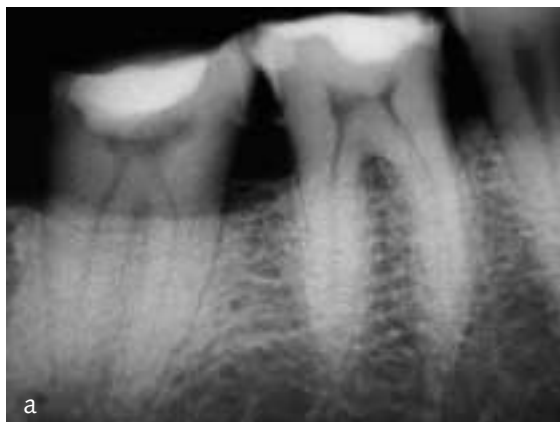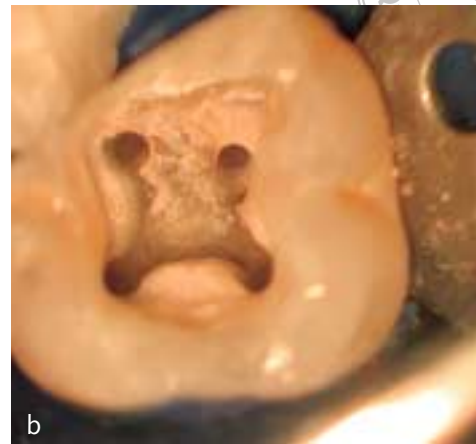
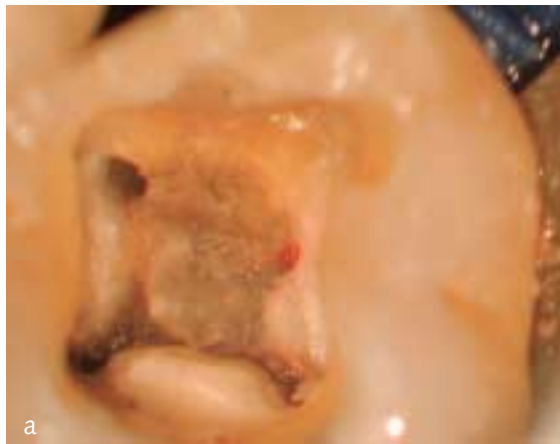
Success in root canal treatment depends on a thorough knowledge of root canal anatomy and its variants<sup>1</sup>. Careful investigation of main root canal/s and accessory canal/s should help the clinician to be aware of the negotiable endodontic space, important parts of the root canal system that may cause treatment difficulties<sup>2</sup>. Clinicians may consider lower molars as simple teeth with two roots and three canals, and it is easy to overlook a fourth canal. This is a reason why sometimes root canal treatment of the lower molars is unsuccessful and re-treatment necessary, especially of the distal root. The use of an operating microscope aids location of a second distal canal (Fig 1).

The presence of two canals in the same root requires particular care during the canal preparation

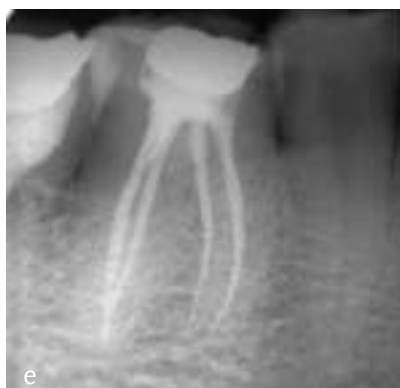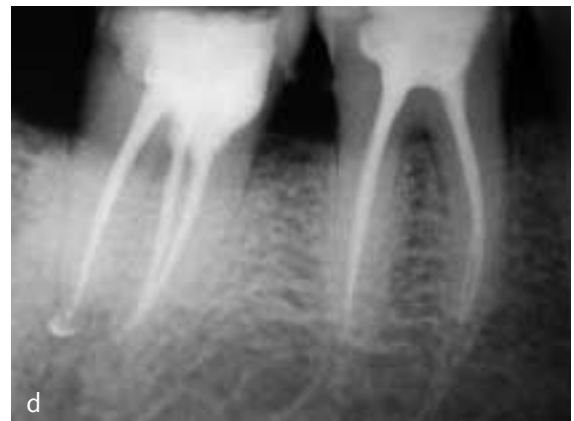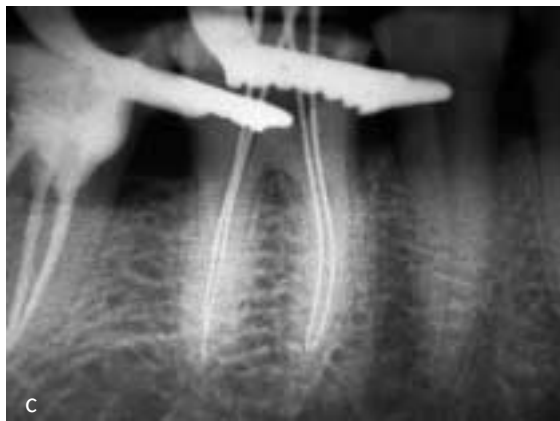procedures, especially when using nickel-titanium (NiTi) instruments. Two separate canals are frequently found in the mesial roots of mandibular first molars (Fig 2 c–e) and in the mesial roots of maxillary first molars. According to Weine<sup>3</sup>, four typical canal configurations can be found in these roots (Type I–IV) (Fig 3).

In a recent study, the number of canals and incidence of apical confluency in mandibular molars were reported<sup>4</sup>. The results showed that 53.7% of mandibular first molars had three root canals and 43% four canals. More than 80% of lower second molars showed three canals, two and four canals were present in about 5% of the cases, while less than 3% of the teeth showed a single canal or C-shaped anatomy. Most of the lower third molars have three canals.

**Figs 1a and 1b** The most common configuration in mandibular first molars is the presence of two mesial canals and often two distal canals.



**Figs 2a and 2b** Three root canals in a mandibular second molar.



**Figs 2c to 2e** Two separate root canals are frequently found in the mesial and distal roots of mandibular first molars.

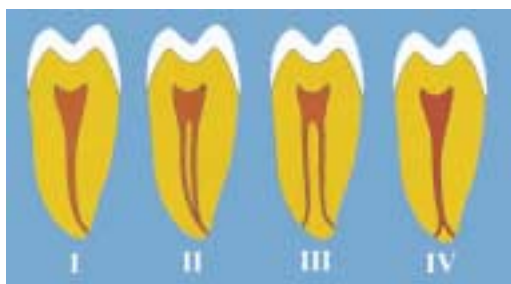

Fig 3 Typical canal configurations according to Weine<sup>3</sup>.

### ■ Analysis of canal confluency

A sample of 409 mandibular teeth was studied and the distribution of these teeth is shown in Table 1.

Table 1 Distribution of analysed mandibular teeth.

First molars	Second molars	Third molars	Total
231	156	22	409

The number of canals per mandibular tooth is summarised in Table 2. The presence of canal confluences in both mesial and distal roots is shown in Tables 3 and 4 respectively. The presence of confluency of all three root canals, even in the absence of C-shaped anatomy, was found in four mandibular second molars.

Canal confluency was present in more than 50% of the mesial roots of mandibular first molars and in 70% of the distal canals of mandibular first molars and mesial roots of mandibular second molars. The sample size of distal canals of mandibular second molars and

third molars was not sufficient to draw any conclusions.

From the analysis of these results, it can be concluded that canal confluency in mandibular molars are not infrequent. The data are in agreement with those reported by Al-Nazhan<sup>5</sup> and Sert et al<sup>6</sup>, that confluency occurs in the mesial root of the mandibular first molars in about half of the cases. Vertucci<sup>7</sup> found an even higher percentage, in approximately 65% of the roots. In the distal root of the mandibular first molars, the confluency of canals has been found in more than 70% of cases. This is in agreement with previous reports by other authors<sup>8,9</sup>; only Vertucci<sup>10</sup> found an incidence of approximately 50%. In the mesial root of mandibular second molars, the incidence observed in the present study was significantly higher compared with those reported in the literature; Sert et al<sup>6</sup> and Vertucci<sup>10</sup> found confluency in slightly more than 50% of cases. In the present study this configuration was found in almost three-quarters of the cases.

### ■ Clinical considerations

Different considerations should be made during the shaping of joint canals in mandibular molars, in particular with different canal types. The use of NiTi rotary files in root canals having the same foramen (Type II), requires meticulous precautions in order to avoid instrument fracture. In these cases, it is dangerous to enlarge the apical portion of the joint canal us-

Table 2 Numbers of root canals per tooth in mandibular molars.

	1 canal	2 canals	3 canals	4 canals	5 canals	C-shaped	Not recognised
First molars	0.8% (2/231)	0.8% (2/231)	53.7% (124/231)	43% (99/231)	0.4% (1/231)	0	1.3% (3/231)
Second molars	2.7% (4/156)	7% (11/156)	82.7% (129/156)	5% (8/156)	0	1.3% (2/156)	1.3% (2/156)
Third molars	4.6% (1/22)	18% (4/22)	72.8% (16/22)	4.6% (1/22)	0	0	0

Table 3 Presence of canal confluency in mesial roots.

	First molars	Second molars	Third molars
Presence	51.5% (103/200)	74.4% (87/117)	36% (5/14)
Absence	48.5% (97/200)	25.6% (30/117)	64% (9/14)

Table 4 Presence of canal confluency in distal roots.

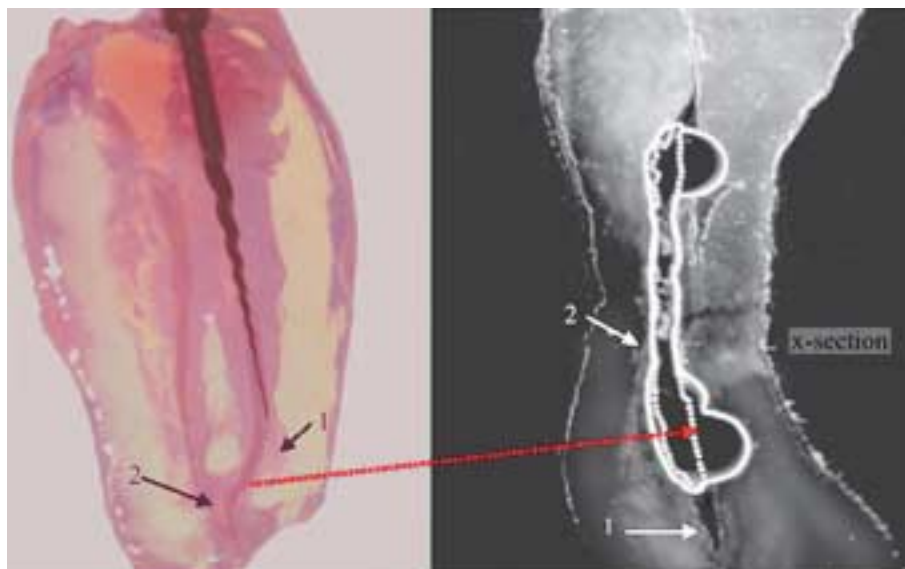
	First molars	Second molars	Third molars
Presence	72.7% (64/88)	50% (3/6)	0
Absence	27.3% (24/88)	50% (3/6)	1

ing rotary instruments, because this may cause instrument fracture when trying to achieve the full working length<sup>11</sup> (Fig 4).

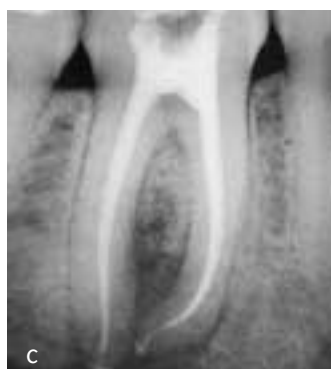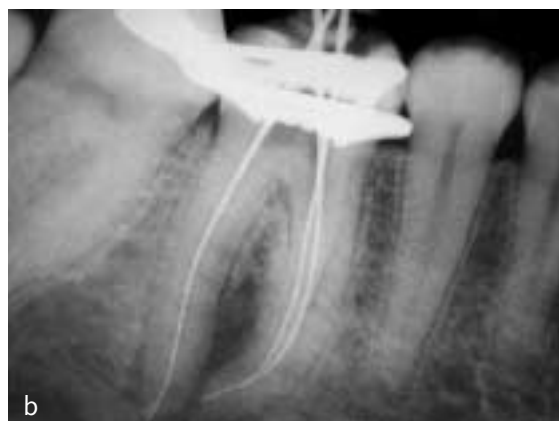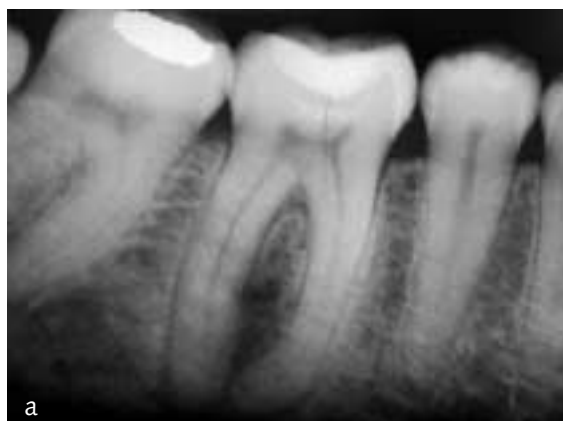When the rotary instrument reaches the canal confluence, the file can penetrate the joined part of the canal at a very acute angle (the less dangerous situation), or at a right angle (extremely dangerous)

(Fig 5). In the latter case, as soon as the instrument passes from the second canal to the joint canal, fracture may occur (Fig 6). For this reason, it is important to know in advance if and where two canals may communicate (Fig 7).

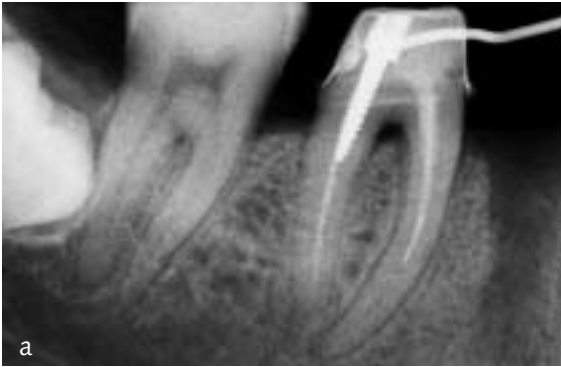

In order to elucidate joint root canals it is necessary to check, during the measurement of the work-



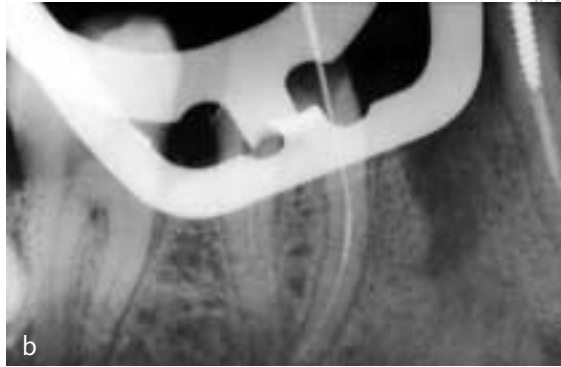
**Fig 4** In order to avoid fracture of rotary NiTi instruments, enlargement of the joint apical portion of the canals should be avoided.



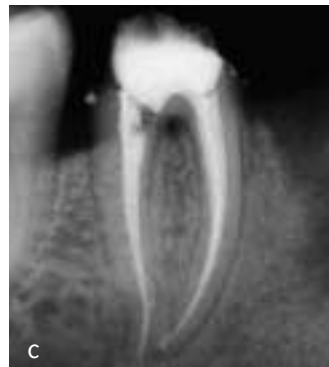**Figs 5a to 5c** Presence of acute confluency in apical region of a mandibular molar.



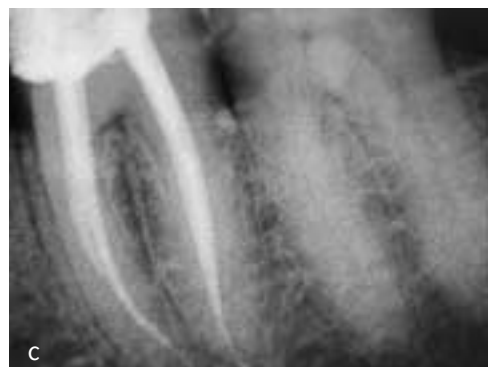
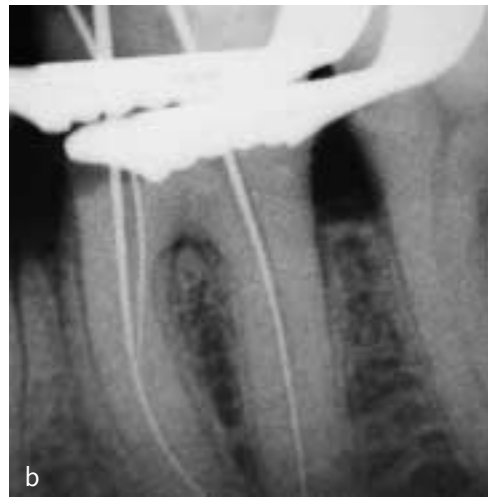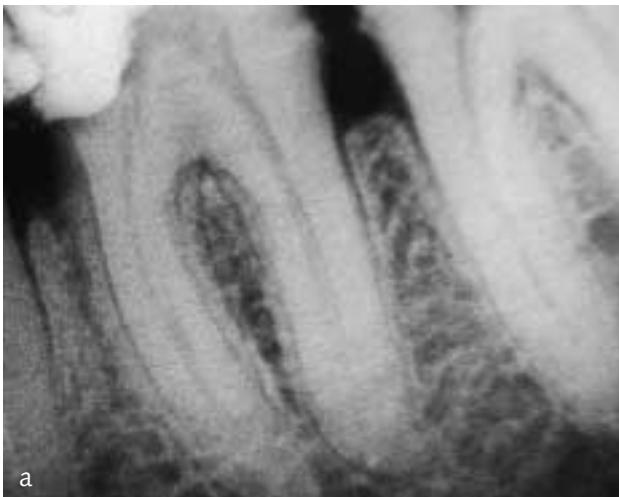**Fig 6a** Separation of a NiTi instrument in the mesial root of a mandibular molar.



**Fig 6b** The fractured instrument bypass.



**Fig 6c** Obturation of the root canal.



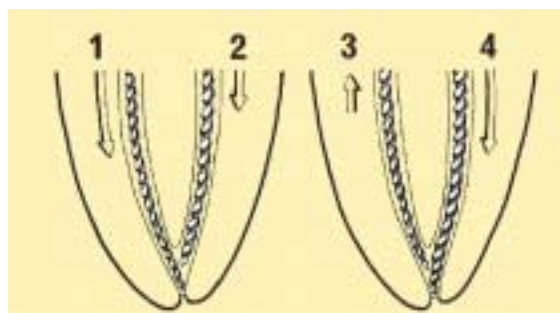
**Fig 7a to 7c** Presence of canal confluency in the coronal part (8 mm apically from the canal orifice) in a mandibular first molar.

ing length, whether the two root canal instruments inserted cannot reach the apex at the same time (Fig 8). In these cases:

1. Take an intra oral radiograph with two instruments inserted into the canals to confirm the presence of two separate canals and the precise point of confluency. Different types of instruments (e.g. reamer and K-file) should be used to radiographically distinguish the two instruments and thereby the two canals.
2. During shaping with NiTi rotary instruments, each canal should be prepared separately. In general, the main canal, which is longer, needs to be prepared to the apex and the second canal, which is shorter, needs to be shaped until the point of confluency.
3. In order to verify the exact point of confluency, a gutta-percha cone should be inserted into the first canal while a K-file is introduced into the second canal (Fig 9a). After the file has been withdrawn from the second canal, the gutta-percha cone extracted from the main canal must be examined for any imprints; a groove, a scratch or

depression left by the file confirms the presence and the level of confluency (Fig 9b). Thereafter, the shaping of the second canal should be performed, measuring its working length until the point of confluency.

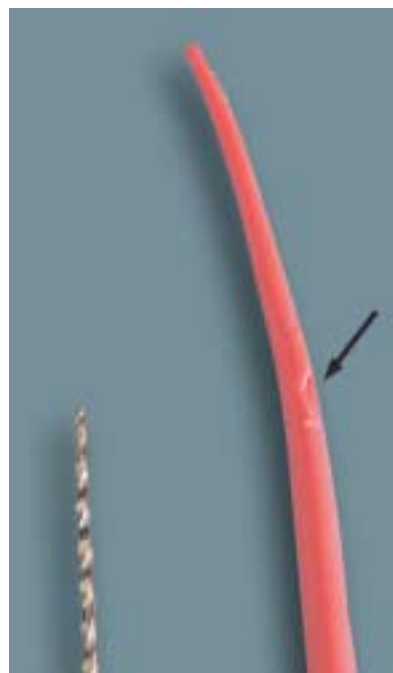4. During the root canal filling, the procedure is the same. Firstly, the main canal should be obturated and thereafter the second canal should be obturated to the point of confluency.




**Fig 8** In order to diagnose a canal confluency it is necessary to check whether during the determination of the working length, the two instruments can reach the apex at the same time.



**Fig 9a** In order to verify the exact point of confluency, a gutta-percha cone should be inserted into the first canal while a K-file is introduced into the second canal to mark the gutta-percha.



**Fig 9b** After the file is withdrawn from the second canal, the gutta-percha cone extracted from the main canal is examined for any imprints; a groove, a scratch or a depression left by the file confirms the presence and the site of confluency.



■ **Conclusions**

The confluency of root canals in mandibular molars is a not uncommon anatomic variation and should be considered as an important clinical factor during root canal treatment with regard to preservation of sound hard tissue. Moreover, thorough knowledge of the anatomy of mandibular molars can reduce the risk of instrument separation when using rotary NiTi instruments and thus ensures a successful treatment outcome.

■ **References**

1. Schilder H. Cleaning and shaping the root canals. *Dent Clin North Am* 1974;18:269-296.
2. Hess W. Anatomy of the root canals of the teeth of the permanent dentition. Part I. New York: William Wood & Co. 1925;1-35.
3. Castellucci A. *Endodonzia*. Prato: Edizioni Odontoiatriche Il Tridente, 1993.
4. Furri M. L'anatomia endodontica dei molari inferiori: studio clinico su 409 denti. *G It Endo* 2006;20:95-98.
5. Al-Nazhan S. Incidence of four canals in root-canal-treated mandibular first molars in a Saudi Arabian sub-population. *Int Endod J* 1999;32:49-52.
6. Sert S, Aslanalp V, Tanalp J. Investigation of the root canal configurations of mandibular permanent teeth in the Turkish population. *Int Endod J* 2004;37:494-499.
7. Vertucci FJ. Root canal morphology and its relationship to endodontic procedures. *Endodontic Topics* 2005;10:3-29.
8. Wasti F, Shearer AC, Wilson NHF. Root canal systems of the mandibular and maxillary first permanent molar teeth of South Asian Pakistanis. *Int Endod J* 2001;34:263-266.
9. Gulabivala K, Opananon A, Ng Y-L, Alawi A. Root and canal morphology of Thai mandibular molars. *Int Endod J* 2002;35:58-62.
10. Vertucci FJ. Root canal anatomy of the human permanent teeth. *Oral Surg Oral Med Oral Pathol* 1984;58:589-599.
11. Bonaccorso A, Tripi TR. *Il nichel-titanio in endodonzia*. Bologna: Edizioni Martina, 2006.