

Expert Consensus on Procedures and Operations of Navigation-guided Needle Biopsy Techniques for Skull Base Tumours

Jing WANG¹, Chuan Bin GUO¹, Jian Hua ZHU¹, Yu Xing GUO¹, Guang Yan YU¹, Yang HE¹, Wen Bo ZHANG¹, Yi ZHANG¹, Xin PENG¹, Xiao Jing LIU¹, Yan Pu LIU², Xiao Ming GU³, Wei Dong TIAN⁴, Li LU⁵, Zu Bing LI⁶, Shi Lei ZHANG⁷, Guo Fang SHEN⁷, Sheng De BAO⁸, Tie Jun LI¹, Kai Yuan FU¹; Society of Oral and Maxillofacial Surgery, Chinese Stomatological Association

Skull base surgery is an interdisciplinary subject. The anatomical structures in the skull base related to oral and maxillofacial surgery include the parapharyngeal space, the pterygopalatine fossa and the infratemporal space. This operative area is one of the most challenging surgical areas in oral and maxillofacial surgery due to its deep site, complex anatomy and high risk. Obtaining pathological information of the tumour preoperatively may help surgeons optimise their treatment plan. Needle biopsy is one of the major minimally invasive techniques that allows preoperative pathological results to be obtained. The navigation technology, which is developing rapidly nowadays, provides a reliable assistance for deep tissue biopsy surgery. Experts from the Society of Oral and Maxillofacial Surgery, Chinese Stomatological Association formulated an expert consensus on the procedures and operations of navigation-guided needle biopsy techniques for skull base tumours, so as to standardise and promote the application and operation of navigation-guided needle biopsy for skull base tumours.

Key words: skull base tumour, biopsy, surgical navigation, expert consensus
Chin J Dent Res 2020;23(1):27–32; doi: 10.3290/j.cjdr.a44333

- 1 Department of Oral and Maxillofacial Surgery, Peking University School and Hospital of Stomatology, Beijing, P.R. China.
- 2 Department of Oral and Maxillofacial Surgery, School of Stomatology, Air Force Military Medical University, Xi'an, P.R. China.
- 3 Department of Oral & Maxillofacial Surgery, The Third Medical Centre of Chinese PLA General Hospital, Beijing, P.R. China.
- 4 Department of Oral & Maxillofacial Surgery, West China Stomatology Hospital, Sichuan University, Chengdu, P.R. China.
- 5 Department of Oromaxillofacial-Head and Neck Surgery, School of Stomatology, China Medical University, Shenyang, P.R. China.
- 6 Department of Oral and Maxillofacial Surgery, School of Stomatology, Wuhan University, Wuhan, P.R. China.
- 7 Department of Oral and Craniomaxillofacial Surgery, Shanghai Ninth People's Hospital, Shanghai Jiao Tong University School of Medicine, Shanghai, P.R. China.
- 8 Department of Stomatology, Peking University First Hospital, Beijing, P.R. China.

Corresponding author: Prof. Chuan Bin GUO, Department of Oral and Maxillofacial Surgery, Peking University School and Hospital of Stomatology, 22# Zhongguancun South Avenue, Haidian District, Beijing 100081, P.R. China. Tel: 86-10-82195295; Fax: 86-10-62173402. Email: guodazuo@vip.sina.com

Skull base surgery is an interdisciplinary subject involving neurosurgery, maxillofacial surgery, otorhinolaryngology, ophthalmology, plastic surgery, etc. The anatomical structures in the skull base related to oral and maxillofacial surgery include the parapharyngeal space, the pterygopalatine fossa and the infratemporal space. This area is deep, its anatomical structures are complex (adjacent to important vessels and cranial nerves), and there are mandibular ascending branches, parotid glands and facial nerves on the lateral side, which cause a great difficulty in exposing this area. The skull base, as ‘the

This article was first published in *Zhonghua Kou Qiang Yi Xue Za Zhi* (Chinese Journal of Stomatology) 2019;54(4):228–233 (in Chinese), and this is the second publication using the same contents as the original publication.

The article was funded by the Health Care for Capital Citizen Incubating Project of the Beijing Municipal Science & Technology Commission (Z161100000116053).

dividing wall' separating the intracranial and extracranial parts, contains many important anatomical structures, which makes the surgical risk high. This therefore comprises one of the most challenging surgical areas. For skull base lesions, whether for preoperative biopsy or surgical treatment, there is a greater degree of difficulty and risk¹.

Obtaining pathological information of the tumour preoperatively can help surgeons optimise the treatment plan. Needle biopsy is one of the main, minimally invasive techniques to obtain pathological results. This technique has been widely used in the diagnosis of breast, lung and liver tumours. It has been proven to have high diagnostic specificity and sensitivity, high safety, low risk and a low complication rate²⁻⁴. It is also widely used in the diagnosis of head and neck tumours⁵⁻⁷. Rapidly developing navigation technology provides reliable assistance for deep tissue biopsy surgery^{8,9}. The application of stereotactic or image localisation in neurosurgical brain lesion biopsies is becoming more common^{10,11}.

Experts from the Society of Oral and Maxillofacial Surgery, Chinese Stomatological Association formulated an expert consensus on 'Procedures and operations of navigation-guided needle biopsy techniques for skull base tumours', to standardise the application method of navigation-guided needle biopsy of skull base tumours and to promote its popularisation and application.

Indications and contraindications

Indications

The indications for this technique mainly refer to indications from the skull base tumour needle biopsy itself:

- Skull base and lateral facial deep tumours requiring pathological diagnosis to guide the therapeutic plan;
- Cases when it is difficult to perform incisional biopsy;
- The navigation positioning is more suitable for the following situations: the tumour space occupation leads to displacement of the internal carotid artery and veins; the tumours are small and difficult to locate; the tumour imaging shows uneven texture, indicating the need to select intratumoural sites to collect a specimen.

Contraindications

- The whole tumour is cystic;
- Clinical and imaging diagnosis suggests benign polymorphic adenomas.

Image requirements for navigation surgery

To better display the positional relationship between the important vessels and tumours in the skull base area, enhanced spiral computed tomography (CT) is recommended with an intravenous iodine contrasting agent. The scope of the CT scanning should include all facial and cervical tissues from the calvarium to the clavicle to avoid missing intracranial and external tumour boundaries, and to avoid the loss of cervical metastatic lymph nodes. The thin-layer CT scan helps with better identification of the tumour boundaries and improves the navigation accuracy. The minimum requirements for the CT layer thickness are different in each navigation system; therefore, surgeons should refer to the operating instructions for the various navigation systems. Scanned images may be stored in DICOM format. If a point-to-point registration method is used, different registration markers can be selected such as wearing a bite plate containing registration markers, skin sticking markers, or bone screw markers when obtaining an image. The number of registration points should generally be no less than four, and should be widely distributed, covering the central area of the navigation; in case of the use of a skin-sticking marker, this must be located in the regions where the skin is difficult to move and deform such as the forehead, cheekbone and mastoid. Magnetic resonance imaging (MRI) can be used to gain a clearer image of the tumour and to aid in the diagnosis and navigation of preoperative designs⁹.

For those patients who cannot tolerate enhanced CT, the navigation design can be combined with a plain CT scan and MRI.

Preoperative design

The obtained DICOM data should be imported into the digital surgical planning software

When using point-to-point registration, it is necessary to identify the registration point in advance. Threshold segmentation should be used to rebuild the skull.

Segmentation, registration and fusion

The internal carotid artery, the external carotid artery, the common carotid artery and the internal jugular vein must be segmented according to threshold and region growth methods. In the design software, a segmentation tool is used to outline the scope of the tumour, and the tumour must be subjected to a 3D reconstruction in order

to obtain 3D visualisation of the tumour location (Fig 1). If two different images are obtained, registration and fusion can be performed to acquire a better image display for the tumour segmentation and 3D reconstruction.

Diameter selection of the biopsy needle

Needle biopsy is generally divided into fine needle biopsy and core needle biopsy. Fine needle biopsy has the advantage of being less traumatic. However, the number of aspirate specimens is too small, and is generally used for cytological diagnosis. It is difficult to perform the histological diagnosis by paraffin section and immunohistochemical stain via the above-mentioned technique, and it is not possible to assess the extent of tumour differentiation is not possible to be assessed¹². Core needle biopsy provides a pathological diagnosis with higher sensitivity and specificity¹³, enables the extent of tumour differentiation to be assessed, and provides prognostic information to inform clinical treatment decisions¹⁴.

Navigational needle biopsy of skull base tumours usually uses core needle biopsy. Biopsy needles can be paired with a manual or automatic biopsy device used for core needle biopsy. The diameter of the puncture needle used varies from 18 G to 11 G (about 1.2 to 2.6 mm). The diameter of the biopsy needle should be appropriate according to the size and depth of the tumour. The biopsy needle must not be too thin, so that an adequate amount of tissues can be harvested for diagnosis, and needle bending should be avoided during the puncture process. Needle bending can cause an excessive deviation of the needle tip from the navigation position to the actual position during the puncture process. If the needle trajectory is long, a stiff needle should be used with a relatively large diameter to reduce needle bending in the soft tissue. The issue of needle passage causing tumour cell implantation in the core needle biopsy has been more fully studied in breast cancer. A systematic review showed that the detection of tumour cells in the needle passage is common, reaching 2% to 63%; however, the recurrence of implants, lymph node metastasis and systemic metastasis attributed to needle passage is rare, and is difficult to distinguish from those caused by the tumour and surgical treatment itself. Furthermore, long-term follow-up patients showed no difference in prognosis from patients who had not undergone biopsy². Although there are fewer studies of core needle biopsy of head and neck tumours, the conclusion is similar to the above¹⁵. The high detection rate of tumour cells due to needle passage means that, theoretically, the risk of local recurrence and metastasis cannot be ruled out. Besides, the diameter of the needle

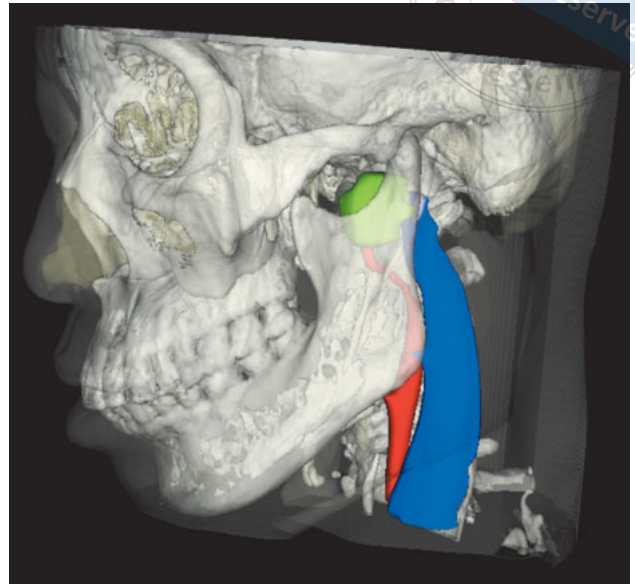


Fig 1 Segmentation and display of tumours (green), arteries (red) and veins (blue).

may also be one of the risk factors. Currently, there is still no reliable evidence regarding whether the risk could be reduced by shortening the time delay between the needle biopsy and 1) radical surgery; 2) radical radiotherapy; 3) chemotherapy; and 4) needle resection².

Virtual design of the needle path

In the multi-view navigation design software, with the axial position, coronal position, sagittal position and 3D data, the virtual design of the needle path can be constructed. The entry point is placed on the skin, and the puncture target is placed at the junction of the tumour and the normal tissue. The ejection path is located on the extension cord of the needle path^{8,16} (Fig 2).

Note that different needle paths and ejection distances are selected based on the location and size of the tumour. It is recommended to design multiple needle paths and obtain specimens from different locations of the tumour at different angles.

Commonly used needle paths are the sigmoid notch approach and the retromandibular approach¹⁶. The needle path needs to be kept away from bone structures. One of the complications of needle biopsy is that the biopsy needle enters blood vessels, causing bleeding and haematoma¹⁷. In the virtual design, the needle path and the ejection path must be kept away from the internal carotid artery, the internal jugular vein and the external carotid artery as well as any other well-known blood vessels visible on the image. After the design,

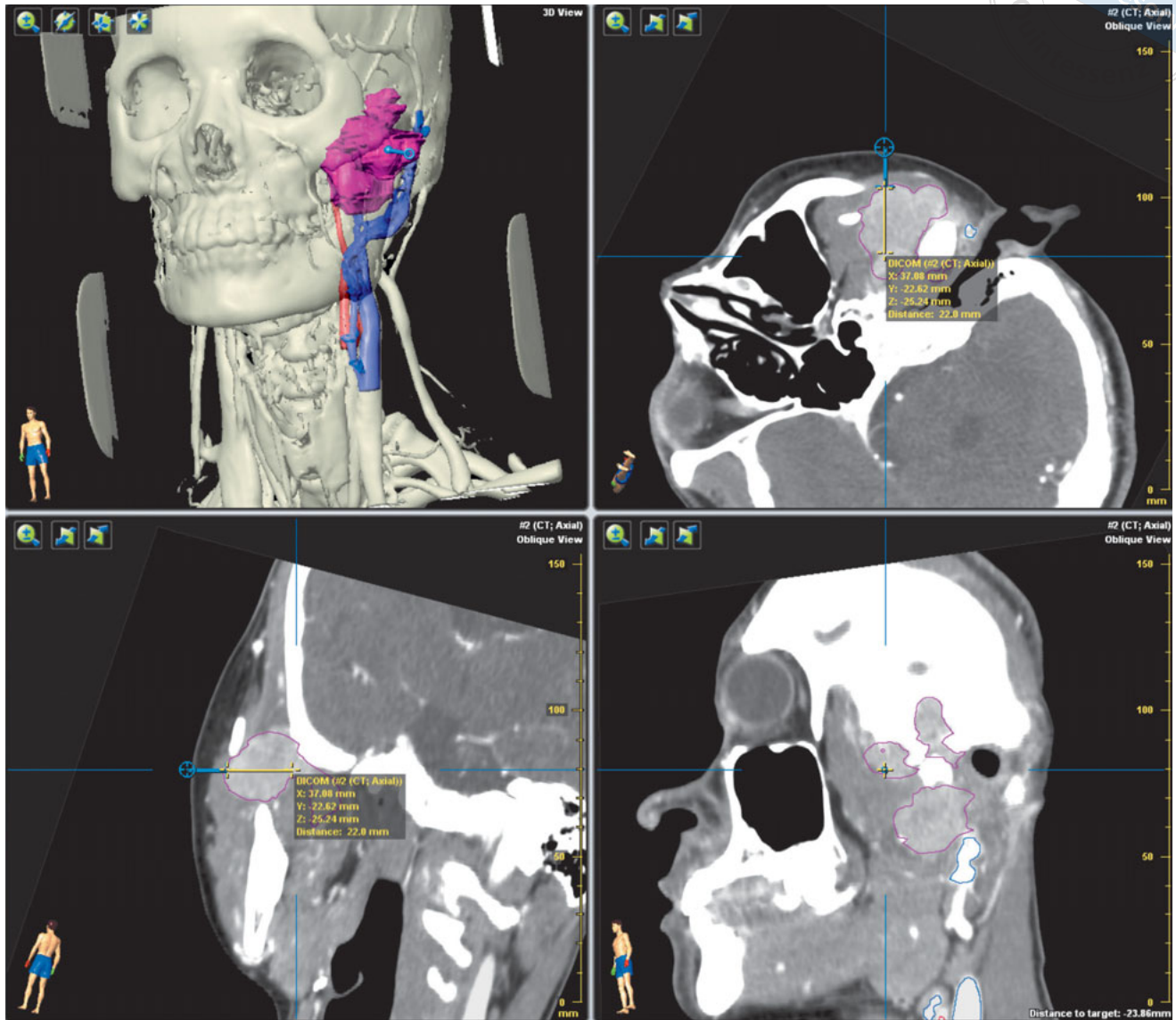



Fig 2 Design of the needle path (blue dotted line shows the puncture path, yellow line shows the ejection distance).

multiple views should be used to carefully check whether the needle path avoids the bone barrier and how far it will be from the blood vessels. An intraoral needle path should be avoided; however, if an intraoral approach must be used, the mouth should be thoroughly disinfected before surgery.

The data assigned as a specific format for intraoperative navigation should be exported.

Navigation installation and registration

Installation of the headband reference unit

A needle biopsy is usually performed in a short period of time and can be navigated using a non-invasive headband reference unit. In the operation, the headband should be fixed to the forehead of the patient, and then the reference unit and the reflecting light balls can be connected to complete the installation.

The reference unit is simple to install; the main point is to ensure that the forehead skin is dry and that the headband does not move during surgery. It is recommended

to use a headscarf to facilitate fixation. The reference unit should be kept stable during the puncture process.

Patient registration

Different navigation systems use different registration methods. Surgeons should refer to the instructions of the specific navigation system for its standard operation. The registration methods commonly used in optical navigation systems include facial scan registration and point-to-point registration.

Puncture needle registration

In the needle biopsy, the biopsy device needs to be registered by a third-party device so that the puncturing process can be visually navigated throughout. The third-party device registration methods vary in different navigation systems and should be operated according to the navigation system specifications.

Needle biopsy procedure

Preparation

Patients can be operated on under local anaesthesia or under intravenous sedation. The entry point is localised by the navigation probe. The needle path should be treated with a local anaesthetic (2% lidocaine), and a small incision should be made using a sharp scalpel.

Surgical procedure

The puncture needle should be inserted in the boundary between the tumour and the normal tissue according to the design trajectory. Specimens should be immediately frozen for use in later pathological examinations. If no tumour tissue is found, the surgeon should try to obtain it by adjusting the angle on the needle path.

Different angles and depths may be used to obtain material tissues in multiple locations within the tumour tissue, usually no less than three times, to improve the accuracy of the pathological diagnosis.

Intraoperative frozen pathology

It is recommended to use frozen tissue for the intraoperative pathological study to help determine whether or not the tumour tissue was collected. If the frozen histopathology fails to give a positive result, the needle path can be changed to obtain tissues again.

Finishing the surgical procedure

After the biopsy needle is withdrawn, the wound should not be actively bleeding. In any case, the wound should be covered with a sterile dressing and a pressure dressing should be applied.

Evaluation of the effectiveness of the needle biopsy

The quality of specimens harvested is one of the evaluation indicators. Specimens should be collected from soft tissue and not be less than 1 cm in length. The key indices to assess the effectiveness of a biopsy are whether it can produce a pathological diagnosis of the specimen, and whether there is consistency in the pathological results between biopsy specimen and surgical specimen.

Risks and complications

The risks and complications of navigational biopsy of skull base tumours are mainly the same as those for needle biopsy, including haemorrhage, haematoma, nerve injury, infection and delayed wound healing^{10,11,17}. Navigation is only an auxiliary tool, which does not introduce extra complications and risks. Puncturing the needle too deeply into the brain should be avoided, because the risk of intracranial haemorrhage is high and there is a certain mortality rate¹⁰.

References

1. Guo YX, Guo CB, Yu GY, et al. Analysis of factors affecting the prognosis of malignant tumors in the parapharyngeal space. *Zhonghua Shen Jing Wai Ke Za Zhi* (Chinese Journal of Neurosurgery) 2012;28:775–779. [in Chinese]
2. Liebens F, Carly B, Cusumano P, et al. Breast cancer seeding associated with core needle biopsies: a systematic review. *Maturitas* 2009;62:113–123.
3. Silva MA, Hegab B, Hyde C, Guo B, Buckels JA, Mirza DF. Needle track seeding following biopsy of liver lesions in the diagnosis of hepatocellular cancer: a systematic review and meta-analysis. *Gut* 2008;57:1592–1596.
4. Inoue M, Honda O, Tomiyama N, et al. Risk of pleural recurrence after computed tomographic-guided percutaneous needle biopsy in stage I lung cancer patients. *Ann Thorac Surg* 2011;91:1066–1071.
5. Zhang J, Zheng, Liu SM, et al. Core needle biopsy in the diagnosis of oral and maxillofacial tumors. *Beijing Da Xue Xue Bao Yi Xue Ban* (Journal of Peking University. Health Sciences) 2012;44:801–803. [in Chinese]
6. Orlandi D, Sconfienza LM, Lacelli F, et al. Ultrasound-guided core-needle biopsy of extra-ocular orbital lesions. *Eur Radiol* 2013;23:1919–1924.

7. Farrag TY, Lin FR, Koch WM, et al. The role of pre-operative CT-guided FNAB for parapharyngeal space tumors. *Otolaryngol Head Neck Surg* 2007;136:411–414.
8. Grasso RF, Luppi G, Cazzato RL, et al. Percutaneous computed tomography-guided lung biopsies: preliminary results using an augmented reality navigation system. *Tumori* 2012;98:775–782.
9. Mouraviev V, Verma S, Kalyanaraman B, et al. The feasibility of multiparametric magnetic resonance imaging for targeted biopsy using novel navigation systems to detect early stage prostate cancer: the preliminary experience. *J Endourol* 2013;27:820–825.
10. Gilkes CE, Love S, Hardie RJ, Edwards RJ, Scolding NJ, Rice CM. Brain biopsy in benign neurological disease. *J Neurol* 2012;259:995–1000.
11. Malone H, Yang J, Hershman DL, Wright JD, Bruce JN, Neugut AI. Complications following stereotactic needle biopsy of intracranial tumors. *World Neurosurg* 2015;84:1084–1089.
12. Sauer T, Myrvold K, Lomo J, Anderssen KY, Skaane P. Fine-needle aspiration cytology in nonpalpable mammographic abnormalities in breast cancer screening: results from the breast cancer screening programme in Oslo 1996–2001. *Breast* 2003;12:314–319.
13. Britton PD. Fine needle aspiration or core biopsy. *The Breast* 1999;8:1–4.
14. Kaufmann M, Hortobagyi GN, Goldhirsch A, et al. Recommendations from an international expert panel on the use of neoadjuvant (primary) systemic treatment of operable breast cancer: an update. *J Clin Oncol* 2006;24:1940–1949.
15. Shah KS, Ethunandan M. Tumour seeding after fine-needle aspiration and core biopsy of the head and neck – a systematic review. *Br J Oral Maxillofac Surg* 2016;54:260–265.
16. Guo CB, Guo Yu Xing. Surgical navigation technology guided skull base tumor needle biopsy. *Zhongguo Shi Yong Kou Qiang Ke Za Zhi (Chinese Journal of Practical Stomatology)* 2014;7:321–324. [in Chinese]
17. Bai L, Yang T, Tang Y, et al. Clinical analysis and prevention of complications associated with ultrasound-guided percutaneous thick needle biopsy. *Nan Fang Yi Ke Da Xue Xue Bao (Journal of Southern Medical University)* 2009;29:1055–1059. [in Chinese]