

Nodular Fasciitis in the Orofacial Region: A Report of Three Cases

Shu Xin REN¹, Yi ZHANG¹

Nodular fasciitis is a benign fibroblastic proliferate lesion that is thought to be a response of tissue to injury. It usually presents as a rapidly growing subcutaneous mass. Upper extremities are most commonly affected, followed by the head and neck region. The clinical behaviour and histological presentation mimic those of malignant tumours, thus the lesion is easily misdiagnosed. The authors report here three cases of orofacial nodular fasciitis and review the literature focused on the diagnosis of the disease. Patient one had a history of trauma. The physical examination, radiographic features and findings in surgery were suggestive of a malignant tumour. The final diagnosis of nodular fasciitis was made through the immunohistochemical pathology. The other two patients had no history of trauma, but presented typical clinical and pathological features of nodular fasciitis. It is essential that dentists are aware of the distinctions between nodular fasciitis and malignant tumours in order to limit overtreatment and treatment-related morbidity.

Key words: nodular fasciitis, orofacial region

Nodular fasciitis is a rare benign fibroblastic proliferate lesion that grows by extending from the muscular fascia into the subcutaneous tissue and, less frequently, into the underlying muscle. A history of trauma has been suggested as an inciting factor, although the pathogenesis is still unknown. It most commonly presents as a painless, rapidly growing mass in upper and lower extremities. The next most frequent location is the head and neck region.

There are numerous reports of nodular fasciitis in the medical literature because the upper extremities and trunk are commonly affected. There are also a few reports of nodular fasciitis in the orofacial region; however, dentists might not recognise the clinical characteristics of orofacial nodular fasciitis. Misdiagnosis of

nodular fasciitis is not uncommon due to its similarity to a malignant tumour in both clinical behaviour and histological presentation.

In this study, we report three cases with orofacial nodular fasciitis treated in Peking University Hospital of Stomatology and review the literature focused on the diagnosis of the disease. We believe that a history of trauma, typical clinical features and pathological characteristics are essential for a differential diagnosis.

Case reports

Case one

A 26-year-old male presented with an asymptomatic mass on the right side of his face which had been developing for 3 months. Six months previously, the patient had been struck on the right side of his face by a basketball. One month later, he began to complain about pain and clicking in the right jaw joint, but did not receive any medical treatment. Physical examination revealed a well circumscribed, firm, immobile mass anterior to the right ear. The mandible could move freely without

¹ Department of Oral and Maxillofacial Surgery, Peking University School and Hospital of Stomatology, Beijing, P.R. China

Corresponding author: Dr Yi ZHANG, Department of Oral and Maxillofacial Surgery, Peking University School and Hospital of Stomatology, #22 Zhongguansun Nandajie, Haidian District, Beijing 100081, P.R. China. Tel: 86-10-82195158; Fax: 86-10-62173402; E-mail: zhangyi2000@263.net

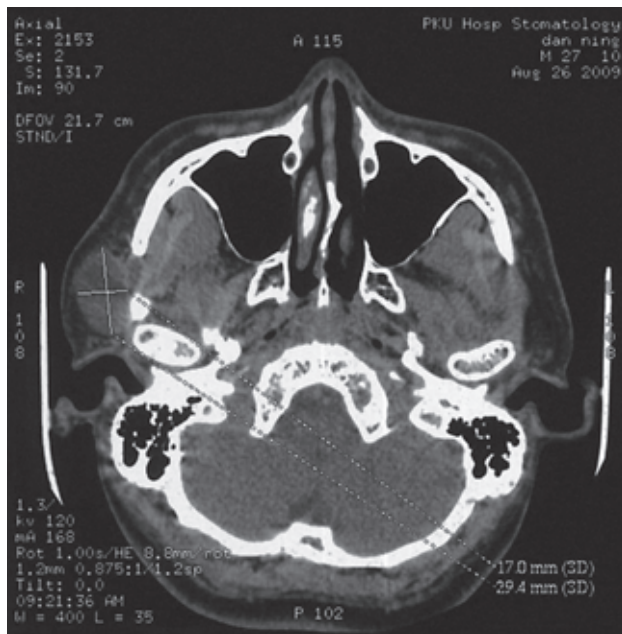


Fig 1 CT scans showed a well-defined soft tissue mass lying superficial to the right parotid gland.

pain or limitation in the range of movement. Abnormal facial sensation was not detected. No enlarged lymph nodes were found at the site or in the neck. Computed tomographic (CT) scans showed a $1.7 \times 2.9 \times 2$ cm well-defined soft tissue mass lying superficial to the right parotid gland (Fig 1).

The patient underwent a superficial parotidectomy and mass excision. The mass was intraoperatively observed as if growing from the parotid gland. Two zygomatic branches of the facial nerve were found to be thinner than normal, but could still be identified. One branch coursed through the mass and had to be sacrificed, the other ran underneath the capsule of the mass and was preserved (Fig 2).

During surgery, the frozen section revealed a 'spindle cell tumour, not ruling out low-grade atypical features', whereas the postoperative pathological examination demonstrated a well-delineated solid tumour surrounded by a fibrous pseudocapsule. Numerous spindle-shaped fibroblasts were randomly arranged in an interstitial ground substance, which was predominantly collagenous with myxoid areas. An inflammatory infiltrate with few scattered red blood cells was also visible (Fig 3).

Immunohistochemical staining showed the lesional cells stained for smooth muscle actin (SMA) (Fig 4), but not for human soluble protein 100 (S100) and creatine kinase (data not shown). Accordingly, the diagnosis of nodular fasciitis was finally made. Postoperatively, the patient experienced short-term slight facial paralysis, but recovered full facial expression function within 1 month. The patient was followed up regularly every 2 to 3 months over the following year and no recurrence of the lesion was found.

Case two

A 14-year-old girl presented with a gradually enlarging painless mass in the left preauricular region over 3 months. There was no history of trauma in the area. The physical examination revealed a hard and immovable mass. A CT scan showed a well-defined soft-tissue mass lying on the superficial surface of the left zygomatic arch. The mass was approximately 8 mm in size. Fine-needle aspiration cytology showed abundant adipocytes.

During surgery, the mass was found immediately adherent to the periosteum of the left zygomatic arch. Microscopically, the mass was heterogeneous with myxoid hypocellular cystic areas alternating with spindle-shaped fibroblastic cells arranged in bundles. The nuclei of fibroblasts were large, and nucleoli were often prominent. Mitoses were frequent and appeared normal (Fig 5). Immunohistochemical testing using antisera to SMA was positive in lesional cells. However, immunostaining for S100, desmin and anaplastic lymphoma kinase was negative. The patient was observed for 1 year postoperatively without evidence of recurrence.

Case three

The patient was an 11-year-old boy. He had found a painless mass in the left cheek 1 year previously which had enlarged in the 2 months prior to examination. There was no history of trauma. The physical examination revealed a subcutaneous mass approximately 1 cm in diameter in the region of the left cheek. It was found to be hard, poor circumscribed and immediately adherent to the skin. Under general anaesthesia, a complete excisional biopsy was performed. Intraoperative examination indicated that the mass had infiltrated the subcutaneous tissues. The histopathology revealed a proliferation of plump cells exhibiting a storiform pattern in a myxoid stroma. The nuclei were large, and nucleoli were often prominent. No recurrence was observed during the 1-year follow-up period.

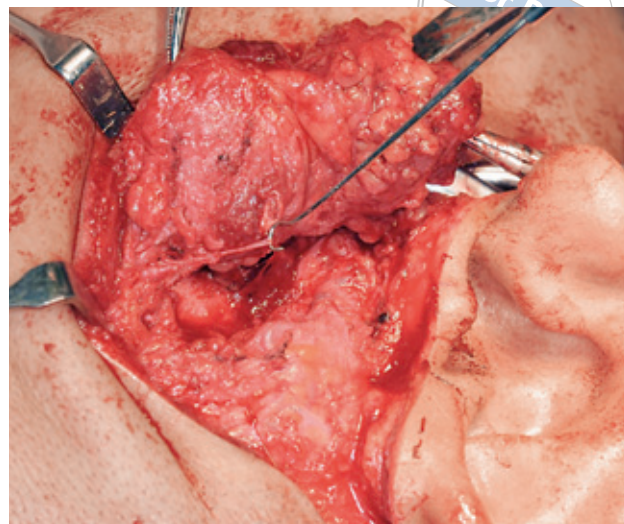
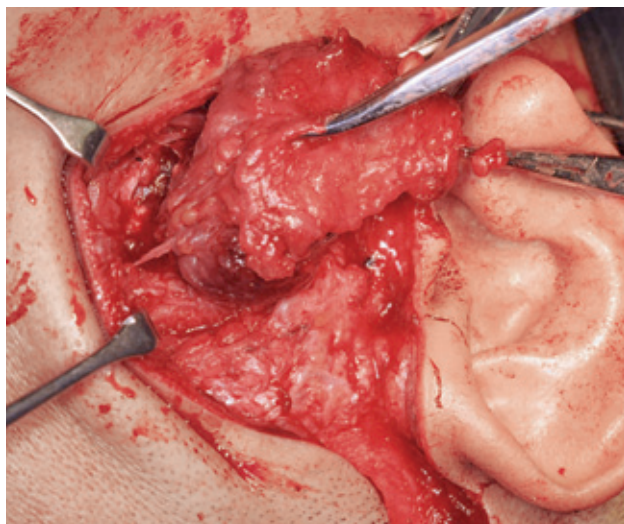


Fig 2 a) One zygomatic branch of the facial nerve coursed through the mass. b) The other zygomatic branch ran underneath the capsule of the mass.

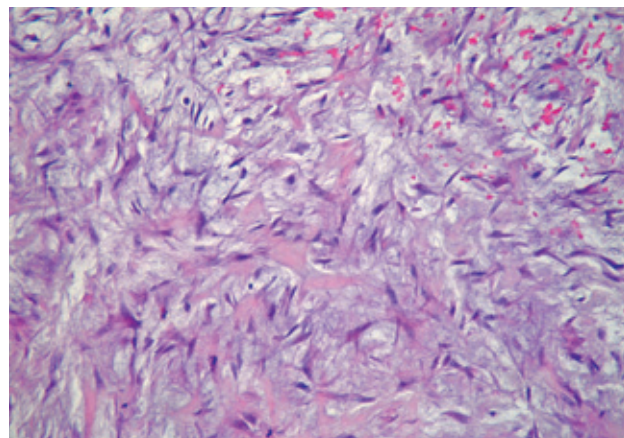
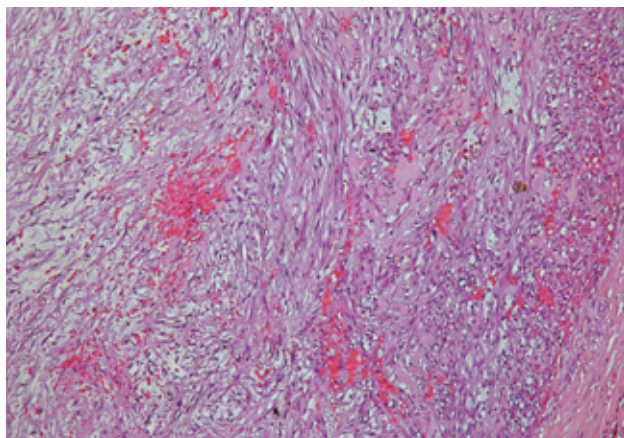


Fig 3 a) A well-delineated, solid tumour surrounded by a fibrous pseudocapsule (haematoxylin eosin (H&E) stain; original magnification $\times 10$). b) Higher magnification shows sheets of spindle cells in a myxoid stroma. Vascular channels with extravasated erythrocytes were also present (H&E stain; original magnification $\times 40$).

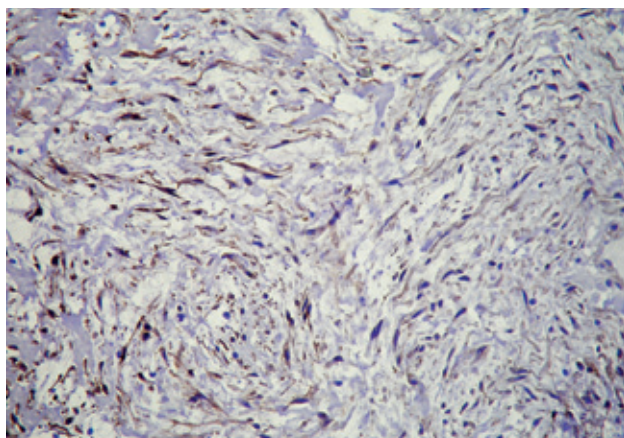


Fig 4 Immunohistochemical staining of smooth muscle actin (SMA). The spindle cells displayed positive staining with SMA $\times 40$.

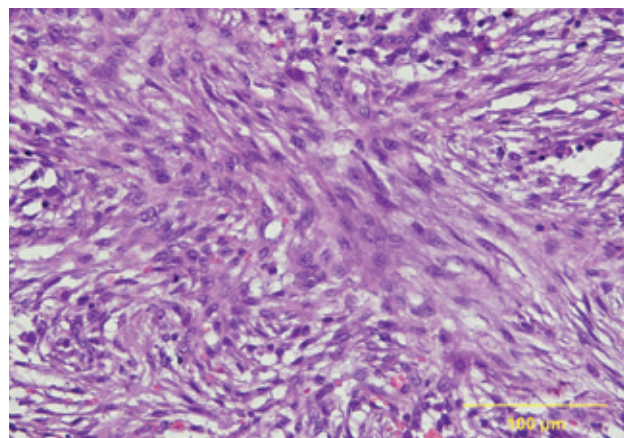


Fig 5 Myxoid, hypocellular cystic areas alternating with spindle-shaped fibroblastic cells arranged in bundles (H&E Stain; original magnification $\times 40$).

Table 1 Distribution of nodular fasciitis in the orofacial region^{5-17,19}

Site	No. of cases
Skin of face	41
Zygomatic arch	9
Posterior mandible	20
Anterior mandible	4
Face, area not specified	8
Parotid	17
Parotid sheath	10
Parenchyma involved	7
Oral mucosa	14
Buccal mucosa	8
Labial mucosa	3
Other	3
Neck	9

Discussion

Nodular fasciitis, first reported in 1955 by Konwaler¹, is a benign and probably reactive fibroblastic growth extending from the superficial fascia into the subcutaneous tissue. It is also referred to as pseudosarcomatous fasciitis, proliferative fasciitis, subcutaneous fibromatosis and infiltrative fasciitis². Nodular fasciitis occurs in all age groups, although most commonly in the third and fourth decades of life. There is no predilection for sex or race. Nodular fasciitis affects almost any anatomic location except the viscera. Nearly half of lesions were found to occur in the upper extremity, with 7% to 20% found in the head and neck³.

The aetiology of nodular fasciitis is uncertain. Trauma is often cited as a possible aetiology³, as was the situation case one, but a specific history of trauma is absent in most cases. Recently, clonal chromosomal abnormalities have been reported in some cases⁴, which indicates that nodular fasciitis might be a benign neoplasm and not a reactive lesion. By contrast, there was also a report of biopsy-proven nodular fasciitis being completely absorbed after intralesional injection of corticosteroid, which suggests an inflammatory aetiology⁵.

Nodular fasciitis in the orofacial region occurs in every age group, but rarely in children. The highest incidence is found in the third, fourth and fifth decades of life⁶. In the orofacial region, most of the lesions are located in the subcutaneous tissues immediately overlying a bony prominence – either the zygomatic arch, the posterior mandible or the anterior mandible⁶⁻¹⁷. Lesions in the parotid sheath and parenchyma are occasionally reported. The involvement of oral mucosa is exceptional, mostly found in the buccal mucosa, labial mucosa and tongue¹⁸. The distribution of nodular fasciitis in the orofacial region is shown in Table 1.

The clinical features of lesions in the orofacial region are similar to those of lesions in other regions. Patients typically present with a solitary and fast growing mass which has been present for a few weeks. Less frequently, compression of the peripheral nerve could cause numbness, paraesthesia and shooting pain, therefore malignancy may be suspected. The typical lesions are nodular, firm, painless and about 2 cm in size, although larger lesions have been reported. Lesions with an ulcerated surface and bone invasion are occasionally reported in the oral cavity¹⁹.

Radiographic findings generally show a benign nature, with a relatively well-defined mass in a superficial location, and with moderate to strong enhancement on CT or magnetic resonance imaging. Deep-seated lesions, however, tend to be large and ill-defined. They can invade and destroy the adjacent structures, including the bone; in one case, a lesion embedded deep in the temporalis muscle caused destruction to the bony orbit and skull¹⁵. In radiographic images, these aggressive natures mimic malignant tumours, which dentists should pay attention to.

Fine-needle aspiration cytology (FNAC) of nodular fasciitis in the orofacial region has been described in a few reports^{7,12}. The typical cytology is that of a cellular smear and is composed of predominantly spindle cells in a wide variety of sizes. The nuclei are round to oval and there is a moderate amount of delicate cytoplasm. Stanley et al believed that a diagnosis of nodular fasciitis based on combined clinical and FNAC findings was accurate²⁰. But some parotid lesions initially diagnosed by FNAC as pleomorphic adenomas were subsequently found to be nodular fasciitis¹².

Although FNAC is regarded as a reliable diagnostic tool in the assessment of salivary gland neoplasms, diagnostic pitfalls exist in differentiating between nodular fasciitis and pleomorphic adenoma. Microscopically, the non-encapsulated lesion has well circumscribed margins and could infiltrate surrounding tissue. The lesions are composed of numerous large pleomorphic

fibroblasts arranged in bundles and a vague storiform pattern. A mucoid intersitial ground substance is generally loose and rich. A mild to moderate infiltrate of chronic inflammatory cells and extravasated red blood cells are present. Mitoses are frequent and appear normal. Immunohistochemically, nodular fasciitis is positive to vimentin (a fibroblast marker), actin (a smooth muscle marker) and histiocyte marker. To establish a differential diagnosis with other myxoid tumours, it should be noted that nodular fasciitis cells are positive to muscle-specific actin and SMA.

The differential diagnosis of nodular fasciitis in the maxillofacial region should consider benign or malignant head lesions. Clinical and radiographic findings might lead to equivocal diagnoses. We suspected case one to be a malignant tumour before and during the surgery, due to the rapid growth of the mass, the involvement of the facial nerve and the findings of the frozen section. The final diagnosis was established by the typical histological features and immunohistochemical findings.

Excisional biopsy is the standard treatment for nodular fasciitis and recurrence is reported to be exceedingly rare³. Involvement of adjacent nerves in nodular fasciitis was rarely reported. Facial nerve preservation in case one was proved to be the correct decision as there was no recurrence and the facial expression of the patient was only slightly affected postoperatively.

In summary, nodular fasciitis in the orofacial region is rare and may have an association with a history of trauma. Final diagnosis depends on the pathological and immunohistochemical results. The recommended treatment is usually complete, conservative excision and the prognosis is satisfactory.

References

1. Konwaler BE, Keasbey L, Kaplan L. Subcutaneous pseudosarcomatous fibromatosis (fasciitis). *Am J Clin Pathol* 1955;25:241–252.
2. Grobmyer SR, Knapik JA, Foss RM et al. Nodular fasciitis: Differential considerations and current management strategies. *Am Surg* 2009;75:610–614.
3. Shimizu S, Hashimoto H, Enjoji M. Nodular fasciitis: An analysis of 250 patients. *Pathology* 1984;16:161–166.
4. Donner LR, Silva T, Dobin SM. Clonal rearrangement of 15p11.2, 16p11.2, and 16p13.3 in a case of nodular fasciitis: Additional evidence favoring nodular fasciitis as a benign neoplasm and not a reactive tumefaction. *Cancer Genet Cytogenet* 2002;139:138–140.
5. Graham BS, Barrett TL, Goltz RW. Nodular fasciitis: Response to intralesional corticosteroids. *J Am Acad Dermatol* 1999;40:490–492.
6. Werning JT. Nodular fasciitis of the orofacial region. *Oral Surg Oral Med Oral Pathol* 1979;48:441–446.
7. Matusik J, Wiberg A, Sloboda J et al. Fine needle aspiration in nodular fasciitis of the face. *Cytopathology* 2002;13:128–132.
8. Katada T, Tsuchimochi M, Oda T et al. Magnetic resonance imaging findings of nodular fasciitis in the mental region. *Odontology* 2004;92:77–80.
9. Madorsky SJ, Allison GR. Management of buccal space tumors by rhytidectomy approach with superficial musculoaponeurotic system reconstruction. *Am J Otolaryngol* 1999;20:51–55.
10. Han W, Hu Q, Yang X et al. Nodular fasciitis in the orofacial region. *Int J Oral Maxillofac Surg* 2006;35:924–927.
11. Carr MM, Fraser RB, Clarke KD. Nodular fasciitis in the parotid region of a child. *Head Neck* 1998;20:645–648.
12. Saad RS, Takei H, Lipscomb J et al. Nodular fasciitis of parotid region: A pitfall in the diagnosis of pleomorphic adenomas on fine-needle aspiration cytology. *Diagn Cytopathol* 2005;33:191–194.
13. Shin JH, Lee HK, Cho KJ et al. Nodular fasciitis of the head and neck: Radiographic findings. *Clin Imaging* 2003;27:31–37.
14. Reitzen SD, Dogan S, Har-El G. Nodular fasciitis: A case series. *J Laryngol Otol* 2009;123:541–544.
15. Kim ST, Kim HJ, Park SW et al. Nodular fasciitis in the head and neck: CT and MR imaging findings. *AJNR Am J Neuroradiol* 2005;26:2617–2623.
16. Abendroth CS, Frauenhoffer EE. Nodular fasciitis of the parotid gland. Report of a case with presentation in an unusual location and cytologic differential diagnosis. *Acta Cytol* 1995;39:530–534.
17. Davies HT, Bradley N, Bowerman JE. Oral nodular fasciitis. *Br J Oral Maxillofac Surg* 1989;27:147–151.
18. Dayan D, Nasrallah V, Vered M. Clinico-pathologic correlations of myofibroblastic tumors of the oral cavity: I. Nodular fasciitis. *J Oral Pathol Med* 2005;34:426–435.
19. Bernstein KE, Lattes R. Nodular (pseudosarcomatous) fasciitis, a nonrecurrent lesion: Clinicopathologic study of 134 cases. *Cancer* 1982;49:1668–1678.
20. Stanley MW, Skoog L, Tani EM et al. Nodular fasciitis: Spontaneous resolution following diagnosis by fine-needle aspiration. *Diagn Cytopathol* 1993;9:322–324.