

# Sialendoscopy-based Diagnosis and Treatment of Salivary Ductal Obstructions

Gui Qing LIAO<sup>1</sup>, Yu Xiong SU<sup>1</sup>, Guang Sen ZHENG<sup>1</sup>, Li Zhong LIANG<sup>1</sup>

*Salivary gland ductal obstruction is traditionally treated by sialoadenectomy when conservative measures fail. During the last decade, sialendoscopy has become the preferred approach in the management of salivary ductal obstructions. Sialendoscopy can provide direct, accurate and reliable visualisation of the salivary duct lumen and ductal pathologies, and can eliminate pathologies with miniaturised instrumentation. Now, sialendoscopic surgery is a promising option for patients who can be offered a satisfactory clinical outcome while avoiding sialoadenectomy. The present article briefly outlines sialendoscopy-based diagnosis and treatment of salivary ductal obstructions.*

**Key words:** sialendoscopy, diagnosis and treatment, salivary ductal obstructions

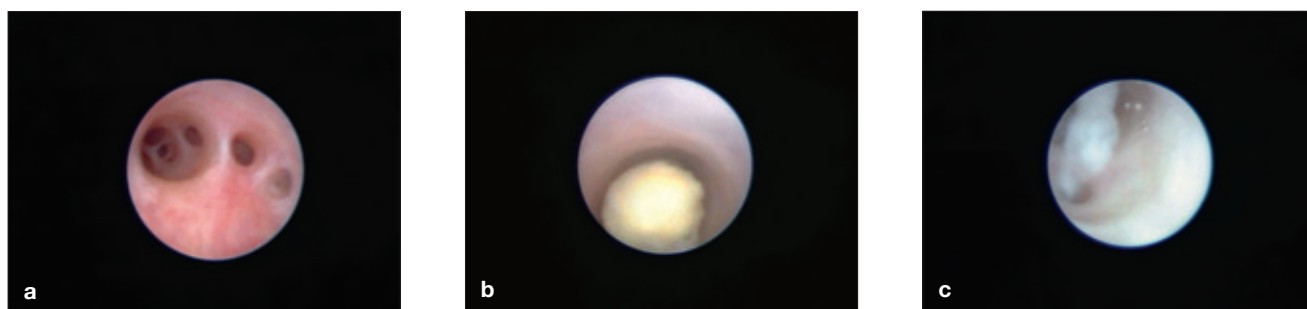
Obstructive salivary gland disease is one of the most common problems that afflict salivary glands and a major cause of salivary gland dysfunction and sialoadenectomy<sup>1</sup>. The exact causes of obstructions per se remain elusive<sup>2</sup>. Sialoliths, strictures, mucous plugs and other obstructions located in Wharton's duct or Stensen's duct may result in obstructive symptoms and

may cause acute or chronic infection<sup>3</sup>. These pathologies cause repeated episodes of gland swelling and pain, usually at mealtime. Conservative therapeutic approaches including gland massage, sialagogues (chewing gum, sour drops) and antibiotics can only ease the symptoms. Sialoadenectomy is usually indicated for these patients if the conservative therapies fail.

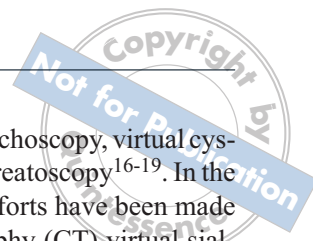
Over the last decade, sialendoscopy has been introduced as a minimally invasive surgical procedure in the diagnosis and treatment of salivary ductal diseases<sup>4-6</sup>. With the advantages of this new technique, surgeons can visualise the duct lumen (Fig 1a) and the pathologies (Fig 1b and c), making the diagnosis according to the endoscopic findings. Then, interventions can be performed, aiming to eliminate obstructions or dilate the

<sup>1</sup> Department of Oral and Maxillofacial Surgery, Guanghua School of Stomatology, Sun Yat-sen University, Guangzhou, P.R. China

**Corresponding author:** Dr Gui Qing LIAO, Department of Oral and Maxillofacial Surgery, Guanghua School of Stomatology, Sun Yat-sen University, 56 Lingyuanxi Road, Guangzhou, 510055, P.R. China. Tel: 86-20-83862531; Fax: 86-20-83822807. E-mail: drliaoguiqing@hotmail.com



**Fig 1** Sialendoscopic view of salivary duct lumen and pathologies: (a) endoscopic view of Stensen's duct, (b) endoscopic view of sialoliths in Wharton's duct, (c) mucous plugs floating in the hilus of parotid gland.



duct. Sialendoscopy enables preservation of the salivary gland, with relief of symptoms in the majority of patients who previously would have had to receive a sialoadenectomy<sup>7</sup>. The present article outlines the current status of sialendoscopy-based diagnosis and treatment of salivary ductal obstructions.

## Sialendoscopy-based diagnosis

### *Diagnostic sialendoscopy*

Most obstructive symptoms of the salivary gland are due to stones and stenosis<sup>4</sup>. Until now, radiographic evaluation has been the most frequently used method in the diagnosis of salivary ductal disorders. However, there are some obvious weaknesses of conventional radiography and contrast sialography<sup>8</sup>. First, patients are exposed to radiation, and in some cases such as pregnant women, ionising radiation is forbidden. Second, conventional radiography is unable to detect radiolucent sialoliths, mucous plugs and polyps. Third, the injection of contrast solution to perform sialography may push backward the sialoliths and make it more difficult to perform an open sialolithectomy. Finally, some patients may be allergic to the contrast solution<sup>8</sup>. With current advances in endoscopic techniques, sialendoscopy can provide surgeons direct, accurate and reliable information about salivary duct lumen and ductal pathologies, and can reduce the need for radiographic investigations<sup>7</sup>. With the endoscopic approach, a high rate of radiolucent sialoliths has been reported: 32% in Wharton's duct and 63 to 67% in Stensen's duct<sup>4,9</sup>. Also, a high rate of multiple sialoliths has been detected by sialendoscopy: 58% of parotid stones and 29% of submandibular stones were multiple<sup>10,11</sup>. The application of sialendoscopy makes it possible to detect all of these ductal pathologies directly and clearly (Fig 1b and c), including sialoliths, stenosis, mucous plugs, polyps, foreign bodies and other obstructions. At present, diagnostic sialendoscopy should be the investigation of choice for any suspected obstructive diseases of the salivary glands<sup>12</sup> or any gland swelling of unclear origin<sup>10,13,14</sup>, except malignancies.

### *CT virtual sialendoscopy*

Virtual endoscopy is a diagnostic tool used to view the inner surface of hollow organs by computer-generated simulations of endoscopic images derived from three-dimensional imaging datasets<sup>15</sup>. During the last decade, virtual endoscopy has become a rapidly evolving technique and has been widely studied in medical fields such

as virtual colonoscopy, virtual bronchoscopy, virtual cystoscopy and virtual cholangiopancreatography<sup>16-19</sup>. In the field of salivary gland imaging, efforts have been made to develop computerised tomography (CT) virtual sialendoscopy for the visualisation of salivary duct lumen in an *in vitro* study<sup>20</sup>. In this study, conventional sialendoscopy was performed in 16 submandibular glands *in vitro* and the surgical findings were recorded<sup>20</sup>. Then, a contrast agent was injected into the Wharton's duct via an orifice. After CT scanning, the CT data were transferred to an independent workstation and were post-processed with commercially available software to generate three-dimensional reconstructive and virtual sialendoscopic images. CT virtual sialendoscopic images were generated with a ray-casting algorithm, which selected visible voxels by tracing rays from the current viewing position. The threshold was set to allow identification of ductal wall as opaque voxels and to achieve optimal clarity. With this mode, all pixels above the selected threshold level were considered to be within the ductal lumen and pixels below the selected threshold level were considered to be outside the ductal lumen. Then, the path of virtual sialendoscopy was determined to simulate the surgical process of conventional sialendoscopy. The computer calculated consecutive endoluminal views of salivary duct along the path, as viewed from the tip of conventional sialendoscopy. The results showed that CT virtual sialendoscopy could generate endoluminal images of salivary ducts, simulating those obtained with conventional sialendoscopy. CT virtual sialendoscopy provides another potential imaging tool for direct visualisation of the endoluminal view of salivary ducts. However, *in vivo* studies are needed to reach final conclusions<sup>20</sup>.

### *MR virtual sialendoscopy*

In 1996, Lomas et al<sup>21</sup> first reported magnetic resonance (MR) sialography as a noninvasive method for investigating the main salivary gland duct systems. Based on an MR water imaging acquisition technique, also called MR hydrography, MR sialography yields salivary duct images originating from static or nearly static fluid that occupies the duct cavity. Recently introduced MR virtual endoscopy is a post-processing technique used to create three-dimensional images from high resolution MR data, which enables endoluminal navigation through hollow organs and the simulation of conventional surgical endoscopy<sup>8,22,23</sup>. It can provide the precise spatial relationships of pathological lesions and their surrounding structures. Such images can be used for surgical simulation in the individual patient, allowing the surgeons to perform surgical procedures with greater confidence.

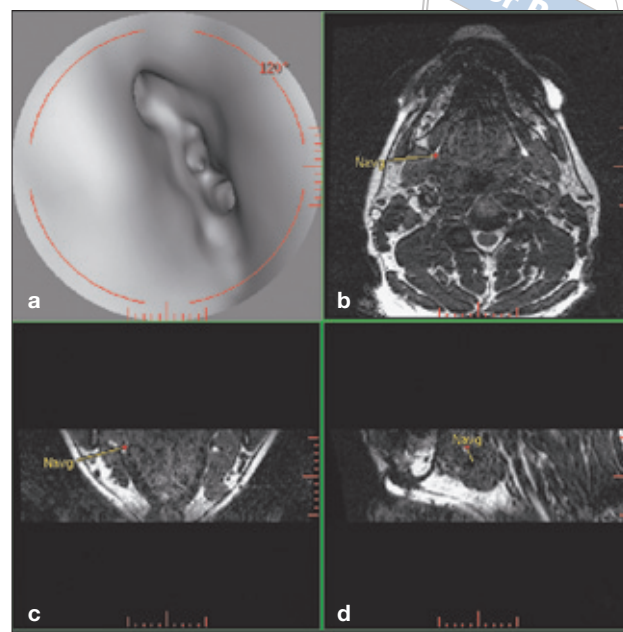
Virtual endoscopy has high diagnostic power without the risk inherent in invasive procedures. MR virtual endoscopy has been conducted using three-dimensional fast imaging, employing steady-state acquisition (3D FIESTA) (Fig 2)<sup>8</sup>. 3D FIESTA is a relatively new MR sequence which provides outstanding high-resolution images of fluid-filled structures with very rapid acquisition times. This bright fluid sequence employs ultra short times of repetition and echo with excellent image contrast, and it uses steady-state contrast mechanisms to provide a high signal-to-noise ratio. This provides images with a strong signal from fluid, while effectively suppressing background tissue. Tissues with large T2/T1 ratios such as fluid, blood and fat show strong signals in this imaging sequence. The images can be post-processed with maximum intensity projections or volume rendering techniques to generate three-dimensional reconstructions of clear anatomic details of miniature structures. The authors' experience illustrates the high value of the clinical application of 3D FIESTA for MR sialography and virtual endoscopy: bright signal from the fluid-filled salivary duct, rapid acquisitions times and excellent image contrast and spatial resolution. Virtual endoscopy enables preoperative surgical planning based on information from a "surgeons' view" of the individual patient, contributing to the safety of the procedures. For patients, the advantages include the non-invasiveness and low risk of the procedure, the lack of ionising radiation, low body discomfort, no need for cannulation and no risk of allergy to the contrast solution<sup>8</sup>.

### Sialendoscopy-based treatment

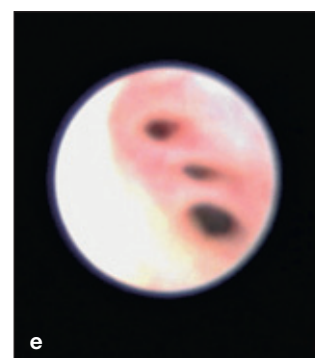
#### *Sialendoscopic intraductal removal of calculi*

Sialendoscopy, which serves as a minimally invasive surgical technique, enriches the treatment of obstructive salivary gland disease and obviates the need for sialoadenectomy. The miniaturisation of the instrumentation makes it possible to eliminate pathologies located deep in the ductal system with a high cure rate and a low morbidity rate of postoperative complications<sup>24,25</sup>.

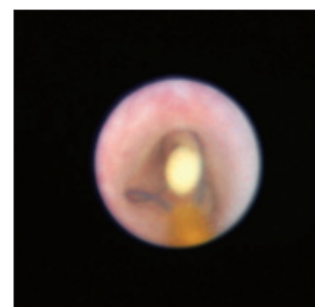
Sialoliths can be removed intraductally by wire basket, grasping forceps and/or balloon catheter. Wire basket is the first choice for retrieval, especially for movable small stones (Fig 3). Grasping forceps are indicated for bigger stones and unmovable stones stuck to the ductal wall. Balloon catheter is only used as a supplement to wire baskets and forceps. A combined application of these instruments is always indicated in dealing with multiple stones<sup>24,25</sup>.



**Fig 2** Comparison of MR virtual sialendoscopic and conventional sialendoscopic view of hilus of submandibular gland: (a) MR virtual sialendoscopy shows the orifices of the branches; (b, c and d) represent axial, coronal and sagittal orientations, respectively; (e) sialendoscopic finding shows close resemblance to the virtual endoscopic image.

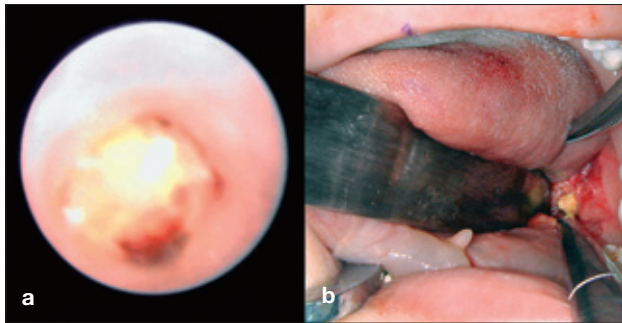


**Fig 3** Stone was captured by wire basket.



#### *Sialendoscopic dilatation of stricture*

Dilatation of a stricture can be performed first by saline irrigation with continuous pressure and the passage of the sialendoscope. Then, if necessary, a balloon catheter can be inserted to the position of the stricture, and mechanical dilatation can be accomplished by the dilated balloon-tip filled with saline. Each stricture will be inflated for



**Fig 4** Sialendoscopically assisted open sialolithectomy for a huge submandibular hilum stone: (a) the stone attached to the ductal wall is identified under endoscopic view, (b) the calculus was removed using a sialendoscopically assisted open sialolithectomy technique.

90 seconds at least two times, until the endoscope can pass smoothly through the stricture<sup>26</sup>. For mucous plugs floating in the duct, saline lavage is effective in most cases. Otherwise, a wire basket or grasping forceps can be introduced for the removal. Polyps and foreign bodies can be extracted by forceps or wire basket. For Stensen's duct, after hydrocortisone lavage, an endoluminal stent is inserted into the duct. The endoluminal stent is removed 2 weeks after surgery. The patients are then encouraged to massage the affected glands and to be well-hydrated.

#### *Sialendoscopically assisted open sialolithectomy*

A large hilar sialolith is still one of the most technically challenging issues in sialendoscopic surgery. Stones larger than 1 cm that locate in the hilum are always attached to the ductal wall. Intraductal approaches including wire basket and forceps are incapable of releasing such large stones<sup>27</sup>. Even if these stones can be captured, it is nearly impossible for them to pass through the relatively narrow duct channel. Therefore, the authors use the surgical technique of sialendoscopically assisted open sialolithectomy for removal of large hilar sialoliths (Fig 4)<sup>5</sup>. The surgical procedure includes the following steps:

- inserting the endoscope
- identifying and locating the stone intraductally by sialendoscopy
- marking the position of the calculus according to the light transmitted from the tip of the endoscope in the oral floor mucosa (for submandibular gland) or in the cheek skin (for parotid gland)
- making an incision in the marked position, under the guidance of endoscopic light
- isolating the duct from the surrounding tissues, distinguishing the lingual nerve from Wharton's duct

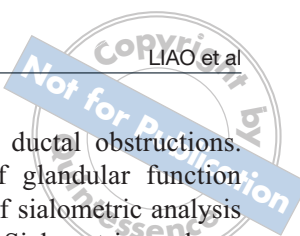
- performing the incision in the hilum according to the guidance of the endoscope
- separating the stone from the ductal wall and releasing it
- irrigating the hilum
- sialendoscopic surgery for the remnant stones, mucous plugs and other possible pathologies
- suturing the hilum and the oral mucous (or cheek skin) and inserting an endoluminal stent for duct plasty.

The technique is similar to what Nahlieli et al, McGurk et al and Marchal reported<sup>27-30</sup>. When compared to the traditional transoral open sialolithectomy<sup>31,32</sup>, this endoscopically assisted technique has its advantages. The endoscope plays an indispensable role in this approach, including duct exploration, exact orientation of sialoliths, differentiation of the main duct and the lingual nerve, and management of other pathologies such as remnant calculi and mucous plugs. One of the most important issues in this procedure is to identify and protect the lingual nerve. Anterior to the hilum, the lingual nerve laterally crosses the duct and then passes medially to the tongue. With the endoscopic light transmitted inside the duct, it is not only easier to locate the sialoliths but also more reliable for the operator to distinguish the duct from the lingual nerve. The authors' experience is that the endoscope facilitates the retrieval of large hilar calculi, making the surgery more precise and reducing the possibility of there being remaining stones<sup>5</sup>. The technique can be used as an attractive alternative to existing techniques such as extracorporeal shockwave lithotripsy<sup>3,33</sup> for extraction of large hilar sialoliths.

#### *Sialendoscopic secondary intervention after failure of open sialolithectomy*

Although sialendoscopy has shown several obvious advantages over open sialolithectomy, open sialolithectomy is still used in clinical practice, especially in those medical institutions without instruments for sialendoscopy. And for patients with sialoliths located in the anterior part of the duct, open sialolithectomy is easier to perform, less time consuming, less expensive and more cost-effective than sialendoscopy. However, one of the substantial drawbacks of open sialolithectomy is the relatively high failure rate. The relatively high incidence of radiolucent and multiple sialoliths, mucous plugs, strictures and polyps, which could be easily misdiagnosed by conventional imaging examinations, gives an explanation for the high recurrence rate of between 9% and 18% after conventional intraoral open sialolithectomy<sup>34,35</sup>. Conventionally, sialoadenectomy





was always indicated when open sialolithectomy failed. Sialoadenectomy could eradicate the obstructive symptoms but at the same time entailed possible postoperative complications such as facial nerve injury, in addition to the obvious functional and cosmetic impairments<sup>36</sup>. Now, sialendoscopy can be recommended as an effective secondary intervention after failure of open sialolithectomy. The technique of sialendoscopic secondary intervention is similar to the primary treatment with an endoscope<sup>6</sup>.

With advances in minimally invasive surgery during the past decade, there are more and more options in the management of obstructive salivary gland diseases. Open sialolithectomy, extracorporeal shockwave lithotripsy<sup>3,33</sup> and sialendoscopy are three currently available techniques in the treatment of sialolithiasis that avoid sialoadenectomy. Taking into account the indication, the technical difficulty, the hospital equipment and the medical cost, open sialolithectomy, extracorporeal shockwave lithotripsy and sialendoscopy will co-exist and serve as the main organ-preserving approaches. Thus, it is an important issue to address the complementary advantages and disadvantages of each technique and combine them for better clinical outcomes and patient satisfaction. Extracorporeal shockwave lithotripsy is always indicated for the huge sialoliths located in the posterior part of the duct and the hilum. The stone-free rate for extracorporeal lithotripsy varies from 40% to 50% according to previous reports, and it has a relatively high rate of complications, such as cutaneous hematoma, duct hemorrhage, pain and swelling of the gland, bacterial sialadenitis, and potential damage to the teeth and adjacent tissues<sup>37,38</sup>. For the radiopaque, large and single sialolith which is located in the anterior part of the duct, open sialolithectomy is easier to perform, less time consuming and less expensive than extracorporeal lithotripsy and sialendoscopy. But for the radiolucent, multiple, small and hilar stones, sialendoscopic surgery has overwhelming advantages. Future studies are needed to further investigate the advantages and disadvantages of these different procedures and provide more evidence for doctors to determine the optimal treatment for individual patients<sup>6</sup>.

#### *Salivary gland functional recovery after sialendoscopy*

To evaluate salivary gland functional recovery after sialendoscopic management of obstructive salivary gland disease, a prospective, self-controlled study was performed on the glandular functional assessment before and after sialendoscopic treatment<sup>39</sup>. The study was undertaken with patients scheduled for sialendoscopic

surgery with unilateral salivary ductal obstructions. Multidimensional assessment of glandular function was performed through the use of sialometric analysis and salivary gland scintigraphy. Sialometric analyses included resting and stimulated glandular saliva flow rate tests. The uptake index and excretion fraction were quantitatively assessed by use of scintigraphic examination with <sup>99m</sup>Tc-pertechnetate. The results showed that although the degree of functional recovery varied postoperatively in individuals, statistical analysis revealed that the glandular function increased significantly in the affected glands and had no differences when compared to the contralateral glands. These data provided a unique functional assessment after sialendoscopic surgery, which provides support for the use of sialendoscopy as a function-preserving technique in the treatment of salivary duct obstructions. These results demonstrate that sialendoscopy is an organ-preserving surgical approach that can achieve satisfactory functional recovery in the management of salivary ductal obstructions<sup>39</sup>.

#### **Conclusions**

The clinical application of sialendoscopy is a breakthrough in the diagnosis and treatment of salivary ductal obstructions. Sialendoscopy is an organ-preserving technique which is safe, effective and promising, and should therefore be considered as the treatment of choice for patients affected by obstructive salivary gland diseases.

#### **Acknowledgments**

This study was supported by grants from the National Natural Science Foundation of China (No. 30901682), Specialized Research Fund for the Doctoral Program of Higher Education of China (No. 20090171120105), Natural Science Foundation of Guangdong Province (No. 9451008901001993), Medical Science Research Grant of Guangdong Province (No. WSTJJ2008112935952 1197704015050) and the Priming Scientific Research Foundation for the junior teachers of medicine at Sun Yat-sen University (No. 3171914).

#### **References**

1. Williams MF. Sialolithiasis. *Otolaryngol Clin North Am* 1999;32:819-834.
2. Su YX, Zhang K, Ke ZF, Zheng GS, Chu M, Liao GQ. Increased calcium and decreased magnesium and citrate concentrations of submandibular/sublingual saliva in sialolithiasis. *Arch Oral Biol* 2010;55:15-20.
3. McGurk M, Escudier MP, Brown JE. Modern management of salivary calculi. *Br J Surg* 2005; 92:107-112.

4. Nahlieli O, Nakar LH, Nazarian Y, Turner MD. Sialoendoscopy: A new approach to salivary gland obstructive pathology. *J Am Dent Assoc* 2006;137:1394-1400.
5. Su YX, Liao GQ, Zheng GS, Liu HC, Liang YJ, Ou DM. Sialoendoscopically assisted open sialolithectomy for removal of large submandibular hilar calculi. *J Oral Maxillofac Surg* 2010;68:68-73.
6. Su YX, Wang L, Liao GQ, Liu HC, Liang YJ, Zheng GS. Sialoendoscopic secondary intervention after failure of open sialolithectomy. *J Oral Maxillofac Surg* 2010;68:313-318.
7. Marchal F, Dulguerov P, Lehmann W. Interventional sialendoscopy. *N Engl J Med* 1999; 341:1242-1243.
8. Su YX, Liao GQ, Kang Z, Zou Y. Application of MR virtual endoscopy as a presurgical procedure before sialendoscopy. *Laryngoscope* 2006;116:1899-1906.
9. Nahlieli O, Baruchin AM. Long-term experience with endoscopic diagnosis and treatment of salivary gland inflammatory diseases. *Laryngoscope* 2000; 110:988-993.
10. Marchal F, Dulguerov P, Becker M, Barki G, Disant F, Lehmann W. Specificity of parotid sialendoscopy. *Laryngoscope* 2001;111:264-271.
11. Marchal F, Dulguerov P, Becker M, Barki G, Disant F, Lehmann W. Submandibular diagnostic and interventional sialendoscopy: new procedure for ductal disorders. *Ann Otol Rhinol Laryngol* 2002;111:27-35.
12. Su YX, Liao GQ, Wang L, Liang YJ, Chu M, Zheng GS. Sialoliths or phleboliths? *Laryngoscope* 2009;119:1344-1347.
13. Koch M, Zenk J, Bozzato A, Bumm K, Iro H. Sialoscopy in cases of unclear swelling of the major salivary glands. *Otolaryngol Head Neck Surg* 2005;133:863-868.
14. Marchal F, Becker M, Dulguerov P, Lehmann W. Interventional sialendoscopy. *Laryngoscope* 2000;110:318-320.
15. Jolesz FA, Lorensen WE, Shinmoto H, Atsumi H, Nakajima S, Kavanaugh P et al. Interactive virtual endoscopy. *AJR Am J Roentgenol* 1997;169:1229-1235.
16. Fenlon HM, Nunes DP, Schroy PC 3rd, Barish MA, Clarke PD, Ferrucci JT. A comparison of virtual and conventional colonoscopy for the detection of colorectal polyps. *N Engl J Med* 1999;341:1496-1503.
17. Honnef D, Wildberger JE, Das M, Hohl C, Mahnken AH, Barker M et al. Value of virtual tracheobronchoscopy and bronchography from 16-slice multidetector-row spiral computed tomography for assessment of suspected tracheobronchial stenosis in children. *Eur Radiol* 2006;16:1684-1691.
18. Bernhardt TM, Schmidl H, Philipp C, Allhoff EP, Rapp-Bernhardt U. Diagnostic potential of virtual cystoscopy of the bladder: MRI vs CT. Preliminary report. *Eur Radiol* 2003;13:305-312.
19. Prassopoulos P, Raptopoulos V, Chuttani R, McKee JD, McNicholas MM, Sheiman RG. Development of virtual CT cholangiopancreatography. *Radiology* 1998;209:570-574.
20. Su YX, Feng ST, Liao GQ, Zhong YQ, Liu HC, Zheng GS. CT virtual sialendoscopy versus conventional sialendoscopy in the visualization of salivary ductal lumen: an *in vitro* study. *Laryngoscope* 2009;119:1339-1343.
21. Lomas DJ, Carroll NR, Johnson G, Antoun NM, Freer CE. MR sialography. Work in progress. *Radiology* 1996;200:129-133.
22. Morimoto Y, Tanaka T, Tominaga K, Yoshioka I, Kito S, Ohba T. Clinical application of magnetic resonance sialographic 3-dimensional reconstruction imaging and magnetic resonance virtual endoscopy for salivary gland duct analysis. *J Oral Maxillofac Surg* 2004;62:1237-1245.
23. Morimoto Y, Tanaka T, Yoshioka I, Masumi S, Yamashita M, Ohba T. Virtual endoscopic view of salivary gland ducts using MR sialography data from three dimension fast asymmetric spin-echo (3D-FASE) sequences: a preliminary study. *Oral Dis* 2002;8:268-274.
24. Nahlieli O, Shacham R, Bar T, Eliav E. Endoscopic mechanical retrieval of sialoliths. *Oral Surg Oral Med Oral Pathol Oral Radiol Endod* 2003;95:396-402.
25. Nahlieli O, Baruchin AM. Endoscopic technique for the diagnosis and treatment of obstructive salivary gland diseases. *J Oral Maxillofac Surg* 1999;57:1394-1401.
26. Nahlieli O, Shacham R, Yoffe B, Eliav E. Diagnosis and treatment of strictures and kinks in salivary gland ducts. *J Oral Maxillofac Surg* 2001;59:484-490.
27. Nahlieli O, Shacham R, Zagury A, Bar T, Yoffe B. The ductal stretching technique: an endoscopic-assisted technique for removal of submandibular stones. *Laryngoscope* 2007;117:1031-1035.
28. Nahlieli O, London D, Zagury A, Eliav E. Combined approach to impacted parotid stones. *J Oral Maxillofac Surg* 2002;60:1418-1423.
29. McGurk M, MacBean AD, Fan KF, Sproat C, Darwish C. Endoscopically assisted operative retrieval of parotid stones. *Br J Oral Maxillofac Surg* 2006;44:157-160.
30. Marchal F. A combined endoscopic and external approach for extraction of large stones with preservation of parotid and submandibular glands. *Laryngoscope* 2007;117:373-377.
31. Roh JL, Park CI. Transoral removal of submandibular hilar stone and sialodochoplasty. *Otolaryngol Head Neck Surg* 2008;139:235-239.
32. McGurk M. Surgical release of a stone from the hilum of the submandibular gland: a technique note. *Int J Oral Maxillofac Surg* 2005;34:208-210.
33. Escudier MP, Brown JE, Drage NA, McGurk M. Extracorporeal shockwave lithotripsy in the management of salivary calculi. *Br J Surg* 2003;90:482-485.
34. Lustmann J, Regev E, Melamed Y. Sialolithiasis. A survey on 245 patients and a review of the literature. *Int J Oral Maxillofac Surg* 1990;19:135-138.
35. Rice DH. Advances in diagnosis and management of salivary gland diseases. *West J Med* 1984;140:238-249.
36. Berini-Ayres L, Gay-Escoda C. Morbidity associated with removal of the submandibular gland. *J Craniomaxillofac Surg* 1992;20:216-219.
37. Iro H, Zenk J, Waldfahrer F, Benzel W, Schneider T, Ell C. Extracorporeal shock wave lithotripsy of parotid stones. Results of a prospective clinical trial. *Ann Otol Rhinol Laryngol* 1998;107:860-864.
38. Capaccio P, Ottaviani F, Manzo R, Schindler A, Cesana B. Extracorporeal lithotripsy for salivary calculi: a long-term clinical experience. *Laryngoscope* 2004;114:1069-1073.
39. Su YX, Xu JH, Liao GQ, Zheng GS, Cheng MH, Han L, Shan H. Salivary gland functional recovery after sialendoscopy. *Laryngoscope* 2009;119:646-652.