

# MUCORMYCOSIS IN POST-COVID PATIENT: A CASE REPORT AND REVIEW OF LITERATURE

## Case history:

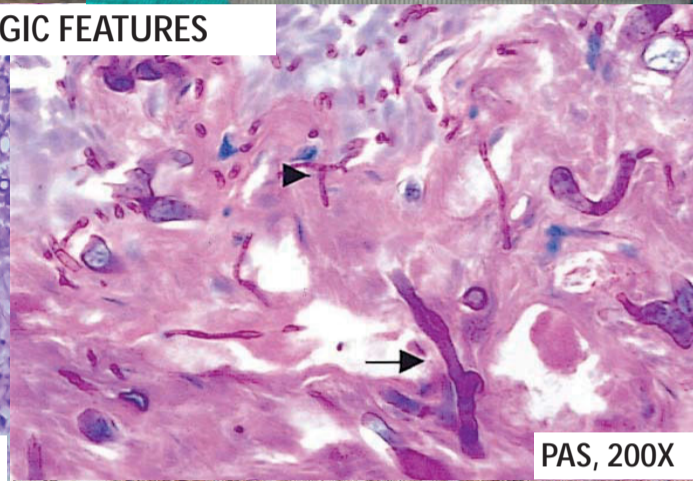
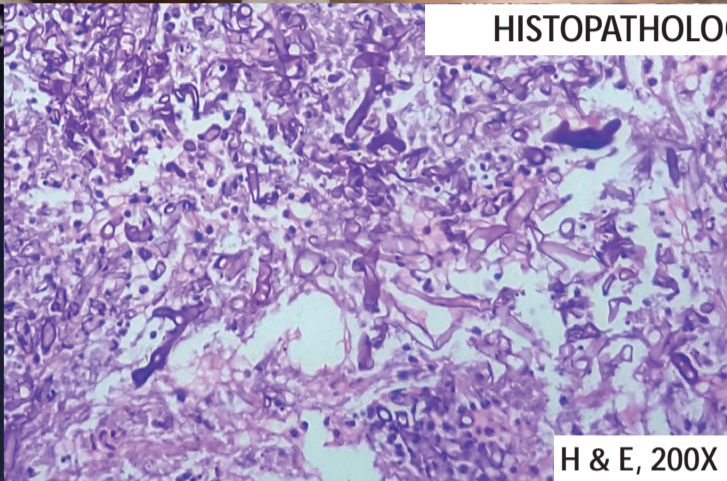
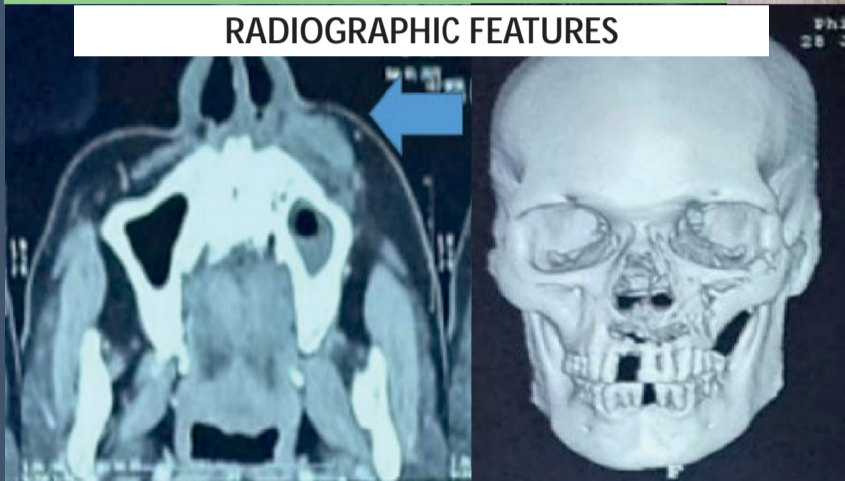
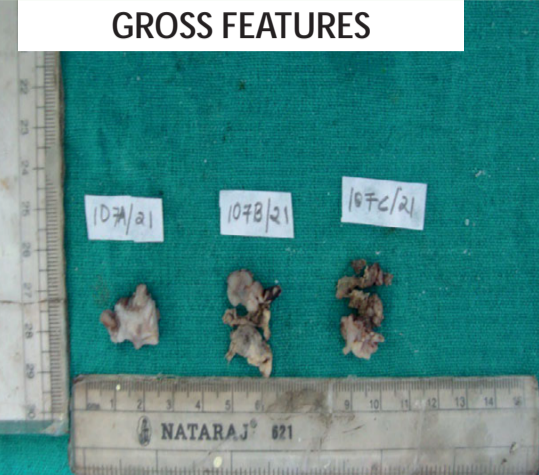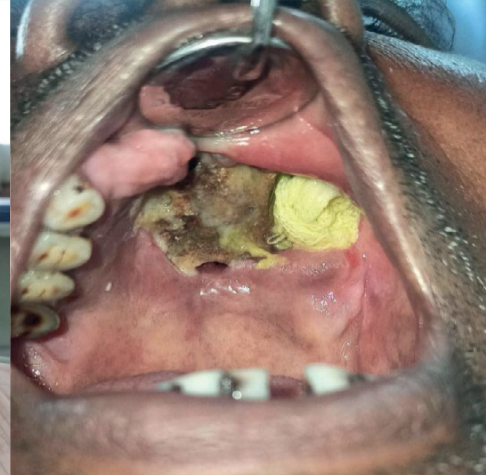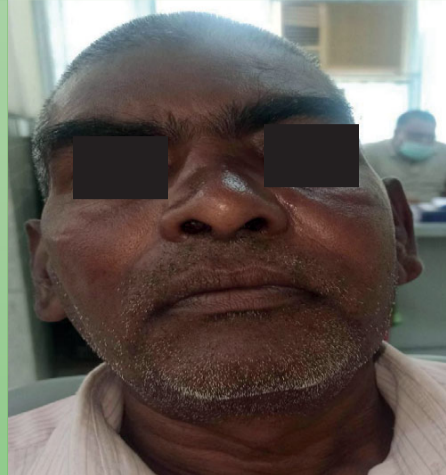A 62 year-old male patient complaining of pain and difficulty during eating due to ulceration in the palatal region of the upper jaw for 1 month.

### Extra-oral examination:


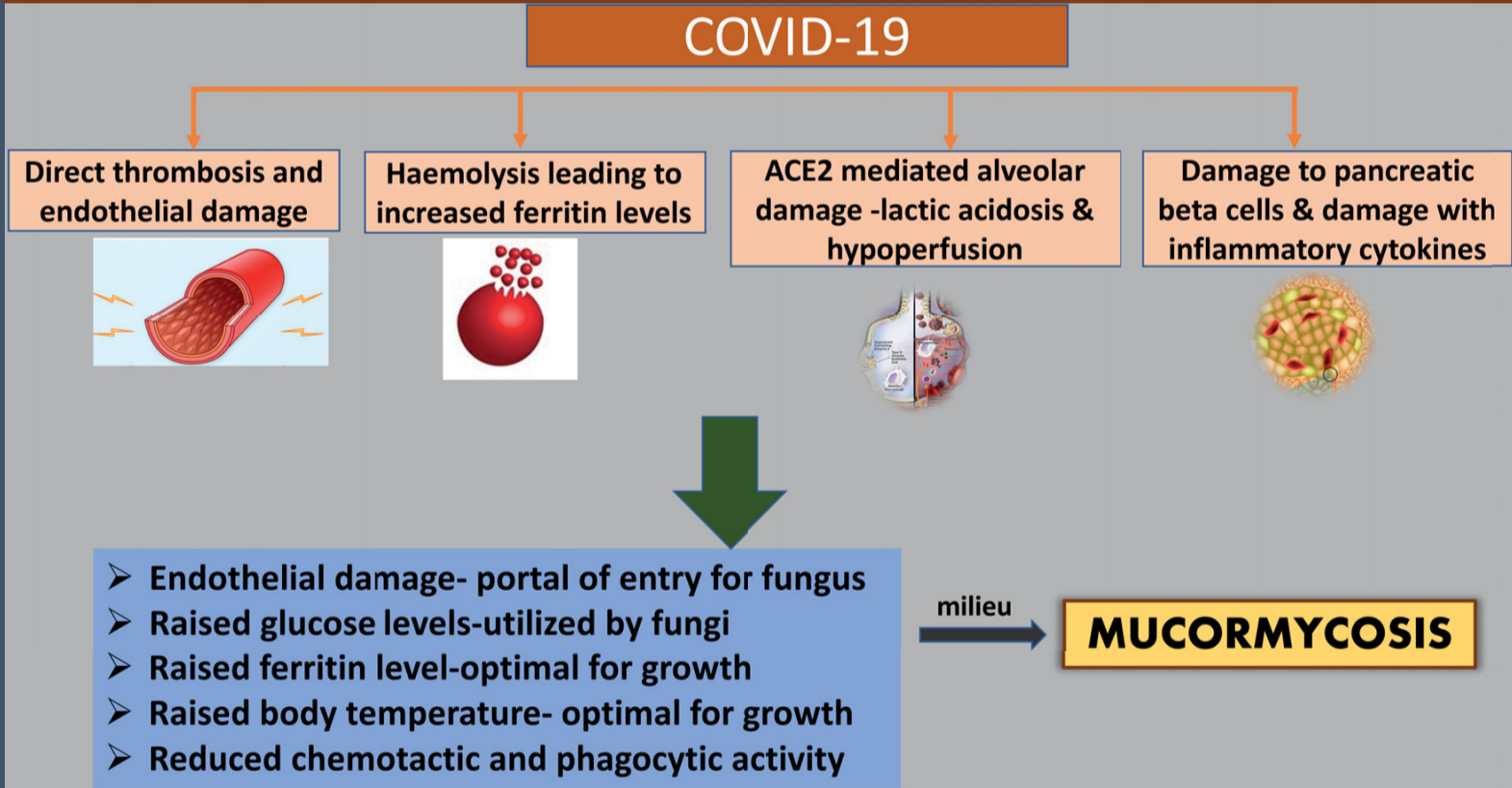
- ❖ Diffuse swelling on left side of face
- ❖ Downward displacement of medial canthus
- ❖ Non-tender, soft on palpation.

### Intraoral examination:

- ❖ An infiltrating ulcer (4 X 5 cm)
- ❖ Covered by necrotic slough
- ❖ Base of ulcer = hard, no bleeding



## SEQUAE OF EVENTS LEADING TO MUCORMYCOSIS POST COVID



### DIFFERENTIAL DIAGNOSIS:

- MUCORMYCOSIS
- OSTEOMYELITIS
- ASPERGILLOSIS

### HALLMARKS OF MUCORMYCOSIS:

- ❖ ANGIOINVASION
- ❖ THROMBOSIS
- ❖ ISCHEMIA
- ❖ NECROSIS

## TABLE DEPICTING THE REPORTED CASES IN INDIA THROUGH A SEARCH IN THE LITERATURE

S. No.	AUTHOR	LOCATION AND NO. OF CASE REPORTED	AGE/SEX	LOCATION OF LESION	S. No.	AUTHOR	LOCATION AND NO. OF CASE REPORTED	AGE/SEX	LOCATION OF LESION
1.	Mehta et al	Mumbai (1)	60/M	Paranasal sinus	13.	Patel et al	Multicentric(178)	-	Rhino-cerebro-orbital
2.	Garg et al	Chandigarh (1)	55/M	Pulmonary	14.	Singh et al	New Delhi (1)	48/M	Gastrointestinal
3.	Maini et al	Mumbai (1)	38/M	Sino-orbital	15.	Arjun et al	Kerala (10)	Mean=53	Rhino-cerebro-orbital
4.	Saldanha et al	Mangalore (1)	32/F	Paranasal sinus	16.	Saidha et al	Haryana (6)	29-56, M:4, F:2	Rhino-cerebro-orbital
5.	Revannavar et al	Mangalore (1)	Middle age/ F	Paranasal sinus	17.	Jain et al	Uttar Pradesh (1)	57/F	Gastrointestinal
6.	Sen et al	Mumbai (6)	46.2-73.9, M	Rhino-orbital	18.	Baskar et al	New Delhi (1)	28/M	Rhino-orbital
7.	Sarkar et al	Puducherry (10)	27-67, M: 8 F:2	Orbital	19.	Joshi et al	Mumbai (25)	Mean=55.2/ M:16, F:9	Rhino-orbital
8.	Mishra et al	Bangalore (10)	37-78, M: 9 F:1	Paranasal sinus	20.	Rao et al	Karnataka (1)	66/M	Rhino-orbital
9.	Satish et al	Bangalore (11)	30-74	Paranasal sinus	21.	Ravani et al	Gujarat (31)	Mean=56.3, M:20, F:11	Rhino-orbital
10.	Moorthy et al	Bangalore (17)	39-73, M: 15, F:2	Rhino-cerebro-orbital	22.	Nehara et al	Rajasthan (5)	52-70, M:1, F:4	Rhinocerebral
11.	Sharma et al	Jaipur (23)	NR/ M: 15 F: 8	Paranasal sinus	23.	Chauhan et al	Bhopal (1)	44/M	Rhino-orbital
12.	Sen et al	Multicentric (2826)	Mean=51.9/ M: 71%	Rhino-cerebro-orbital					

REFERENCES  
 1. Singh AK, Singh R, Joshi SR, Misra A. Mucormycosis in COVID-19: a systematic review of cases reported worldwide and in India. *Diabetes & Metabolic Syndrome: Clinical Research & Reviews*. 2021 Jul 1;15(4):102146. 2. Nagalli S, Kikkeri NS. Mucormycosis in COVID-19: A systematic review of literature. *Le Infezioni in Medicina*. 2021;29(4):504. 3. Azhar A, Khan WH, Khan PA, Alhosaini K, Owais M, Ahmad A. Mucormycosis and COVID-19 pandemic: Clinical and diagnostic approach. *Journal of Infection and Public Health*. 2022 Apr 1;15(4):466-79. 4. Patel A, Agarwal R, Rudramurthy SM, Shevkani M, Xess I, Sharma R, Savio J, Sethuraman N, Madan S, Shastri P, Thangaraju D. Multicenter epidemiologic study of coronavirus disease-associated mucormycosis, India. *Emerging infectious diseases*. 2021 Sep;27(9):2349. 5. Keerthika R, Narwal A, Kamboj M, Devi A, Anand R, Sivakumar N, Singh V, Agarwal V, Gupta A. Mucormycosis infection associated with global COVID-19 pandemic-an institutional histopathological study. *Medicina Oral, Patologia Oral y Cirugia Bucal*. 2023 Mar;28(2):e99. 6. Narayanan S, Chua JV, Baddley JW. Coronavirus disease 2019-associated mucormycosis: risk factors and mechanisms of disease. *Clinical Infectious Diseases*. 2022 Apr 1;74(7):1279-83.