

# Novel Digital Mouth Preparation Technique for Fabricating Implant-Retained Removable Partial Dentures with Distal Extension: a Case Report

Wan Rong WANG<sup>1#</sup>, Rui XIE<sup>1,#</sup>, Li Na NIU<sup>1</sup>, Zhi Hong FENG<sup>1</sup>, Yi Min ZHAO<sup>1</sup>

*Implant-retained removable partial dentures (RPDs) are commonly used to resolve the complications associated with traditional distal extension RPDs; however, this technology does not consider the necessity and importance of parallelism between the path of RPD insertion and the long axis of the implant. This clinical report presents a novel digital preparation technique that involves the preparation of parallel guiding planes on abutment teeth and implant insertion in the distal extension area using a computer-aided design and manufacturing template. This clinical case of implant-retained RPDs illustrates the fabrication and application of the digital template. Using this technique, the path of RPD insertion is parallel to the long axis of the implant. As a result, the components of the implant-retained RPD, including the abutment teeth, implants and attachments, can demonstrate greater longevity.*

**Key words:** *abutment teeth, digital preparation technique, distal extension, guide rods, guiding plane, implant, removable partial denture*

*Chin J Dent Res 2023;26(2):113-117; doi: 10.3290/j.cjdr.b4128029*

As the global population ages, the number of people with partial edentulism has increased<sup>1</sup>. Demand for removable partial dentures (RPDs) is high due to their low cost and wide range of indications<sup>2</sup>; however, the most common complaints related to distal extension RPDs are their lack of stability and retention, and other complications include irritation of the soft tissue under the connector or denture base<sup>3</sup>. Strategic placement of dental implants can minimise or eliminate all these difficulties<sup>4-7</sup>. Implant-retained RPDs provide favourable retention and stability for the denture base and

limit rotational movements. Many studies have reported patient satisfaction with implant-retained RPDs due to comfort, good retention, masticatory capacity, aesthetic appearance, ease of cleaning and significant improvements to speech<sup>8-10</sup>. In addition, a systematic review concluded that using an implant-retained removable dental prosthesis does not adversely affect the survival rate of the underlying implants<sup>11</sup>.

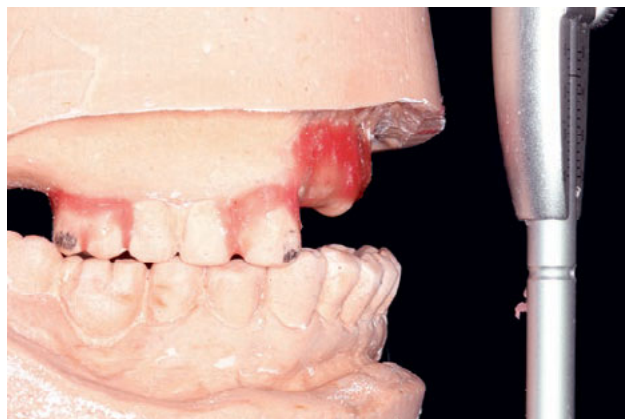Nevertheless, flaws in the fabrication of implant-retained RPDs remain. Specifically, some scholars have not considered the necessity and importance of parallelism between the path of removable denture insertion and the long axis of the implant. The convergence or divergence of implant attachments and the path of removable denture insertion commonly accelerates the wear undergone by attachments. Moreover, RPDs cannot be placed passively, resulting in an excessive, unfavourable force on the natural abutment teeth. Although some scholars have noted this problem, no feasible solution has yet been developed<sup>12</sup>. With the application of computer technology in stomatology, insertion of implants using guides or navigation has become common; however, a comprehensive design for implant placement and preparation of the path of insertion of implant-retained RPDs has not yet been reported.

1 National Clinical Research Center for Oral Diseases, State Key Laboratory of Military Stomatology, Shaanxi Key Laboratory of Stomatology, Department of Prosthodontics, School of Stomatology, The Fourth Military Medical University, Xi'an, Shaanxi Province, P.R. China.

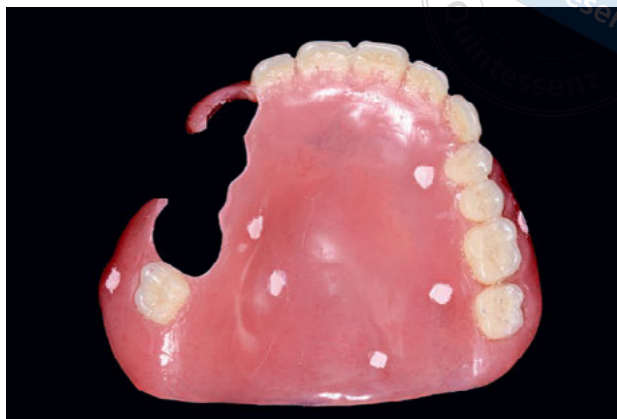# These two authors contributed equally to this work.

**Corresponding authors:** Dr Zhi Hong FENG and Prof Yi Min ZHAO, Department of Prosthodontics, School of Stomatology, The Fourth Military Medical University, No.145, Changle West Road, Xi'an 710032, Shaanxi Province, P.R. China. Tel: 86-029-84776465; Fax: 86-029-84776465. Email: fengzhong0516@163.com; zhaoyim@fmmu.edu.cn

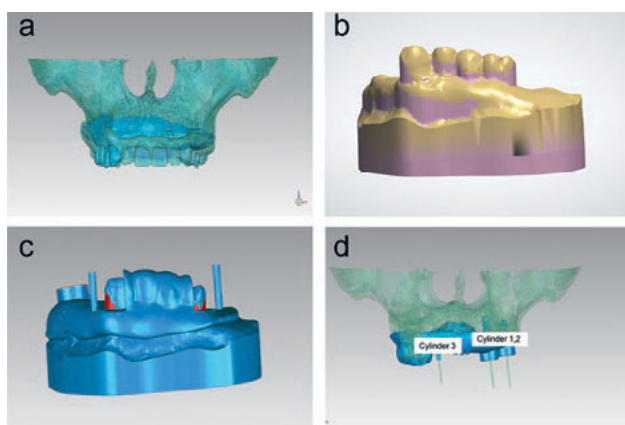
This work was supported by the Innovation Capability Support Program of Shaanxi (2023-CX-PT-27) and New Technology and New Project Research Grant from the Third Affiliated Hospital of Air Force Medical University.



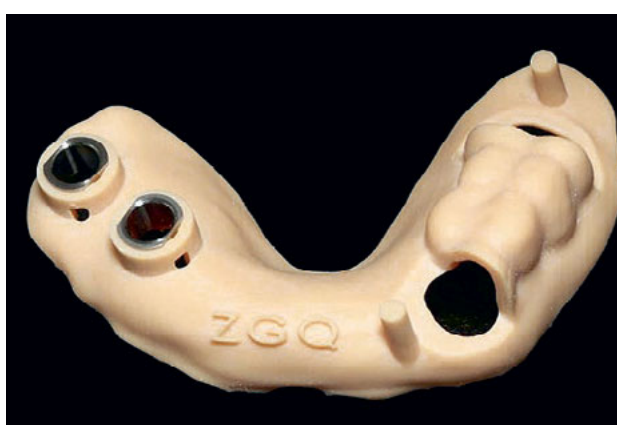**Fig 1** The anterior reverse articulation is clearly visible on the maxillary and mandibular study casts on the articulator.



**Fig 2** Temporary radio-opaque dentures were used as a radiographic guide.



**Fig 3** Computer-aided design of the combined guide plate: (a) The master 3D model; (b) the direction of the path of insertion was defined; (c) a base plate with guide rod; (d) the axis of the implants (cylinders 1 and 2) was as parallel to the path of insertion of the RPD (cylinder 3) as possible.



**Fig 4** Resin guide plate with guide rods and guide rings.

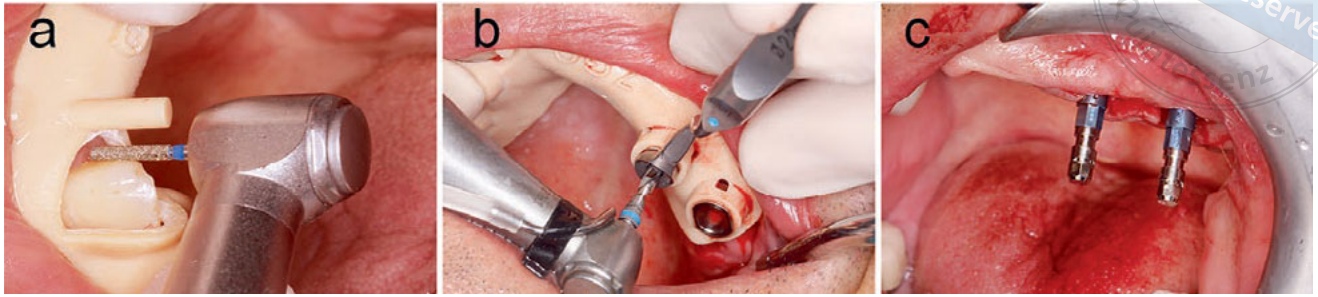
To solve these issues, the present authors explored a novel digital technique: computer technology was used for model survey and analysis, and the path of removable denture insertion was determined. Subsequently, the orientation of the implant was designed based on the path of removable denture insertion, and a combined guide plate was designed and fabricated through CAD/CAM to ensure that the virtual design could be implemented intraorally.

**Case report**

All procedures were performed in accordance with the ethical standards of the Committee on Human Experimentation of The Air Force Medical University, Xi'an, China, and the use of the patient's pictures was approved by the ethics committee. The patient also voluntarily provided written informed consent.

A healthy 56-year-old man requested an RPD for partial edentulism in the maxilla. Intraoral examination revealed the absence of maxillary anterior teeth, left posterior teeth and the right second molar. An obvious anterior reverse articulation and lack of support for the upper lip precluded the fabrication of implant fixed partial dentures. After a comprehensive review of the patient's oral condition and communication with him and his family, the patient decided to proceed with an implant-retained RPD with a distal extension.

Maxillary and mandibular study casts were obtained, and the maxillomandibular relationship was recorded and transferred to the articulator. The anterior reverse articulation was observed more clearly on the cast, and the need for an implant-retained RPD instead of an implant fixed partial denture was confirmed (Fig 1). The study casts were scanned using Ceramill Map 600 (Aman Girschbach, Pforzheim, Germany) to obtain a 3D



**Fig 5** Surgery with the combined guide plate: (a) the guiding plane was prepared according to the guide rods; (b) implant insertion surgery under the guidance of the combined guide plate; (c) visually, the two implants are completely parallel.

model of the dentures, which was saved as a standard tessellation language (STL) file.

Temporary radio-opaque dentures were fabricated on the study models and used as a radiographic guide (Fig 2). Dual CBCT was performed. Based on the CBCT data, 3D models of the maxilla and mandible, remaining dentition and artificial dentition were reconstructed and matched with the 3D models obtained by scanning the study models to set up the master 3D models in MIMICS 20.0 (Materialize, Leuven, Belgium). The model data were also saved as STL files (Fig 3a).

The 3D master models were transferred to the 3Shape Dental System 2020 software (3Shape, Copenhagen, Denmark) to survey the 3D model of the maxillary study cast to define the most advantageous position and path of insertion for an RPD. The undercuts were placed on the cast model (Fig 3b). A suprabulge circumferential retainer was designed on the maxillary first molar, and the infrabulge clasp on the maxillary right canine only played a stabilising role.

Thereafter, the 3D model of the maxillary study cast with the most advantageous position was input into MIMICS 20.0, and a model of the remaining teeth and support base plate was generated. Subsequently, guide rods with a diameter of 1.5 mm, completely parallel to the path of insertion of the final RPD, were designed on the base plate. The guide rods were placed 5 to 8 mm from the abutment teeth, and their height was the same as that of the abutment teeth. If the guide rods were too close or too high in relation to the abutment teeth, they would have hindered the accessibility of the handpiece during the preparation of the abutment teeth (Fig 3c).

Data related to the base plate were imported into Simplant 18.0 (Materialize). Based on the condition of the maxillary alveolar bone and the defined path of insertion of the RPD, the position, size and axial direction of the implants were determined. Accordingly, guide ring holes were designed in the same base plate, which served as the final guide plate, and the data

were saved as STL files. The long axis of the implant was completely parallel to the guide rods and path of insertion of the RPD. The key was to adjust the axial orientation of the implants to be as parallel to the path of insertion of the RPD as possible (Fig 3d).

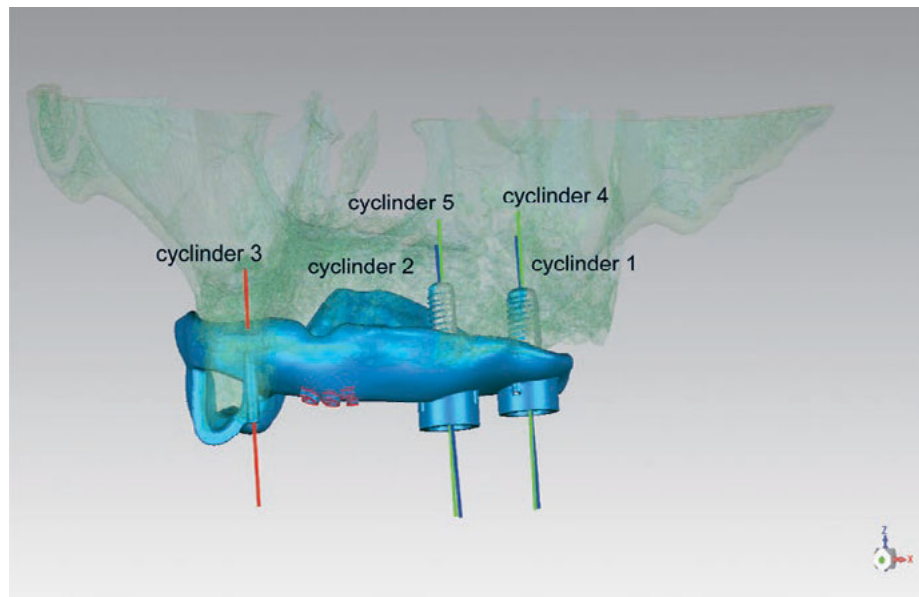
Data of the final 3D template were transmitted to a 3D printer (Form 2; Formlabs, Sommerville, MA, USA) to fabricate the physical resin guide plate (Fig 4). The guide rings were positioned in the corresponding holes. The CAD/CAM resin guide plate was positioned and retained in the remaining maxillary teeth. The guiding planes on the abutment teeth of the RPD were prepared as indicated by the guide rods. The dental burs were completely parallel to the guide rods during preparation (Fig 5a). The other guiding planes were prepared in the same manner. Thus, all guiding planes were parallel to each other and the pre-designed guide rods.

Subsequently, at the same appointment, standard disinfection protocols were followed. The resin guide plate was dipped in 5% o-phthalaldehyde for 10 minutes and rinsed thoroughly with saline before being placed in the patient's mouth. Under the guidance of the resin guide plate, two implants were placed in the maxillary alveolar bone (Straumann BL 4.1 [Ø 10 mm] and Straumann BL 4.8 [Ø 8 mm]; Straumann, Basel, Switzerland) under local infiltration anaesthesia with primacaine, and cover screws were attached to the implants (Fig 5b).

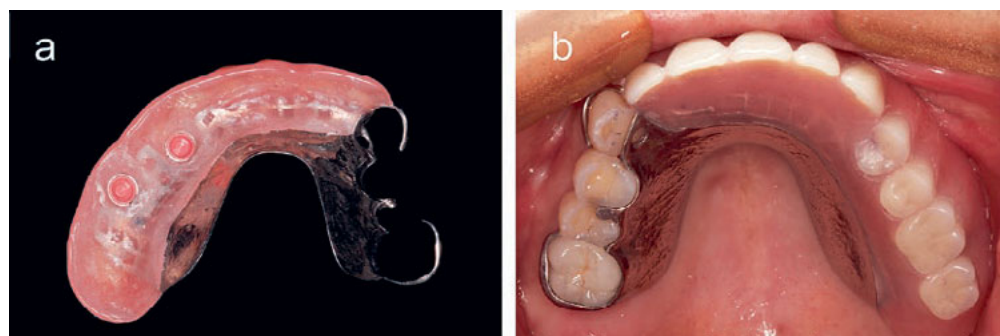
At the time of surgery, the two implants were visually parallel (Fig 5c). After surgery, CBCT was performed and the 3D model was reconstructed. The parallelism between the long axis of the two implants and guide rods and the long axis of the pre-designed implant was confirmed (Fig 6). The results were in agreement with the expected design.

After 6 months, implant osseointegration was complete and the locator attachments were torqued in the implants at the pre-planned positions. The final RPD was fabricated and inserted intraorally (Fig 7).





**Fig 6** Postoperative implants (grey) and pre-planned implants (blue); the blue axes of the two pre-planned implants (cylinders 1 and 2) are parallel to the green axes of the postoperative implants (cylinders 4 and 5) and to the expected path of insertion (red cylinder 3). Thus, the implants were accurately inserted into their positions and according to the ideal angle.



**Fig 7** (a) Final RPD and (b) insertion of the RPD.

Instructions for denture use were provided to the patient, including proper hygiene procedures and follow-up for possible annual relines.

**Discussion**

The present article describes a novel digital technique to ensure parallelism between the path of removable denture insertion and the long axis of the implant using a guide plate designed and fabricated through CAD/CAM.

In theory, implants are placed in the distal extension area and the attachment is used to connect the implant to RPDs to transform the free end into the non-free end, providing retention and stability for traditional RPDs while greatly reducing the non-axial force of the abutments. Implant-retained RPDs can, to some extent, reduce the stress on the alveolar bone under the base plate, the pressure on the alveolar mucosa and the probability of mucosal tenderness. Depending on the implant position and design of the RPD, this technique can also help eliminate the need for unsightly clasps

and improve the arch form if necessary. Compared with implant-supported fixed restorations, the number of implants can be reduced, and the economic burden on patients can be greatly alleviated; however, owing to the lack of unified planning between the design of the RPD and implant insertion, the aforementioned processes can result in many adverse events.

The path of RPD insertion has not been considered fully during implantation, resulting in a significant difference in the path of insertion and axis of implantation<sup>13-15</sup>. Through digital technology, the relevant information on the natural abutment teeth and alveolar bone can be considered comprehensively to design the RPD. In implant-retained RPDs, the implants mainly serve to provide retention and stability. Thus, when designing the axial direction of the implant, it should firstly be considered to be parallel to the insertion path of the removable denture; secondly, the axial direction of the implant should be within the range of available bone volume in the jaw; and finally, it should be coordinated with the position of the opposite dentition. This

can ensure that the path of RPD insertion is parallel to the long axis of the implant to achieve the best clinical outcome: when the RPD is inserted and removed along the direction of the insertion path, the negative and positive components of the implant attachment can move without crossing angles, thus reducing wear between components; the insertion and removal direction of the denture and implant attachment can be unified and the RPD can be passively positioned and removed smoothly without exerting a large lateral force on the natural abutment teeth, which is the most desired outcome when designing and manufacturing an RPD; and abutment tooth preparation and implant surgery can help coordinate the axial direction of the implant and direction of the masticatory forces as much as possible, reducing the unfavourable lateral forces on the implant, thus slowing bone resorption and extending the life of the implant. However, studies with longer follow-up are still needed to confirm this novel technique.

## Conclusion

This article presents a novel method that can help combine restoration-guided implantation with standard RPD design and tooth preparation through digital technology. It is possible to design and manufacture a combined guide plate for guide plane preparation on abutment teeth and for implantation using digital model surveying and alveolar bone analysis.

## Conflicts of interest

The authors declare no conflicts of interest related to this study.

## Author contribution

Dr Wan Rong WANG collected the data and drafted the manuscript; Drs Rui XIE and Zhi Hong FENG diagnosed and treated the patient; Drs Li Na NIU and Yi Min ZHAO revised the manuscript. All authors approved the final manuscript.

(Received Nov 07, 2022, accepted Feb 07, 2023)

## References

1. Campbell SD, Cooper L, Craddock H, et al. Removable partial dentures: the clinical need for innovation. *J Prosthet Dent* 2017;118:273–280.
2. Cooper LF. The current and future treatment of edentulism. *J Prosthodont* 2009;18:116–122.
3. De Kok IJ, Cooper LF, Guckes AD, et al. Factors influencing removable partial denture patient-reported outcomes of quality of life and satisfaction: a systematic review. *J Prosthodont* 2017;26:5–18.
4. Giffin KM. Solving the distal extension removable partial denture base movement dilemma: A clinical report. *J Prosthet Dent* 1996;76:347–349.
5. Lee JH, Kim SH, Yoon HI, Yeo ISL, Han JS. Implant-assisted removable prosthetic rehabilitation after distraction osteogenesis in a patient with ameloblastoma recurrence: A case report. *Medicine (Baltimore)* 2019;98:e18290.
6. Baek YW, Lim YJ, Lee JH, Ryu HS. Restoration of a partially edentulous patient with an implant-supported removable partial denture: A case report. *Quintessence Int* 2014;45:307–312.
7. Mijiritsky E. Implants in conjunction with removable partial dentures: A literature review. *Implant Dent* 2007;16:146–154.
8. Gonçalves TM, Campos CH, Garcia RC. Implant retention and support for distal extension partial removable dental prostheses: Satisfaction outcomes. *J Prosthet Dent* 2014;112:334–339.
9. Mijiritsky E, Lorean A, Mazor Z, Levin L. Implant tooth-supported removable partial denture with at least 15-year long-term follow-up. *Clin Implant Dent Relat Res* 2015;17:917–922.
10. Jensen C, Meijer HJA, Raghoobar GM, Kerdijk W, Cune MS. Implant-supported removable partial dentures in the mandible: A 3-16 year retrospective study. *J Prosthodont Res* 2017;61:98–105.
11. Zancopé K, Abrão GM, Karam FK, Neves FD. Placement of a distal implant to convert a mandibular removable Kennedy class I to an implant-supported partial removable Class III dental prosthesis: A systematic review. *J Prosthet Dent* 2015;113:528–533.e3.
12. Phoenix RD, Cagna DR, DeFreest CF. *Stewart's Clinical Removable Partial Prosthodontics*, ed 4. Chicago: Quintessence, 2008.
13. Bural C, Buzbas B, Ozatik S, Bayraktar G, Emes Y. Distal extension mandibular removable partial denture with implant support. *Eur J Dent* 2016;10:566–570.
14. Park JH, Lee JY, Shin SW, Kim HJ. Effect of conversion to implant-assisted removable partial denture in patients with mandibular Kennedy classification I: A systematic review and meta-analysis. *Clin Oral Implants Res* 2020;31:360–373.
15. Tribst JP, de Araújo RM, Ramanzine NP, et al. Mechanical behavior of implant assisted removable partial denture for Kennedy class II. *J Clin Exp Dent* 2020;12:e38–e45.