

## INTRODUCTION

Chondrodysplasias are a heterogeneous group of genetically determined pathologies, characterized by changes in cartilage, which translate into abnormal skeletal development<sup>1-3</sup>. Inside this group are the metaphyseal chondrodysplasias (MDCs), whose skeletal disorders mainly disturb the growth of long bones<sup>4</sup>. Both the classification and diagnosis of these pathologies are based on clinical, radiological, and genetic aspects<sup>1,2</sup>.

Within the large spectrum of metaphyseal chondrodysplasias, there is a group called type II<sup>5</sup> collagenopathies, whose clinical manifestations can range from lethal perinatal pathologies to mild conditions that manifest only in late adolescence or adulthood<sup>3</sup>. These pathologies result from mutations in the gene that encodes the alpha-1 chain of type II collagen<sup>5</sup>, the COL2A1 gene<sup>1-6</sup>, culminating in an essential deficit for the endochondral ossification process<sup>5</sup>. Therefore, these individuals suffer from disturbances in the epiphyseal plates at the articular level, in the nucleus pulposus of the intervertebral discs, and also at the ocular level, in the vitreous humor<sup>1</sup>.

Spondyloepimetaphyseal Dysplasia Strudwick type (SMED) is a rare autosomal dominant entity<sup>2</sup>. Clinically characterized by disproportionate short stature, *pectus carinatum*, scoliosis, lordosis, myopia, retinal detachment, equinovarus, *genu valgum*, *coxa vara*, hip arthritis, and even cleft palate<sup>1,2</sup>, although there are cases described with normal craniofacial appearance<sup>4</sup>. Radiographically, alterations such as metaphyseal dapping, atlantoaxial instability, hypoplasia of the odontoid process, platyspondyly and epiphyseal defects in the femur and tibia, among others, are detectable<sup>1,2</sup>. Patients suffering from this pathology require a multidisciplinary follow-up<sup>2</sup>.

Studies of MDCs at the orthodontic level are scarce and directed to specific subtypes, which may be related to the great clinical and radiological diversity within the different types of MDCs<sup>7</sup>. Cases of orthodontic treatment (OT) in individuals with SEMD are absent in the literature.

**OBJECTIVE:** Demonstrate the importance of orthodontic diagnosis and correct planning of treatment timings in rare cases of craniofacial deformity.

## CASE REPORT

A 14-year-old male patient with a history of SEMD and sleep apnea attended the Institute of Orthodontics of the Faculty of Medicine of the University of Coimbra, referred by a pediatrician for orthodontic treatment. Physical examination (fig.1) showed characteristic disproportionate short stature with *genu valgum*, *coxa vara*, *pectus carinatum*, and a face with mid-third hypoplasia, retrognathia, depression of the nasal bridge, and dental crowding. Complementary diagnostic exams - Photographic protocol, radiographs (fig.2) and models of study- allowed to collect the main orthodontic problems of the patient: SEMD, skeletal and hyperdivergent class II, apical and buccal position of teeth 1.3 and 2.3, lack of maxillary and mandibular space, respectively 7 and 5mm, increased overjet and overbite, accentuated mandibular curve of Spee associated with deep bite (fig.3) and the presence of a 2.1 tooth fragment in the lower lip.

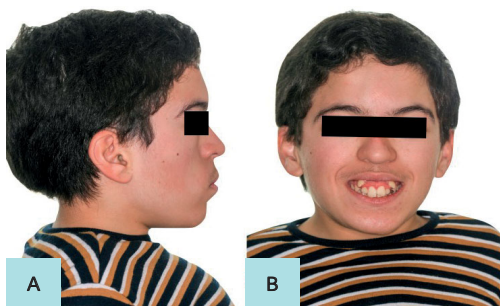


Figure 1. (A) Profile and (B) frontal facial photographs of the patient with 14 years old.

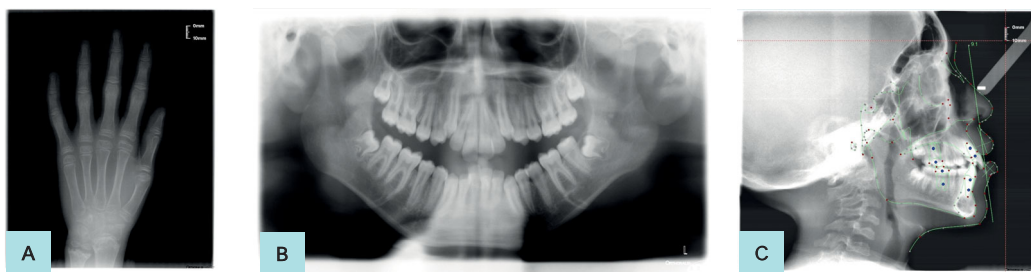

Figure 2. (A) Radiography of the hand and wrist, (B) Orthopantomography and (C) Cephalometric analysis—begin of OT.

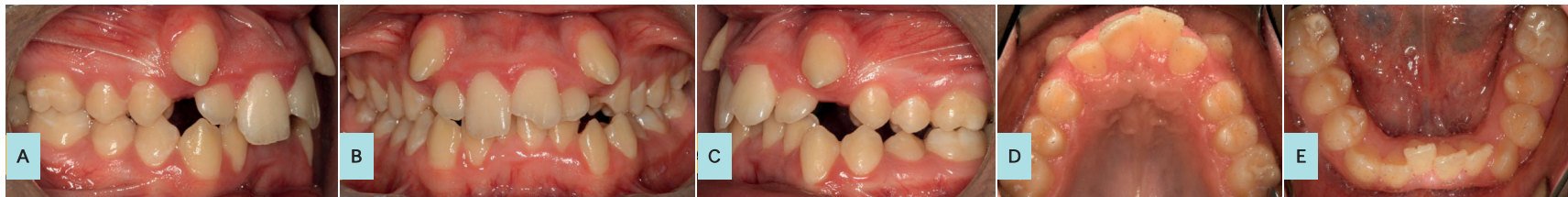


Figure 3. Intraoral photographs (A) right side, (B) frontal, (C) left side, (D) upper occlusal and (E) lower occlusal of the patient – begin of OT.

OT was planned without intervention in the skeletal position, with fixed multibrackets appliances (Roth's prescription .018), transpalatal bar and extraction of the first premolars in the upper jaw, in order to promote tooth alignment and leveling, as well as the canine class I and incisor block contraction. A fixed multibracket appliance was also placed in the mandible and stripping was performed for tooth alignment and levelling (fig.4).

At the end (fig.5,6 and 7), a Hawley plate was placed in the upper jaw and fixed retainer wire from 3.3 to 4.3.

In the short term, correction of crowding, overjet, overbite and smile line was achieved, and canine class I, molar class II and canine guides were obtained. In the medium and long term, it was possible to prevent temporomandibular joint pathology, improve the occlusal relationship, chewing and the patient's facial aesthetics.

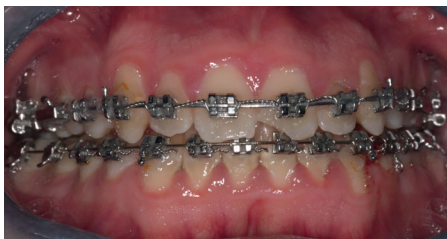

Figure 4. Frontal intraoral photograph - middle phase of OT.

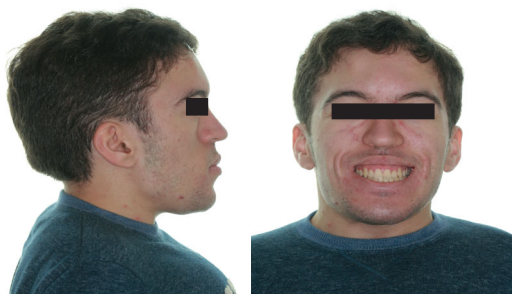

Figure 5. (A) Profile and (B) frontal facial photographs – end of OT.

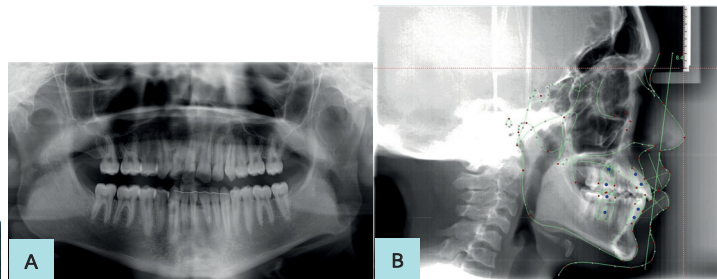


Figure 6. (A) Orthopantomography and (B) Cephalometric analysis – end of OT.

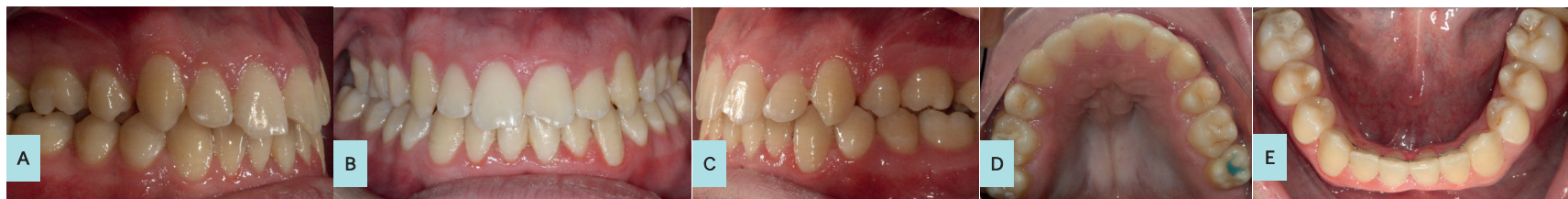


Figure 7. Intraoral photographs (A) right side, (B) frontal, (C) left side, (D) upper occlusal and (E) lower occlusal of the patient – end of OT.

## DISCUSSION

Given the lack of reports of OT in similar cases, the treatment results should be put into perspective and should not be extrapolated to all cases of SEMD.

It is important that doctors, dentists, orthodontists and maxillofacial surgeons are conscious of this type of pathology in order to be able to adapt the OT to each phenotype, that is, to the severity of craniofacial anomalies, functional pathologies, and existing aesthetic alterations, taking into account the patient expectation<sup>8</sup>. It is essential that these cases are treated in a multidisciplinary way.

## CONCLUSION

In the orthodontic treatment of this patient, the main objectives were accomplished. The fact that we were able to provide occlusion and improved facial appearance in this patient with SEMD allowed us to significantly improve his quality of life.

## BIBLIOGRAPHY

- 1- Tiller, G. E. *et al.* Dominant mutations in the type II collagen gene, COL2A1, produce spondyloepimetaphyseal dysplasia, Strudwick type. *Nat. Genet.* **2**, 983-989 (1995).
- 2- Amirfeyz, R., Taylor, A., Smithson, S. F. & Gargan, M. F. Orthopaedic manifestations and management of Spondyloepimetaphyseal dysplasia Strudwick type. *J. Pediatr. Orthop. Part B* **15**, 41-44 (2006).
- 3- Walter, K. *et al.* COL2A1-Related Skeletal Dysplasias With Predominant Metaphyseal Involvement. *Am. J. Med. Genet. Part A* **143A**, 161-167 (2007).
- 4- Isidor, B. *et al.* A New Form of Severe Spondyloepimetaphyseal Dysplasia: Clinical and Radiological Characterization. *Am. J. Med. Genet. Part A* **161**, 2645-2651 (2013).
- 5- M. Garza, R., C. Alyono, J., W. Dorfman, D. & C. Wan, D. Mandibular Distraction in a Patient with Type II Collagenopathy. *J. Craniofac. Surg.* **176**, 139-148 (2017).
- 6- Jhamb, T., Masood, H., Arigo, J. & Roussou, P. E. Orthodontic Treatment in a Patient With Kniest Dysplasia: A Case Study and Review of Literature. *Cleft Palate-Craniofacial J.* **56**, 1393-1403 (2019).
- 7- Spranger, J. W. Metaphyseal Chondrodysplasia. *Postgrad. Med. J.* **53**, 480-486 (1977).
- 8- Pineau, M., Farrow, E., Nicot, R. & Ferri, J. Achondroplasia: Orocraniofacial features and orthodontic-surgical management guidelines proposal. *J. Craniofac. Surg.* **29**, 2186-2191 (2018).