

# Double Gemination or Fusion of a Permanent Mandibular Second Molar: A Case Report

Glynn Dale BUCHANAN<sup>1</sup>, Sheree TREDOUX<sup>1</sup>, Ciska-Mari SCHOUWSTRA<sup>2</sup>, Chane NEL<sup>2</sup>, Mohamed Yasin GAMIELDIEN<sup>3</sup>

*Gemination and fusion are developmental conditions affecting the shape of teeth in both primary and permanent dentition. A 12-year-old girl presented for clinical assessment and the examination revealed an unusually shaped mandibular right second molar with irreversible pulpitis. Correlation of the intraoral and radiological appearance of this tooth suggested a diagnosis of either double gemination or fusion. The favourable position of the developing third molar supported early extraction of the abnormal second molar. The present report documents the clinical and radiological presentation of a mandibular second molar with an unusual developmental alteration in shape. Well-timed extraction therapy and good communication may reduce the need for unnecessary, complex treatment.*

**Key words:** dental anomalies, fusion, gemination, oral surgery, permanent molar  
*Chin J Dent Res 2021;24(3):199–202; doi: 10.3290/j.cjdr.b1964973*

Developmental alterations involving the shape of both primary and permanent human dentition are well documented<sup>1</sup>. These alterations may take the form of multiple tooth crowns, formed either from the splitting of a single tooth bud (gemination) or the fusion of two separate, adjacent tooth buds into a single, enlarged or joined tooth (fusion)<sup>2,3</sup>. Such developmental alterations in shape are reportedly more commonly found in permanent anterior maxillary teeth<sup>2,3</sup>.

Teeth with developmental alterations in shape may develop various dental complications including but not limited to dental caries, malocclusion, misalignment, arch asymmetry and functional problems<sup>4</sup>; however, historical definitions of gemination and fusion have

resulted in confusion and debate amongst investigators in cases where the precise pathogenesis (i.e., a split or a fusion) may be difficult to determine<sup>2</sup>. The present report describes the clinical and radiological presentation and management of a permanent mandibular second molar that appeared to have features resembling both gemination and fusion.

Ethical approval for the present case report was granted by the Research Ethics Committee of the Faculty of Health Sciences, University of Pretoria (#506/2020).

## Case report

A healthy 12-year-old girl presented to the Department of Maxillofacial and Oral Surgery at the University of Pretoria Oral and Dental Hospital, Pretoria, with the primary complaint of pain associated with chewing on the right side for several weeks. Clinical examination revealed a mandibular right second molar with additional tooth material situated buccally, resembling the crowns of two additional teeth (Fig 1). As her parents expressed a desire to retain the tooth, the patient was referred to the Division of Endodontics.

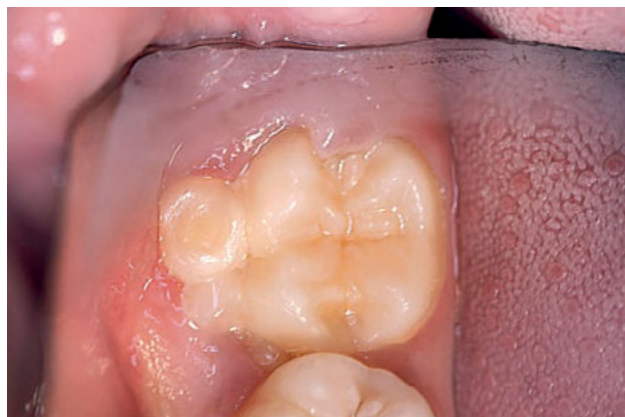Further evaluation revealed gingival inflammation associated with the mandibular right second molar and a small operculum covering the distal aspect of the crown. Periodontal probing depths were normal.

1 Department of Odontology, School of Dentistry, Faculty of Health Sciences, University of Pretoria, Pretoria, South Africa.

2 Department of Oral Pathology and Oral Biology, School of Dentistry, Faculty of Health Sciences, University of Pretoria, Pretoria, South Africa.

3 Department of Maxillofacial and Oral Surgery, School of Dentistry, Faculty of Health Sciences, University of Pretoria, Pretoria, South Africa.

**Corresponding author:** Dr Glynn Dale BUCHANAN, Room 4-12 Pretoria Oral and Dental Hospital, 31 Bophelo Road, Prinshof Campus, Riviera, Pretoria, 0002, South Africa. Tel: 27-12-319 2214. Email: glynn.buchanan@up.ac.za



**Fig 1** Clinical image of the mandibular right second molar.

Cold pulp sensibility testing (PulpoFluorane, Septodont, Saint-Maur-des-Fossés, France) revealed an exaggerated pulp response of over 10 seconds. The tooth displayed tenderness to percussion.

Periapical radiography and CBCT scanning images (ProMax 3D, Planmeca, Helsinki, Finland) were acquired. These revealed incomplete root development and open apices of the mandibular right second molar. A radiopaque lesion, suggestive of condensing osteitis, was present in relation to the apex. A complex internal canal morphology with confluent root canal systems was observed. The radicular pulp resembled the form of a single C-shaped root canal and was housed in a single root, but the pulp tissue extended coronally as three distinct divisions within the three joined crowns (Fig 2).

Although features resembling both gemination and fusion were demonstrated, the enlarged/joined tooth combined with the normal tooth count favoured a final diagnosis of double gemination. This diagnosis was based on a normal tooth count<sup>2,5</sup>; however, the possibility of a double fusion of the mandibular right second molar with two supernumerary teeth could not be definitively excluded.

Both endodontic treatment approaches and exodontia were considered in the initial treatment planning. The endodontic treatment options included root canal treatment with mineral trioxide aggregate (MTA) apexification and complete pulpotomy with reduction of the additional crown material to attempt apexogenesis and correct the crown morphology. An unfavourable crown–root ratio made the former option undesirable, and the latter was decided against due to the difficulty of adequate rubber dam isolation, uncertainty regarding long-term outcomes, continued root development and restorative prognosis.

Following a detailed conversation with the patient

and her parents and informed consent and assent, exodontia was performed under local anaesthesia. Mesial migration of the developing, unerupted third molar (with or without posteruptive orthodontic movement) was considered the treatment of choice.

CBCT scanning of the tooth without the supporting tissues was repeated following extraction, and ground sections of the dental hard tissue were obtained for microscopic examination (Fig 3). This helped the researchers to detail the complex internal and external root and canal morphology of the present case.

## Discussion

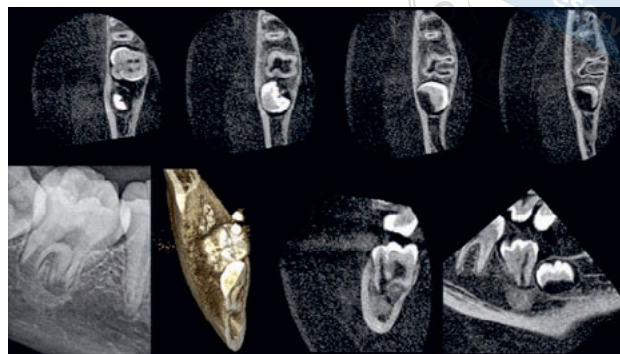
The supposition that gemination displays a single root canal and fusion displays several root canals<sup>6</sup> is controversial. The features used to distinguish gemination from fusion may, in certain instances such as the present case, be difficult to detect<sup>2,7,8</sup>. The prevalence of unilateral gemination in permanent dentition has been reported to be as low as 0.1%<sup>9</sup>.

In the event that fusion with supernumerary teeth is considered, there may be no definitive method for differentiation between gemination and fusion. The rule considering maintenance of the normal number of teeth no longer holds as fusion of a normal tooth with supernumeraries will still result in a normal tooth count<sup>6,10</sup>. Given the presence of features suggestive of both diagnoses, the present case presented a diagnostic dilemma.

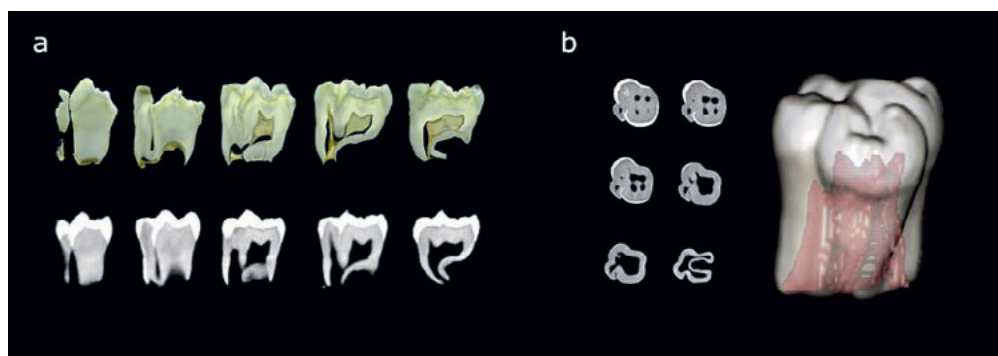
The authors could find only one other example in the literature where a permanent mandibular second molar demonstrated a somewhat similar presentation with multiple joined crowns in the posterior permanent dentition; however, this example was diagnosed as fusion of a permanent second molar with a supernumerary tooth and not gemination<sup>11</sup>. The present case displays the potential for double fusion of three separate teeth (one normal tooth and two supernumeraries) or double gemination of a single tooth in the posterior mandible. Triple teeth, also known as triplication defects (by fusion), have previously been described in both permanent and primary teeth, albeit reported exclusively in the anterior dentition<sup>12</sup>. Thus, gemination of posterior permanent teeth, whether unilateral or bilateral, is considered an uncommon finding<sup>13</sup>. No other reports diagnosed as double gemination of a posterior permanent tooth could be found in the existing English literature.

Depending on the tooth type and the perceived long-term treatment outcome, teeth with developmental alterations in shape may either be retained via multidisciplinary approaches or extracted<sup>2,7</sup>. In the present

**Fig 2** Periapical radiograph and CBCT slices demonstrating the complex internal and external morphology and apical pathoses of the mandibular right second molar.



**Fig 3 (a)** Ground sections and CBCT slices of the extracted mandibular right second molar demonstrating features of gemination and/or fusion. **(b)** Axial slices and 3D reconstruction demonstrating the complex internal and external anatomy of the extracted mandibular right second molar.



case, a simple solution, namely extraction with mesial drift of an unerupted third molar, avoided unnecessarily complex treatment which may have resulted in a questionable long-term prognosis and unnecessary trauma, particularly in a paediatric patient<sup>8</sup>.

CBCT has been previously reported to be highly effective in identifying tooth morphology and root canal systems<sup>14,15</sup>. The complex anatomy displayed in the present case was better visualised using 3D imaging, and this greatly facilitated both diagnosis and management of the case.

**Conclusion**

In conclusion, clinicians should be aware that developmental tooth alterations of shape, whether diagnosed as gemination, fusion or any other combination of these processes, exist and may affect any tooth. The treatment provided must ultimately be based on the specific clinical situation, good patient communication, informed consent and the perceived long-term outcome. The use of 3D imaging such as CBCT may greatly expedite treatment planning and patient communication in these uncommon and unusual cases.

**Conflicts of interest**

The authors declare no conflicts of interest related to this study.

**Author contribution**

Drs Glynn Dale BUCHANAN, Sheree TREDoux and Mohamed Yasin GAMIELDIEN were involved in the concept, design, writing and editing of the manuscript; Drs Ciska-Mari SCHOUWSTRA and Chane NEL contributed to the data collection, editing and writing. All authors are in agreement with the final version.

(Received Oct 05, 2020; accepted Feb 09, 2021)

**References**

1. Fekonja A. Prevalence of dental developmental anomalies of permanent teeth in children and their influence on esthetics. *J Esthet Restor Dent* 2017;29:276–283.
2. Neville B, Damm D, Allen C, Chi A (eds). *Abnormalities of teeth*. In: *Oral and Maxillofacial Pathology*, ed 4. St Louis: Elsevier Health Sciences, 2016:49–110.
3. Duncan WK, Helpin ML. Bilateral fusion and gemination: A literature analysis and case report. *Oral Surg Oral Med Oral Pathol* 1987;64:82–87.

4. Dhindsa A, Garg S, Damle SG, Opal S, Singh T. Fused primary first mandibular macromolar with a unique relation to its permanent successors: A rare tooth anomaly. *Eur J Dent* 2013;7:239–242.
5. Mader CL. Fusion of teeth. *J Am Dent Assoc* 1979;98:62–64.
6. Kelly JR. Geminatio, fusion, or both? *Oral Surg Oral Med Oral Pathol* 1978;45:655–656.
7. Nunes E, de Moraes IG, de Novaes PM, de Sousa SM. Bilateral fusion of mandibular second molars with supernumerary teeth: Case report. *Braz Dent J* 2002;13:137–141.
8. Neves AA, Neves ML, Farinhas JA. Bilateral connotation of permanent mandibular incisors: A case report. *Int J Paediatr Dent* 2002;12:61–65.
9. Gurbuz O, Ersen A, Dikmen B, Gumustas B, Gundogar M. The prevalence and distribution of the dental anomalies in the Turkish population. *J Anat Soc India* 2019;68:46–51.
10. Dang HQ, Constantine S, Anderson PJ. The prevalence of dental anomalies in an Australian population. *Aust Dent J* 2017;62:161–164.
11. Zhu M, Liu C, Ren S, Lin Z, Miao L, Sun W. Fusion of a supernumerary tooth to right mandibular second molar: A case report and literature review. *Int J Clin Exp Med* 2015;8:11890–11895.
12. Mohapatra A, Prabhakar AR, Raju OS. An unusual triplication of primary teeth-A rare case report. *Quintessence Int* 2010;41:815–820.
13. Sandeep S, Kumar GJ, Potdar S, et al. Rare case of gemination of mandibular third molar-A case report. *J Family Med Prim Care* 2020;9:2577–2579.
14. Matherne RP, Angelopoulos C, Kulild JC, Tira D. Use of cone-beam computed tomography to identify root canal systems in vitro. *J Endod* 2008;34:87–89.
15. Buchanan GD, Gamielidien MY, Tredoux S, Vally ZI. Root and canal configurations of maxillary premolars in a South African subpopulation using cone beam computed tomography and two classification systems. *J Oral Sci* 2020;62:93–97.