

# Evidence-Based Clinical Orthodontics



# Evidence-Based Clinical Orthodontics

*Edited by*

**Peter G. Miles, BDS<sub>c</sub>, MDS**

Senior Lecturer  
Department of Orthodontics  
University of Queensland School of Dentistry  
Brisbane, Australia

Visiting Lecturer  
Graduate Program in Orthodontics  
Seton Hill University Center for Orthodontics  
Greensburg, Pennsylvania

**Daniel J. Rinchuse, DMD, MS, MDS, PhD**

Professor and Associate Director  
Graduate Program in Orthodontics  
Seton Hill University Center for Orthodontics  
Greensburg, Pennsylvania

**Donald J. Rinchuse, DMD, MS, MDS, PhD**

Professor and Program Director  
Graduate Program in Orthodontics  
Seton Hill University Center for Orthodontics  
Greensburg, Pennsylvania



**Quintessence Publishing Co, Inc**

Chicago, Berlin, Tokyo, London, Paris, Milan, Barcelona,  
Istanbul, Moscow, New Delhi, Prague, São Paulo, and Warsaw

# Dedication

This book is dedicated to our families, teachers, mentors, students, and in particular to our patients. More importantly, this book is dedicated to you, the reader, the present and future of orthodontics.

## Library of Congress Cataloging-in-Publication Data

Evidence-based clinical orthodontics / edited by Peter G. Miles, Daniel J. Rinchuse, Donald J. Rinchuse.

p. ; cm.

Includes bibliographical references and index.

ISBN 978-0-86715-564-8

I. Miles, Peter G. II. Rinchuse, Daniel J. III. Rinchuse, Donald Joseph.

[DNLM: 1. Malocclusion--therapy. 2. Dental Bonding. 3. Evidence-Based Dentistry. 4. Orthodontics--methods. WU 440]

617.6'43--dc23

2012017471

5 4 3 2 1



© 2012 Quintessence Publishing Co Inc

Quintessence Publishing Co Inc  
4350 Chandler Drive  
Hanover Park, IL 60133  
www.quintpub.com

All rights reserved. This book or any part thereof may not be reproduced, stored in a retrieval system, or transmitted in any form or by any means, electronic, mechanical, photocopying, or otherwise, without prior written permission of the publisher.

Editor: Leah Huffman  
Design: Ted Pereda  
Production: Sue Robinson

Printed in China

---

# Contents

In Memoriam *vii*

Foreword *viii*

Preface *ix*

Contributors *x*

- 1** | **Introduction: Evidence-Based Clinical Practice** 1  
Nikolaos Pandis, Daniel J. Rinchuse, Donald J. Rinchuse, James Noble
  - 2** | **Early Intervention: The Evidence For and Against** 7  
Daniel J. Rinchuse, Peter G. Miles
  - 3** | **Bonding and Adhesives in Orthodontics** 17  
Peter G. Miles, Theodore Eliades, Nikolaos Pandis
  - 4** | **Wires Used in Orthodontic Practice** 31  
William A. Brantley
  - 5** | **Class II Malocclusions: Extraction and Nonextraction Treatment** 47  
Peter G. Miles, Daniel J. Rinchuse
  - 6** | **Treatment of Class III Malocclusions** 61  
Peter Ngan, Timothy Tremont
  - 7** | **Subdivisions: Treatment of Dental Midline Asymmetries** 89  
Peter G. Miles
  - 8** | **Evidence-Based Use of Orthodontic TSADs** 107  
James Noble
-

9 | The Effectiveness of Treatment Procedures for Displaced and Impacted Maxillary Canines 127

Tiziano Baccetti

10 | Orthodontically Induced Inflammatory Root Resorption 137

M. Ali Darendeliler, Lam L. Cheng

11 | Orthodontics and TMD 157

Donald J. Rinchuse, Sanjivan Kandasamy

12 | Orthodontic Retention and Stability 167

Daniel J. Rinchuse, Peter G. Miles, John J. Sheridan

13 | Accelerated Orthodontic Tooth Movement 179

Eric Liou

Index 201

---

# In Memoriam



**Dr Tiziano Baccetti (1966–2011)**

Chapter 9 of this book, “The Effectiveness of Treatment Procedures for Displaced and Impacted Maxillary Canines,” was written by Dr Tiziano Baccetti. This may well have been his last scholarly work; he completed this chapter just a few weeks before his untimely and tragic death on November 25, 2011, at the young age of 45. While posing for a photograph on a historic bridge in Prague, Czech Republic (he was the Keynote Speaker at the 9th International Orthodontic Symposium held November 24 to 26, 2011), he slipped on old stonework at the base of one of the saintly statues that decorate the bridge and fell 8 meters to the rocks below. It was the Charles Bridge—Ponte Carlo in Italian, the same name as Tiziano’s beloved father, who knows that bridge well and for whom the picture was intended.

Tiziano authored over 240 scientific articles on diverse orthodontic topics. He has been described by those who knew him best as a “superman.” This is supported by what he had accomplished in his short life. In 2011, Tiziano gave the Salzmann Lecture at the 111th Annual American Association of Orthodontists Session on “Dentofacial Orthopedics in Five Dimensions.” In concluding his presentation, he explained how his grandfather in Italy had told him as a young boy that one day he would “find his America” and fulfill his dreams. Tiziano said at the end of his lecture, “I have found my America, fulfilled my dreams.” Few, even with a long life, can say that they have fulfilled their dreams, their ambitions. We can be comforted that Tiziano did.

We feel fortunate that we can share Tiziano’s excellent chapter with our readers.

# Foreword

This text can serve as a reference guide for research and studies in many difficult clinical areas where there is a lack of evidence-based information. The distinguished editors are all involved in education, research, and practice, and they have invited other well-known experts and authorities to critically evaluate the literature and topics such as early treatment, extraction and nonextraction, Class III treatment, asymmetries, temporary skeletal anchorage devices (miniscrews), impacted canines, root resorption, temporomandibular disorders, retention, stability, and accelerated orthodontic tooth movement. These are all critical areas in the full scope of clinical orthodontic practice. I am sure that every orthodontist will learn from the enormous contributions provided so clearly in this text. The first chapter introduces and defines *evidence-based clinical practice*. Every other chapter provides evidence for and against each controversy and concludes with a summary and points to remember.

The topics are covered in detail with extensive illustrations, cases, diagrams, and references. All discussions are based on current research findings, and when evidence is not available, it is clearly stated as such. As the editors point out, the purpose of this book is to provide the orthodontist with an evidence-based perspective on selected important orthodontic topics and to stimulate practicing orthodontists to reflect on their current treatment protocols from an evidence-based view. In the future, clinical decisions should be based ideally on evidence rather than personal opinion, and treatment strategies should be proven to be both efficacious and safe.

I am very honored and privileged to have been asked to present this foreword because this text should be the evidence-based text for EVERY orthodontist and student.

Robert L. Vanarsdall, Jr, DDS  
Assistant Dean for Advancement of Dental Specialties  
Professor, Department of Orthodontics  
University of Pennsylvania



# Preface

The specialty of orthodontics has evolved from an apprenticeship to a learned profession requiring academic training. Nevertheless, many in our profession still cling to biased beliefs and opinions rather than embracing evidence-based practice. When evidence conflicts with what experience has taught, it becomes even more difficult for such practitioners to change their views. Hence, there is complacency and resistance within the profession to adopt evidence-based treatments.

Most orthodontists experience at least enough treatment success to support a practice. Yet treatment success does not necessarily equate with treatment efficacy or even verification of an appropriate diagnosis. This success can be the biggest obstacle to change. Clinical success may be associated with a multitude of appliances, strong belief in a particular philosophy, financial motivations (even unethical ones such as inappropriate phase I treatments), the difficulties involved in switching from an experience-based practice to an evidence-based practice, and a simple lack of understanding of evidence-based clinical practice (described in chapter 1). In our profession, therefore, treatment efficacy is currently evaluated broadly in relation to benefits, costs, risks, burden, and predictability of success with various treatment options.

No longer can the role of evidence-based decision making be shunned and ignored in favor of clinical experience alone. From both ethical and legal perspectives, sound clinical judgment must be based on the best evidence available. Today a paternalistic view, whereby the doctor knows what is best for the patient without soliciting patient input, is unacceptable. Patients have a right to autonomy and input into their treatment provided that it does no harm.

The 2001 Institute of Medicine report estimated that it takes an average of 17 years for new, effective medical research findings to become standard medical practice.<sup>1</sup> For example, there was a reemergence of the use of self-ligating brackets in the mid-1990s amid claims not only of faster ligation but also of quicker and more comfortable treatment. Several prospective clinical trials began to be published in 2005 and then two systematic reviews in 2010 concluded

that in fact there was no difference in discomfort or treatment time when self-ligating brackets were used compared with conventional brackets. Yet despite the weight of evidence, these claims of faster treatment times and less discomfort are still made and supported by many orthodontists. As Dr Lysle Johnston, Jr, pointed out, our specialty tends to have a pessimistic attitude toward evidence and a minimal capacity to judge its quality. But what effect does this pessimism have on our patients? Can we as an orthodontic profession really wait 17 years to incorporate emerging quality evidence into our clinical practices?

With the exponential growth of information in today's world, how does the busy orthodontist evaluate evidence that will affect his or her practice? This book was conceived out of a need for evidence regarding relevant clinical topics and ongoing controversies in orthodontics such as early treatment, bonding protocols, treatment of Class II and Class III malocclusions, asymmetries, impacted canines, root resorption, retention, and accelerated tooth movement. We have done our best to incorporate the best evidence available regarding these topics, and hopefully this book will show you not only how to judge quality evidence but also why it is so important to implement it.

## Reference

1. Institute of Medicine. *Crossing the Quality Chasm: A New Health System for the 21st Century*. Washington, DC: National Academies Press, 2001.

## Acknowledgments

This book would not have been possible without the support of the publisher, Quintessence, and the tedious and dedicated work of our editor, Leah Huffman. We especially want to thank all of the contributing authors who have taken the time to write chapters in this book.

# Contributors

**Tiziano Baccetti**, DDS, PhD\*

Assistant Professor  
Department of Orthodontics  
University of Florence  
Florence, Italy

Thomas M. Graber Visiting Scholar  
Department of Orthodontics and Pediatric Dentistry  
University of Michigan School of Dentistry  
Ann Arbor, Michigan

**William A. Brantley**, PhD

Professor and Director  
Graduate Program in Dental Materials Science  
Division of Restorative, Prosthetic, and Primary Care  
Dentistry  
College of Dentistry  
The Ohio State University  
Columbus, Ohio

**Lam L. Cheng**, BDS, MDS, MOrth RCS (ED),  
MRACD (Ortho)

Honorary Associate Professor  
Department of Orthodontics  
Faculty of Dentistry  
The University of Sydney  
Sydney, Australia

**M. Ali Darendeliler**, BDS, PhD, Dip Orth, Certif Orth,

Priv Doc, MRACD (Ortho)  
Professor and Chair  
Department of Orthodontics  
Faculty of Dentistry  
The University of Sydney  
Sydney, Australia

**Theodore Eliades**, DDS, MS, Dr Med, PhD

Professor and Director  
Department of Orthodontics and Pediatric Dentistry  
University of Zurich  
Zurich, Switzerland

**Sanjivan Kandasamy**, BDS, BSc Dent, Doc Clin

Dent, MOrth RCS, MRACDS  
Clinical Senior Lecturer  
Department of Orthodontics  
University of Western Australia  
Perth, Australia

Adjunct Assistant Professor  
Department of Orthodontics  
University of Saint Louis  
St Louis, Missouri

**Eric Liou**, DDS

Director  
Department of Orthodontics and Craniofacial Dentistry  
Chang Gung Memorial Hospital  
Taipei, Taiwan

Program Director  
Department of Orthodontics  
Graduate School of Craniofacial Medicine  
Chang Gung University  
Taoyuang, Taiwan

\*Deceased.

**Peter G. Miles**, BSc, MDS  
Senior Lecturer  
Department of Orthodontics  
University of Queensland School of Dentistry  
Brisbane, Australia

Visiting Lecturer  
Graduate Program in Orthodontics  
Seton Hill University Center for Orthodontics  
Greensburg, Pennsylvania

Private practice  
Caloundra, Australia

**Peter Ngan**, DMD  
Professor and Chair  
Department of Orthodontics  
West Virginia University School of Dentistry  
Morgantown, West Virginia

**James Noble**, BSc, DDS, MSc, FRCD(C)  
Visiting Lecturer  
Division of Orthodontics  
University of Manitoba  
Winnipeg, Manitoba  
Canada

Visiting Clinical Lecturer  
Graduate Program in Orthodontics  
Seton Hill University Center for Orthodontics  
Greensburg, Pennsylvania

**Nikolaos Pandis**, DDS, MS, Dr med dent, MSc  
Private practice  
Corfu, Greece

**Daniel J. Rinchuse**, DMD, MS, MDS, PhD  
Professor and Associate Director  
Graduate Program in Orthodontics  
Seton Hill University Center for Orthodontics  
Greensburg, Pennsylvania

**Donald J. Rinchuse**, DMD, MS, MDS, PhD  
Professor and Program Director  
Graduate Program in Orthodontics  
Seton Hill University Center for Orthodontics  
Greensburg, Pennsylvania

**John J. Sheridan**, DDS, MSD  
Clinical Associate Professor  
School of Orthodontics  
Jacksonville University  
Jacksonville, Florida

**Timothy Tremont**, DMD, MS  
Clinical Associate Professor  
Department of Orthodontics  
West Virginia University School of Dentistry  
Morgantown, West Virginia

Private practice  
White Oak, Pennsylvania



Peter G. Miles  
BDS, MDS

Theodore Eliades  
DDS, MS, Dr Med, PhD

Nikolaos Pandis  
DDS, MS, Dr med dent, MSc

## CHAPTER

# 3

# Bonding and Adhesives in Orthodontics

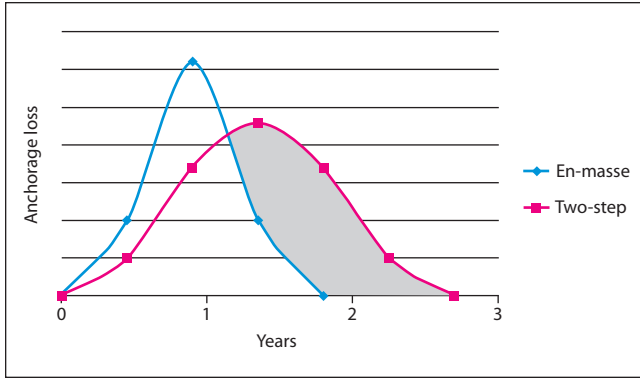
## Introduction

Treatment efficiency in orthodontics relies on several factors, including accurate bracket positioning and effective bonding of brackets to the enamel. The advent of direct bonding of orthodontic attachments to the etched enamel surface as first described by Newman<sup>1</sup> was a major advance in orthodontic treatment. He described a technique using 40% phosphoric acid for 60 seconds, and this technique remained basically unchanged for another 25 years. Shorter etch times were later examined in clinical trials, and no significant difference in bond failure rates were found between 60-second and 15-second etch times.<sup>2,3</sup> Hence, over time we have seen a reduction in practitioner acid etch times from 60 seconds in 1986 to an average of 30 seconds by 1996, which has remained the same up to 2008.<sup>4</sup> Despite this reduction in etch times, the reported average bond failure in orthodontic offices has remained at 5%; however, this data comes from a survey,<sup>4</sup> so it may well underestimate the true breakage rate. Bracket debonding during treatment is inconvenient and costly to both the orthodontist and the patient. In our own practices, our goal is to have as low a bond failure risk as possible, so it is preferable to be 5% or lower. As demonstrated in Table 3-1, a practice with an average of 250 case starts per year and an average treatment time of 24 months can save 4 repairs per day (or 776 per year) if the bond failure risk can be reduced from 10% to 2%.

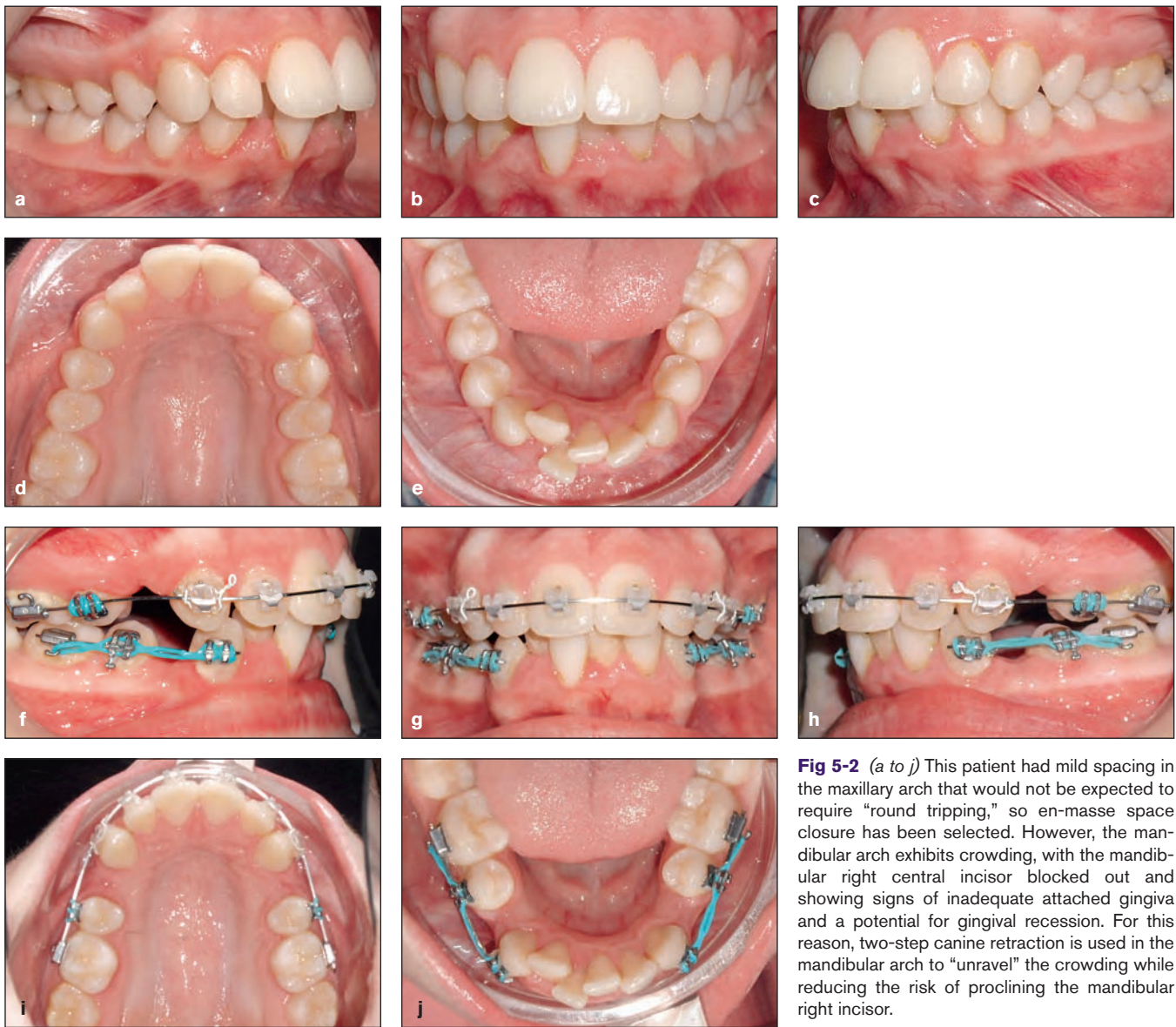
So what steps should we take and what information can we gather from the literature to help us in such a basic skill as the bonding of orthodontic brackets? Some may choose to base their choice of adhesive or primer on the myriad of laboratory studies that have been published over the years. However, there are a number of problems with this approach. The American Dental Association Council on Dental Materials reported that most laboratory bonding

studies cannot predict the clinical behavior of the adhesives tested.<sup>5</sup> Some of the limitations of in vitro studies include that most in vitro studies are conducted within a short time after bonding (often within 24 hours), so the potential influence of the oral environment on the bonding material cannot be taken into account. Thermocycling cannot replicate the effects of bond degradation by saliva, and the loading rates are slow compared with chewing. Bond strength can also be affected clinically by pH and microbial degradation.<sup>6,7</sup> In a systematic review of bond studies, many factors were found to play a significant role in the final bond strength measured in laboratory studies.<sup>8</sup> For example, water storage can decrease bond strength by an average 10.7 MPa, each second of curing time with a halogen light can increase bond strength by 0.077 MPa, and each millimeter per minute of greater crosshead speed of the Instron machine increases bond strength by 1.3 MPa. The authors of the review concluded that many in vitro studies fail to report test conditions that could significantly affect the outcome.<sup>8</sup>

Some clinicians will judge or select an adhesive from a laboratory study based on its mean or median bond strength without also considering the variation. For example, Fig 3-1 shows two curves representing bond strengths in MPa for two adhesives, both having the same mean bond strength of 13 MPa, which is considered adequate for the orthodontic bonding of brackets. However, if we pick an arbitrary bond strength of about 8 MPa, as suggested by Reynolds<sup>9</sup> as the minimum (6 to 8 MPa) required bond strength to survive clinically, we can see that the adhesive represented by the blue curve has substantially fewer brackets that could potentially fail compared with the adhesive represented by the pink curve. For these reasons, even a well-controlled, statistically valid laboratory study of bond strength should merely serve as a precursor to a controlled clinical investigation. It is important for the clinician to realize that most bond strength tests are



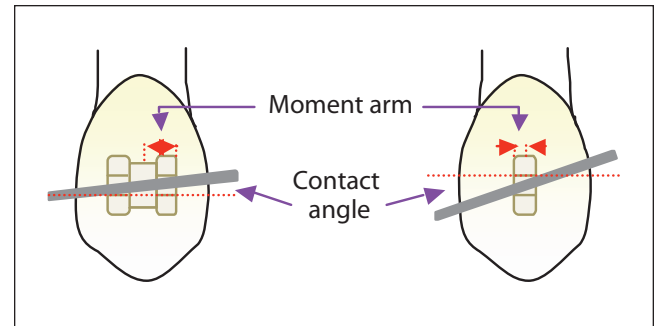
**Fig 5-1** Plotting normal curves based on the average and standard deviation data from Heo et al.<sup>8</sup> Note that a sizeable proportion of the two-step cases moved slower than the en-masse cases (shaded area under the pink two-step curve). En-masse space closure saved an average 4.8 months (0.4 years) of treatment time with no noticeable difference in anchorage loss.



**Fig 5-2 (a to j)** This patient had mild spacing in the maxillary arch that would not be expected to require “round tripping,” so en-masse space closure has been selected. However, the mandibular arch exhibits crowding, with the mandibular right central incisor blocked out and showing signs of inadequate attached gingiva and a potential for gingival recession. For this reason, two-step canine retraction is used in the mandibular arch to “unravel” the crowding while reducing the risk of proclining the mandibular right incisor.



**Fig 5-3** The width of the bracket determines the size of the moment arm (one-half the bracket width) and the contact angle between the wire and the bracket corner. The wider bracket thereby requires less force to generate the moment necessary to upright the root. (Adapted from Proffit.<sup>13</sup>)



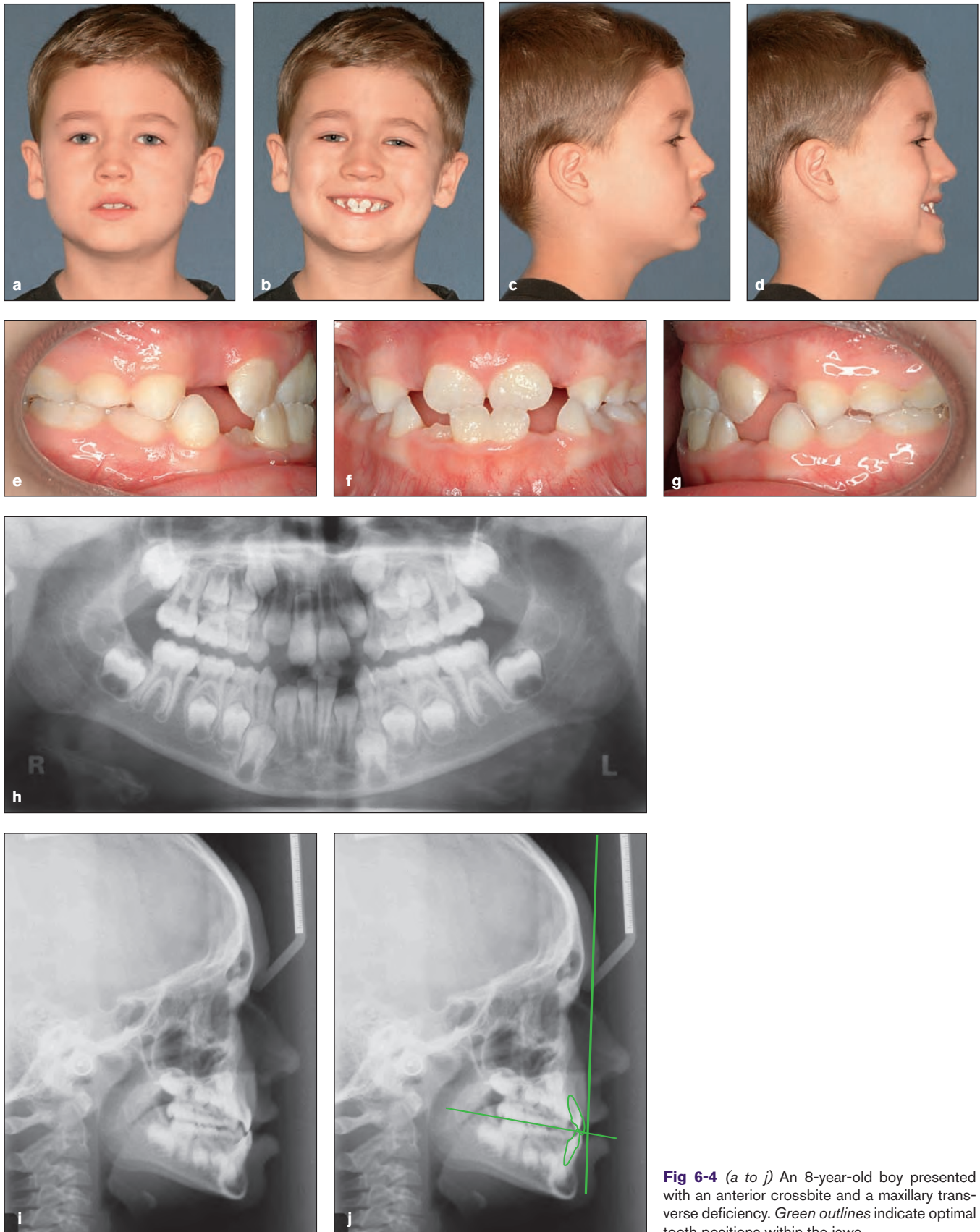
the spaces were 0.9 years (1 standard deviation = 0.6 to 1.3 years) in the en-masse group versus 1.3 years (1 standard deviation = 0.6 to 2.0 years) in the two-step retraction group (Fig 5-1). Two-step retraction demonstrated no benefit in terms of anchorage loss and a tendency to take longer than en-masse retraction. No difference in anchorage loss was also found in a pilot randomized controlled trial (RCT) comparing en-masse retraction with two-step retraction.<sup>9</sup> Therefore, en-masse retraction is the treatment of choice for efficiency. However, there are individual cases in which initial sectional canine retraction or a trapped coil on a continuous archwire is preferred to alleviate anterior crowding (Fig 5-2), such as when not “unraveling” the crowded anterior teeth first would “round trip” them and possibly create periodontal concerns. This treatment philosophy is supported by Burstone,<sup>10</sup> who argued that separating the retraction of canines from that of the incisors makes little sense because all six teeth can be retracted at once with relatively low forces; the only patients for whom separate canine retraction is appropriate, he continued, are those with anterior crowding as a result of arch-length problems. With the trend toward longer treatment times with two-step retraction, there may be an associated risk of greater root resorption. However, in a clinical trial investigating this, no clinically or statistically significant difference could be found.<sup>11</sup>

Some believe that tipping mechanics during canine retraction may be more efficient than bodily retraction. However, a split-mouth study in 14 subjects found that bodily retraction was faster than tipping because of less time spent uprighting the roots, with anchorage loss similar in both groups (17% to 20% or 1.2 to 1.4 mm).<sup>12</sup> The authors also found that the use of a Nance button did not provide absolute anchorage. A previous study had found no difference in the rate of canine retraction but did not measure tipping or time spent uprighting.<sup>13</sup> The split-mouth study also recorded a greater anchorage loss with the tipping mechanics. Another option when retracting canines is to use either a single wing or a twin (also called a *Siamese*) bracket. The advantage of a wider bracket in this situation is that it allows better tip control because it is easier to generate the required moments needed to bring the roots parallel to one another at extraction sites.<sup>14</sup>

When sliding mechanics are used, a wider bracket has a smaller contact angle and requires less force to generate the moment during space closure (Fig 5-3). Conversely, single wing and narrow brackets, including some self-ligating bracket designs, potentially require more force or demonstrate a greater resistance to sliding because of the greater contact angle and smaller moment arm. This is supported by two clinical trials evaluating the rate of maxillary canine retraction and en-masse space closure.<sup>15,16</sup> Both studies found a conventional twin bracket resulted in a slightly faster rate of space closure (1.2 mm/month) compared with the slightly narrower self-ligating brackets (1.1 mm/month and 0.9 mm/month).

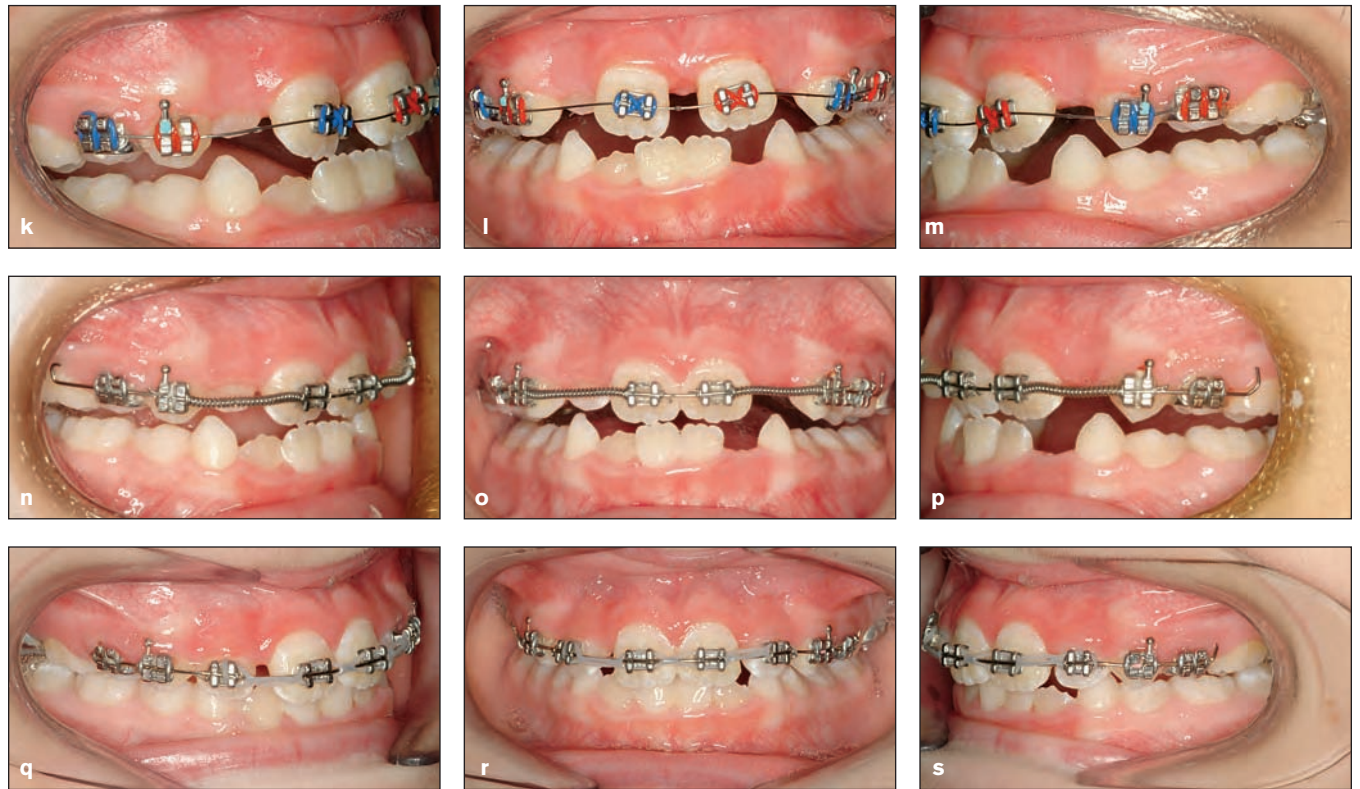
## Anchorage

As previously described, it appears from the best evidence available that there is no advantage to two-step retraction over en-masse retraction when it comes to anchorage. However, there are other options available for reinforcing anchorage, such as transpalatal arches (TPAs), headgear, and, more recently, temporary skeletal anchorage devices (TSADs) or miniscrews. When examining the effect of the TPA during extraction treatment, Zablocki et al<sup>17</sup> found no significant effect on either the anteroposterior or vertical position of the maxillary first molars. In a study comparing TPAs, headgears, and TSADs, the TSADs and headgears helped to control anchorage during leveling and alignment while the TPA group experienced anchorage loss (mean of 1.0 mm;  $P < .001$ ).<sup>18</sup> However, during the space closure phase, only the TSAD group was stable. Overall, the anchorage loss per incisor retraction was 2% for the TSAD group, 15% for the headgear group, and 54% for the TPA group. A potential confounder in this study was that compliance with headgear wear was not measured, so compliance was assumed when molars remained stable and non-compliance suspected when they were not, representing what would happen clinically. Other authors found a similar 1.2-mm anchorage saving with 1.4 mm greater retraction of the anterior teeth when using skeletal anchorage (miniplates, miniscrews, or microscrews),<sup>19</sup> while others have found palatal implants to be at least as effective as



**Fig 6-4** (a to j) An 8-year-old boy presented with an anterior crossbite and a maxillary transverse deficiency. *Green outlines* indicate optimal tooth positions within the jaws.





**Fig 6-4** (cont) (k to s) Treatment with a Hyrax expander and fixed appliances.

## Early Orthodontic Treatment

### Indications

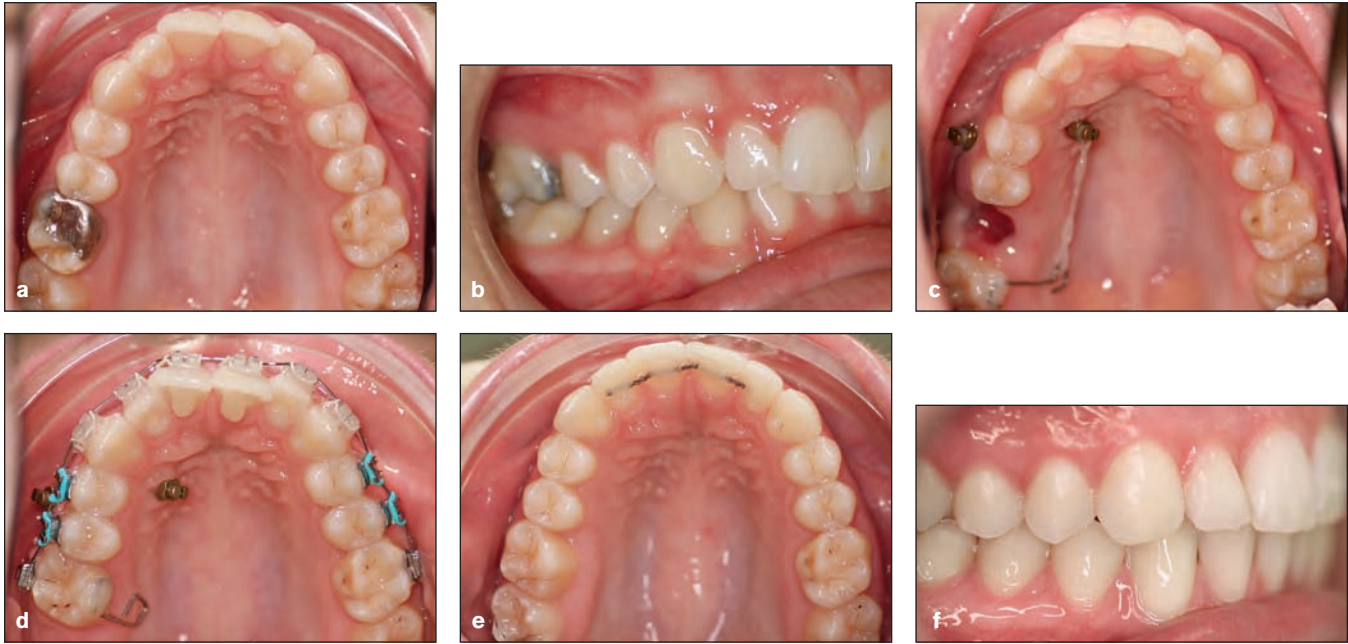
Objectives of early Class III treatment may include (1) preventing progressive hard or soft tissue damage, such as enamel abrasion and bony or gingival dehiscence; (2) improving skeletal discrepancies and possibly avoiding orthognathic surgery; (3) improving occlusal function; (4) developing arch length; and (5) improving dental and facial esthetics.<sup>17</sup> Common conditions warranting early treatment are anterior or posterior crossbites with or without functional shifts and blocked-out maxillary lateral incisors. Favorable factors for successful early treatment include mild to moderate skeletal disharmony, no familial mandibular prognathism, a convergent facial type, symmetric condylar growth, and expected good cooperation. Patients and parents should be informed that unpredictable dysplastic skeletal growth in the future may necessitate orthognathic surgery despite early intervention.

Borrie and Bearn<sup>18</sup> published a systematic review of 45 articles to identify the appropriate method for anterior crossbite correction. The authors found low-level evidence, and no statistical methods were employed for the analysis. They stated that higher-level studies are necessary before definitive conclusions can be made.

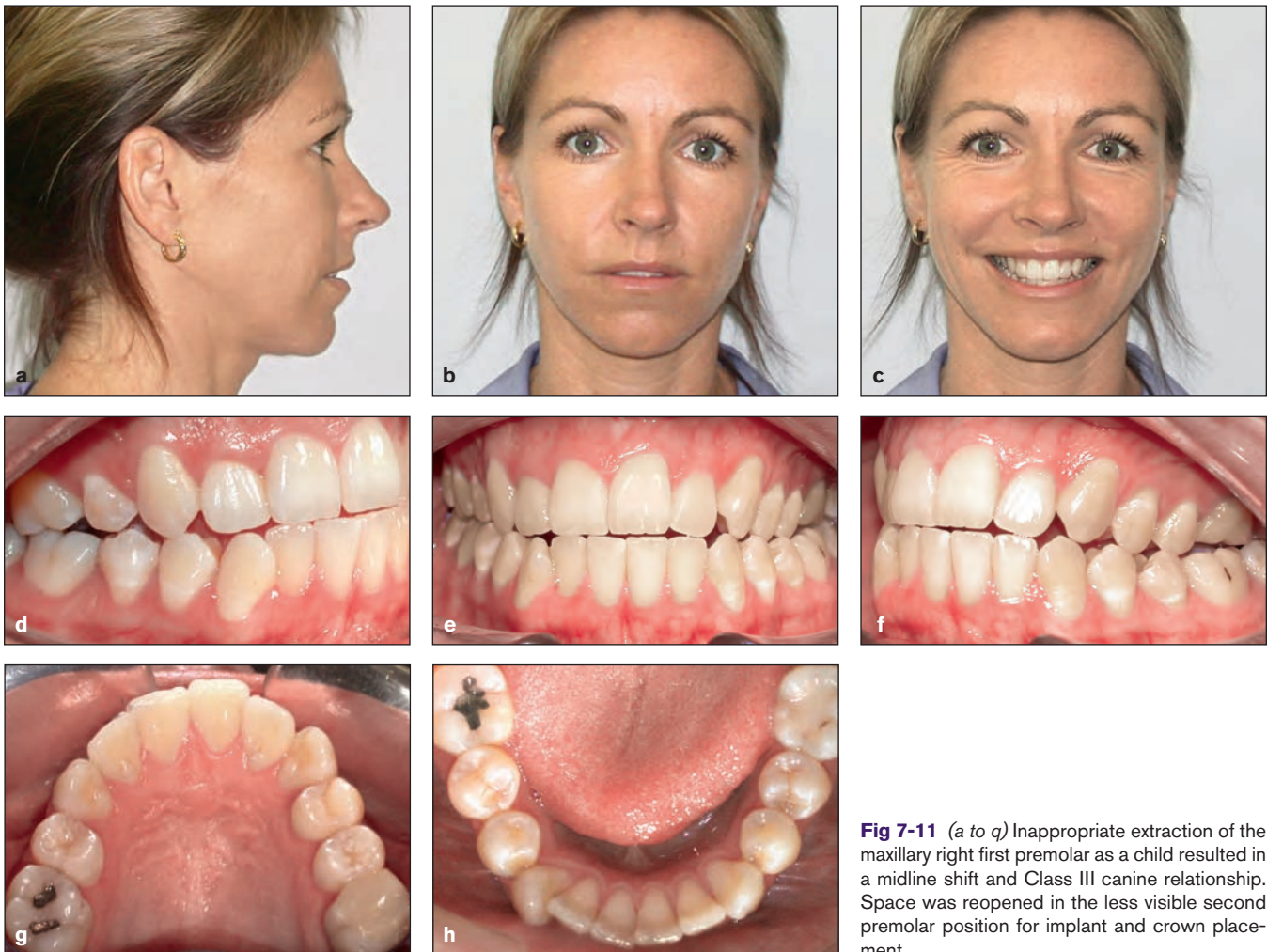### Maxillary expansion and partial fixed appliances

Figure 6-4 shows a patient who presented with an anterior crossbite and a maxillary transverse deficiency. Associated with the transverse discrepancy is inadequate arch length for the unerupted maxillary lateral incisors. This particular patient had a near optimal anteroposterior positioning of the maxilla and mandible, as indicated by the relationship of the optimal incisors to the GALL (Fig 6-4j). The panoramic radiograph (Fig 6-4h) showed that the lateral incisors were ready to erupt but were blocked out of the arch. The primary first molars had minimal root resorption and, along with the permanent first molars, provided good anchor units for rapid maxillary expansion (RME).

A Hyrax expander was inserted, and brackets were bonded to the central incisors and primary canines (maxillary premolar brackets were used on the primary canines) (Figs 6-4k to 6-4m). Skeletal expansion was accomplished with two turns per day for 10 days. The expander was tied off, and a 0.012-inch nickel-titanium (Ni-Ti) wire was inserted from the right primary first molar through the right canine, central incisors, left canine, and left primary first molar. Six weeks later, a 0.018-inch Ni-Ti wire was inserted, and a Ni-Ti open coil was compressed between the incisors and the primary canines (Figs 6-4n to 6-4p). The archwire was cinched distal to the primary first molar brackets to direct



**Fig 7-10** (a to d) The maxillary right first molar required extraction, so miniscrew anchorage was used to protract the second molar into its place. This was done prior to placement of full fixed appliances to reduce the overall time in full braces. (e and f) The second molar has taken the place of the maxillary right first molar, and the third molar erupted and aligned to replace the second molar.



**Fig 7-11** (a to q) Inappropriate extraction of the maxillary right first premolar as a child resulted in a midline shift and Class III canine relationship. Space was reopened in the less visible second premolar position for implant and crown placement.

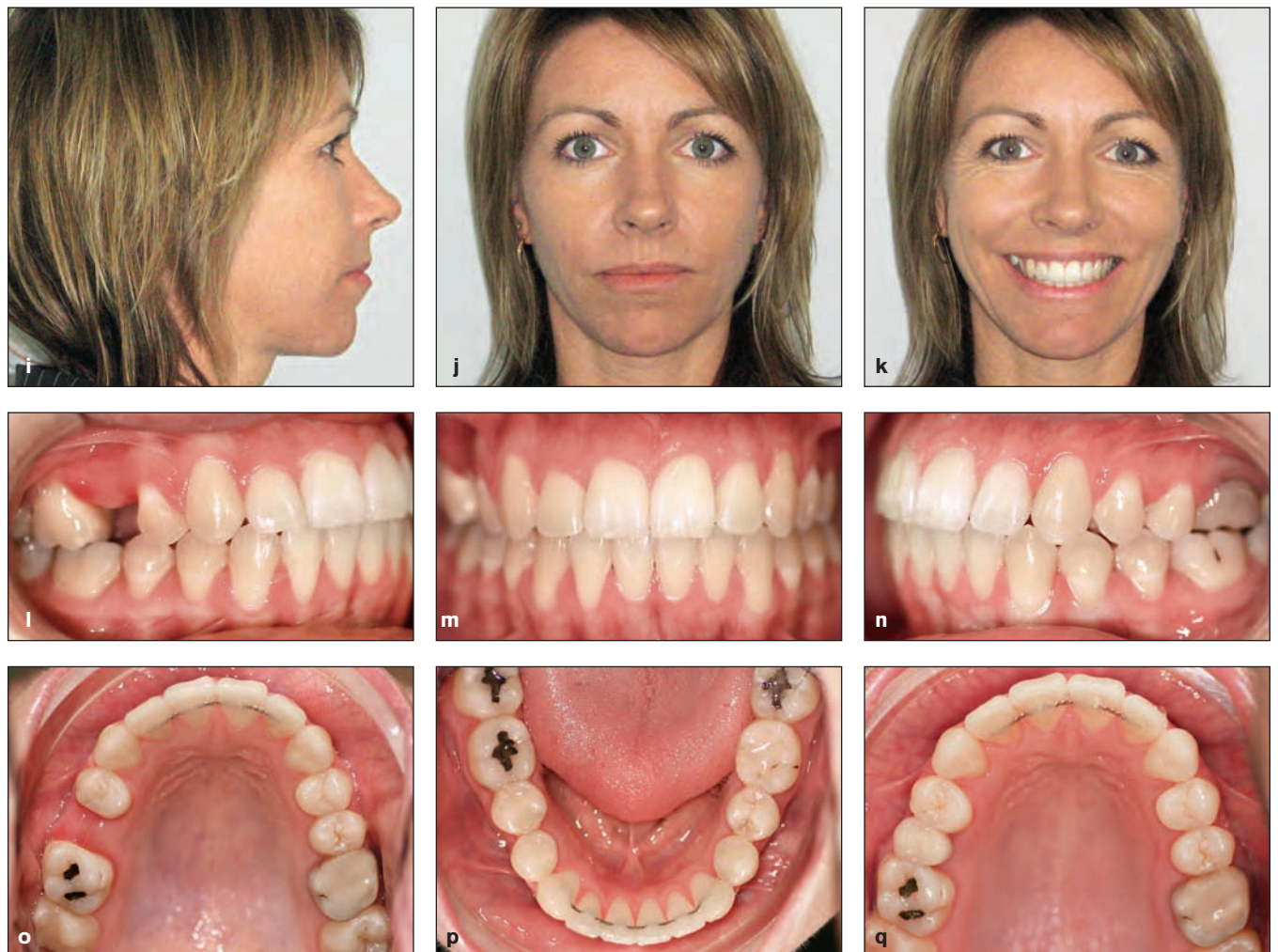

## Other Asymmetries

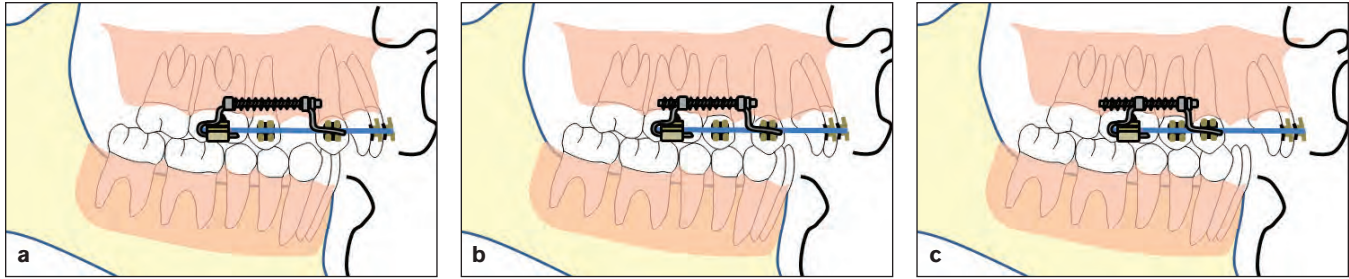
Asymmetries can also be created by the inappropriate extraction of teeth in crowded dentitions, by congenitally absent teeth or impacted teeth, or by the loss of teeth. For example, the patient in Fig 7-10 had an internally resorbing maxillary right first molar that required extraction. Because she had only minor crowding in a Class I occlusion, a nonextraction approach was preferred. After consultation with the family, miniscrews were placed to protract the second molar into the first molar space. After 6 months and six visits, the extraction space was closed with no movement of the anterior teeth (Figs 7-10c and 7-10d). Full

braces were then placed to commence aligning the remaining teeth and permit root uprighting on the second molar. Use of the miniscrew maintained the canine relationship, thereby preventing an asymmetry from developing in this case.

Inappropriate removal of a tooth can result in an asymmetry that was not originally present. The patient in Fig 7-11 had a blocked-out maxillary right premolar removed as a child, which resulted in a reasonable alignment but also created a Class III subdivision malocclusion with the maxillary midline skewed to the right side. In this case, treatment would involve either extraction of three other teeth to match or the reopening of the space for prosthetic replacement, which was the option chosen by the patient.



**Fig 7-11** (cont)



**Fig 13-2** (a to c) Schematic illustrations of maxillary rapid canine retraction through distraction of the PDL with an intraoral distraction device.

## Surgical-Assisted Approach

Surgical-assisted accelerated orthodontic tooth movement is currently the most effective technique experimentally and clinically in accelerating orthodontic tooth movement. This approach includes the techniques of rapid canine retraction through distraction of the PDL,<sup>91–95</sup> rapid canine retraction through distraction of the dentoalveolus,<sup>96–98</sup> corticotomy-assisted rapid orthodontic tooth movement,<sup>99,100</sup> and corticision.<sup>101</sup>

### Rapid canine retraction through distraction of the PDL

This technique is beneficial in treating adult patients, for whom treatment duration may be a deciding factor toward the acceptance of treatment. The rate of orthodontic tooth movement in adults, particularly in the beginning of treatment, is slower than in adolescents.<sup>102–104</sup> Two basic components, the alveolar bone and PDL, are encountered during orthodontic tooth movement and affect its rate based on factors such as cellular activity,<sup>105,106</sup> mechanical strength of the PDL,<sup>107</sup> and bony resistance of alveolar bone.<sup>108–110</sup> In the initial stage of tooth movement, Young's modulus (stiffness) of the PDL is higher in adults than in adolescents, and this might produce a reduction in the biologic response of the PDL, leading to a delay in the early stage of tooth movement.<sup>107</sup> However, Young's modulus decreases markedly 4 to 7 days after application of orthodontic force and does not last through the entire period of orthodontic tooth movement.<sup>111</sup> The rate of tooth movement is shown to depend on the state of alveolar bone resistance, and it is faster in alveolar bone with loose bone trabeculae.<sup>108–110,112</sup>

#### Mechanism

By incorporating a surgical procedure on the interseptal bone distal to the canine at the time of extraction of the first premolar, the resistance on the pressure side of canine retraction is reduced, thus enhancing rapid canine retraction through distraction of the PDL<sup>91</sup> (Fig 13-2). This approach is based on the bifocal distraction osteogenesis technique. On the pressure side, the canine–interseptal

bone complex is transported distally inside of the extraction socket. On the tension side, it is a distraction of the PDL followed by osteogenesis and ossification.<sup>91</sup>

#### Clinical and surgical procedures

Bonding and banding are performed before extraction of the first premolars. The first molars and second premolars are the anchor units. A triple tube is welded on the buccal side of the canine band and the molar band. No archwire or active appliance is placed on the anchor units before extraction, but a segment of Ni-Ti archwire is placed in the anterior teeth for the initial alignment and activation of the periodontal cells. The period of predistraction preparation is 1 to 2 months.

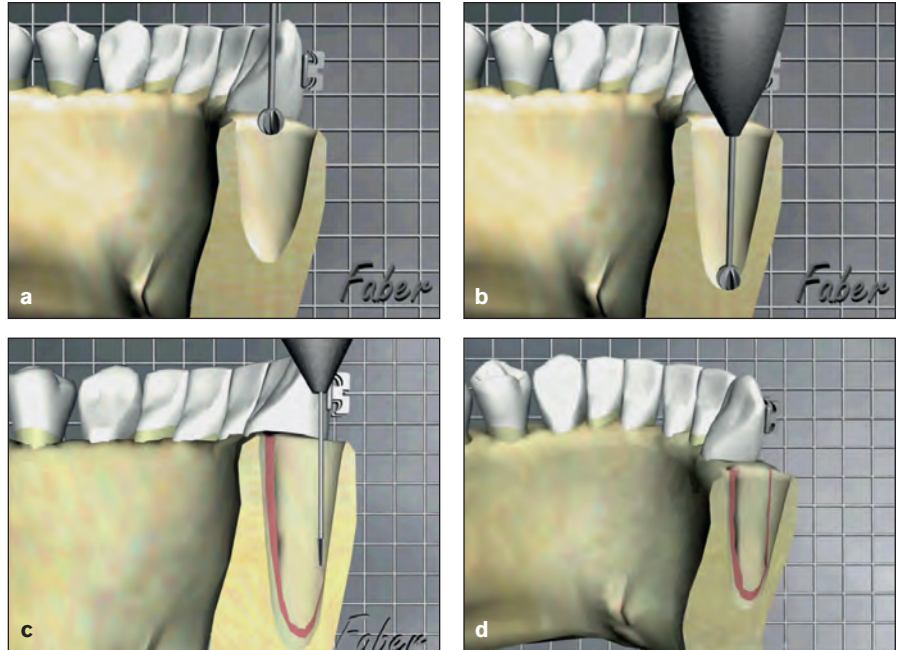
At the time of the first premolar extractions, surgery is performed with surgical burs to undermine and reduce the thickness of the interseptal bone distal to the canine. The surgery is then performed inside the extraction socket of the first premolar without a mucoperiosteal flap and osteotomy. The length of the canine can be either obtained directly from cone beam computed tomography (CBCT) or estimated by applying the ratio of the premolar length (which can be measured after extraction) to the canine length on the periapical film.

The socket of the first premolar is deepened to the same depth as that of the canine with a 4-mm carbide surgical round bur (Figs 13-3a and 13-3b). Then a cylinder carbide surgical bur is used to reduce the thickness of the interseptal bone distal to the canine. This procedure is critical to the distraction results. The interseptal bone is better reduced to 1.0 to 1.5 mm in thickness. The last step is to undermine the interseptal bone distal to the canine. A 1-mm carbide fissure bur is used to make two vertical grooves, running from the socket bottom to the alveolar crest, on the mesiobuccal and mesiolingual corners inside the extraction socket. These two vertical grooves extend and join obliquely toward the base of the interseptal bone (Figs 13-3c and 13-3d).

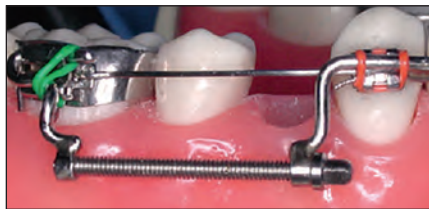
A custom-made intraoral distraction device (Fig 13-4) is delivered immediately after the extraction and surgical procedures. It is activated 0.5 mm/day right after the surgery until the canine is distracted into the desired position (Fig 13-5). Patients are seen once a week during the distraction procedure.



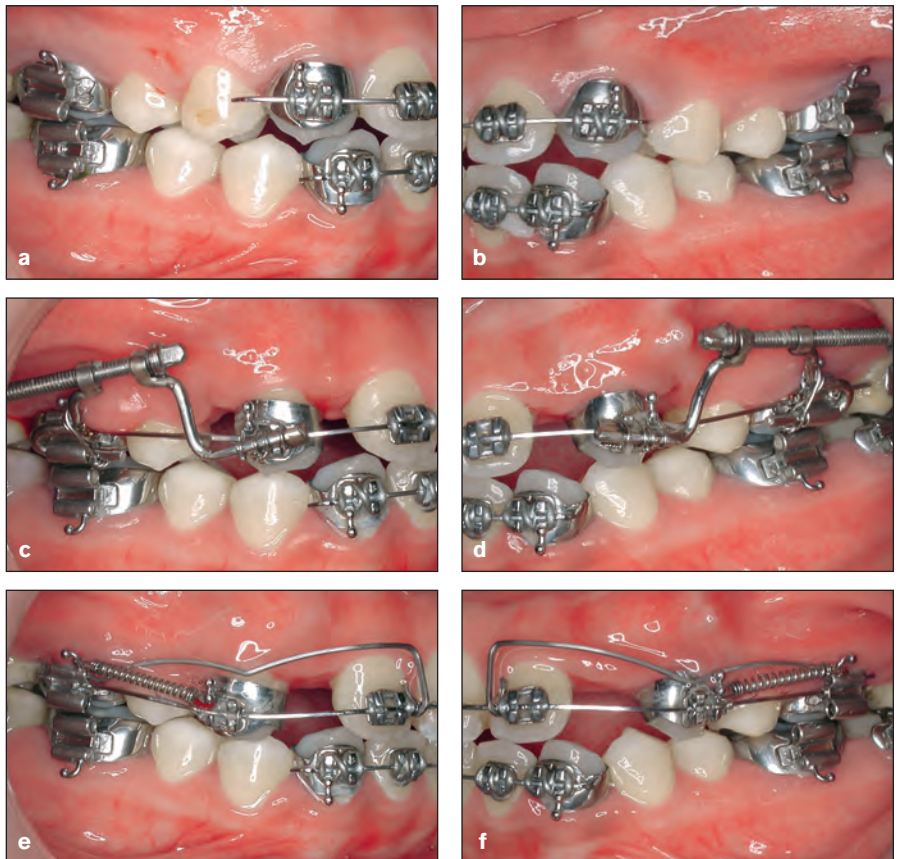
**Fig 13-3** Schematic illustrations of the surgical procedure for undermining the interseptal bone distal to the canine in rapid canine retraction through distraction of the PDL. (a and b) The socket of the first premolar is deepened to the same depth as that of the canine with a 4-mm carbide surgical round bur. (c and d) A 1-mm carbide fissure bur is used to make two vertical grooves, running from the socket bottom to the alveolar crest, on the mesiobuccal and mesiolingual corners inside the extraction socket, and these two vertical grooves extend and join obliquely toward the base of the interseptal bone.



**Fig 13-4** The intraoral distraction device for rapid canine retraction through distraction of the PDL.



**Fig 13-5** The clinical progress of maxillary rapid canine retraction through distraction of the PDL in a 23-year-old woman. The canine retraction was completed in 3 weeks. (a and b) Before distraction. (c and d) After 2 weeks of distraction. (e and f) After 3 weeks of distraction.



# Index

Page numbers followed by “f” indicate figures; those followed by “t” indicate tables; those followed by “b” indicate boxes

## A

Absolute anchorage, 107  
Accelerated orthodontic tooth movement  
  baseline bone metabolism effects on, 193  
  biomechanical approach for, 179–180  
  bone density effects on, 193  
  bone metabolism–density guided orthodontics, 193–194  
  direct electric current stimulation for, 180, 180f  
  low-level laser therapy for, 180–181  
  overview of, 179  
  pharmacologic approach for, 181–183  
  physiologic approach for, 180–181  
  prostaglandins for, 181–182  
  relaxin for, 182–183  
  self-ligating bracket system for, 179–180  
  submucosal injection of platelet-rich plasma for, 191–193, 192f  
  surgical-assisted approaches for  
    corticision, 189f–190f, 189–191  
    rapid canine retraction, 183–186, 183f–186f  
    selective alveolar decortication, 186–189, 187f  
Acid etching  
  description of, 17–18  
  enamel, 21–22  
  hydrofluoric, 20–21  
  microetching before, 20  
Active ligatures, 50  
Active self-ligating brackets, 179  
Adhesives  
  bond strength of, 17, 18f  
  fillers in, 24  
  fluoride-releasing, 22  
  light-cured, 23f, 24–25  
  selection of, 17  
Air abrasion, 20  
Air embolus/emphysema, 121  
Alveolar bone density, 193  
Anchorage  
  absolute, 107  
  bicortical, 111  
  direct, 112, 112f  
  in extraction treatment, 49–50  
  history of, 107  
  indirect, 112, 113f–117f  
  nomenclature associated with, 108  
  options for, 107  
  orthodontically induced inflammatory root resorption affected by, 141  
  temporary skeletal anchorage devices for. *See* Temporary skeletal anchorage devices.  
Angle's paradigm, 175  
Anterior crossbite, 68f–69f, 71, 72f–73f, 76f–77f, 82f–83f  
Anterior open bite, 122–123, 190f, 191  
Anterior positioning appliance, 162  
Appliances. *See* Fixed appliances; Functional appliances.

Arch crowding, 78f–79f  
Arch expansion. *See also* Mandibular arch.  
  limits of, 12f  
  maxillary, 10–13, 12f  
Arch length, 14  
Arch perimeter, 167–168  
Archwire, 41–43  
Articulators, 161–162  
Asymmetries, midline. *See* Midline asymmetries.  
Austenitic wires  
  nickel-titanium, 35, 38  
  stainless steel, 33–34

## B

Baseline bone metabolism, 193  
Begg appliances, 140  
Behavioral therapies, 164  
Beta-titanium orthodontic wires, 32, 40–41  
Bicortical anchorage, 111  
Biocatalytic fuel cell, 180, 180f  
Biopsychosocial model, 158t, 162  
Bleached enamel, bonding to, 19–20  
Blue light, 25–26  
Bonded expansion appliance, 67  
Bonding. *See also* Adhesives.  
  air abrasion before, 20  
  to bleached enamel, 19–20  
  to ceramic, 20–21  
  enamel preparation for, 20  
  failure of, 25  
  history of, 17  
  indirect, 23  
  microetching before, 20  
  to porcelain, 20–21  
  pumice prophylaxis before, 18, 20  
  saliva contamination avoidance during, 19  
Bone density, 193  
Bone metabolism–density guided orthodontics, 193–194  
Brackets  
  canine retraction using, 49, 49f  
  gingivally offset, 22  
  self-ligating, 179–180  
Buccal alveolus, maxillary, 111

## C

Canine(s)  
  palatally displaced. *See* Palatally displaced canines.  
  palatally impacted. *See* Palatally impacted canines.  
  tie-backs, 47  
Canine retraction. *See also* En-masse retractions.  
  Class II malocclusion treated with, 47, 48f, 49  
  rapid  
    through dentoalveolus distraction, 184–186  
    through periodontal ligament distraction, 183f, 183–184, 185f  
Canine-protected occlusion, 159  
Cementoenamel junction, 111

- Cementum, in orthodontically induced inflammatory root resorption, 137, 138f
- Centric occlusion, 157
- Centric relation, 160–161
- Ceramics
- bonding to, 20–21
  - types of, 21
- Cervical vertebral maturation, 53, 127, 128f
- Children
- Class III malocclusion in, 64f–66f, 68f–69f
  - eruption guidance appliances for, 54, 54f
- Chin cup therapy, 71, 72f–73f
- Chinese nickel-titanium orthodontic wires, 35
- Circumferential supracrestal fiberotomy, 168
- Class I malocclusion, 63, 116f
- Class II malocclusion
- early interventions for, 7–10, 52–53
  - extraction treatment of
    - anchorage options, 49–50
    - appointment intervals, 51–52
    - canine retraction, 47, 48f, 49
    - canine tie-backs, 47
    - en-masse retraction, 47, 48f, 49
    - premolars, 50
    - space closure, 50–51
  - functional appliances for, 7–8, 52–53
  - maxillary expansion for, 10–13
  - nonextraction treatment of
    - molar distalization, 55–58, 56f–57f
    - overview of, 52
    - second phase of treatment predictions, 54–55
    - timing of, 52–55
- Class III malocclusion
- anteroposterior jaw positions, 62, 62f
  - craniofacial complex aberrations associated with, 62
  - dental etiology of, 62, 63f
  - differential diagnosis of, 61–64
  - early treatment for
    - benefits of, 61
    - chin cup therapy, 71, 72f–73f
    - indications for, 65
    - maxillary expansion and partial fixed appliances, 65–66, 65f–66f
    - objectives of, 65
    - protraction face mask therapy, 66–71, 68f–69f
  - non-surgical treatment of
    - extraction, 73–77, 73f–77f
    - nonextraction, 77, 77f–79f
  - pseudo skeletal, 63
  - skeletal etiology of, 62–63, 63f
  - surgical treatment of
    - mandibular surgery, 82f–83f, 83
    - maxillary and mandibular surgery, 84f–85f, 85f
    - maxillary surgery, 80, 80f–81f
    - presurgical orthodontics, 79
    - three-dimensional planning, 79
  - types of, 62, 63f
- Clinical decision making, 1
- Cobalt-chromium wires, 32, 35
- Cochrane Collaboration, 1, 42
- Comprehensive early treatment, 8
- Cone beam computed tomography
- anchorage value of root surface area evaluated using, 193
  - Class II subdivision midline asymmetry, 90
  - site evaluation before temporary skeletal anchorage device placement, 111
- Conventional etch and prime technique, 18–19
- Copper nickel-titanium orthodontic wires, 37, 39, 43
- Corticision, 189f–190f, 189–191
- Council on Scientific Affairs, 12
- Craniofacial sutures, 67
- Crossbite
- anterior, 68f–69f, 71, 72f–73f, 76f–77f, 82f–83f
  - posterior, 10–12, 11f, 15, 76f–77f, 82f–83f
- Crowding
- arch, 78f–79f
  - arch perimeter decreases as cause of, 167–168
  - corticision for accelerating tooth alignment in patient with, 190f
  - E-space for, 13–14, 14t
  - intercanine width decreases as cause of, 167–168
  - mandibular incisor, 168–169
  - maxillary expansion for. *See* Maxillary expansion.
  - maxillary midline deviation with, 103
- C-terminal telopeptide of type I collagen, 193
- Cytokines, 181
- ## D
- Decalcification, 21–22, 22f
- Dental midline asymmetries. *See* Midline asymmetries.
- Dentoalveolus distraction, rapid canine retraction through, 184–186
- Deprogramming appliances, 160–161
- Diagnosis, articulators use for, 161–162
- Direct anchorage, 112, 112f
- Direct bonding, 17
- Direct electric current stimulation, 180, 180f
- Disc displacements, 162
- Displacement
- maxillary canines, 127. *See also* Palatally displaced canines.
  - temporomandibular joint disc, 162
- Distalization, molar, 55–58, 56f–57f
- Dolichofacial patients, 14
- ## E
- Early caries lesions, 21, 22f
- Early interventions/treatments
- Class II malocclusion, 7–10, 52–53
  - Class III malocclusion. *See* Class III malocclusion, early treatment of.
  - functional appliances for, 7–8, 15
- Edgewise appliances, 140
- Eicosanoids, 181
- Elastic bending stiffness, 32
- Elastic modulus, 32, 38, 40
- Elastomeric chain, 50
- Elgiloy wires, 35
- Enamel
- acid etching of, 21–22
  - air abrasion of, 20
  - bleaching of, 19–20
  - microetching of, 20
- Endothelial growth factors, 191
- En-masse retractions
- description of, 47, 48f, 49
  - space closure in, 50–51
- Eruption guidance appliances, 54
- E-space, 13–15, 14t. *See also* Leeway space.
- Etching. *See* Acid etching.
- Evidence categories, 1, 3t
- Evidence-based clinical practice, 4–5
- Evidence-based dentistry, 1
- Evidence-based orthodontics, 4
- Extractions
- Class II malocclusion treated with. *See* Class II malocclusion, extraction treatment of.
  - Class III malocclusion treated with, 73f–77f, 73–77
  - inappropriate, midline asymmetry caused by, 100f–101f, 101
  - mandibular incisor, 104, 104f–105f
  - orthodontically induced inflammatory root resorption affected by, 147
  - premolar. *See* Premolar extractions.
  - primary maxillary canine, 129–130, 132
  - third molars, 168–170
- Extrusive force, 143, 144f

**F**

- Face mask therapy, for Class III malocclusion, 66–71, 68f–69f
- Facial sutures, 67
- Fiberotomy, circumferential supracrestal, 168
- Filled sealers, 22
- Fixed appliances. *See also specific appliance.*
  - Class II spring correctors used with, 55, 56f–57f
  - functional appliance components mimicked in, 58, 59f
  - midline asymmetries treated with, 98f–99f
  - partial, for Class III malocclusion, 65–66, 65f–66f
- Fixed bonded retainers, 170–171, 171f
- Flexural rigidity, 32
- Fluoride
  - adhesives that release, 22
  - nickel-titanium orthodontic wires affected by, 39
  - orthodontically induced inflammatory root resorption prevention and, 149–150
- Force
  - extrusive, 143, 144f
  - intermittent versus continuous, 141–142, 142t
  - interproximal, 168
  - intrusive, 143, 143f
  - orthodontically induced inflammatory root resorption affected by, 139, 141–147, 142f–146f, 142t
  - tipping, 144f, 145
- Full-thickness flaps, 186
- Functional appliances
  - Class II malocclusion treated with, 7–8, 52–53
  - components of, 55
  - early treatment using, 7–8, 15, 52
  - fixed appliance mimicking of components of, 58, 59f
  - myofunctional, 54, 54f
  - skeletal maturation determinations, 53
  - timing of use, 53
- Functional occlusion, 159–160

**G**

- Gingival crevicular fluid, 150
- Gingivally offset brackets, 22
- Glass-ionomer cement, 22
- Goal anterior limit line, 62, 73–75, 77
- GRADE approach, 2, 3f
- Growth factors, 191

**H**

- Halogen lamps, 24–25
- Hawley-type retainers, 171–172, 172f, 174
- Headgear
  - anchorage use of, 49, 52
  - Class II malocclusion treated with, 7–8, 52
  - interarch appliances and, 55
  - palatally displaced canines treated with, 130, 130f
- Hydrofluoric acid etching, 20–21
- Hyrax rapid palatal expansion appliance, 70, 75f, 81f

**I**

- Immediate loading, of temporary skeletal anchorage devices, 118–119
- Impacted canines. *See Palatally impacted canines.*
- Indirect anchorage, 112, 113f–117f
- Indirect bonding, 23
- Informed consent, 153
- Infrazygomatic crest, 111
- Interarch appliances, 55
- Inter canine width, 167–168
- Internal derangements, 162
- Interproximal enameloplasty, 174–175
- Interproximal force, 168
- Intraoral distraction device, 184, 185f
- Intrusive force, 143, 143f

**J**

- Japanese nickel-titanium orthodontic wires, 35–36

**L**

- Lacebacks, 47, 50
- Lambert's law, 24
- Lamps, polymerization, 24–26
- Laser lights, 24
- LED light curing units, 24–25
- Leeway space, 13–14, 14t, 54. *See also E-space.*
- Light curing units, 24
- Light-cured adhesives
  - curing sources for, 24
  - degree of cure of, 24–25
  - indirect bonding use of, 23f
  - LED light curing units for, 24–25
  - polymerization initiation in, 24
- Lower lingual arch, 14–15
- Low-intensity pulsed ultrasound, 151
- Low-level laser therapy, 180–181

**M**

- Malocclusion
  - Class I, 63, 116f
  - Class II. *See Class II malocclusion.*
  - Class III. *See Class III malocclusion.*
- Mandible
  - chin cup effects on, 71
  - prognathism of, 82f–83f
  - protrusive, 71
  - temporary skeletal anchorage device placement in, 111
- Mandibular arch
  - E-space preservation, 13–14
  - space-creation strategies in, 12t
- Mandibular incisors
  - crowding of, 168–169
  - extraction of, 104, 104f–105f
- Mandibular intercanine width, 10
- Mandibular lingual arch, 14–15
- Mandibular setback surgery, 83f, 85f
- Mandibular splints, 163, 163f
- Martensitic nickel-titanium, 35, 38
- Maxilla
  - anteroposterior deficiency of, 68f–69f, 76f, 80f–81f
  - anteroposterior position of, 62, 62f
  - buccal alveolus, 111
  - temporary skeletal anchorage device placement in, 111
  - transverse deficiency of, 78f–79f, 84f–85f
- Maxillary canines
  - buccal displacement of, 127
  - cervical vertebral maturation stages for eruption of, 127, 128f
  - displacement of, 127. *See also Palatally displaced canines.*
  - eruption of, 127, 131
  - impaction of
    - palatal. *See Palatally impacted canines.*
    - prevalence of, 127
  - midline asymmetry caused by, 115f
- Maxillary expansion
  - Class II malocclusion treated with, 10–13, 15
  - Class III malocclusion treated with, 65–66, 65f–66f
  - indications for, 10
  - postretention stability of, 11
  - rapid, 12, 130–132
- Maxillary protraction
  - case study of, 66–71, 68f–69f
  - treatment timing for, 70–71
  - utility of, 71
- Maxillary transverse deficiency, 64f
- Maximal intercuspation, 157



- Meta-analyses, 2, 2t
- Microetching, 20
- Midline asymmetries
- acceptance amount of, 89
  - Class II subdivisions
    - cone beam computed tomography study of, 90
    - definition of, 90
    - Type 1, 90, 92f–93f, 93–94, 95f
    - Type 2, 90, 96f–97f, 97
    - Type 1/Type 2, 98, 98f–99f
  - Class III subdivisions, 102f–105f, 103–104
  - inappropriate tooth extractions as cause of, 100f–101f, 101
  - maxillary canine as cause of, 115f
  - overview of, 89–90
  - tooth extractions as cause of, 100f, 101
  - treatment approaches for
    - early interventions, 91, 91f–92f
    - overview of, 90
- Midline shifts, 89, 90f
- Miniscrew implants, 107
- Modulus of resilience, 32
- Molar(s)
- distalization, 55–58, 56f–57f
  - intrusion, 123, 123f
  - third. *See* Third molars.
- Moment of inertia, 32
- Mucoperiosteal flap reflection, 189
- Mutually protected occlusion, 159
- Myofunctional appliance, 54, 54f
- N**
- Narrative reviews, 1–2
- Neutral axis, 32
- Nickel-titanium coil springs, for space closure, 50–51, 51f
- Nickel-titanium orthodontic wires
- austenitic, 35, 38
  - copper, 37, 39, 43
  - corrosion of, 39
  - elastic behavior of, 32
  - elastic modulus of, 38
  - fluoride effects on, 39
  - heating curve for, 36f
  - history of, 35
  - martensitic, 35, 38
  - mechanical properties of, 35–36, 36f
  - nonsuperelastic, 42
  - superelastic, 35–36, 39, 42–43
  - surface modification of, 39
  - surface roughness of, 38
  - thermoelastic effect of, 38
- Nitinol, 35
- Nonextraction treatments
- Class II malocclusion treated with. *See* Class II malocclusion, nonextraction treatment of.
  - Class III malocclusion treated with, 77, 77f–79f
  - orthodontically induced inflammatory root resorption affected by, 147
- O**
- Occlusal contacts, 159, 175
- Occlusal interference, 159
- Occlusal splints, 163, 163f
- Orthodontic force. *See* Force.
- Orthodontic wire. *See* Wire.
- Orthodontically induced inflammatory root resorption
- animal studies of, 149
  - apical region predilection of, 142, 148
  - with Begg appliances, 140
  - biologic markers of, 150
  - blood and saliva test for, 150–151
  - case report of, 151–152, 151f–152f
  - cementum properties in, 137, 138f
  - clinical consequences of, 148
  - craters caused by, 147–148, 148f
  - definition of, 137
  - early treatments as risk factor for, 53
  - with edgewise appliances, 140
  - extraction protocol effects on, 147
  - factors that affect
    - appliances, 140–141
    - description of, 137, 138b
    - direction of force, 142–147
    - extrusive force, 143, 144f
    - force magnitude, 139
    - intermittent versus continuous force, 141–142, 142t
    - intrusive force, 143, 143f
    - rotational force, 146, 146f
    - tipping force, 144f, 145
    - tooth movement distance, 139
    - torque movement, 145, 145f
    - treatment duration, 139
    - treatment techniques, 140–141
  - fluoride effects on, 149–150
  - gingival crevicular fluid tests, 150
  - low-intensity pulsed ultrasound effects on, 151
  - nonextraction protocol effects on, 147
  - prevention of, 149–152
  - radiographic monitoring of, 149
  - repair of, 147–148, 147f–148f
  - risk reduction for, 149, 153
  - with sequential aligners, 141
  - skeletal anchorage effects on, 141
  - space closure concerns, 50
  - treatment planning considerations for, 151–152
- Osteoprotegerin, 150–151
- Osteotomy, 184–185
- Overjet correction
- alignment and, 55
  - twin block for, 8, 9f
- P**
- Palatally displaced canines
- cephalometric superimposition of, 131f
  - definition of, 127
  - dental anomalies associated with, 128, 129b, 129f
  - eruption of, 130, 133f
  - interceptive therapies for
    - cervical headgear, 130, 130f
    - description of, 130–131
    - initiation of, 128
    - outcome evaluations of, 132–133
    - primary canine extraction, 129–130, 132
    - rapid maxillary expansion, 130–133
    - studies on, 132t
    - transpalatal arch, 131–132
  - palatally impacted canine progression of
    - cervical vertebral maturation stage as predictor of, 127, 128f
    - description of, 129, 132
    - prevalence of, 127
    - risk indicators for, 128
- Palatally impacted canines
- orthodontic-surgical repositioning of, 133
  - palatally displaced canine progression to
    - cervical vertebral maturation stage as predictor of, 127, 128f
    - description of, 129, 132
    - “tunnel technique” for, 133–134, 134f
- Palate
- rapid palatal expander, 10, 70
  - temporary skeletal anchorage device placement in, 111
- Partial fixed appliances, for Class III malocclusion, 65–66, 65f–66f

- Passive self-ligating brackets, 179
- Patient self-directed therapies, 163–164
- Percent degree of cure, 24
- Periodontal ligament
- prostaglandin E<sub>2</sub> stimulation of bone deposition in, 181
  - rapid canine retraction through distraction of, 183f, 183–184, 185f
- Periodontal pockets, 169
- Periodontally accelerated osteogenic orthodontics, 186–189, 187f–188f
- Phosphoproteins, 150
- Piezocision, 189
- Pitch, 89
- Plasma lamps, 24, 26
- Platelet-rich plasma, 191–193, 192f
- Platelets, 191
- Polymerization
- blue light for, 25–26
  - lamps used in, 24–26
  - light intensity variation, 23–24
- Porcelain
- bonding to, 20–21
  - fracture of, 21
  - microetching of, 21
- Posselt's theory, 161
- Posterior crossbite, 10–12, 11f, 15, 76f–77f, 82f–83f
- Pre-drilled temporary skeletal anchorage devices, 110–111
- Premolar extractions, 175, 184
- Class II malocclusion treated with, 50
  - Class III malocclusion treated with, 73
- Prostaglandins, 181–182
- Protraction face mask therapy, for Class III malocclusion, 66–71, 68f–69f
- Protrusion, mandibular, 71
- Pseudo skeletal class III malocclusion, 63
- Pumice, 18, 20
- ## R
- Randomized clinical trials
- Class II malocclusion early treatment, 7–8, 52–53
  - description of, 1
  - en-masse retraction, 49
  - gingivally offset brackets, 22
  - Hawley-type retainers, 171–172
  - interceptive therapies, 130
  - lower lingual arch, 14
  - occlusal appliances, 163
  - self-etching primers, 18
  - third molar extractions, 169
  - vacuum formed retainers, 172–174
- Range, of orthodontic wires, 32
- RANKL. See Receptor activator of nuclear factor kappa B ligand.
- Rapid canine retraction
- through dentoalveolus distraction, 184–186
  - through periodontal ligament distraction, 183f, 183–184, 185f
- Rapid maxillary expansion
- description of, 12
  - palatally displaced canines treated with, 130–132
- Rapid palatal expander, 10, 70
- Recapturing of temporomandibular joint discs, 162
- Receptor activator of nuclear factor kappa B ligand, 150–151, 194
- Recommendations, 2–4, 3f
- Rectangular wires, 31, 33
- Relaxin, 182–183
- Resilience, 32
- Retainers
- combined removable and fixed, 174
  - fixed bonded, 170–171, 171f
  - Hawley-type, 171–172, 172f, 174
  - thermoplastic, 170, 172–174, 173f–174f
  - vacuum formed, 172–174, 173f–174f
- Retention
- fixed bonded retainers for, 170–171, 171f
  - Hawley-type retainers for, 171–172, 172f
  - overview of, 167
  - thermoplastic retainers for, 170, 172–174, 173f–174f
  - vacuum formed retainers for, 172–174, 173f–174f
- Reviews, 1–2, 2f
- Roll, 89
- Root parallelism, 175
- Root resorption. See Orthodontically induced inflammatory root resorption.
- Rotational force, 146, 146f
- Round wires, 31, 33
- ## S
- Saliva contamination, 19
- Selection bias, 2
- Selective alveolar decortication, 186–189, 187f
- Self-drilling temporary skeletal anchorage devices, 110–111
- Self-etching primers, 18–19
- Self-ligating bracket system, 179–180
- Sequential aligners, 141
- Siamese bracket, 49
- Silanation, 21
- Silicization technique, 21
- Single wing bracket, 49
- Six Elements of Orofacial Harmony, 61, 79
- Skeletal maturation, 53, 127, 128f
- Space closure
- en-masse retraction, 50–51
  - orthodontically induced inflammatory root resorption concerns, 50
  - stability of, 175
- Springback, 32
- Square wires, 31
- Stability
- interproximal enameloplasty for, 174–175
  - options for, 168, 175
  - overview of, 167
- Stainless steel wires, 32–34, 34f, 170
- Stiffness, of orthodontic wires, 32–33
- Strength, of orthodontic wires, 32
- Submucosal injection of platelet-rich plasma, for accelerated orthodontic tooth movement, 191–193, 192f
- Sulcular releasing incisions, 186, 187f–188f
- Superelastic nickel-titanium orthodontic wires, 35–36, 39, 42–43
- Supracrestal fiberotomy, circumferential, 168
- Systematic reviews
- Class II malocclusion treatments, 7, 52
  - description of, 2
- ## T
- Temporary skeletal anchorage devices
- air embolus/emphysema caused by, 121
  - anchorage effectiveness of, 49
  - angle of insertion, 119
  - anterior open bite treated with, 122–123
  - bicortical anchorage, 111
  - bone overheating caused by, 121
  - clinical uses of, 122–123
  - complications of, 120–122
  - composition of, 109
  - cone beam computed tomography evaluation before placement of, 111
  - contraindications, 121–122
  - description of, 4, 107
  - design of, 109–111, 110f
  - diameter of, 109
  - direct anchorage using, 112, 112f
  - displacement of, 120
  - factors that affect success of, 118

- failure of, 118–119, 122  
 flutes, 110  
 fracture of, 121  
 in hard tissue, 111–112  
 history of, 107  
 immediate loading of, 118–119  
 indications for, 107, 122–123  
 indirect anchorage using, 112, 113f–117f  
 insertion angle for, 119  
 length of, 109  
 mandibular placement of, 111  
 maxillary placement sites for, 111  
 midpalatal, 111, 118  
 molar intrusion using, 123, 123f  
 nerve injury caused by, 120–121  
 nomenclature associated with, 108  
 orthodontist placement of, 108f, 108–109  
 palate placement of, 111  
 pitch of, 110  
 placement of  
   by orthodontist, 108f, 108–109  
   root clearance considerations, 120  
   technique for, 119–120  
 pre-drilled, 110–111  
 removal of, 120  
 root damage caused by, 120  
 self-drilling, 109, 110–111  
 self-taping, 109  
 sinus perforation of, 121  
 site selection for, 111–112  
 skeletal asymmetries treated with, 89  
 skeletal discrepancies managed with, 122  
 slippage of, 120  
 smoking effects on, 122  
 in soft tissue, 111  
 soft tissue coverage of, 121, 122f  
 studies of, 118  
 thread design of, 109–110, 110f  
 tip of, 109  
 torque effects on, 119  
 types of, 109f, 109–111
- Temporomandibular disorders  
 behavioral therapies for, 164  
 biopsychosocial model of, 158t, 162  
 canine-protected occlusion, 159–160  
 centric relation, 160–161  
 definition of, 164  
 deprogramming appliances, 160–161  
 diagnosis of, 163  
 evidence-based treatment of, 163–164  
 gnathologic-prosthetic view of, 157  
 management of, 162–164  
 multifactorial view of, 158  
 natural history of, 157  
 orthodontics and, 157–159, 158t  
 patient self-directed therapies for, 163–164  
 temporomandibular joint disc internal derangements associated with, 162
- Temporomandibular joint disc, 162
- Terminal hinge axis, 161
- Thermoelastic effect, 38
- Thermoplastic retainers, 170, 172–174, 173f–174f
- Third molar extractions  
 American Association of Oral and Maxillofacial Surgery conference, 169–170  
 mandibular incisor relapse as reason for, 168–169  
 morbidity associated with, 169
- Tipping force, 144f, 145
- Titanium-molybdenum alloy, 40
- TMDs. *See* Temporomandibular disorders.
- Tooth extractions. *See* Extractions.
- Tooth movement, accelerated orthodontic  
 baseline bone metabolism effects on, 193  
 biomechanical approach for, 179–180  
 bone density effects on, 193  
 bone metabolism–density guided orthodontics, 193–194  
 direct electric current stimulation for, 180, 180f  
 low-level laser therapy for, 180–181  
 overview of, 179  
 pharmacologic approach for, 181–183  
 physiologic approach for, 180–181  
 prostaglandins for, 181–182  
 relaxin for, 182–183  
 self-ligating bracket system for, 179–180  
 submucosal injection of platelet-rich plasma for, 191–193, 192f  
 surgical-assisted approaches for  
   corticision, 189f–190f, 189–191  
   rapid canine retraction, 183–186, 183f–186f  
   selective alveolar decortication, 186–189, 187f
- Torque  
 orthodontically induced inflammatory root resorption affected by, 145, 145f  
 temporary skeletal anchorage devices affected by, 119
- Transforming growth factors, 191
- Transpalatal appliance, 123
- Transpalatal arches  
 anchorage use of, 49–50, 52  
 palatally displaced canines treated with, 131–132  
 “Tunnel technique,” for palatally impacted canines, 133–134, 134f
- Twin block, for overjet correction, 8, 9f
- Two-step canine retraction, 47, 49
- ## U
- U-shaped wire, 174f
- Utility arches, 91f
- ## V
- Vacuum formed retainers, 172–174, 173f–174f
- ## W
- Weibull analysis, 25
- White spots, 21–22, 22f
- Wire  
 beta-titanium, 32, 40–41  
 biocompatibility of, 31  
 characteristics of, 31  
 cobalt-chromium, 32, 35  
 elastic modulus of, 32  
 friction properties of, 179  
 ISO standard for, 32  
 manufacturing process for, 31  
 mechanical properties of, 32  
 nickel-titanium. *See* Nickel-titanium orthodontic wires.  
 properties of, 32–33, 34t  
 range of, 32  
 rectangular, 31, 33  
 round, 31, 33  
 springback of, 32  
 square, 31  
 stainless steel, 32–34, 34f, 170  
 stiffness of, 32–33  
 strength of, 32  
 tension testing of, 32  
 Type 1, 32  
 Type 2, 32  
 types of, 31
- ## Y
- Yaw, 89
- Young’s modulus, 32