

**Edoardo Foce**

# Endo-perio

## **Endo-periodontal Lesions**

 **QUINTESSENCE PUBLISHING**

London, Berlin, Chicago, Tokyo, Barcelona, Beijing, Istanbul, Milan,  
Moscow, New Delhi, Paris, Prague, São Paulo, Seoul and Warsaw

## Dedications

To my wife, Lilly and son, Alessandro — this book may have robbed you of some of my time but not one ounce of my love;

to my sister Giovanna, with whom I silently treasure both memories and the present;

to my mother Milla, with immense love, respect, and gratitude;

and especially to my father, Dr Gianfranco, to whom I would have wished to present my first book with pride and thankfulness, but who is no longer with us and whose loss is with me constantly.

## Acknowledgments

My sincere gratitude goes to all those from whom I have learned, in particular Dr Arnaldo Castellucci, Dr Fabio Gorni, and Dr Gianfranco Carnevale, without whose guidance this work probably would never have happened.

I am grateful to my colleagues and friends, Dr Augusto Malentacca, Dr Mario Badino, Dr Piero Alessandro Marcoli, and Prof Elio Berutti for kindly permitting me to use their documentation.

Special thanks are due to Grazia Innocenti for her extraordinary professional skill, patience, and acumen in arranging and enhancing the layout, text, and images.

My keen appreciation goes to my office administrator, Lorenza Garosi and my hygienist, Dr Roberta Russo.

Sincere thanks go to all my patients.

I am indebted to Dr Piero Biaggini and his firm for all of their moral and logistic support and assistance.

Finally, I owe much to Gianfranco Cavallo, who spurred me on tirelessly to develop on this theme.

## Foreword

The subject of combined endo-perio lesions is surrounded by considerable confusion. One frequently hears diagnoses of endo-perio lesions when in fact there is an endodontic lesion mimicking periodontal disease or, vice versa, a purely periodontal lesion perfectly is camouflaged as an endodontic pathology. This occurs as a result of the similarity of their signs and symptoms, given that both diseases and their resulting lesions affect the same area, namely the tooth-support apparatus that is comprised of the cementum, periodontal ligament, and bone.

Therefore, I have great pleasure in recommending this work by Dr Edoardo Foce not only to undergraduates and graduates but, above all, to clinicians who practice our profession. This book offers a significant advantage in that Dr Foce has finally thrown light on a subject that until now was often confused or misinterpreted. His new classification system, accompanied by abundant clinical case documentation, provides a starting point for correct diagnosis and consequently a successful treatment plan.

My sincere congratulations go to my friend and colleague, Dr Foce for having produced a text illustrating with rare clarity on such a complex and often-debated subject while also highlighting the importance of interdisciplinary knowledge. Periodontology goes hand-in-hand with endodontics, conservative dentistry, prosthodontics, implant dentistry, and oral surgery.

Dr Arnaldo Castellucci



## Foreword

This work by Dr Edoardo Focè stands apart from other single-author books or chapters on this subject thanks to the clinical approach he has chosen.

I find the new classification proposed by the author highly interesting and logical, especially in the light of its impact on how to proceed with treatment. It is my opinion that the endo-perio area has until now been complicated by hazy classifications often having little in common with reality.

Dr Focè's decision to present emblematic cases illustrating the correlations between endodontium and periodontium appears intelligent and eminently practical since the book provides many ideas and suggestions concerning the connections not only between endodontics and periodontics but also between endodontics and all the other dental specialties involving the periodontium, including conservative dentistry, oral surgery, and prosthodontics.

Dr Gianfranco Carnevale



# Table of Contents

# Contents

<b>Introduction</b> .....	1
<b>Chapter One: Terminology</b> .....	5
<b>1</b> Endodontic Lesions .....	7
Periodontal Lesions .....	9
Summary .....	21
<b>Chapter Two: Lesions of the Periodontium</b> .....	25
<b>2</b> Periodontal Lesions of Endodontic Origin .....	25
Plaque-Induced Periodontal Lesions .....	33
Differential Diagnosis .....	33
Clinical Cases .....	33
<b>Chapter Three: Historical Classifications and Diagnostic Criteria</b> .....	43
<b>3</b> Primary Endodontic Lesions .....	45
Primary Endodontic Lesions with Secondary Periodontal Involvement .....	45
Primary Periodontal Lesions .....	45
Primary Periodontal Lesions with Secondary Endodontic Involvement .....	45
New Diagnostic Criteria for Endo-Perio Lesions .....	45
<b>Chapter Four: Proposed New Terminology and Classification</b> .....	51
<b>4</b> Diagnosis of Crown-Down and Down-Crown Lesions .....	52
Class 1: Crown-Down Plaque-Induced Periodontal Lesions .....	65
Class 2: Down-Crown Periodontal Lesions of Endodontic Origin .....	66
Class 3: Combined Endo-Perio Lesions .....	68
<b>Chapter Five: Clinical Case Studies</b> .....	73
<b>5</b> Procedure .....	73
Pseudo Endo-Perio Lesion Profiles: Case Studies 1 to 6 .....	74
Pseudo Endo-Perio Lesion Profiles: Clinical Case Studies 7 to 9 .....	85
Endo-Perio Lesion Profiles: Clinical Case Studies 11 to 21 .....	102
<b>Bibliography</b> .....	143
<b>Index</b> .....	145

# Introduction

The human periodontium and dental pulp cavity are closely connected by their proximity and by the presence of apical and lateral radicular foramina, which permit the passage of pathogens between these two distinct anatomical areas (Fig 1). The pulp-periodontal interrelationship is one in which “there are so many paths of communication that one is tempted to put aside the notion of two distinct anatomical structures and consider them as a single continuous system.”<sup>1</sup>

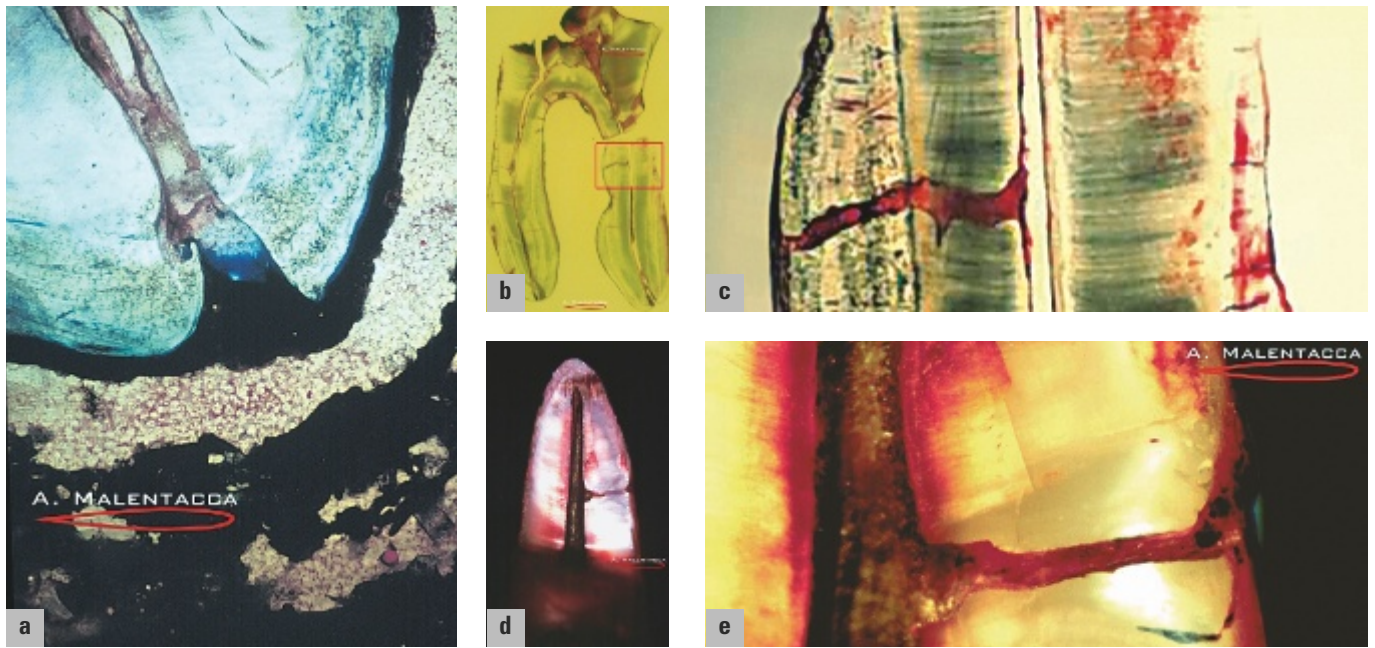
Nomenclature distinguishes between lesions caused by periodontal pathogens, as seen in chronic periodontitis, and disorders of the apical periodontal tissues associated with endodontic pathology. When the location is distinct and the lesion is discrete, the two are easy to differentiate (Fig 2).

Other pathologic profiles exist that, as shown by clinical and radiologic examination, simultaneously affect the marginal and apical areas of the periodontium, thus making it essential to ascertain their true cause through differential diagnosis (Fig 3). The expression *endo-perio lesion*<sup>2</sup> was devised to better describe the etiopathogenesis in such cases and includes lesions:

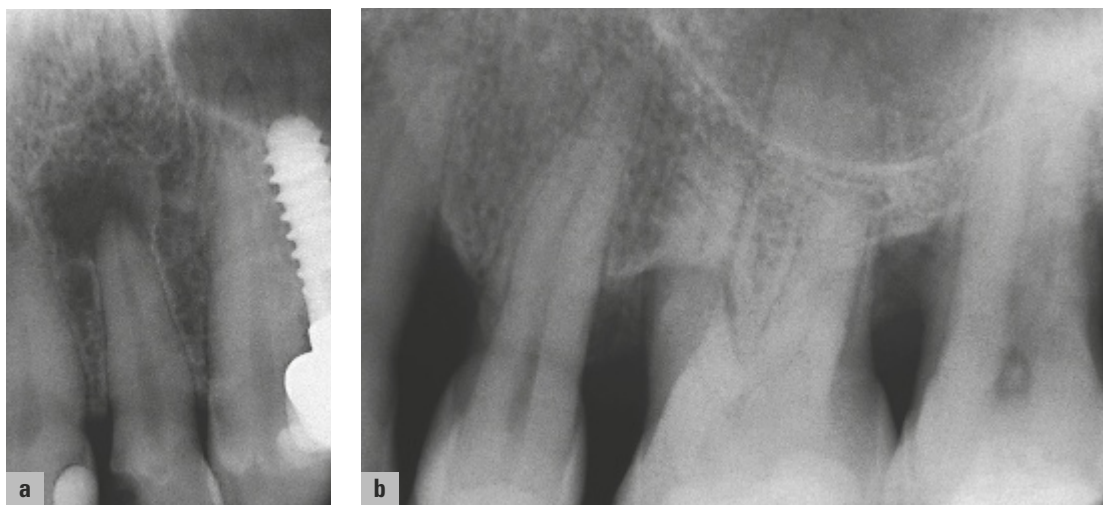
- Caused by endodontic pathogens that have spread coronally, thus involving the gingival margin and in some cases creating a fistula, or *sinus tract*
- Originating from a marginal lesion which has subsequently affected more apical periodontal areas

- Resulting from of a combination of the above, in which case the differential diagnosis must attribute each portion of the lesion to its cause (Fig 4)

Because chronic endo-perio lesions are common in clinical practice, a number of authors have already addressed this issue.<sup>1,3-9</sup> This contribution has been added because the term *endo-perio lesion* can often be unclear and merits further elaboration. When one fails to distinguish clearly among varying pathologies, one falls into the trap of lumping them together, defeating the purpose of much research and literature. ■

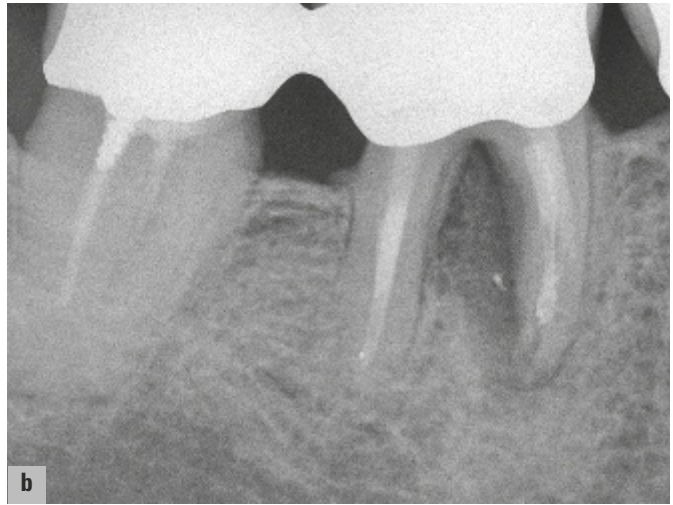
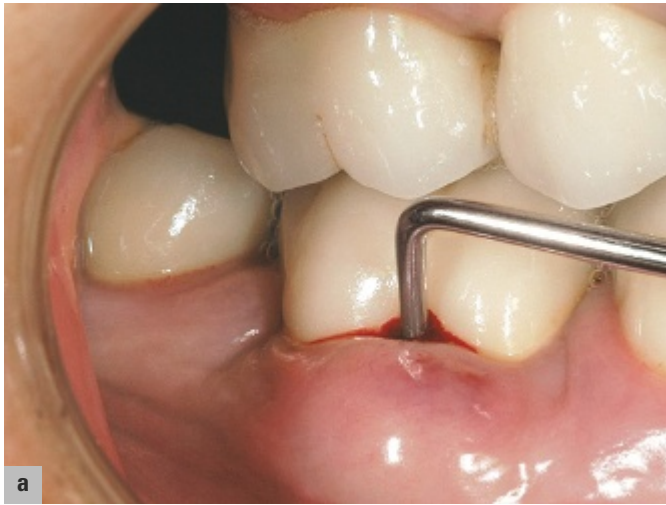
**Fig 1** (a to e) Although the pulp and the periodontium are distinct from one another, they are anatomically connected via foramina. (Courtesy of Dr Augusto Malentacca.)

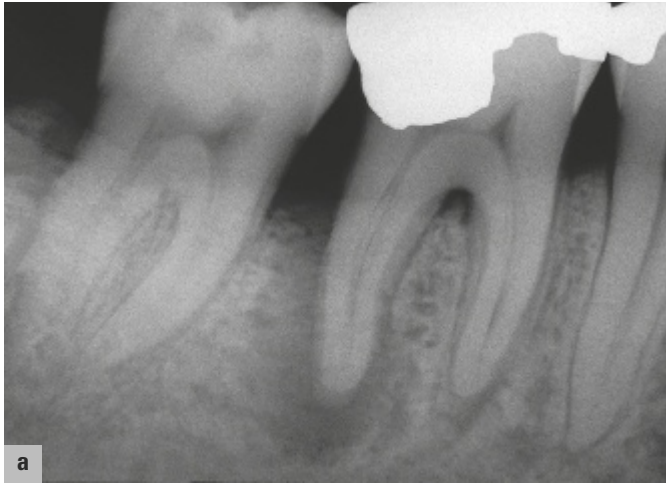


**Fig 2** (a) An apical lesion of endodontic origin. (b) Attachment and bone loss in the alveolar crest area.

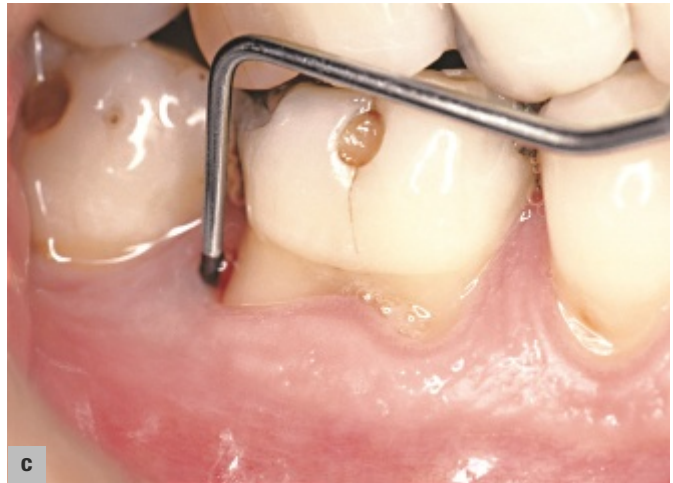
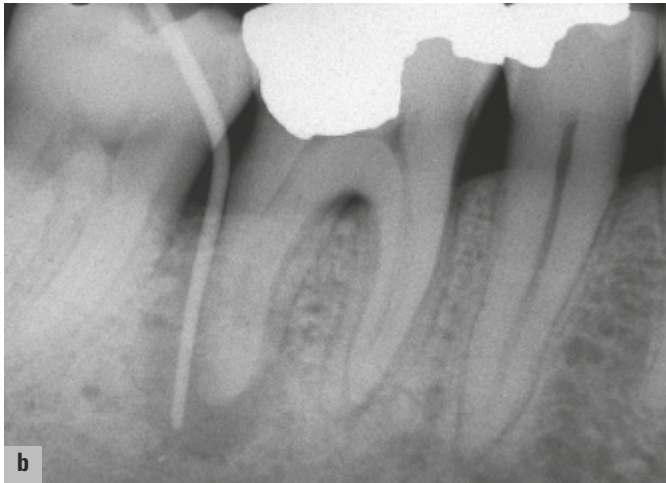


**Fig 3** (a and b) Clinical and radiologic investigation of the marginal and more apical periodontium, highlighting the need for a differential diagnostic approach to uncover the true nature of the lesion's endo-perio status.



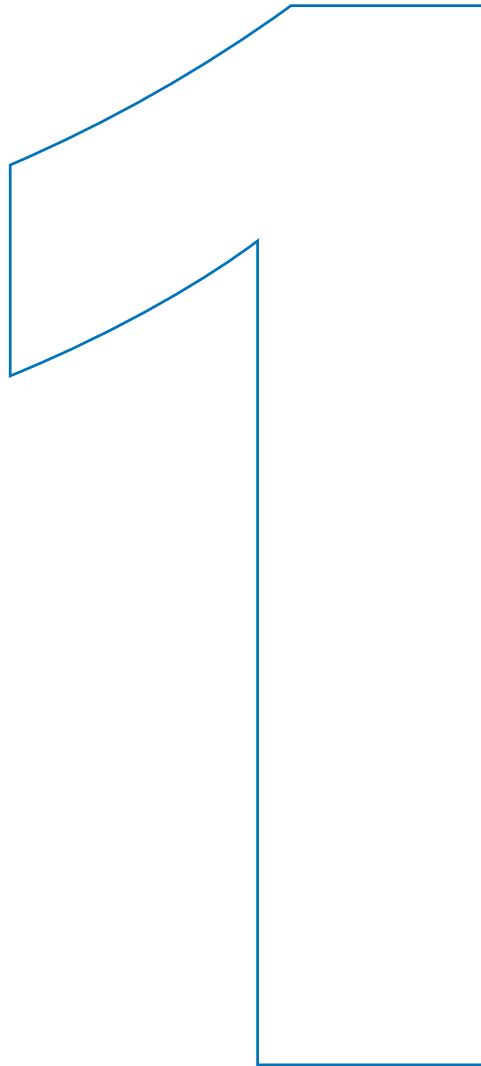
**Fig 4** (a to c) Clinical and radiologic examinations show marginal and apical periodontal involvement, making it necessary to ascertain the true nature of the lesion.





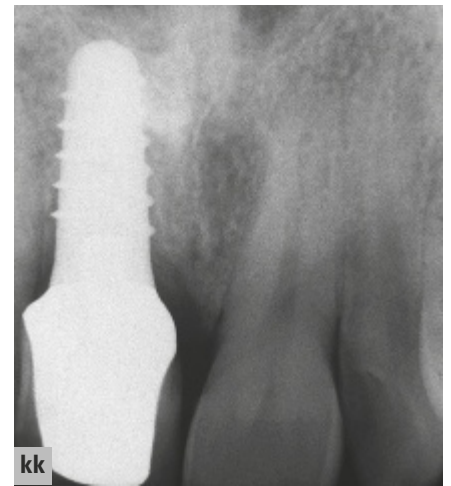
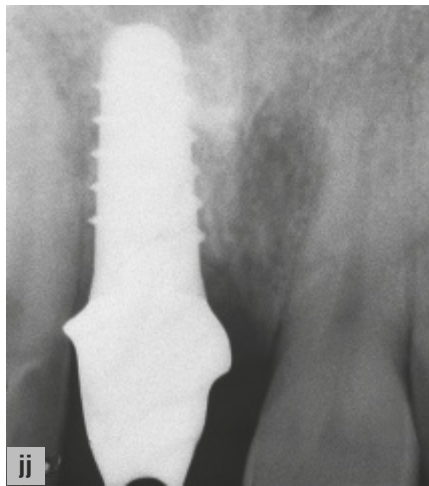
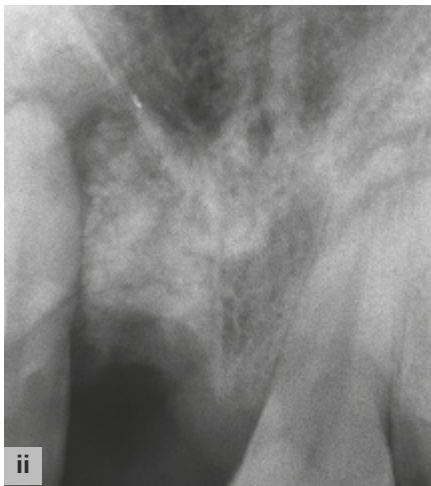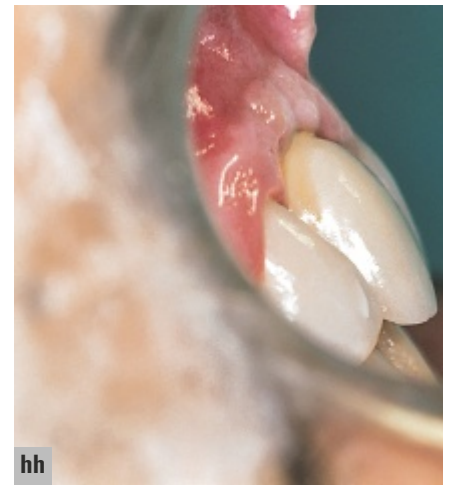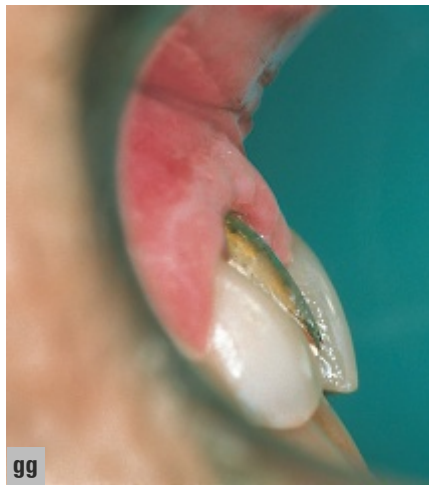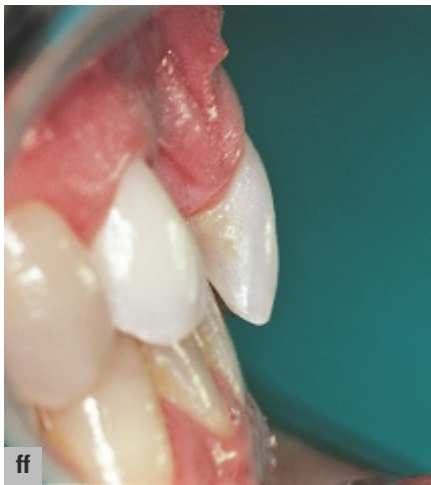## Chapter One

# Terminology



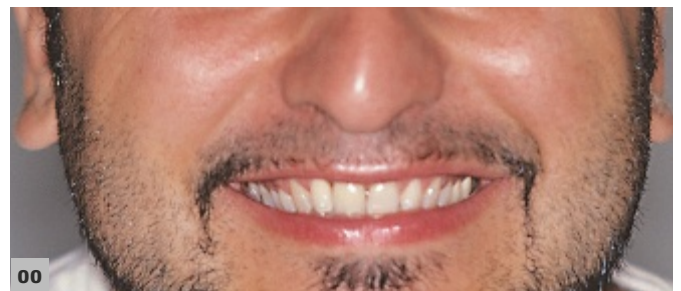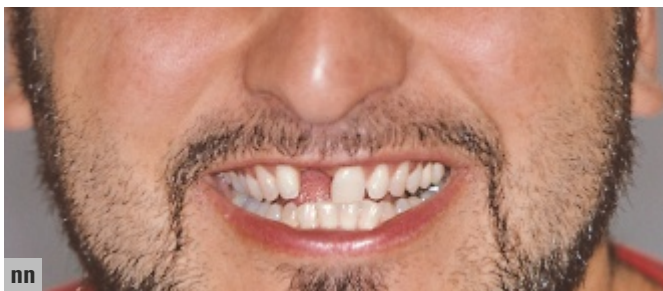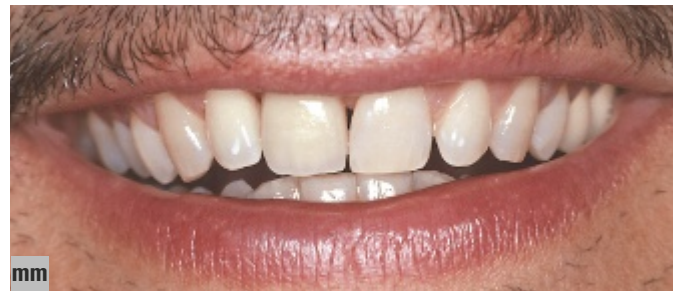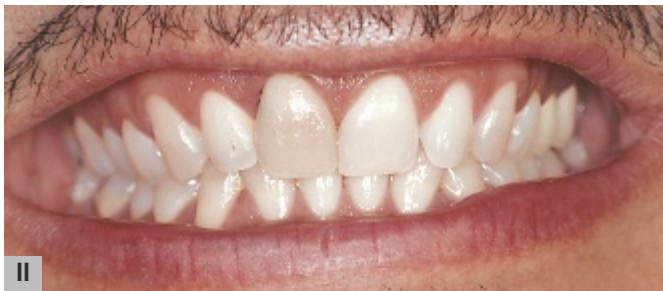Terminology, by nature, implies a consensus in regards to the terms used to define a given thing, person, or concept. This brings to mind the famous quote from Umberto Eco's *The Name of the Rose*: "Stat rosa pristina nomine, nomina nuda tenemus (what is left of the rose is only its name)."<sup>10</sup>

In the English language the first word in expressions such as *bone injuries*, *cardiac lesions*, or *brain damage* clearly denotes which part of the body is affected. As a logical extension of this concept, the expression *endo-perio lesions* should be interpreted as meaning that the lesions in question are present in both the pulp cavity and the periodontium. While this is in itself correct and precisely describes the affected parts, it is problematic that the term is often misinterpreted as a reference to the etiopathogenesis, or origin. This misunderstanding is usually implied rather than directly stated.



**Figs 1-13ff to 1-13kk** Following the ridge expansion there is a visible improvement in labial osseous contours in the area of the implant.

**Figs 1-13ll to 1-13oo** Pretreatment and posttreatment conditions.



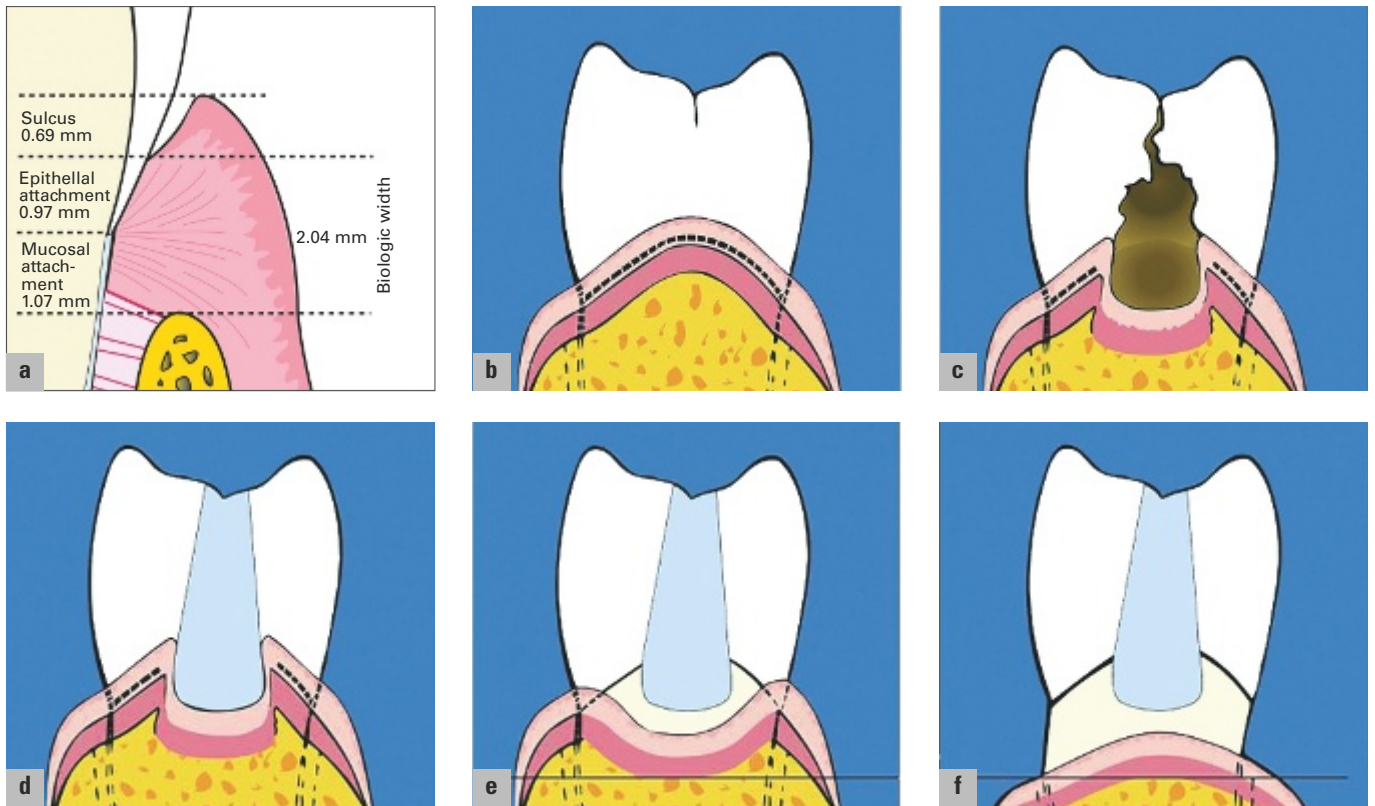
From both a diagnostic and operational perspective it is essential to consider endo-perio relations (see Figs 1-12j to 1-12n). Failure to take these into due consideration may, for example, result in proceeding with regenerating treatment on the grounds that an intrabony defect seemed a perfect surgical candidate in light of its location, width, depth, angle and number of remaining walls. Recognizing the endo-perio origin of a lesion should guide treatment decision making.

Lesions provoked in the periodontium, in addition to the various diseases and disorders listed on page 9, may also be associated with or caused by:

- Caries affecting the external root surface below the CEJ (Figs 1-14 and 1-15).<sup>19-22</sup>
- Iatrogenic causes such as restoration margins (Figs 1-16 and 1-17) and prosthetic devices (Fig 1-18), which may affect the external root surface apical to the CEJ and invade the biologic width. This damage may spread to apically located tissues.<sup>19-22</sup>

The interproximal areas in Fig 1-18 show the periodontal attachment apparatus following apically the scalloping of the CEJs. By their embryologic nature, the supracrestal fibers in a healthy undamaged periodontium insert into the radicular cementum situated just below the enamel. The physiologic architecture of the interproximal area means that the attachment level in the buccal and palatolingual areas is more apical than in the interproximal areas. This creates a convex coronal shape known as *physiologic* or *positive* architecture. Should this area be affected by caries or iatrogenic causes leading to loss of attachment apparatus and consequent apical migration of the CEJ, the positive architecture will be lost. The interproximal fibers will insert into the radicular cementum further apically than in the buccal and lingual attachment apparatus. The resulting shape is defined as *inverted* or *negative* architecture. From a practical point of view, this altered, concave shape is difficult to clean and favors the onset of soft tissue craters.

**Fig 1-14 (a to f)** Relationship between carious damage and periodontal margin attachment.





tioner must proceed towards division into endo-perio classes, even if the final diagnosis remains pseudo endo-perio:

- Class 1: Crown-down plaque-induced periodontal lesion
- Class 2: Down-crown periodontal lesion of endodontic origin

In Class 1 lesions, the difference between classification into the endo-perio category as opposed to pseudo endo-perio depends on the ease and immediacy with which pulp vitality is ascertained.

At this preliminary diagnosis stage, a tooth with a healthy crown in which pulp necrosis is not suspected and that responds normally to noninvasive pulp vitality testing using a thermal or electric pulp tester (EPT), is defined as a *Class 1 pseudo endo-perio* case.

Conversely, if the tooth shows signs of pulp pathology such as draining sinus tracts, unsuccessful endodontic treatment, or extensive restorations while also not responding to noninvasive pulp vitality testing (ie, presenting a potential lesion of endodontic nature) the *Class 1 endo-perio* profile will be the preliminary diagnosis.

Similarly, when a tooth presents with changes in the periodontium extending apicomarginally but probing is not compatible with chronic periodontal disease, the *Class 2 pseudo endo-perio* hypothesis is applied (see Fig 5-2). If probing depth indicates lesion of attachment, the diagnosis will be *Class 2 endo-perio*.

Although of academic and didactic interest, the distinction between pseudo endo-perio and genuine endo-perio profiles is of little relevance in clinical and practical applications.

### Final diagnosis

The final diagnosis, the moment in which the etiopathogenesis of the lesion has been diagnosed with certainty, may not be determined until some or all treatment has been completed.

## Pseudo Endo-Perio Lesion Profiles: Case Studies 1 to 6

### Clinical case study 1

#### Clinical and radiologic examination

The mandibular right first molar is slightly mobile; radiographs show a periodontal bony defect along the mesial root. Calculus is detectable on the root surface.

#### Initial diagnosis: Endo-perio profile

Further investigation is required to ascertain the status of the periodontium and pulp.

#### Periodontal examination

**Figs 5-1a and 5-1b** Probing depth along the mesial root is 10 mm; subgingival calculus is present.

**Figs 5-1c to 5-1f** Generalized periodontal condition is very poor with widespread inflammation and supra- and subgingival calculus. Full mouth plaque score (FMPS) and full mouth bleeding score (FMBS) greater than 50%. Gingival recession and significant probing depths recorded in a number of sites.

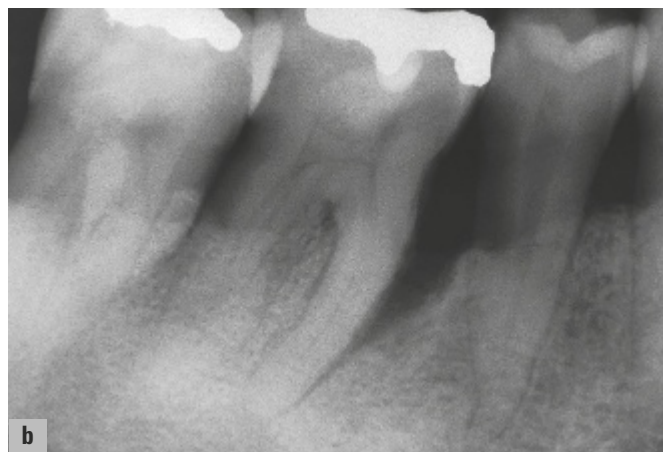
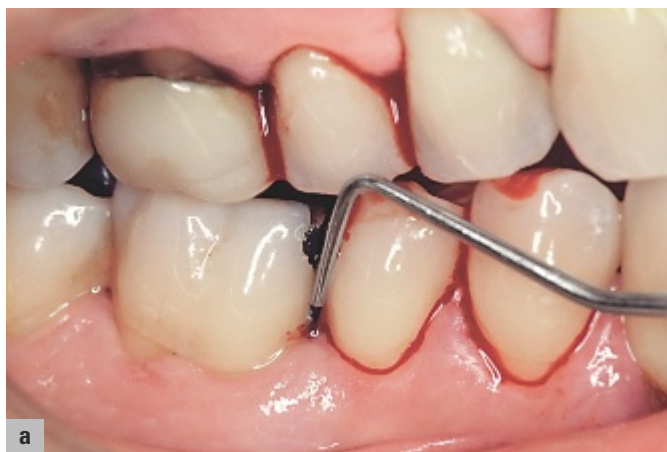#### Preliminary treatment choice

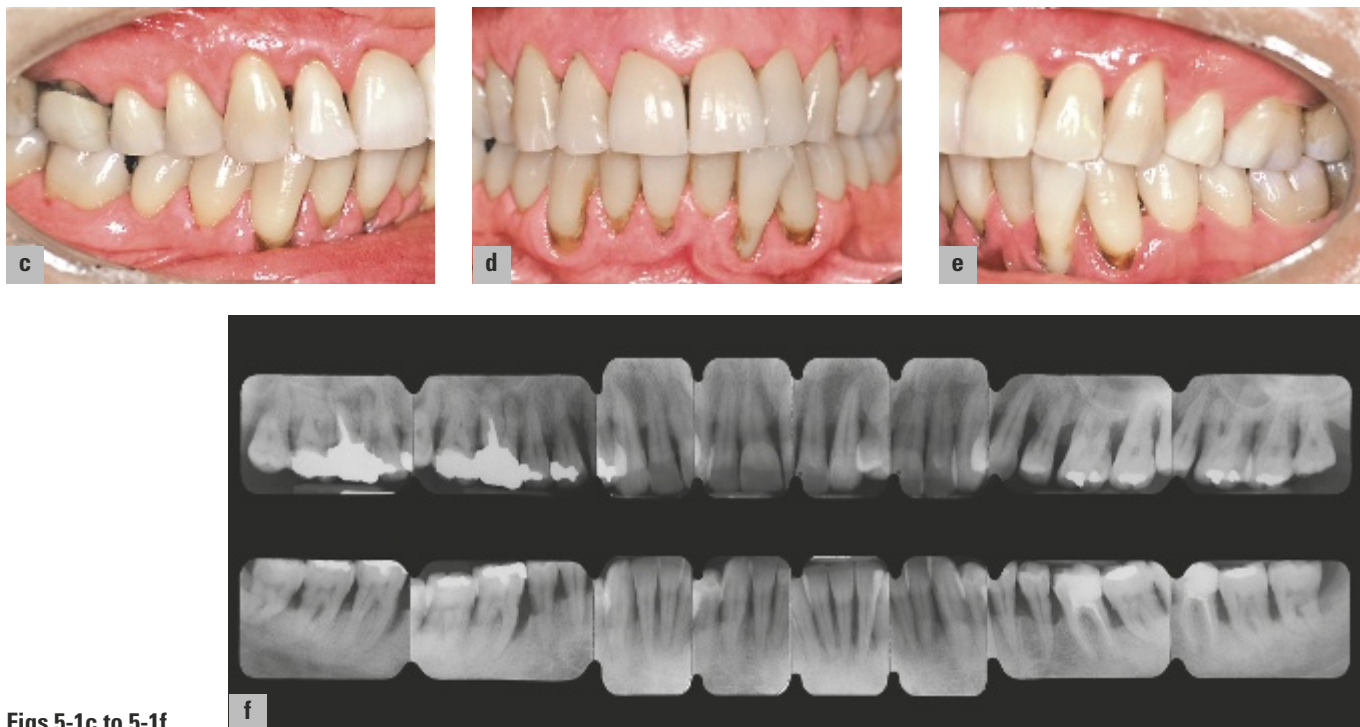Treatment to include management of periodontal disease with scaling and root planing, patient education, and a program of periodontal hygiene maintenance.

#### Treatment objectives

To eliminate periodontal inflammation and to bring FMPS and FMBS under 20%, reduce probing depths, regain some clinical attachment, and achieve acceptable and continued hygiene maintenance.

**Figs 5-1a and 5-1b**





**Figs 5-1c to 5-1f**

**Endodontic examination**

The mandibular left first molar responded normally to thermal and EPT testing. In the endo-perio context, immediate confirmation of pulp vitality along with significant probing depths consistent with radiologic evidence resolves any diagnostic doubt.

*Preliminary diagnosis: Pseudo endo-perio profile*  
*Final diagnosis: Class 1 plaque-induced periodontal lesion*

**Figs 5-1g to 5-1l** Following treatment the patient was reassessed, with considerable improvement in periodontal health noted. Probing depth around the molar in question was reduced from 10 mm to 7 mm.

**Figs 5-1g to 5-1l**

