



---

# ADVANCES IN RESTORATIVE DENTISTRY

*Edited by*

Adrian Lussi and Markus Schaffner

*With contributions from:*

Adrian Lussi, Brigitte Zimmerli, Klaus Neuhaus,  
Matthias Strub, Stefan Hänni, Markus Schaffner, Svante Twetman,  
Martina Eichenberger, Simon Flury, Philippe Perrin, Rainer Seemann,  
Philip Ciucchi, Anne Grüniger, Daniel Jacky, Thomas Jaeggi,  
Franziska Jeger, Karin Kislig, Domenico Di Rocco, Jonas Rodrigues,  
Benjamin Schüz, and Beat Suter

 **QUINTESSENZ PUBLISHING**

London, Berlin, Chicago, Tokyo, Barcelona, Beijing, Istanbul, Milan,  
Moscow, New Delhi, Paris, Prague, São Paulo, Seoul, Singapore and Warsaw

# Acknowledgements

Thanks go to Ueli Iff and Anne Seeger (Department of Multimedia and Computer Science, University of Bern) for the production of the graphical figures, as well as to Herrmann Stich (Department of Preventive, Restorative and Pediatric Dentistry, University of Bern) for the histology pictures.

British Library Cataloguing in Publication Data  
Lussi, Adrian.

Advances in restorative dentistry.

1. Dentistry, Operative. 2. Dentistry, Operative--  
Technological innovations.

I. Title II. Schaffner, Markus.

617.6'05-dc23

ISBN-13: 978-1-85097-228-0



Quintessence Publishing Co. Ltd,  
Grafton Road, New Malden, Surrey KT3 3AB,  
United Kingdom  
[www.quintpub.co.uk](http://www.quintpub.co.uk)

Copyright © 2012 Quintessence Publishing Co. Ltd

All rights reserved. This book or any part thereof may not be reproduced, stored in a retrieval system, or transmitted in any form or by any means, electronic, mechanical, photocopying, or otherwise, without prior written permission of the publisher.

Editing: Quintessence Publishing Co. Ltd, London, UK

Layout and Production: Walburga Rothenhagen, Falkensee, Germany and  
Quintessenz Verlags-GmbH, Berlin, Germany

Printed and bound in Germany

---

# Preface

Dentistry has undergone a major transformation over recent years and decades. New technologies have been developed and a better understanding of biological principles and processes has been gained. This book sheds light on these new aspects in preventive dentistry and restorative dentistry.

*Advances in Restorative Dentistry* gives an overview of current trends in this diverse and important specialist field for dental practitioners. The broad scope of restorative and preventive dentistry is examined in 25 chapters. The following subjects are discussed:

- Structure and pathology of the tooth
- Aspects of prevention
- Caries
- Magnification aids in restorative dentistry
- Damage to adjacent teeth and minimally invasive preparation
- Yesterday retention – today adhesion?
- Bleaching
- Dental erosion
- Endodontology
- Halitosis

The wealth of illustrations and highlighted key sentences make it easy to incorporate current knowledge into daily practice as well as into teaching and study activities.

Adrian Lussi  
Markus Schaffner

# Authors and contributors

**Prof. Dr. med. dent. Adrian Lussi**

Executive Director and Head of Department  
Department of Preventive, Restorative and  
Pediatric Dentistry  
University of Bern  
E-Mail: [adran.lussi@zmk.unibe.ch](mailto:adran.lussi@zmk.unibe.ch)

**Dr. med. dent. Markus Schaffner**

Senior Lecturer  
Department of Preventive, Restorative and  
Pediatric Dentistry  
University of Bern  
E-Mail: [markussch@bluewin.ch](mailto:markussch@bluewin.ch)

**Dr. med. dent. Philip Ciucchi**

Research Associate  
Department of Preventive, Restorative and  
Pediatric Dentistry  
University of Bern  
E-Mail: [Philip.ciucchi@zmk.unibe.ch](mailto:Philip.ciucchi@zmk.unibe.ch)

**Dr. med. dent. Martina Eichenberger**

Lecturer  
Department of Preventive, Restorative and  
Pediatric Dentistry  
University of Bern  
E-Mail: [martina.eichenberger@zmk.unibe.ch](mailto:martina.eichenberger@zmk.unibe.ch)

**Dr. med. dent. Simon Flury**

Research Associate  
Department of Preventive, Restorative and  
Pediatric Dentistry  
University of Bern  
E-Mail: [simon.flury@zmk.unibe.ch](mailto:simon.flury@zmk.unibe.ch)

**Dr. med. dent. Anne Grüninger**

Senior Lecturer  
Department of Preventive, Restorative and  
Pediatric Dentistry  
University of Bern  
E-Mail: [amvv@bluewin.ch](mailto:amvv@bluewin.ch)

**Dr. med. dent. Stefan Hänni**

Senior Lecturer  
Department of Preventive, Restorative and  
Pediatric Dentistry  
University of Bern  
E-Mail: [stefan.haenni@zmk.unibe.ch](mailto:stefan.haenni@zmk.unibe.ch)

**Dr. med. dent. Daniel Jacky**

Lecturer  
Department of Preventive, Restorative and  
Pediatric Dentistry  
University of Bern

**Dr. med. dent. Thomas Jaeggi**

Senior Lecturer  
Department of Preventive, Restorative and  
Pediatric Dentistry  
University of Bern  
E-Mail: [thomasjaeggi@bluewin.ch](mailto:thomasjaeggi@bluewin.ch)

**Dr. med. dent. Franziska Jeger**

Senior Lecturer  
Department of Preventive, Restorative and  
Pediatric Dentistry  
University of Bern  
E-Mail: [franziska.jeger@zmk.unibe.ch](mailto:franziska.jeger@zmk.unibe.ch)

**Dr. med. dent. Karin Kislig**

Senior Lecturer  
Department of Preventive, Restorative and  
Pediatric Dentistry  
University of Bern  
E-Mail: [karin.kislig@zmk.unibe.ch](mailto:karin.kislig@zmk.unibe.ch)

**Dr. med. dent. Klaus W. Neuhaus**

Senior Lecturer  
Department of Preventive, Restorative and  
Pediatric Dentistry  
University of Bern  
E-Mail: [klaus.neuhaus@zmk.unibe.ch](mailto:klaus.neuhaus@zmk.unibe.ch)

**Dr. med. dent. Philippe Perrin**

Senior Lecturer  
Department of Preventive, Restorative and  
Pediatric Dentistry  
University of Bern  
E-Mail: [perrins@bluewin.ch](mailto:perrins@bluewin.ch)

**Dr. med. dent. Domenico Di Rocco**

Senior Lecturer  
Department of Preventive, Restorative and  
Pediatric Dentistry  
University of Bern  
E-Mail: [domenico@dirocco.ch](mailto:domenico@dirocco.ch)

**Dr. med. dent. Jonas de Almeida Rodrigues  
MSc, PhD**

Research Associate  
Department of Preventive, Restorative and  
Pediatric Dentistry  
University of Bern  
E-Mail: [jorodrigues@hotmail.com](mailto:jorodrigues@hotmail.com)

**PD. Dr. med. dent. Rainer Seemann**

Senior Lecturer  
Department of Preventive, Restorative and  
Pediatric Dentistry  
University of Bern  
E-Mail: [rainer.seemann@zmk.unibe.ch](mailto:rainer.seemann@zmk.unibe.ch)

**Benjamin Schüz, Dipl.-Psych.**

Lecturer  
School of Psychiatry  
University of Tasmania  
E-Mail: [Benjamin.Schuez@utas.edu.au](mailto:Benjamin.Schuez@utas.edu.au)

**Dr. med. dent. Matthias Strub**

Senior Lecturer  
Department of Preventive, Restorative and  
Pediatric Dentistry  
University of Bern  
E-Mail: [mathias.strub@zmk.unibe.ch](mailto:mathias.strub@zmk.unibe.ch)

**Dr. med. dent. Beat Suter**

Senior Lecturer  
Department of Preventive, Restorative and  
Pediatric Dentistry  
University of Bern  
E-Mail: [bs@endodontic-bern-ch](mailto:bs@endodontic-bern-ch)

**Prof. Svante Twetman**

Head of Department  
Department of Cariology and Endodontics  
Faculty of Health Sciences  
University of Copenhagen  
E-mail: [stw@odont.ku.dk](mailto:stw@odont.ku.dk)

**Dr. med. dent. Brigitte Zimmerli**

Senior Lecturer  
Department of Preventive, Restorative and  
Pediatric Dentistry  
University of Bern  
E-mail: [brigitte.zimmerli@zmk.unibe.ch](mailto:brigitte.zimmerli@zmk.unibe.ch)

# Contents


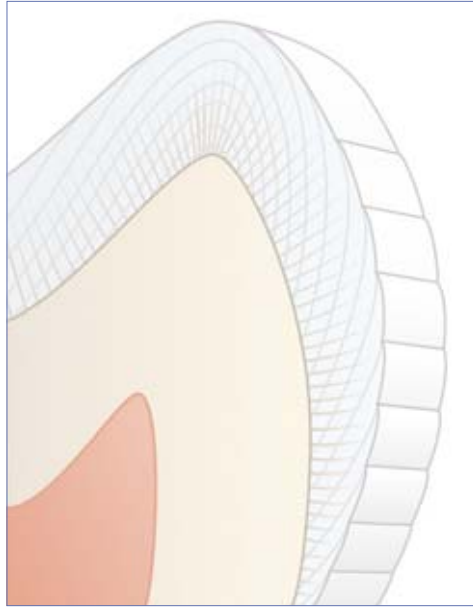
<b>I</b>	<b>Structure and pathology of the tooth</b>	<b>1</b>
1	Structure and pathology of the tooth Markus Schaffner and Adrian Lussi	3
<b>II</b>	<b>Aspects of prevention</b>	<b>17</b>
2	Motivation and action – two aspects of oral hygiene at home Benjamin Schüz and Rainer Seemann	19
3	Cariostatic mechanisms of action of fluorides Adrian Lussi	25
4	The role of xylitol in caries prevention Svante Twetman	33
5	Probiotics – a new approach in caries prevention? Svante Twetman	39
6	Novel methods of promoting remineralization Klaus Neuhaus and Adrian Lussi	45
7	Antibacterial agents for the prevention of caries Svante Twetman and Klaus Neuhaus	53
<b>III</b>	<b>Caries</b>	<b>63</b>
8	Diagnosing caries and caries activity Adrian Lussi, Markus Schaffner, Jonas Rodrigues, and Klaus Neuhaus	65
9	Sealing and infiltration of caries – is this the future? Brigitte Zimmerli and Simon Flury	79
<b>IV</b>	<b>Magnification aids in restorative dentistry</b>	<b>85</b>
10	Utility and futility of magnification aids in restorative dentistry Martina Eichenberger, Philippe Perrin, Daniel Jacky, and Adrian Lussi	87
<b>V</b>	<b>Damage to adjacent teeth and minimally invasive preparation</b>	<b>95</b>
11	Damage to adjacent teeth and minimally invasive preparation Martina Eichenberger, Philippe Perrin, and Adrian Lussi	97
12	Novel preparation and excavation methods Klaus Neuhaus, Franziska Jeger, Philip Ciucchi, and Adrian Lussi	105

<b>VI</b>	<b>Yesterday retention – today adhesion?</b>	
13	Adhesive techniques for dental restorations Brigitte Zimmerli and Matthias Strub	115
14	Direct restorative technology Brigitte Zimmerli, Matthias Strub, and Simon Flury	123
15	Restoration repairs Brigitte Zimmerli and Matthias Strub	137
16	Post systems Brigitte Zimmerli and Matthias Strub	143
17	The CEREC system Domenico Di Rocco and Adrian Lussi	151
<b>VII</b>	<b>Bleaching</b>	<b>161</b>
18	Bleaching Brigitte Zimmerli and Anne Grüninger	163
<b>VIII</b>	<b>Dental erosion</b>	<b>173</b>
19	Dental erosion Adrian Lussi and Thomas Jaeggi	175
<b>IX</b>	<b>Endodontology</b>	<b>191</b>
20	Root canal preparation Beat Suter	193
21	Root canal irrigation Stefan Hänni	207
22	Root canal filling Stefan Hänni	215
23	Cracked tooth syndrome Stefan Hänni and Adrian Lussi	223
24	Endodontology in the primary dentition Markus Schaffner, Klaus Neuhaus, and Adrian Lussi	233
<b>X</b>	<b>Halitosis</b>	<b>243</b>
25	Halitosis Rainer Seemann and Karin Kislig	245
	<b>Index</b>	<b>261</b>



**Fig 1-7 Structural characteristics – enamel**

The periodic laying down of enamel is expressed in the lines of Retzius. Where these lines reach the surface, the perikymata are visible. Viewing the longitudinal and transverse sections of enamel by light microscopy reveals light and dark striae in the inner two-thirds. These Hunter-Schreger bands are caused by the wavelike path of the enamel prisms.

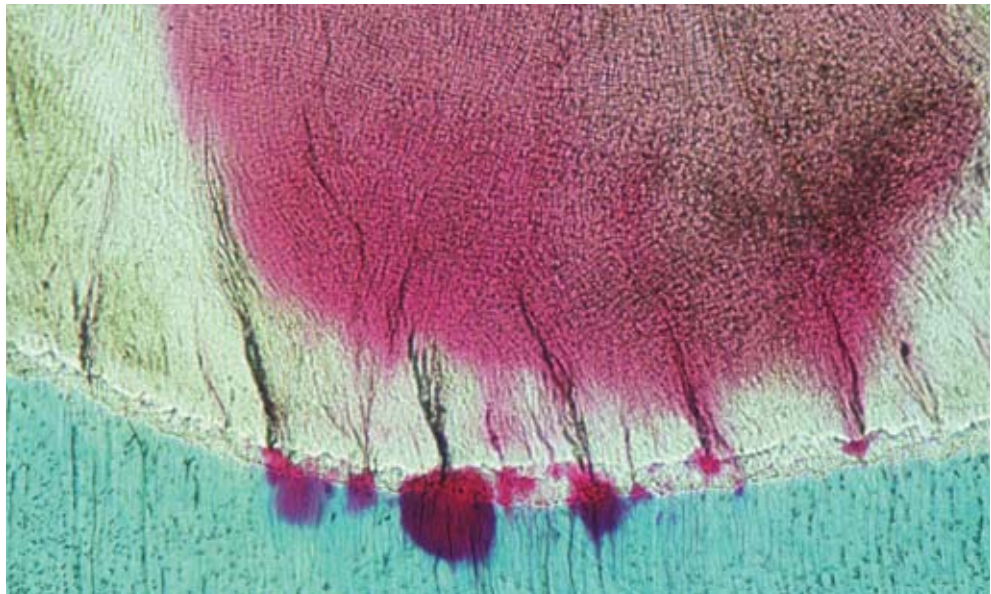

**Fig 1-8 Perikymata under scanning electron microscope (SEM)**

The magnification clearly shows not only the perikymata but also the lines of imbrication running between them.

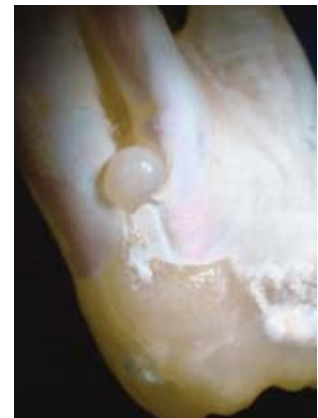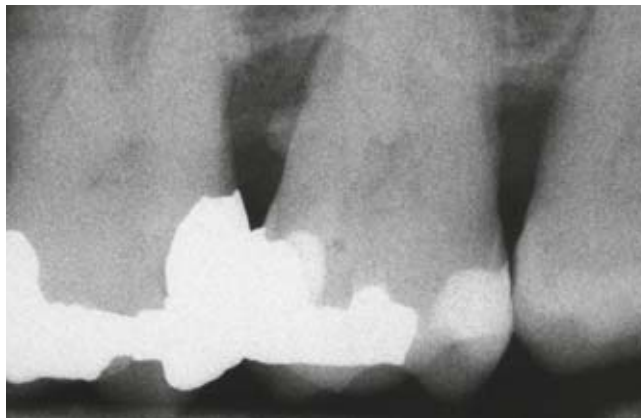**Fig 1-9 Enamel tuft**

Enamel tufts are hypomineralized areas of enamel which look like tufts of grass under light microscopy. Enamel tufts can provide a location favourable to bacteria in the event of carious attack. Caries is clearly visible in the histologic image.



**Fig 1-10 Enamel pearl**

Left: radiograph of an enamel pearl in the interproximal area of a maxillary molar.  
Right: enamel pearl in the bifurcation of a molar.





### ***Structural defects and parapsias of the enamel***

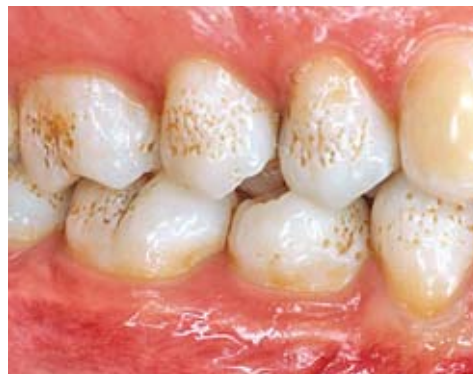In most teeth, enamel structural defects can be identified by light microscopy. A large proportion of these defects arise during amelogenesis. These include enamel tufts (Fig 1-9) and enamel lamellae. Enamel tufts and lamellae can prove to be the line of least resistance in respect of the spread of caries.

The enamel pearl is a parapsias of the enamel. This means the formation of enamel in an atypical localization. Enamel pearls can cause isolated periodontitis in the area of the furcation (Fig 1-10).

### ***Dysplasias of the enamel (and dentin)***

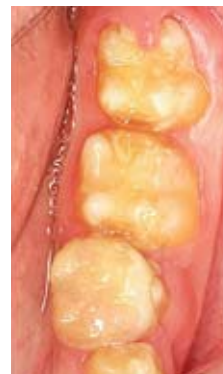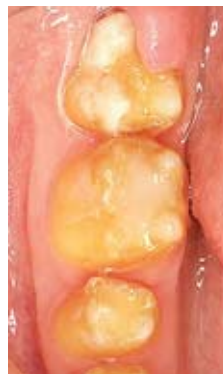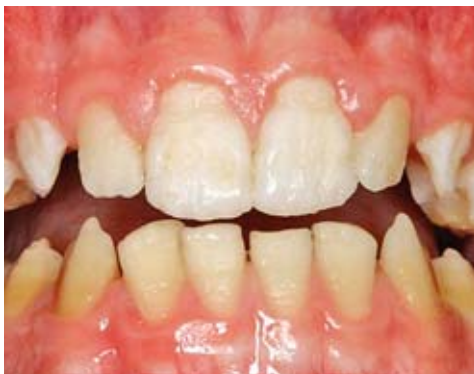Dysplasia of enamel and/or dentin can be caused by defects of genes that are responsible for odontogenesis. However, traumatic, inflammatory, and chemical processes as well as metabolic disorders and systemic diseases can also cause malformations of the enamel and/or dentin.

In enamel and/or dentin dysplasias of genetic origin, all the teeth of one or both dentitions are usually affected to a varying degree. They can be inherited from generation to generation, so that similar disorders of odontogenesis can be found in siblings, parents, and grandparents (Figs 1-11 to 1-13, see also Fig 1-19).



**Fig 1-11 Amelogenesis imperfecta, hypoplastic form (pitting type)**

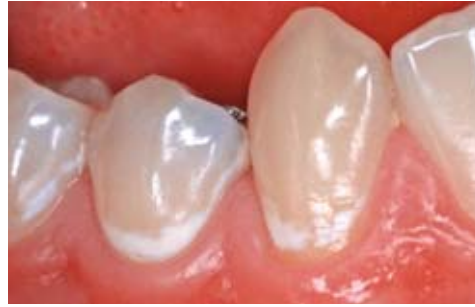*Deposition of exogenous dyes makes the enamel pits in the area of the vestibular surface clearly visible.*



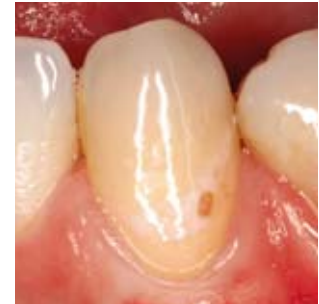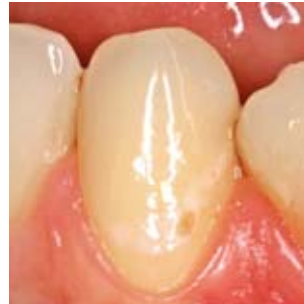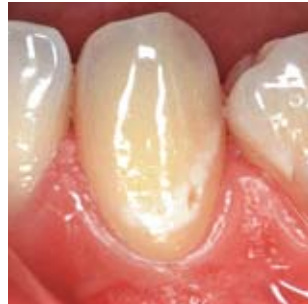**Fig 1-12 Amelogenesis imperfecta, hypomatured form**

*Left and right: the enamel is incompletely mineralized. White, opaque enamel areas are visible in the area of the cusps tips and incisal margins.*

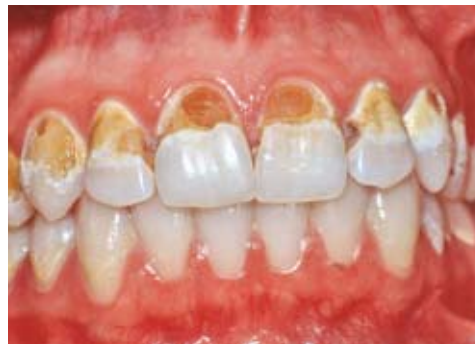



**Fig 8-1** Smooth surface caries with intact surface.



**Fig 8-2** Smooth surface caries with local surface breakdown. Left: initial finding. Centre: after 10 years. Right: after 20 years.

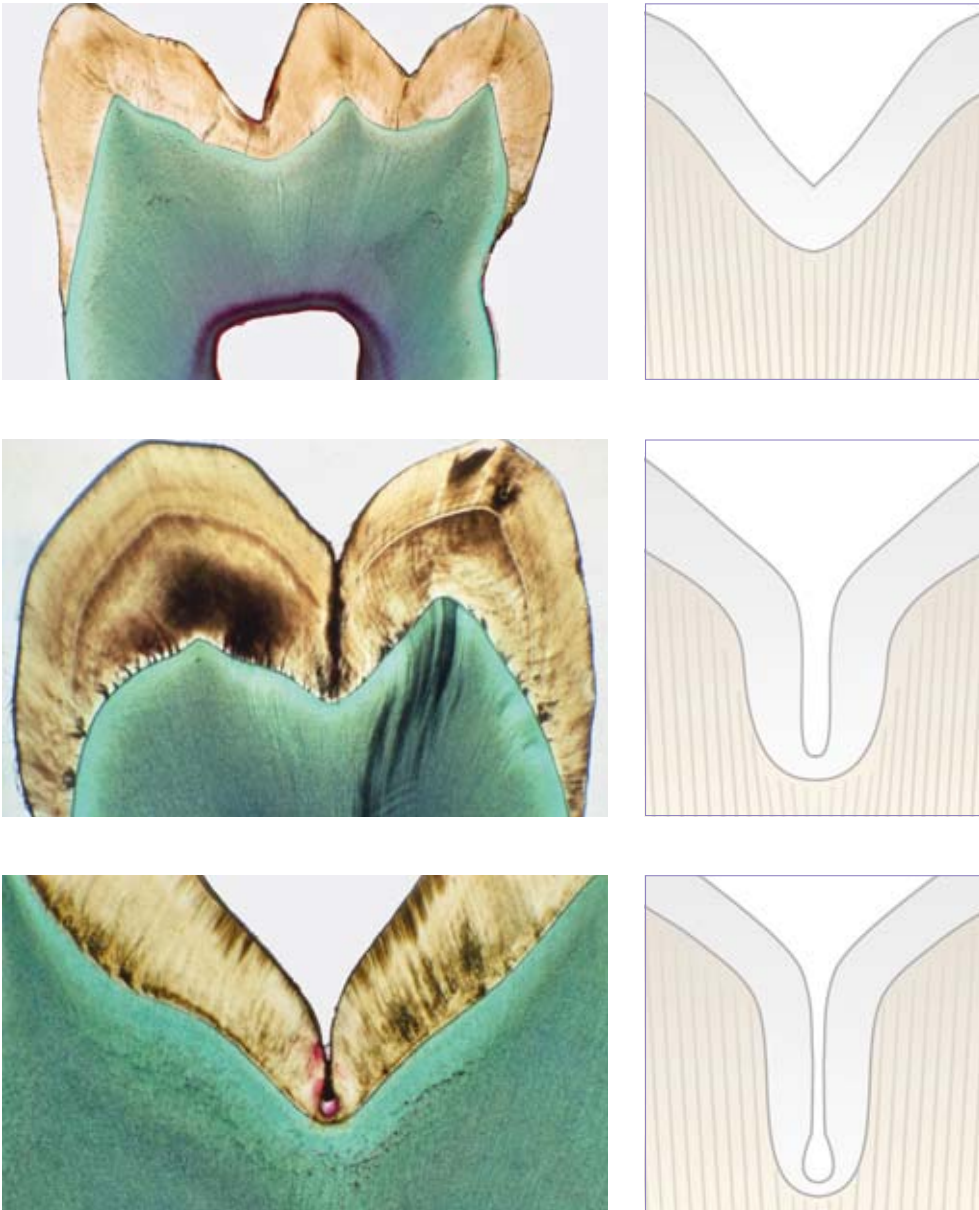


**Fig 8-3** Smooth surface caries with pronounced breakdown of surfaces.

## ■ Pit and fissure caries

Studies have shown that the occlusal surfaces of the permanent molars in children and adolescents are most commonly affected by caries. The proportion of pit and fissure caries in children with minimal caries is between 75% and 92% depending on age. Thus pit and fissure caries is bound to be a common diagnosis. There are various possible reasons for the high caries prevalence in fissures:



- Until final occlusion-finding, an increased accumulation of plaque can be seen in the fissures.
- The enamel is prone to caries in the first few years following eruption. Maturation of enamel involves remineralization and demineralization cycles. The reduced susceptibility of mature enamel to caries is not fissure-specific, but makes a greater impact there.
- The unfavorable fissure morphology prevents adequate cleaning of the fissure base and impedes saliva access (Figs 8-4 to 8-7).



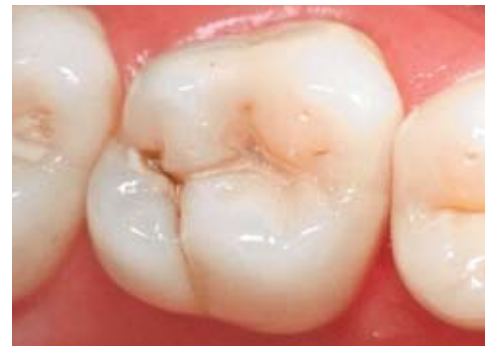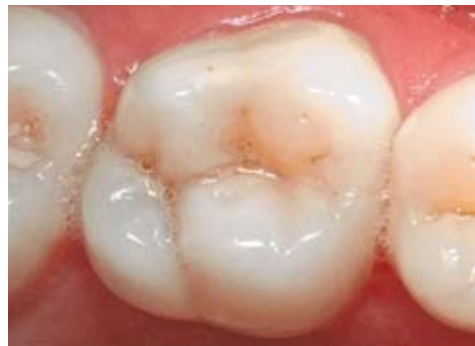*Fig 8-4 to 8-6 Different types of fissure morphology.*

It is important for the teeth to be cleaned before diagnosis so that white spots at the fissure entrance can be identified (Fig 8-8). If a white spot is already visible before drying, it is reasonable to assume that the caries is more advanced than in a white spot which needs to be dried before it can be detected. This long-known fact was recently systematized with the ICDAS system, one of the aims being to publicize comparable diagnostic criteria in all countries.<sup>5</sup>

Diagnosis is difficult because dentin caries can exist underneath an apparently intact surface. In most cases, however, drying and close inspection will reveal an area of decalcification at the fissure entrance. The frequency of the so called "hidden caries" in molars varies between 10% and 50%. It appears to be a direct consequence of suboptimal technique in clinical diagnostics.



**Fig 8-7** It is not possible to clean the base of the fissure with a toothbrush and individual bristles.



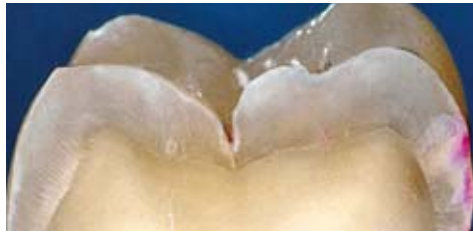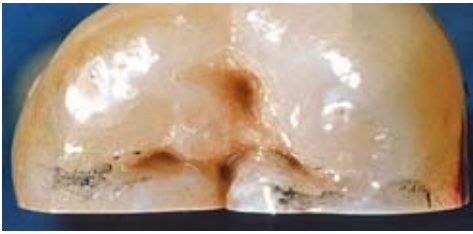
**Fig 8-8** White spots before and after drying of the fissure.

The use of a probe does not improve the diagnostic investigation of pit and fissure caries. Furthermore, a disadvantage of probing with pressure is that enamel areas decalcified at the surface are destroyed and this can accelerate the progression of caries. Drying the surface will reveal an area of decalcification that is a definite sign of caries.

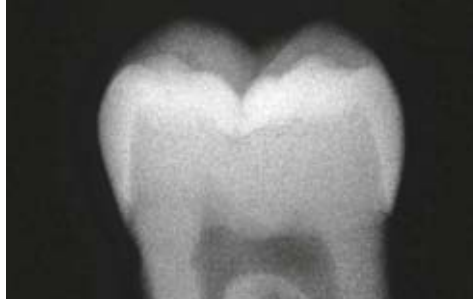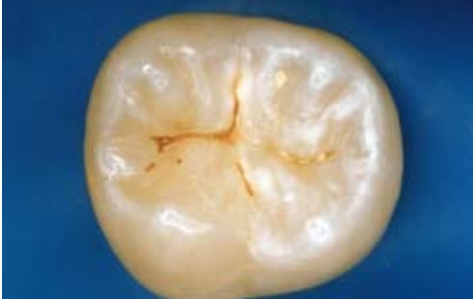Occlusal caries that has penetrated into the dentin can be diagnosed by bitewing radiographs. Dentin caries that is visible on a radiograph but which has an intact surface is generally treated by minimally invasive treatment and restoration (Figs 8-9 and 8-10).

## ■ Fluorescence measurement

Tools enabling caries to be detected early, even when the surface is apparently intact, have been sought for a number of years. The systems now available on the market and suitable for daily use take advantage of the fluorescence of dental hard substance that has been altered by caries.



**Fig 8-9** Left: intact fissure surface with discoloration. Right: no caries despite pronounced fissure discoloration.



**Fig 8-10** Top left: intact fissure surface. Top right: seemingly, the radiograph shows early radiolucency in the dentin. Bottom: pronounced enamel and dentin caries.

When radiant energy is applied to a tooth it causes a temporary transition of certain molecules into an excited state. That energy is then released as the molecules return to their initial state; part of the energy is released into the surrounding tissue as heat, while another part is lost as an emission of light, namely fluorescent radiation. The fluorescent light emitted has a longer wavelength ( $> 680 \text{ nm}$ ) than the light causing the excitation ( $655 \text{ nm}$ ).

This principle was developed into a practical device for caries detection in the form of the DIAGNOdent® (DD) and DIAGNOdent® pen (DD pen) (KaVo, Biberach) (Fig 8-11). Unwanted light is retained by a filter system. An acoustic signal that changes in pitch as the tip of the device is rotated enables the operator to locate the point of highest fluorescence at a specific site without having to look at the display on the device (Fig 8-12). The maximum value is read off after the measuring process. Existing studies prove that the DIAGNOdent based on laser fluorescence has good sensitivity for detecting dentin caries. As previously mentioned, clinical inspection achieves good specificity levels. Therefore, the advantages of the higher specificity and speed of clinical diagnostic examination can usefully be combined with the advantages of this device.



**Table 24-2** Special features of the clinical examination

Caution is advisable during clinical examination because of particular aspects of some children's behavior. The following points should be looked for.
Is there any swelling of the face and/or lymph nodes?
Are there any intraoral swellings? Do these swellings fluctuate on palpation?
Can fistulous tracts be probed? Does any pus exude?
Is the painful tooth sensitive to percussion? What is the tap note like?
Are there any sore mucosal areas on palpation?
Is there mobility of the aching tooth?
If caries is present, the consistency and color of the carious material are of interest.
If pulp is opened, the size and location of the opened site as well as the extent and nature of the bleeding can provide valuable information about inflammation of the pulp.
The informative value of the CO <sub>2</sub> test is limited in small children because of the lack of cooperation and, for psychological reasons, it should therefore be used sparingly.

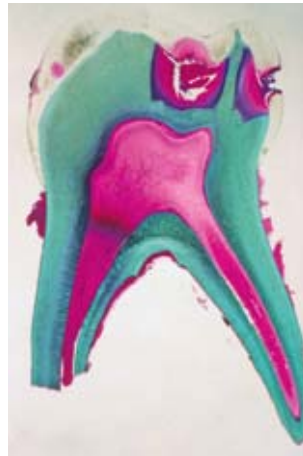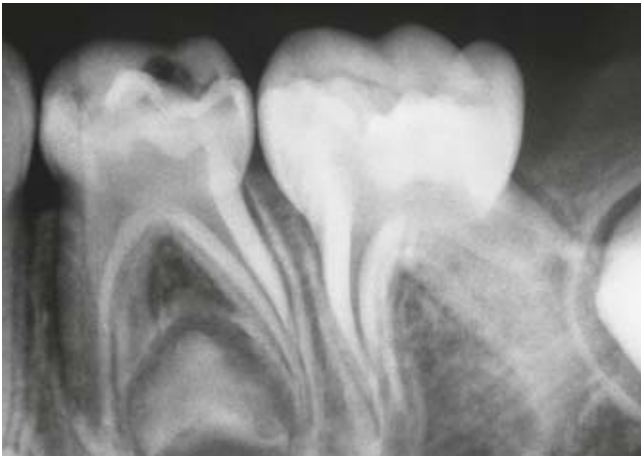
## ■ Reversible and irreversible pulpitis due to caries

Owing to the large pulp cavity and the minimal thickness of enamel and dentin, caries reaches the dentin close to the pulp after only a short time. Initial signs of inflammation in primary tooth pulp can be observed histologically soon after first contact of caries with dentin. At the beginning, this process is still reversible (reversible pulpitis). However, if the caries advances further, it will result in irreversible spread of the inflammation (irreversible pulpitis). These changes do not always involve severe pain. However, if a primary tooth causes persistent pain and/or pain in response to heat, this means the inflammation has spread to the entire pulp of the primary tooth. Sensitivity to percussion means the inflammation has reached the apical or interradicular periodontium. Clinically, it is often very difficult to distinguish between reversible and irreversible pulpitis, especially because the sensitivity test with cold is not very informative in children. In the same primary tooth, healthy, vital areas of pulp can be observed alongside severely inflamed to necrotic pulp segments (Fig 24-1).

## ■ Treatments for reversible pulpitis

### Incomplete (stepwise) caries excavation

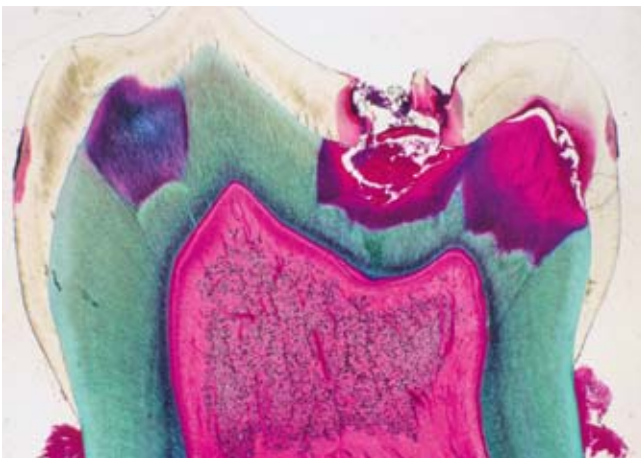
In the case of a vital, symptom-free primary tooth with profound caries, pulp opening can be prevented by incomplete caries excavation. Preparation and thorough excavation of caries close to the pulp are first performed. The carious residual dentin close to the pulp is left in place. The dentin wound is then cleaned and disinfected (eg, with Tubulicid or chlorhexidine). If disinfecting the cavity with hydrogen peroxide, it is important to make sure that polymerization of acrylic resin can be inhibited. After the carious residual dentin has been



**Fig 24-1** Reversible versus irreversible pulpitis

*Left: coronal radiolucencies, but no interradicular or periapical radiolucencies, can be seen on the radiograph of the primary left mandibular first molar.*

*Right: in the histological section through the mesial area of the primary left mandibular first molar, apart from widening of the odontoblast border below the carious lesion and slight proliferation of the blood vessels, no inflammatory changes can be seen. Given appropriate treatment, these are reversible.*



*Left: in the histological section through the middle of the primary first molar, bacterial infiltrates and enlarged blood vessels are visible in the pulp. The entire pulp cavity in the area of the section shows pulpitis changes which are only partly reversible.*

*Right: the histological section through the distal area of the primary first molar shows massive pulp necrosis with opening of the pulp due to the carious process. The pulpal changes are irreversible.*

covered with a glass ionomer cement cavity liner (eg, Vitrebond™), a tight seal is created using an adhesive system and composite resin. Various studies have shown that complete removal of caries is not necessary in deep carious lesions in order to prevent progression of the caries.<sup>17</sup> However, a tight restoration that isolates any bacteria remaining in the cavity is a prerequisite. Individual authors dispense with coverage of the carious residual dentin with a cavity liner.<sup>13</sup> Reopening of the cavity, as has been propounded for stepwise caries excavation, is therefore unnecessary for a symptom-free primary tooth where the restoration is intact.

### Direct pulp capping

If the pulp is opened at points during caries removal from a symptom-free, vital primary tooth, direct pulp capping can be carried out. The opened pulp is covered with a calcium hydroxide material. This is followed by the application of a liner, then tight closure with a composite resin restoration. The use of mineral trioxide aggregate (MTA) is another option (though not very economical).



# Index

## A

abrasion 176, 185  
 accessory canals 12–13  
 acellular afibrillar cementum (AAC) 11  
 acellular extrinsic fiber cementum (AEFC) 11  
 acid attack 26–27  
 acidic drinks 185, 186  
 adhesive luting agents, classification 120–121  
 adhesive systems 115–121  
 adjacent tooth damage 97–103  
   aids to prevent 99–102  
   consequences 98  
   origin 97–98  
 air abrasion 105–107  
 air-polishing technique 106  
 aluminum oxide 105–107, 130  
 amalgam restoration repairs 139  
 amelogenesis 5  
 anorexia nervosa 183, 184  
 antibacterial agents, topical application 53–57  
 antibacterial approaches 53  
   limitations 59  
 apical periodontitis, etiology 207  
 aseptic treatment approach 208  
 attrition 176, 185

## B

bacteria  
   metabolism 15, 33, 59, 246  
   where found 207–208  
 balanced force technique 201  
 Basic Erosive Wear Examination (BEWE) 177–178  
 Bevelshape file 100–101  
 bifidobacteria 40, 41  
 bioactive glass 50, 106  
 bleaching 163–171  
   home 165–167, 170–171  
   household products 170

in-office 169  
 mechanism 164–165  
 over-the-counter products 170  
 procedure 165  
 walking bleach technique 133, 167–168, 170  
 bulimia nervosa 183, 184

## C

c-factor 127  
 calcium content, of drink or food 185  
 calcium fluoride (CaF<sub>2</sub>) 30–31  
 calcium hydroxide 79, 235–240  
 canal inlay 155, 156  
 carbon posts 144  
 caries 14–15, 65–83  
   activity 76–77  
   antibacterial agents for prevention 53–60  
   approximal 71–74  
   CPP-ACP use in prevention 47  
   diagnosis 65–78  
   fluorescence measurement 68–70  
   incomplete (stepwise) excavation 234–235  
   measures to combat vertical transmission 57–58  
   minimally invasive treatment 90–92  
   noninvasive treatment techniques for initial lesions 80–83  
   pit and fissure 66–68, 70–71, 79  
   prevention of progression 79–83  
   in primary dentition 233–240  
   probiotics and 42–43  
   protective and promoting factors 25  
   risk assessment (CRA) 76–78  
   root 74–76  
   selective removal of dentin 109–110  
   smooth surface 65–66  
   understanding 20  
 Carisolv 109–110  
 carrier-based filling systems 220, 221  
 caseins 45–46  
   *see also* CPP-ACP  
 Cavishape file 100  
 cellular intrinsic fiber cementum (CIFC) 11  
 cellular mixed stratified cementum (CMSC) 11  
 cementum 11  
   types 11  
 ceramic restoration repairs 138  
 CEREC system 151–159  
   case studies 153–159  
   aftercare 159  
   amalgam replacement 153–155  
   anterior rehabilitation with veneers 157–158  
   endo-crown 155–157  
   preparation guidelines for ceramic restoration fabrication 152–153  
 cheek retractors 125  
 chemochemical excavation 109–110  
 chlorhexidine (CHX)  
   in caries prevention 54–55, 57–58  
   in root canal irrigation 210  
   in tongue cleaning 255  
 Clearfil SE Bond 117  
 CO<sub>2</sub> laser 107, 108  
 CoJet system 137, 138, 139  
 compomers 124  
 composite resin materials 123–124  
   *see also* direct restorative technology

- composite resin restoration  
   repairs 137–138  
 condenser-based technique 220, 221  
 continuous-wave technique 219  
 core materials 217  
 coronal reconstruction, importance 215–216  
 correlation method 158  
 CPP-ACP 46–49, 185  
 cracked tooth syndrome 223–230  
   clinical examination 228–229  
   clinical picture 227  
   definition 224  
   diagnosis 227–229  
   distribution 225  
   epidemiology 225  
   etiology 224  
   radiologic examination 229  
   restoration and 226, 229  
   symptoms 226–227  
   tooth type 225–226  
   treatment 229–230  
   trial cavity 229
- D**
- demineralization 118  
   inhibition  
     by condensed phosphates 49  
     by fluoride 29  
     by metallic ions 49  
 dental erosion 175–188  
   Basic Erosive Wear Examination (BEWE) 177–178  
   case studies of progression 181  
   CPP-ACP for 48–49, 185  
   diagnosis 175–176  
   etiology 182–185  
   incidence 178  
   localization in dentition 179–180  
   nutritional factors 185  
   occupation and leisure activities and 186  
   patient-related factors 182–185  
   prevalence 178  
   prevention 186–188  
   risk assessment 186
- denticles 12–13  
 dentin 8–11  
   chemical properties 26  
   dysplasias 7–8  
   selective removal 109–110  
 dentin hypersensitivity 223  
 development of teeth 3–5  
 DIAGNOdent pen (DD pen) 69–70, 71, 73, 74  
 diet, and halitosis 250  
 diode laser 107, 108  
 direct pulp capping 235–236  
 direct restorative technology 123–135  
   clinical application 125–131  
   auxiliary instruments 126–127  
   final finishing and polishing 130–131, 134–135  
   layering techniques 127–129  
   light polymerization 129–130  
   optimal operating field creation 125–126  
   composite resin materials 123–124  
   composite resin restoration fabrication procedure 132–135  
 discoloration, etiology 164  
 disinfection  
   alternative approaches 212  
   *see also* root canal irrigation  
 Duraphat 29, 31, 238
- E**
- eating and drinking habits 182–183  
 ecological plaque hypothesis 39  
 electronic apex locator 205  
 enamel 5–8  
   chemical properties 26  
   dysplasias 7–8  
   paraplasias 7  
   structural defects 7  
 Er:YAG laser 107–109  
 Er,Cr:YSGG laser 107, 108  
 erosion *see* dental erosion  
 etch-and-rinse luting agents 120, 147  
 etch-and-rinse systems 115–117, 118, 132, 147–148
- etching, enamel 117  
 ethylene diamine tetra-acetic acid (EDTA) 210  
 extension for prevention principle 97
- F**
- fetor ex ore 245  
 fiber-optic transillumination (FOTI) 71, 73  
 fiber posts 143, 144, 145, 146  
 Filtek Silorane 124  
 finishing 130–131, 134–135  
 fluorapatite (FAP) 25, 26, 29  
 fluorescence measurement 68–70  
 fluoridated hydroxyapatite (FHAP) 26, 27–28, 29  
 fluorides 25–31  
   adsorbed 30  
   demineralization inhibition by 29  
   and dental erosion 187  
   incorporated 30  
   remineralization promotion by 27–28  
   usage recommendations 31  
   *see also* calcium fluoride  
 formaldehyde 240  
 formocresol 240  
 four-step adhesive systems 116
- G**
- Galilean loupes 88  
 gastroesophageal reflux 181, 183–184, 187  
 glide path 200  
 gold-cast cores 143, 144, 145  
 GT hand files 205  
 GTX system 205–206  
 gutta-percha 217
- H**
- Halimeter 252–253  
 halitophobia 259  
 halitosis 245–259  
   causes of odor 246–248  
   cofactors 250  
   diagnostic procedure 248–254

- forms 245–246  
 informing patient 259  
 patient history 249  
 prevalence 245  
 pseudohalitosis 245, 248, 249, 258–259  
 sources of odor 246–248, 252  
 treatment in dental practice 254–258
- hand instruments 102  
 HEMA 119, 128  
 Hertwig's epithelial root sheath 3–5  
 hybrid layer 118, 119  
 hydrofluoric acid 138, 157, 158  
 hydroxyapatite (HAP) 26, 27  
 hypersalivation 184  
 hyposalivation 188
- I**
- iatrogenic damage 97–98  
 ICDAS system 67  
 incomplete caries excavation 234–235  
 infiltration technique 80–81, 83  
 Intensiv Margin Shaper 100–101  
 iodoform paste 209, 236  
 IPS e.max CAD ceramic 155, 156, 158, 159  
 irreversible pulpitis 234, 235  
 treatment 236–237
- K**
- K-files 201, 202, 206  
 Kepler loupes 88
- L**
- lactobacilli 40, 41, 42–43, 75  
 laser preparation 107–109  
 lateral condensation technique 219, 221  
 layering techniques 127–129  
 light polymerization 129–130  
 loupes 87, 88
- M**
- M wire 205  
 magnification aids 87–92, 102
- manual dynamic irrigation (MDI) 212  
 matrices 99, 126–127, 132  
 metal matrices 99  
 metal points 217  
 metal posts 143, 145  
 metal restoration repairs 139  
 microbial homeostatis 59  
 microscopes, operating 87, 89  
 MicroSeal System 220, 221  
 milk proteins 45  
 mineral trioxide aggregate (MTA) 235, 236, 240  
 minimally invasive preparation 97  
 minimally invasive restorations 90–92
- O**
- odontogenesis 3  
 odor diagnostics, instrumental 252–253  
 one-step adhesive systems 116, 117  
 operating microscopes 87, 89  
 Optibond FL 117, 132  
 oral hygiene  
 action 21–22  
 and halitosis 248, 249, 255–256  
 motivation 19–21  
 overcoming implementation deficits 22–24  
 practical implications for dental team 24  
*see also* teeth cleaning  
 oral infections 39  
 organoleptic examination 251–252  
 ormocers 124  
 oscillating instruments 99–102  
 Oswald maturation 156  
 Owen, lines of 8
- P**
- passive ultrasonic irrigation (PUI) 212  
 paste fillings 218, 221  
 patency file 200, 211  
 PathFiles 200  
 pellicles 185
- periodontitis  
 etiology 207  
 probiotics and 42–43  
 understanding 20  
 phosphate content, of drink or food 185  
 photodynamic therapy (PDT) 212  
 planning, oral hygiene 22–23  
 polishing 130–131, 134–135  
 post-and-core restoration 143, 148  
 post systems 143–149  
 povidone iodine (PI), in caries prevention 55–56, 57–58  
 Prepcontrol system 100–101  
 prevention of extension  
 approach 97  
 primary dentition, endodontology in 233–240  
 clinical examination 234  
 history taking 233  
 materials for endodontic measures 240  
*see also* irreversible pulpitis;  
 pulp necrosis; reversible pulpitis  
 primary-primary prevention 57–58  
 prismatic loupes 88  
 probiotics 39–43  
 ProTaper instruments 201  
 proton pump inhibitors 187  
 Proxoshape file 100  
 pseudohalitosis 245, 248, 249, 258–259  
 pulp 12–13  
 devitalized, with periradicular radiolucency 207  
 vital 207  
 zones 12  
 pulp necrosis, treatment 238–239  
 pulpectomy 236–237  
 pulpitis 15–16  
 pulpotomy 236
- Q**
- quantitative laser fluorescence (QLF) 70

**R**

radiography, in caries diagnosis 71–73, 75  
 Raschkow, nerve plexus of 12  
 remineralization 45  
   promotion  
     by bioactive glass 50  
     by CPP-ACP 46–48  
     by fluoride 27–28  
     by milk proteins 45  
 replacement therapy 41  
 Resilon 217  
 resin patch 82, 83  
 restoration repairs 137–140  
 Retzius, lines of 5  
 reversible pulpitis 234, 235  
   treatments 234–236  
 rinsing 31  
 root canal filling 215–221  
   importance 215  
   materials 216–217  
   quality 215  
   rating of methods 221  
   requirements 216  
   techniques 218–220  
 root canal irrigation 207–213  
   alternate rinsing 210, 211  
   choice of irrigant 209–210  
   disinfection strategies 208–209  
   efficacy 210  
   heating of irrigant 212  
   importance 207  
   manual 211–212  
   protocol 213  
   requirements for irrigants 209  
 root canal preparation 193–206  
   anatomy of root canals 196–197  
   chemomechanical 208  
   modern principles 198–203  
     apical gauging 202  
     apical patency 200  
     apical resistance form 202, 218  
   crown down preparation 199  
   deep shape 203  
   delayed length measurement 200  
   glide path 200  
   inlay-shaped access cavity 198

  instrumentation 201  
     straight line access 198–199  
   Ni-Ti instrument properties 203–204  
   for post placement 145–147  
   risk analysis 193–195  
   techniques 205–206  
 root filling cements 217  
 root filling materials 216  
 rotary Ni-Ti instruments 199,  
   200, 201, 202–203  
   fractures 204  
   material properties 203–204  
 rubber dams 125–126

**S**

saliva, protective actions 185  
 sealants 217  
 sealing 79–83  
   conventional 80, 83  
 self-adhesive luting agents 120–121, 147  
 self-etch luting agents 120, 147  
 self-etch systems 116, 117,  
   118–119, 147–148  
 self-observation 23  
 separating rings 126–127, 133  
 silanization 108, 138, 139, 146,  
   147  
 silicatization 147  
 siloranes 124  
 silver diamine fluoride (SDF) 53,  
   57, 61, 238  
 single-cone technique 218, 221  
 sodium hexametaphosphate 49  
 sodium hypochlorite (NaOCl)  
   146, 209, 212–213  
 SONICflex airscaler 101–102  
 stannous fluoride 187  
 stepwise caries excavation 234–235  
 streptococci 33, 34, 36, 40–42,  
   57, 75  
 subjective perception, scientific  
   evidence vs. 87–88  
 Syntac classic 117

**T**

teeth cleaning  
   and dental erosion 185, 187  
   and rinsing 31

*see also oral hygiene*

tetracycline 9, 11  
 Thermafil 220, 221  
 thermoplastic filling methods 219  
 Thomas spanner key 201  
 TiF4 187  
 tongue  
   assessment 254  
   cleaning 255–258  
   morphology 246  
 triclosan, in caries prevention 56  
 two-step adhesive systems 119

**V**

visual gauging 206  
 volatile sulfur compounds (VSCs)  
   246, 252–253, 256  
 vomiting 183, 184, 187  
 von Ebner, lines of 8

**W**

walking bleach technique 133,  
   167–168, 170  
 warm vertical condensation  
   technique 219–220, 221  
 wedges 88, 89, 126, 132  
 Weil, zone of 12  
 white spot lesions, CPP-ACP in  
   treatment 47–48  
 white teeth 163  
 Winkel tongue coating index 254

**X**

xerostomia 188  
 xylitol, role in caries prevention  
   33–37, 57–58  
   clinical evidence 34  
   clinical guidelines 37  
   cost-benefit perspective 35–36  
   doses 34, 35  
   patients benefiting 36  
   products 36–37  
   side effects 34

**Z**

zirconium posts 143, 144–145