

Practical Lessons in Endodontic Treatment

PRACTICAL LESSONS IN ENDODONTIC TREATMENT

Donald E. Arens, DDS, MSD

Alan H. Gluskin, DDS

Christine I. Peters, DMD

Ove A. Peters, DMD, MS, PhD

With contributions by

David C. Brown, BDS, MDS, MSD

Joe H. Camp, DDS, MSD

Gerald N. Glickman, DDS, MS, MBA, JD

Ron Lemon, DMD



Quintessence Publishing Co, Inc

Chicago, Berlin, Tokyo, London, Paris, Milan, Barcelona,
Istanbul, Moscow, New Delhi, Prague, São Paulo, and Warsaw

Library of Congress Cataloging-in-Publication Data

Practical lessons in endodontic treatment / Donald E. Arens ... [et al.].

p. ; cm.

ISBN 978-0-86715-483-2 (softcover)

1. Endodontics. I. Arens, Donald E.

[DNLM: 1. Dental Pulp Diseases--therapy. 2. Root Canal Therapy--methods.

WU 230 P895 2009]

RK351.P73 2009

617.6'342--dc22

2009010042



© 2009 Quintessence Publishing Co, Inc

Quintessence Publishing Co, Inc

4350 Chandler Drive

Hanover Park, IL 60133

www.quintpub.com

All rights reserved. This book or any part thereof may not be reproduced, stored in a retrieval system, or transmitted in any form or by any means, electronic, mechanical, photocopying, or otherwise, without prior written permission of the publisher.

Editor: Bryn Goates

Cover and internal design: Gina Ruffolo

Production: Sue Robinson and Patrick Penney

Printed in China

Contents

Contributors *viii*
Preface *ix*

PART ONE *Examination and Diagnosis*

- 1** Medical Evaluation and Antibiotic Precautions 3
- 2** Clinical Examination and Assessment of an Endodontic Patient 11
- 3** Radiographic Examination and Interpretation 21
- 4** Diagnosis 37
- 5** Treatment Documentation and Record Keeping 47

PART TWO *Treatment Strategies and Decision-Making*

- 6** Managing the Apprehensive Patient 55
- 7** Endodontic Treatment Planning: Tooth-related Considerations 61
- 8** Endodontic vs Implant Therapy for a Single Tooth 69
- 9** Infection and Success Rates 73
- 10** Presenting a Treatment Plan to a Patient 77

PART THREE *Preparation for Treatment*

- 11** Endodontic Instruments and Equipment 85
- 12** Clinical Infection Control 93
- 13** Value of Magnification 103
- 14** Local Anesthesia 107
- 15** Guidelines for Rubber Dam Use 115

PART FOUR *Canal Instrumentation: Shaping, Disinfection, and Case Management*

- 16** Access Preparation and Orifice Identification 127
- 17** Instrument and Material Choices 137
- 18** Root Canal Irrigation 145
- 19** Strategies to Reach the Root Apex 153
- 20** Shaping and Cleaning the Anatomically Uncomplicated Canal 161
- 21** Shaping and Cleaning the Anatomically Complicated Canal 169
- 22** Locating and Opening the Mineralized Canal 177
- 23** Managing the Obstructed Canal 183
- 24** Mishaps During Root Canal Shaping 193
- 25** Mishaps in Shaping the Apical Third 201
- 26** Pain After Cleaning and Shaping 205
- 27** Single-Visit vs Multiple-Visit Therapy 213
- 28** Interappointment Temporization 221
- 29** Final Steps Before Obturation 227

PART FIVE *Endodontic Obturation*

- 30** Guidelines for Sealers and Solid Core Materials 233
- 31** Materials and Methods of Obturation 239
- 32** Posttreatment Pain After Obturation 253
- 33** Responding to Posttreatment Disease 257
- 34** Challenges and Mishaps in Obturation 263

PART SIX *Emergency and Adjunctive Endodontic Procedures*

- 35** Endodontic Emergencies and Their Treatment 271
- 36** Vital Pulp Capping 277
- 37** Apexogenesis and Pulpotomy 283
- 38** Apexification 289
- 39** Pulpal Treatment in Primary Teeth 293
- 40** Treating the Avulsed Tooth 297
- 41** Bleaching Techniques for Nonvital and Vital Teeth 305
- 42** Restoration of Endodontically Treated Teeth 315

Suggested Readings 323

Index 329

Contributors

Donald E. Arens, DDS, MSD

Professor Emeritus
Department of Endodontics
School of Dentistry
Indiana University
Indianapolis, Indiana

David C. Brown, BDS, MDS, MSD

Associate Professor
Department of Endodontics
Arthur A. Dugoni School of Dentistry
University of the Pacific
San Francisco, California

Joe H. Camp, DDS, MSD

Adjunct Professor
Department of Endodontics
School of Dentistry
University of North Carolina
Chapel Hill, North Carolina

Gerald N. Glickman, DDS, MS, MBA, JD

Professor and Chair
Department of Endodontics
Baylor College of Dentistry
Texas A & M Health Science Center
Dallas, Texas

Alan H. Gluskin, DDS

Professor and Chairperson
Department of Endodontics
Arthur A. Dugoni School of Dentistry
University of the Pacific
San Francisco, California

Ron Lemon, DMD

Associate Dean for Advanced Education
Program Director in Endodontics
School of Dental Medicine
University of Nevada, Las Vegas
Las Vegas, Nevada

Christine I. Peters, DMD

Associate Professor
Department of Endodontics
Arthur A. Dugoni School of Dentistry
University of the Pacific
San Francisco, California

Ove A. Peters, DMD, MS, PhD

Professor and Director of Endodontic Research
Department of Endodontics
Arthur A. Dugoni School of Dentistry
University of the Pacific
San Francisco, California

Preface

Contemporary endodontic therapy is based on a sound scientific foundation, but its clinical success is largely dependent on how well clinicians access, clean, shape, disinfect, and seal root canals. This text is first and foremost a practical manual, not a reference book. While we refer to the literature as necessary to corroborate and/or reinforce concepts with scientific evidence, we focus on the essential, practical strategies for providing reliable nonsurgical endodontic care to patients.

Traditional endodontic textbooks often overwhelm readers with the amount of theoretical information presented. In this book, every effort has been made to provide straightforward discussions that emphasize key concepts. Following the tradition of this book's popular predecessor, *Practical Lessons in Endodontic Surgery* (Quintessence), we have adopted an easy-to-use, workbook approach to nonsurgical root canal therapy. Each lesson presents a different component of endodontic therapy and includes simple step-by-step clinical procedures and concise tips and recommendations. Readers will find helpful solutions to myriad endodontic challenges.

With more than of 150 years of combined experience both in developing and teaching graduate endodontic programs and in managing private practices, we have had ample opportunity to critically assess and validate all the procedural changes and technologic improvements demonstrated in the text. We have integrated the latest clinical concepts and technologies with tried-and-true strategies in the diagnosis, treatment planning, and execution of endodontic therapy. Our goal is to assist dentists and their support staffs in the implementation of technologic and procedural recommendations that simplify daily routine, build confidence and skill, enhance treatment outcomes, and make root canal treatment more rewarding, profitable, and fun.

We wish to thank our families for their advice, understanding, and encouragement during the preparation of this manuscript and throughout the countless hours in editing and organization of the text. Few projects of this scope are achieved without the selfless devotion of family. It is to our families that we fondly dedicate this book.

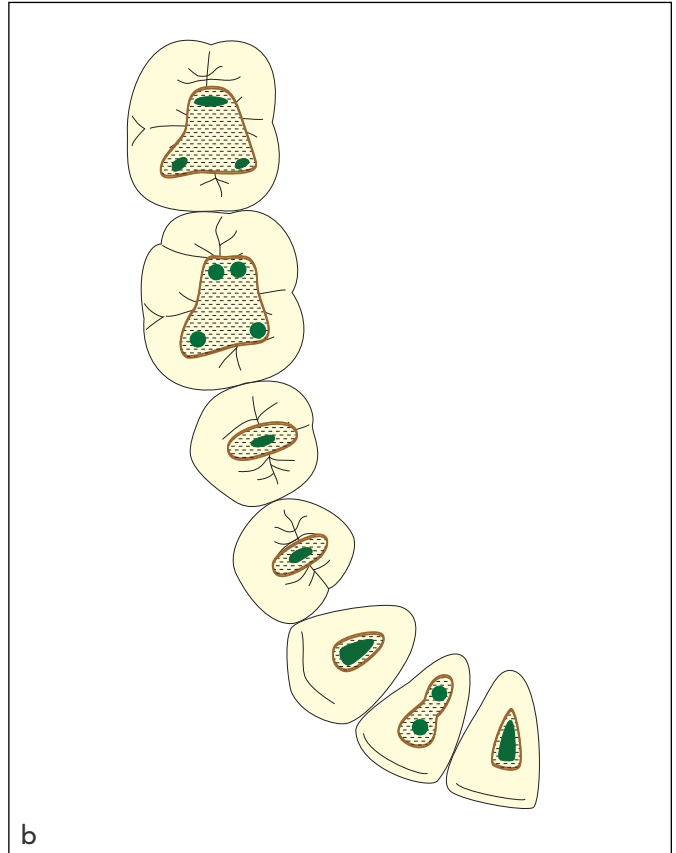
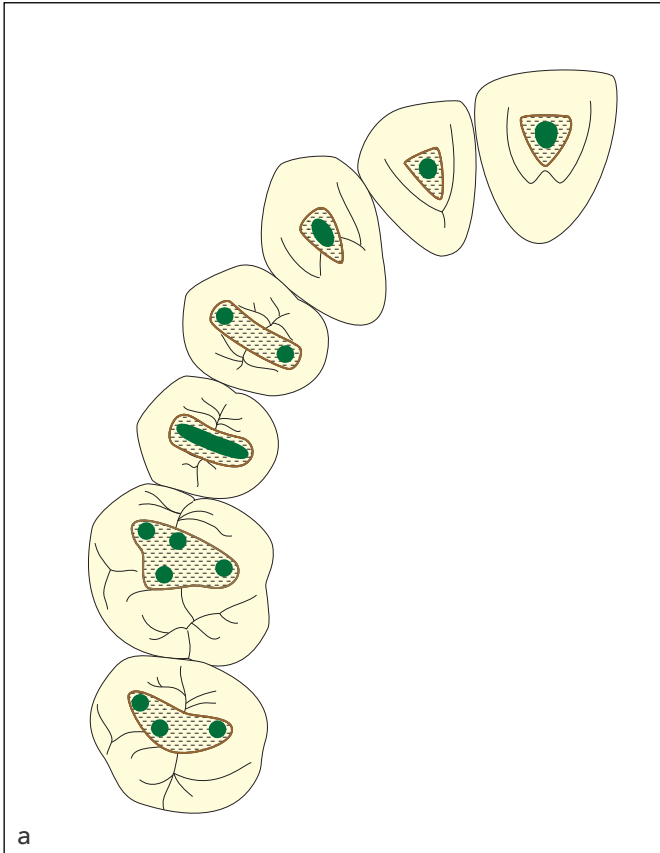


Fig 16-4 Schematics demonstrating the number and arrangement of root canal positions in relation to the occlusal table. (a) Maxillary arch. (b) Mandibular arch.

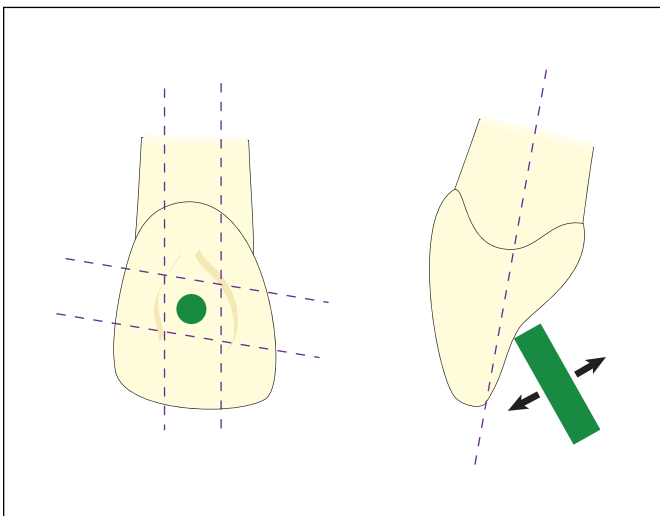


Fig 16-5 Schematic demonstrating the penetration into the pulp chamber of a maxillary incisor. Note the angulation of the bur to the lingual surface. This angulation needs to be carefully assessed to avoid perforation toward the facial aspect.

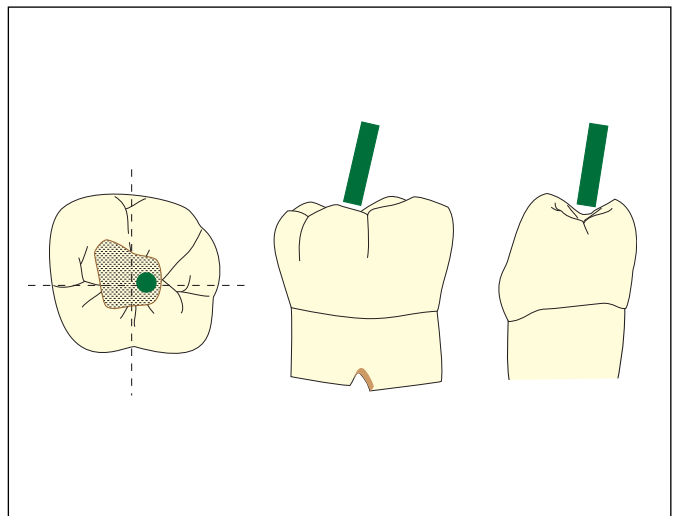
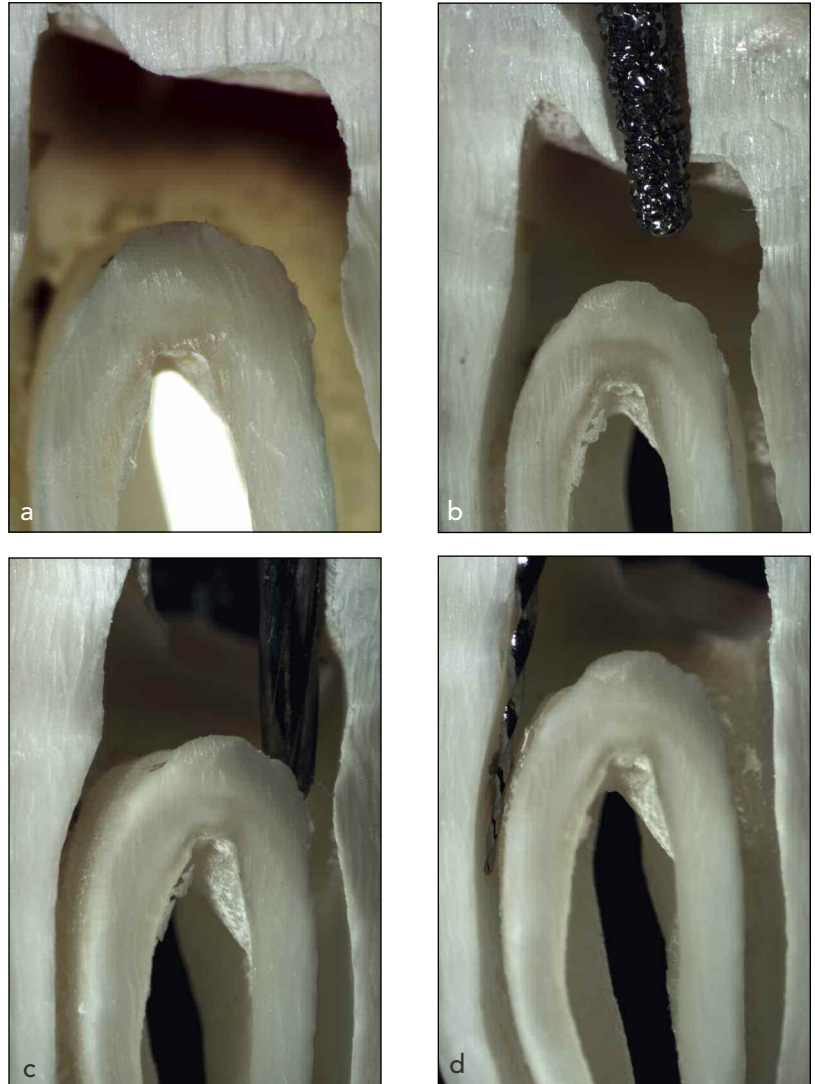


Fig 16-6 Schematic demonstrating penetration into the pulp chamber of a mandibular molar. Note the angulation of the bur which should match the lingual tilt of the clinical crown and also the entry angle to the distal root canal.

Fig 16-7 Important steps during access cavity preparation in a mandibular molar demonstrated on an extracted tooth using a microscope. (a) Lateral section through the pulp chamber. (b) Penetration into dentin with end-cutting diamond bur. (c) Refining access with non-end-cutting EndoZ bur (Dentsply). (d) Removal of dentin triangles, here with a lateral-cutting nickel-titanium rotary instrument used with brushing movements.



done from the lingual, aiming right into the middle of the occlusal surface. Remember that maxillary anterior teeth stand somewhat protruded (Fig 16-5) in the arch, similar to the slight lingual tilt of the mandibular molar crowns.

For posterior teeth, access is typically started in the middle of the occlusal surface, with the bur directed toward the expected greatest pulp volume. For example, in maxillary molars, the mesiobuccal pulp horn is usually the tallest, but the palatal one is the largest. Therefore, the bur is positioned in the main occlusal pit and directed slightly toward the palatal. Figure 16-6 demonstrates the access entry angle to a mandibular molar in which the distal canal has the largest volume.

It is best to begin with a smaller version of the final access cavity and progress into the enamel and dentin. As soon as an opening into the pulp is felt or seen, switch to a bur that is not end-cutting.

Enlarging the opening—The unroofing

With a bur with a noncutting tip, enlarge the opening to expose all root canal orifices, using lateral movements. It is useful to wash away debris frequently to make observation easier; verify that unroofing of the pulp chamber is complete with a probe. If undercuts and pulp horns are noticed, use a small round bur in pulling motions to remove those areas where needed.

Refining and flaring the cavity outline

Next, refine the overall outline so that there is a slightly divergent cavity. At this point, you should be able to see all canal orifices with one direct line of sight and to position a probe into the orifices without excessive wall contact. In mandibular molars, start the access in the central pit, and angle the bur slightly to the distal. The cavity is mapped out and unroofed as explained earlier (Fig 16-7).

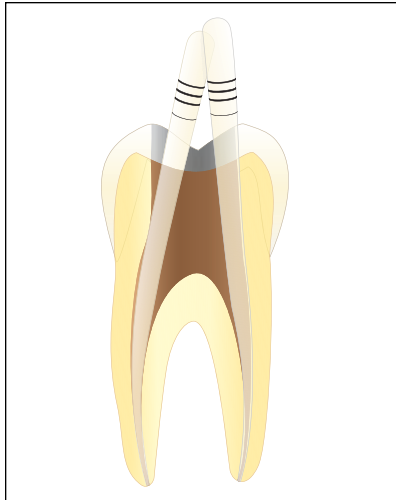


Fig 31-3 Root canal dried with paper points.

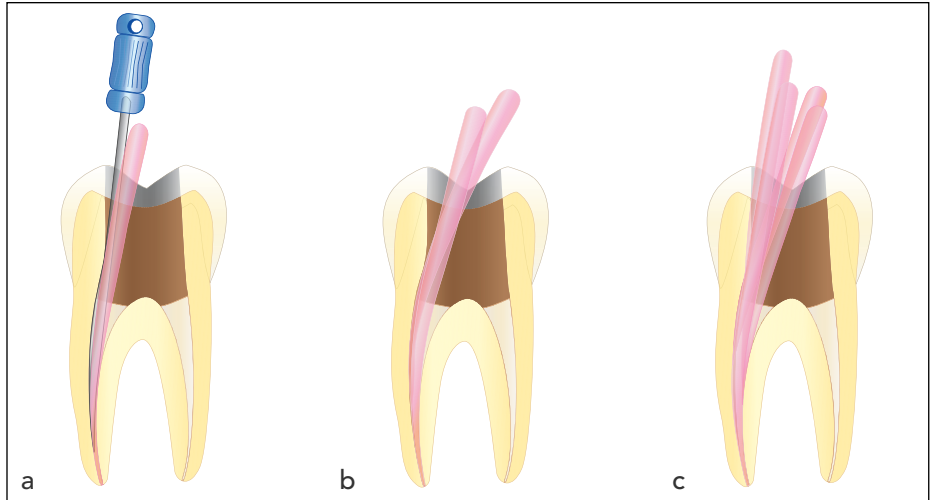


Fig 31-4 Lateral condensation of the mesial root canal of a mandibular molar using a finger spreader. (a) Master cone and finger spreader. (b) First accessory cone seated. (c) Multiple cone-filled root canal.

3. Coat the master cone with sealer, and insert it to the predetermined length using a slight pumping motion to allow trapped air and excess sealer to flow in a coronal direction.
4. Slowly position the preselected spreader alongside the master cone to the marked length and hold with measured apical pressure for approximately 10 seconds.
5. During this procedure, the master cone is pushed laterally and vertically as the clinician feels the compression of the gutta-percha.
6. Rotate the spreader by 180 degrees several times to disengage it from the gutta-percha and facilitate its removal from the canal (Fig 31-4a).
7. Fill the void created by the spreader with lightly sealer-coated accessory gutta-percha cones. Using auxiliary cones equal to or smaller than the spreader prevents voids (Fig 31-4b).
8. Repeat the procedure, inserting several fine cones and moving to larger spreaders and cones until the entire canal is filled (Fig 31-4c).

Caution: Before searing off the protruding cones, take a radiograph to verify the apical condensation of gutta-percha. Once complete and thorough obturation of the apical third is confirmed, it is appropriate to sear off the coronal part of the cones that are protruding into and obscuring the pulp chamber during obturation.

- In multirooted teeth, it may be helpful to fill no more than one or two root canals at a time to avoid confusion and obscured vision.

- The use of matching (and not larger) accessory cones, compared to the spreader size, prevents the creation of voids that reduce filling density and provide potential pathways for microleakage.

Sealer coating and warm compaction of core materials

Thermoplastic obturation using heat-softened gutta-percha can fill accessory canals and communications, promoting the movement of softened gutta-percha into lateral canals and isthmuses. This allows for the filling of canals with a higher volume of core material. On the other hand, it can also result in material extrusion into the periapical area because of the enhanced flow characteristics, especially in cases where the apical foramen has inadvertently been overinstrumented. Clinically, overfilling has been shown to lead to successful healing; however, foreign body reactions and the extrusion of contaminated debris are possible. Confining the root filling to the canal space has predictably shown higher success rates.

Warm vertical condensation

1. Fit a cone slightly short (0.5 mm) of the WL, and verify the fit by testing for tug back. This step produces a cone that is wider in diameter than the prepared apical exit. As such, if the master cone fits well, hydraulic pressure during compaction should not produce an overfill.
2. Cement the cone into the root canal. In the traditional technique for thermoplasticizing gutta-percha, a heat carrier



Fig 31-5 (a) Resilon. (b) Epiphany SE Self-Etch Sealer (Pentron Clinical Technologies).



Fig 31-6 RealSeal.



Fig 31-7 Resinate.

- (eg, Touch 'n Heat [SybronEndo] or a flame-heated plugger) is pushed apically into the center of the master cone.
- Remove the gutta-percha in increments, periodically moving the heated instruments further into the root canal. Use a prefitted cold plugger to condense the mass of gutta-percha in condensation waves until the apical 3 to 5 mm of gutta-percha is compacted.
 - Wipe excess gutta-percha from the utilized pluggers with gauze.
 - Once the apical condensation is confirmed radiographically, repeat the condensation protocol again to add and compact gutta-percha to backfill the coronal portions of the canal.
 - Repeat this procedure until the canal is filled in increments from the apical endpoint to the coronal orifice.
 - Thermoplastic technique can also be used with other core materials (eg, Resilon).

Caution: During condensation with pluggers, avoid excessive force, which could result in root fractures. Proper compaction technique with a cold plugger requires a circumferential ver-

tical motion of the plugger along the wall of the root canal without wedging the plugger.

ADHESIVE OBTURATION SYSTEMS

Adhesive obturation systems that are chemically very similar include Resilon (Fig 31-5), RealSeal (SybronEndo) (Fig 31-6), and Resinate (Obtura Spartan) (Fig 31-7):

- Resilon material is a thermoplastic synthetic polymer-based root canal filling material.
- Based on polymers of polyester, Resilon material contains bioactive glass and radiopaque fillers. It performs like gutta-percha, has the same handling properties, and for retreatment purposes may be softened with heat or dissolved with solvents such as chloroform.