

# Bonded Porcelain Restorations in the Anterior Dentition: A Biomimetic Approach



**Pascal Magne**, PD, DR MED DENT

Senior Lecturer  
Department of Fixed Prosthodontics and Occlusion  
University of Geneva  
School of Dentistry  
Geneva, Switzerland

**Urs Belser**, PROF, DR MED DENT

Professor and Head  
Department of Fixed Prosthodontics and Occlusion  
University of Geneva  
School of Dentistry  
Geneva, Switzerland



Quintessence Publishing Co, Inc  
Chicago, Berlin, London, Copenhagen, Tokyo, Paris, Barcelona, Milano,  
São Paulo, New Delhi, Moscow, Prague, Warsaw, and Istanbul

# TABLE OF CONTENTS



FOREWORD	19
PREFACE	20

## CHAPTER 1

---

UNDERSTANDING THE INTACT TOOTH AND THE BIOMIMETIC PRINCIPLE	23
---	----

- Biology, Mechanics, Function, and Esthetics
- Optimal Compliance and Flexibility
- Rationalized Anterior Tooth Shape
- Mechanics and Geometry During Function
- Physiologic Enamel Cracking and the DEJ
- Natural Tooth Aging and Enamel Thinning
- Biomimetics Applied to Mechanics

## CHAPTER 2

---

NATURAL ORAL ESTHETICS	57
------------------------	----

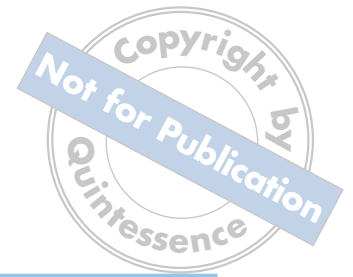- General Considerations
- Fundamental Criteria
- Esthetic Integration

## CHAPTER 3

---

ULTRACONSERVATIVE TREATMENT OPTIONS	99
-------------------------------------	----

- Chemical Treatments and Biomimetics
- Nightguard Vital Bleaching
- Microabrasion and Megabrasion
- Nonvital Walking Bleach Technique
- Reattachment of a Tooth Fragment
- Simplified Direct Composites



## C H A P T E R 4

---

### EVOLUTION OF INDICATIONS FOR ANTERIOR BONDED PORCELAIN RESTORATIONS

129

- Historic Perspective
- Type I: Teeth Resistant to Bleaching
- Type II: Major Morphologic Modifications
- Type III: Extensive Restoration in the Adult
- Combined Indications
- Biologic Considerations
- Perspectives for Occlusal Veneers in Posterior Teeth

## C H A P T E R 5

---

### INITIAL TREATMENT PLANNING AND DIAGNOSTIC APPROACH

179

- Interactive Patient-Operatory-Laboratory Relationships
- Patient Management by the Operatory Team
- Patient Management by the Laboratory Team
- Treatment Planning and Initial Therapy
- Diagnostic Waxup
- Diagnostic Mock-up
- Peculiar Cases
- Summary of Diagnostic Approaches
- Clinical Photography
- Shade Documentation

## C H A P T E R 6

---

### TOOTH PREPARATION, IMPRESSION, AND PROVISIONALIZATION

239

- General Considerations
- Tissue Reduction
- Margin Configuration and Localization
- Peculiar Situations
- Immediate Dentin Bonding
- Definitive Impressions
- Direct Provisionals and Provisional Bonding



## C H A P T E R 7

### LABORATORY PROCEDURES

---

293

- Choice of Restorative Material and Technique
- Master Casts in the Refractory Die Technique
- Ceramic Layering and Finishing
- Special Effects
- Configuration of the Ceramic Workpiece

## C H A P T E R 8

### TRY-IN AND ADHESIVE LUTING PROCEDURES

---

335

- Choice of Luting Composite Resin
- Try-in and Preparatory Steps
- Conditioning of the Ceramic Surface
- Conditioning of the Tooth Surface
- Placement of the Ceramic Restoration
- Final Adjustments and Occlusal Control
- Special Considerations

## C H A P T E R 9

### MAINTENANCE AND REPAIRS

---

371

- Maximum Performance, Reduced Maintenance
- Routine Professional Hygiene
- Complications and Repairs
- Replacement of Class 3 Composite

---

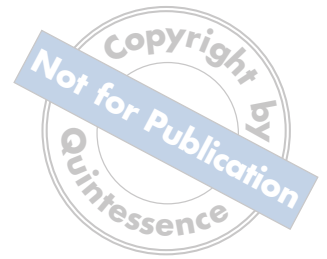### GUIDE TO CLINICAL CASES

387

### INDEX

400

# FOREWORD



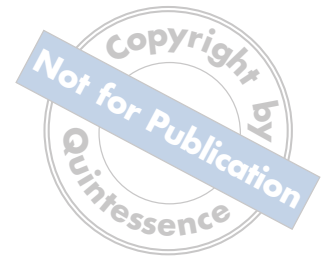It is with considerable pleasure that I write the foreword to Dr Magne and Prof Belser's book, which takes the science of esthetic dental reconstruction to a new level both clinically and academically. Dr Magne spent 2 years as a visiting associate professor in the Minnesota Dental Research Center for Biomaterials and Biomechanics at the University of Minnesota, where many of the ideas promulgated in this book were hotly debated, refined, and tested in a modeling and experimental environment. In this book, the clinician will find all that he or she could wish for in terms of indications and the classic clinical steps for tooth preparation, laboratory procedures, adhesive luting procedures, and maintenance protocol. Those who have heard Dr Magne lecture will not be disappointed. In fact, they will find much more that is practically and intellectually satisfying.

The central philosophy of the book is the biomimetic principle, that is, the idea that the intact tooth in its ideal hues and shades, and perhaps more importantly in its intracoronal anatomy and location in the arch, is the guide to reconstruction and the determinant of success. The approach is basically conservative and biologically sound. This is in sharp contrast to the porcelain-fused-to-metal technique, in which the metal casting with its high elastic modulus makes the underlying dentin hypofunctional. The goal of the authors' approach is to return all of the prepared dental tissues to full function by the creation of a hard tissue bond that allows functional stress to pass through the tooth, drawing the entire crown into the final esthetic result.

I hope that this book will receive a wide readership and that its principles will be carefully studied and become fully established in teaching and research, as well as de rigueur in the practice of restorative dentistry.

William H. Douglas, BDS, MS, PhD  
Director, Minnesota Dental Research Center for Biomaterials and Biomechanics;  
Chair, Department of Oral Science, University of Minnesota  
Minneapolis, Minnesota

# PREFACE

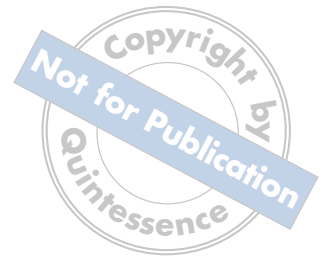

The most exciting developments in dentistry have emerged within the past decade. Oral implant dentistry, guided tissue regeneration, and adhesive restorative dentistry are strategic growth areas both in research and in clinical practice. However, the many advances in dental materials and technology have generated a plethora of dental products in the marketplace. Clinicians and dental technicians are faced with difficult choices as the number of treatment modalities continues to grow. Further, changes in technology do not always simplify technique or decrease treatment costs. Prudence and wisdom need to be combined with knowledge and progress when it comes to improving our patients' welfare.

In this perplexing context, no one will contest the need for less expensive, satisfactory, and rational substitutes for current treatments. The answer might come from an emerging interdisciplinary biomaterial science called biomimetics.<sup>1</sup> This concept of medical research involves the investigation of the structure and physical function of biologic "composites" and the design of new and improved substitutes. Biomimetics in dental medicine has increasing relevance. The primary meaning for dentistry refers to processing material in a manner similar to that by the oral cavity, such as the calcification of a soft tissue precursor. The secondary meaning refers to the mimicking or recovery of the biomechanics of the original tooth by the restoration. This, of course, is the goal of restorative dentistry.

Several research disciplines in dental medicine have evolved with the purpose to mimic oral structures. However, this nascent principle is applied mostly at a molecular level, with the aim to enhance wound healing, repair, and regeneration of soft and hard tissues.<sup>2,3</sup> When extended to a macrostructural level, biomimetics can trigger innovative applications in restorative dentistry. Restoring or mimicking the biomechanical, structural, and esthetic integrity of teeth is the driving force of this process. Therefore, the objective of this book is to propose new criteria for esthetic restorative dentistry based on biomimetics.

Biomimetics in restorative dentistry starts with an understanding of hard tissue structure and related stress distribution within the intact tooth, which is the focus of the opening chapter of this book. It is immediately followed by a systematic review of parameters related to natural oral esthetics. Because the driving forces of restorative dentistry are maintenance of tooth vitality and maximum conservation of intact hard tissues, a brief chapter describes the ultraconservative treatment options that can precede a more sophisticated treatment. The core of the book centers on the application of the biomimetic principle in the form of bonded porcelain restorations (BPRs). The broad spectrum of indications for BPRs is described, followed by detailed instruction on the treatment planning and diagnostic approach, which is the first step in learning this technique. The treatment is then described step-by-step, including tooth preparation and impression, laboratory procedures related to the fabrication of the ceramic workpiece, and its final insertion through adhesive luting procedures. The book ends with discussion of the follow-up, maintenance, and repair of BPRs.



I would have been unable to achieve this work without the valued collaboration of other dentists, dental technicians, specialists, and researchers. We should always remember that a key element for successful and predictable restoration is teamwork and an essential ingredient for teamwork is humility, to consider others better than oneself. We must try to serve each other rather than expect to be served.

I am fortunate to have studied under Prof Urs Belser; his teaching and guidance have been invaluable to me.

Special thanks goes to Drs William Douglas, Ralph DeLong, Maria Pintado, Antheunis Versluis, and Thomas Koriath at the University of Minnesota for their help and friendship during my 2-year research scholarship there. They expanded my vision and knowledge of scientific research in biomaterials and biomechanics.

I extend appreciation to Michel Magne, CDT, for his significant contributions to the chapter on laboratory procedures and for his skills in fabricating the ceramic restorations for all of the cases in this book. I also acknowledge my patients, who indirectly contributed to the realization of this book, and the private practitioners who donated extracted teeth for the studies and illustrations. Special thanks in this regard goes to Drs Rosa Serrano of Geneva, Switzerland, and José de Souza Ne-grão of São Paulo, Brazil.


Finally, I give honor and glory to my Lord and Savior, Jesus Christ, who has made all of my projects possible through his gracious love.

Pascal Magne

#### References

1. Sarikaya M. An introduction to biomimetics: A structural viewpoint. *Microsc Res Tech* 1994;27:360–375.
2. Slavkin HC. Biomimetics: Replacing body parts is no longer science fiction. *J Am Dent Assoc* 1996;127:1254–1257.
3. Mann S. The biomimetics of enamel: A paradigm for organised biomaterial synthesis. *Ciba Found Symp* 1997;205:261–269.

Copyright by  
Not for Publication  
Quintessence

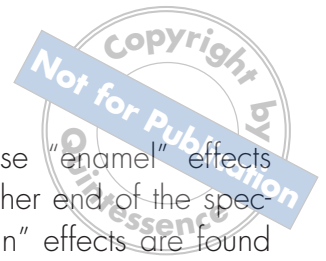





# UNDERSTANDING THE INTACT TOOTH AND THE BIOMIMETIC PRINCIPLE

Mimicry in the field of science involves reproducing or copying a model, a reference. If we as dentists want to replace what has been lost, we need to agree on what is the correct reference. The accepted frame of reference must be the same for the entire profession, and it should be timeless and unchanging. Once this is established, we can then construct appropriate research designs, devise valid concepts, and create rational dental treatment plans. For the restorative dentist, the unquestionable reference is the intact natural tooth. Remains of Inca civilization in South America as well as mummies in Egypt<sup>1</sup> demonstrate age-old principles: the original number, dimensions, and structure of teeth have not changed. While the pattern of oral disease (infections, wear, parafunctions) has been influenced by the ever-changing human lifestyle, the original structure of enamel and dentin appears to be the same today as it was 3,000 years ago. In this context, it seems commendable to study and understand the marvelous design of natural teeth before considering any further concepts in restorative dentistry.

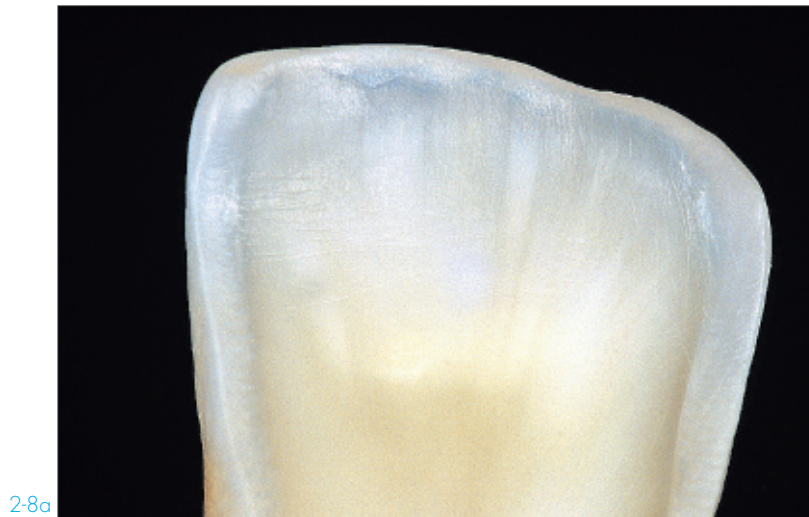


Translucency is the appearance between complete opacity (like ivory) and complete transparency (like glass).<sup>29</sup> Teeth, especially incisal edges, show intense characteristics integrating the wide range of effects defined by translucency and transparency.

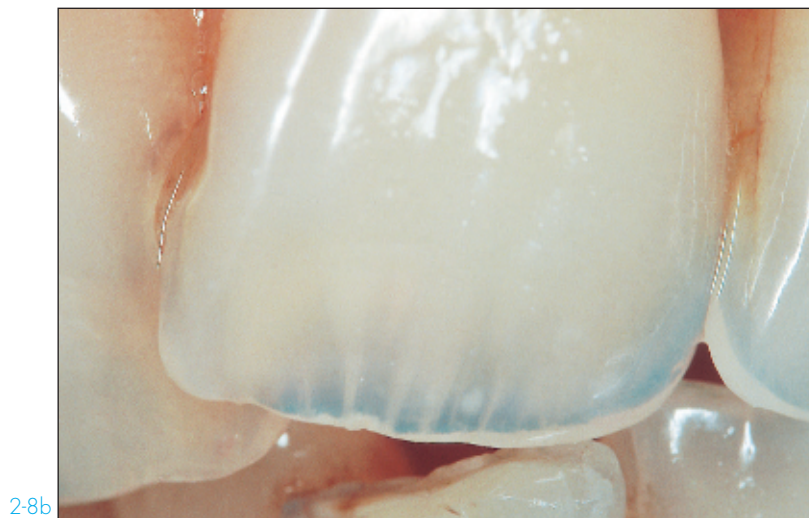
At one end of the spectrum, as illustrated in Figs 2-7b and 2-7c, areas of bluish transparency are present, also showing significant opalescence. Specific porcelains have been

designed to simulate these “enamel” effects (see Chapter 7). At the other end of the spectrum, more opaque “dentin” effects are found at the incisal edge as revealed by abrasion/attrition. The inner structure of the dentin core and its complex architecture become visible in the form of dentin rays, dentin mamelons, dentin infiltrations, etc (Fig 2-8). Dentin fluorescence (see criterion 11) is essential to these kinds of effects.

## DENTIN EFFECTS

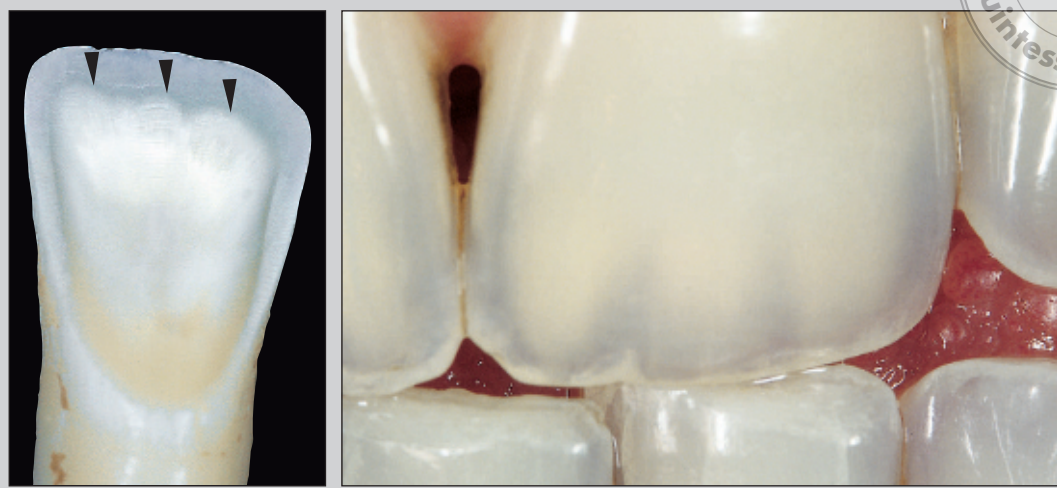


2-8a



2-8b

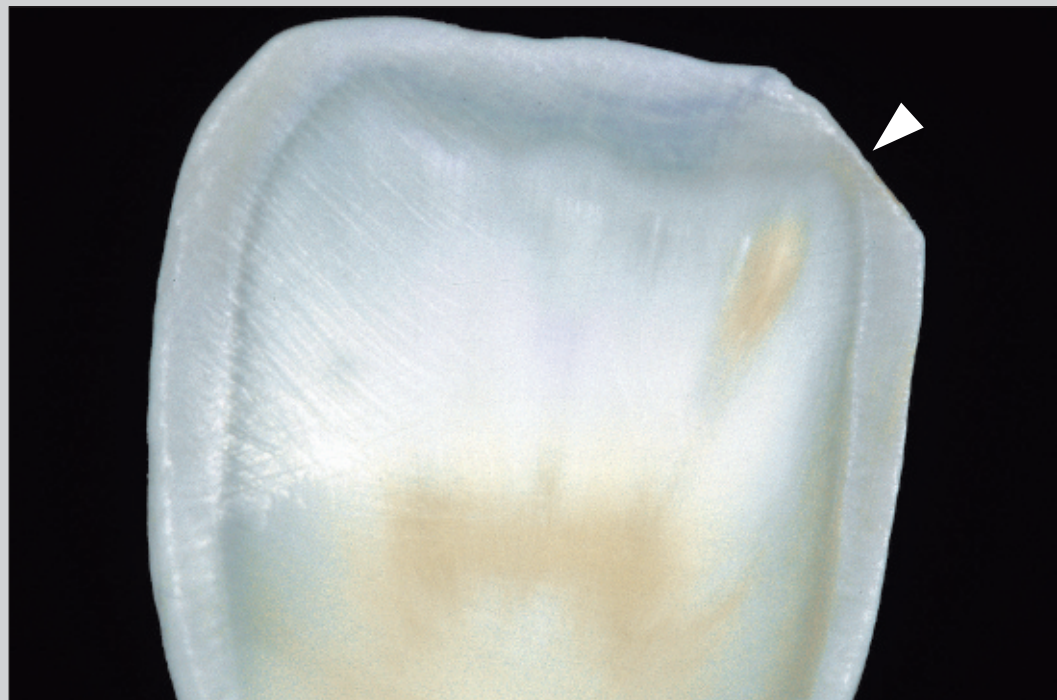
## DENTIN MAMELONS



2-8c

2-8d

## DENTIN INFILTRATION



2-8e

**FIGURE 2-8: DENTIN EFFECTS.** The most complex structural elements of the incisal edge can be better understood by grinding the palatal enamel of extracted teeth (2-8a, 2-8c, 2-8e). Vertical palatal attrition of the incisal edge emphasizes the underlying dentin rays (2-8a, 2-8b). Dentin architecture usually shows three well-organized dentin mamelons (2-8c, *arrowheads*). These structures are often seen in the presence of transparent enamel (2-8d). Dentin infiltration effects can also be noted; their direction is precisely defined by the convergence of the dentin rays, in median and apical directions; external dentin staining typically results from enamel edge chipping (2-8e, *arrowhead*) or progressive wear.



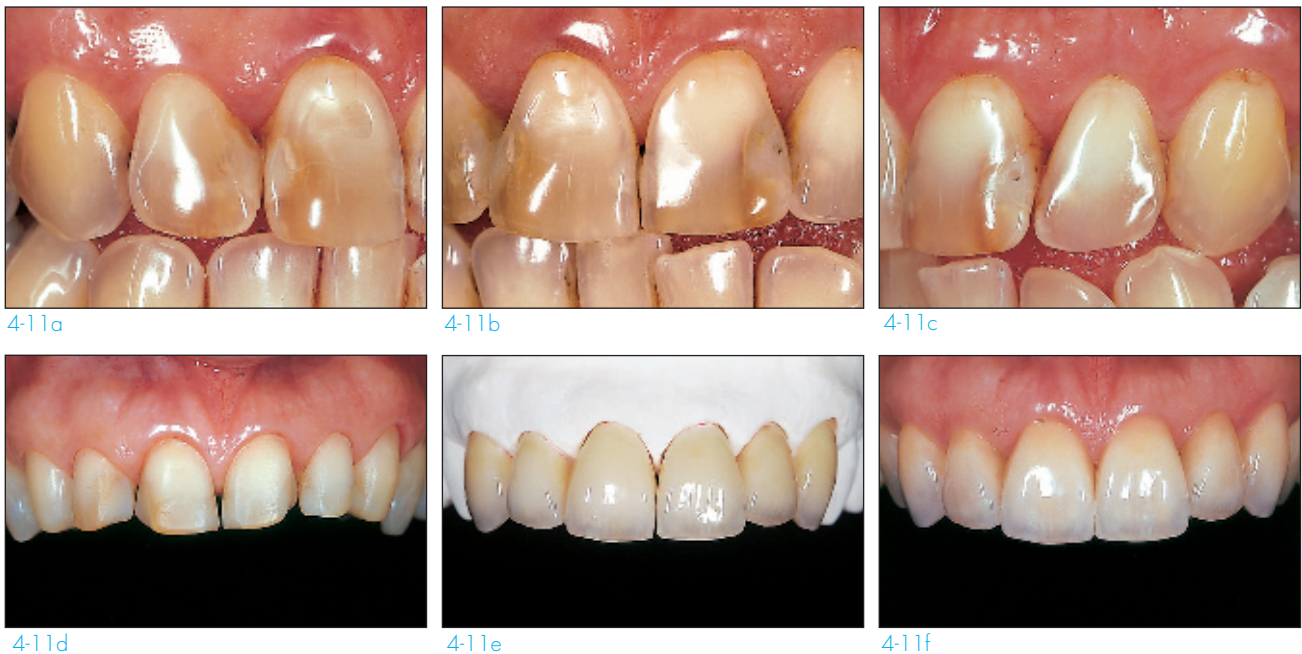## Type IIIB: Extensive loss of enamel

Extensive tooth abrasion is typically found in people of older age groups; of the maxillary teeth, the anterior teeth often exhibit the most wear (Fig 4-11). However, tooth surface loss is a growing problem in younger individuals.<sup>61</sup> Dietary acids are increasingly popular (especially soft drinks). Bulimia, consumption of acidic foods, acid reflux, and chlorine consumption (from swimming) are other typical etiologic factors in young patients.

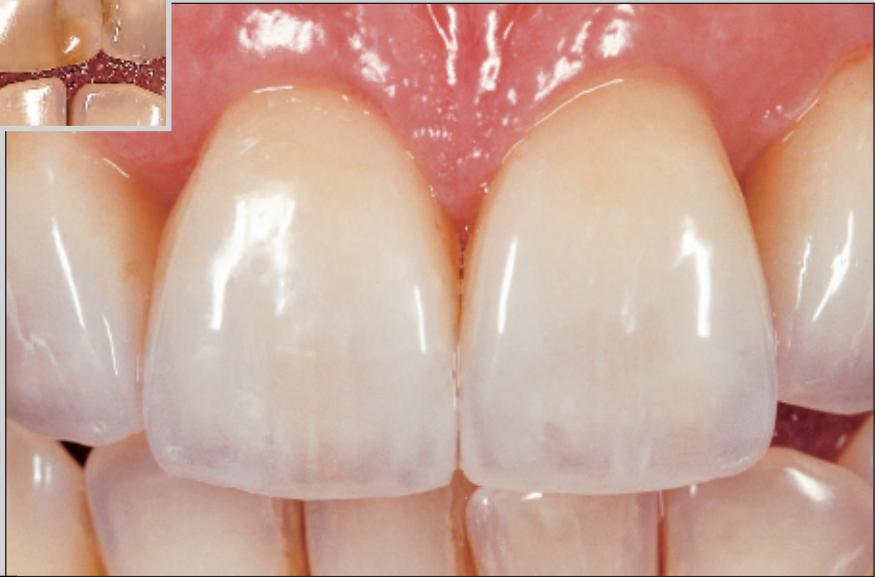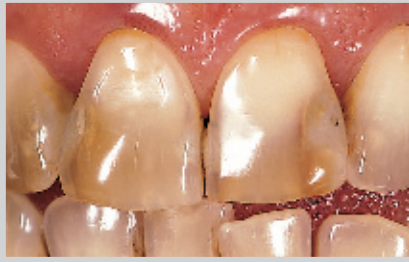Tooth erosion, particularly in young people, presents a considerable challenge to restorative dentists. In all cases, preventive and conservative strategies are essential. Use of neu-

tralizing mouth rinse (eg, bicarbonate solution) and topical application of neutral fluoridated gels can be recommended. Adhesive dentistry should be used whenever possible if restoration is necessary.

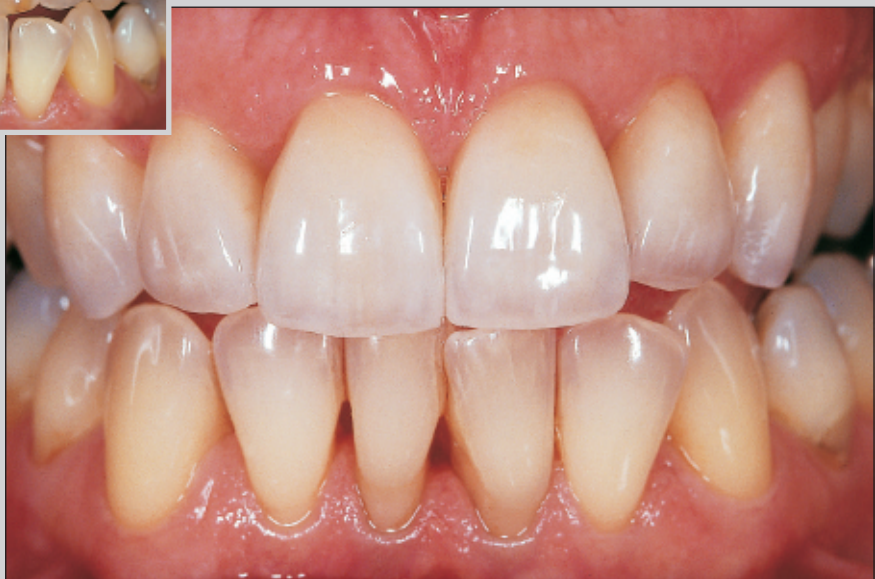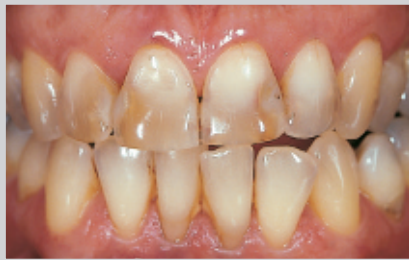Localized loss of enamel can be easily treated by direct application of composite resins. In case of a more extensive wear pattern, bonded porcelain restorations can be proposed and may include posterior teeth. Type IIIB indications can appear somewhat similar to type IIC, but the former features a more generalized nature (often more than four teeth to treat) as compared to the latter (which often involves only two teeth). Another typical type IIIB patient is featured in Figs 8-8g to 8-8j.



**FIGURE 4-11: ENAMEL EROSION OF MAXILLARY ANTERIOR TEETH.** The patient presented with severe facial wear of maxillary anterior teeth and infiltrated Class 3 composite resin restorations (4-11a to 4-11c). Note definite dentin exposures on the facial surface of the right and left central incisors (4-11b). Treatment planning included replacement of preexisting restorations, and teeth were prepared according to a diagnostic template; note the proximal margins extending within the new interdental restorations (especially between the central and lateral incisors) to minimize the volume of remaining composite restorative material (4-11d). The final porcelain restorations feature minor changes of tooth form and length but substantial recovery of the facial volume (4-11e to 4-11h).



4-11g



4-11h