









# Guidelines for Adhesive Dentistry The key to success

F. Mangani – A. Putignano – A. Cerutti

|                                  |   |     |
|----------------------------------|---|-----|
| Introduction to dental anatomy   |    | 11  |
| Etiology of tooth decay          |   | 59  |
| Isolation of the operating field |  | 97  |
| Dentin-enamel adhesion           |  | 139 |
| Operative procedures             |  | 171 |
| Appendix                         |  | 377 |



It is with particular approbation that I present this innovative multimedia approach to teaching operative dentistry, which provides professionals as well as students of dentistry the concepts and procedures inherent to conservative dentistry. The very latest dental techniques available for restoring function and esthetics have been analyzed down to the finest detail with the help of excellent drawings and illustrations. Esthetic detail takes an extremely important role when considering the marked increase nowadays in patients who feel the need to restore and/or improve the esthetics of their smile. Therefore, esthetic dentistry has developed a more nuanced approach than the simple use of prostheses.

For this reason, I wish this multimedia manual the vast circulation that it well deserves. The clarity of the lay out and the competence of the text testifies to the authors' profound dedication to the field of dentistry.

***Prof. Giovanni Dolci***

*Dean of the Department of Dentistry, University of Rome "La Sapienza", Italy  
Past President of Collegio dei Docenti di Odontoiatria*

It is with enormous satisfaction and the very greatest of pleasure that I present this scientific work of Prof Mangani and his colleagues, Profs Cerutti and Putignano. The great didactic and/or clinical value of this work is rendered more tangible by the characteristic and innovative illustrations throughout, making this book a model and reference for all those in the scientific and clinical world of dentistry who have the ambition of using modern multimedia methods to teach.

***Prof. Enrico Bollero***

*General Director - Azienda Ospedaliera Universitaria Policlinico Tor Vergata - Rome, Italy*



**Prof. Francesco Mangani**

M.D., D.D.S.  
Professor  
Chair of Restorative Dentistry  
University of Rome "Tor Vergata", Italy



**Prof. Angelo Putignano**

M.D., D.D.S.  
Professor  
Chair of Restorative Dentistry  
Polytechnic University of Marche, Italy



**Prof. Antonio Cerutti**

M.D., D.D.S.  
Professor  
Chair of Restorative Dentistry  
University of Brescia, Italy

It is a great pleasure for me to present the multimedia work of my friends and colleagues Profs Mangani, Cerutti, and Putignano. This pleasure is due to the professionalism and originality with which this operative teaching method has been researched, elaborated, and presented.

Both the student and the clinician are led through a series of steps that detail each phase of treatment to final result, the successful restoration of the dental apparatus. This book will serve a new generation of dentists with a message of conscience, scientific honesty, and professional ethics.

***Prof. Alberto Barlattani***

*CLOPD Coordinator, University of Rome "Tor Vergata", Italy  
President of the Conferenza Permanente dei Presidenti dei CLOPD*

Prof Putignano and his colleagues, Profs Cerutti and Mangani, are already well known both nationally and internationally for their expertise in conservative dentistry. Their dedicated research and clinical experimentation has led to improvements in composite materials to obtain the very best results in esthetics and function. This book will offer both students and professionals alike all the necessary concepts for obtaining high-quality restorative results in everyday practice.

It, therefore, gives me the very greatest of pleasure to wish this book, a great innovation in the didactic field, all the good fortune that it merits.

***Prof. Maurizio Procaccini***

*Dean, School of Dentistry  
Polytechnic University of Marche - Ancona, Italy*

In recent years, much has been spoken about the need for an innovative approach to recuperate efficiency in education and clinical development. New communication methods are, undoubtedly, among the most popular of these innovations. In fact, it has been demonstrated that efficient communication goes a long way toward efficiency in education.

This commitment to education undertaken by Prof Cerutti and his colleagues, Profs Mangani and Putignano, certainly harnesses "communication methods" brilliantly; by utilizing e-learning instruments, they have devised a teaching method which is well-nigh foolproof.

***Prof. Pier Luigi Sapelli***

*Dean, School of Dentistry  
University of Brescia, Italy*

### Learning

For years, we searched for someone who could explain not only the conceptual techniques involved in restoration, but also the exact movements of the hands; we knew only too well how different practice was from theory. We devoured books, exchanged opinions, experimented with materials, and, all three of us-driven by the same motivation-tried to elaborate simple and reliable protocols for dentistry of quality that was in keeping with our scientific knowledge. It was by no means easy!

### Teaching

Numerous education methods were adopted. For years, we used thousands of slides, with one question first and foremost in our minds: will it be enough? Then, finally, the computer provided the possibility to share knowledge with the simple transmission of a file. As our confidence with computer technology grew, we finally understood the possibility of teaching protocols that guide the operator through restorative protocols using three-dimensional graphics.

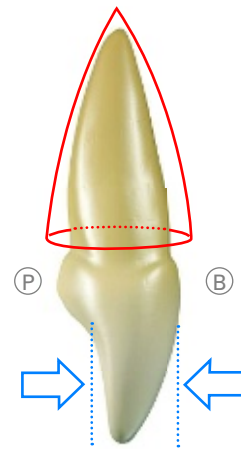
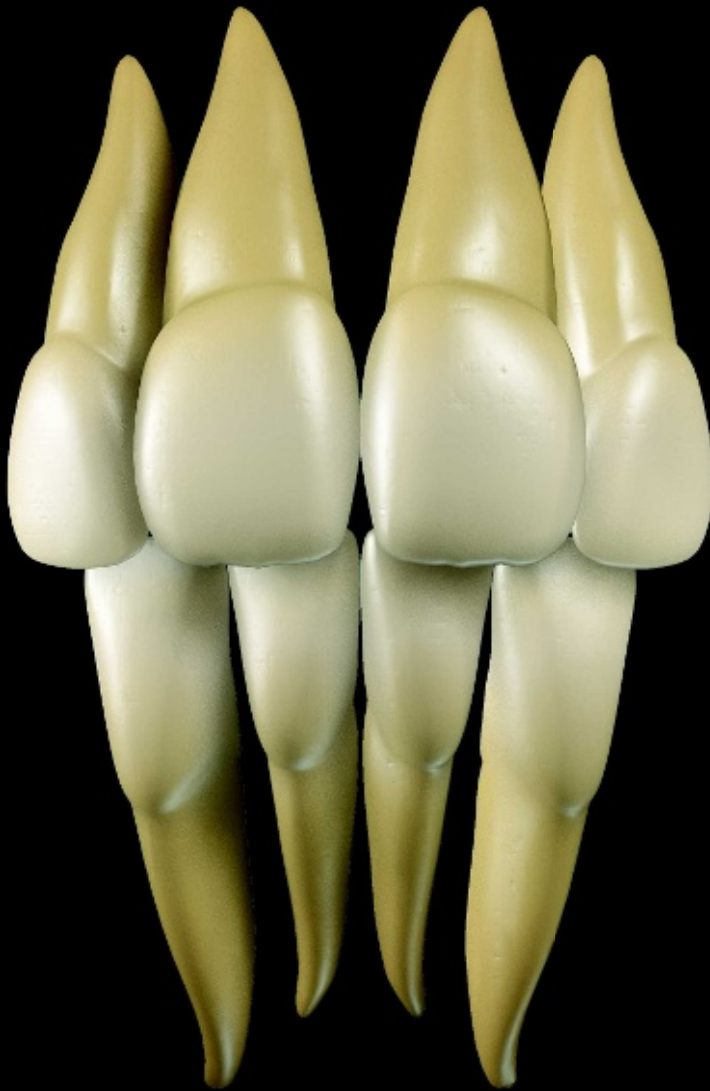With that goal in mind, we worked together as colleagues and friends to bring this book into being. First, we advised some doctoral students with their theses on the role of multimedia education in dentistry. Then, we spent hours working alongside technicians and colleagues to make clips for companies in this field.

The first book in this dentistry series has two basic objectives: **simplify teaching methods** with the possibility of being able to control the technique at any given moment and **facilitate the education of students and colleagues**, who are just getting into adhesive dentistry.

It is for you to decide whether we are on the right track.

*The Authors*

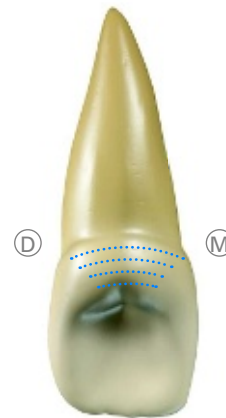
## Characteristics of incisors



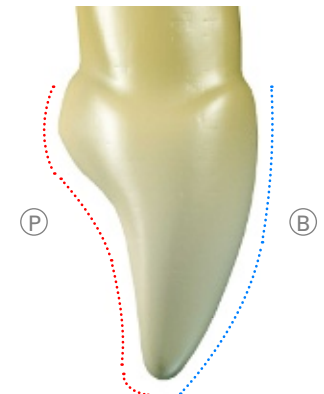
Incisors have single rounded roots and the crown is cuneiform. Two-thirds of the occlusal surface is flattened in a bucco-palatal direction.



The incisal edge is characterized by three small cusps or protrusions and separated by notches.

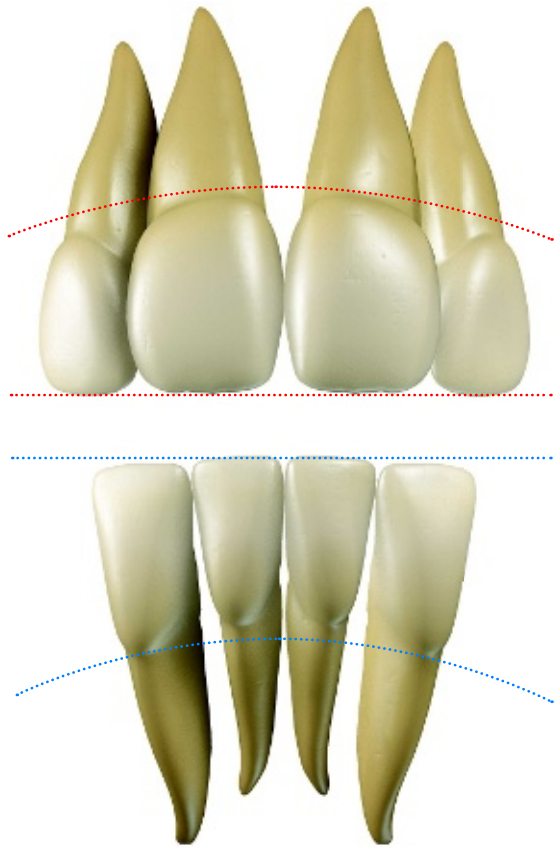


The cingulum is convex on the palatal or lingual side.

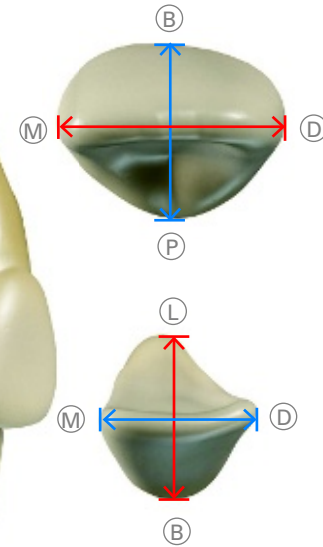
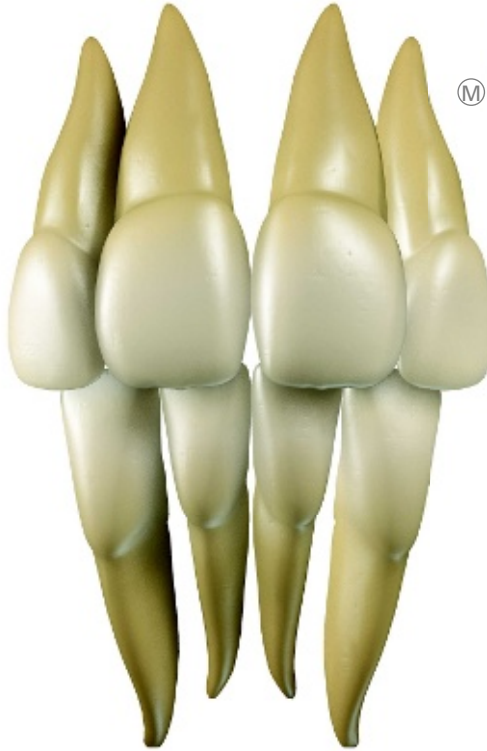

The buccal surfaces are uniformly convex. The palatal surface is concave, except for the cingulum and the marginal ridges.

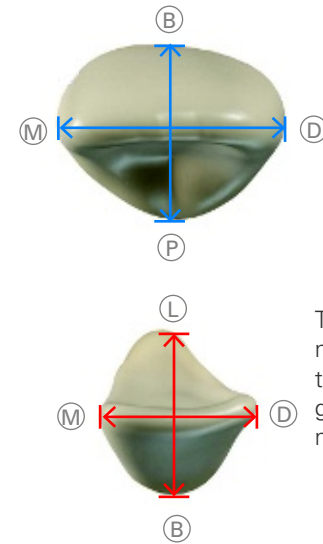




The line of the maxillary incisors descends distally, with the lateral incisors being much smaller than the central incisors. The line mandibular incisors ascends distally, with the lateral incisors being much larger than the central incisors.

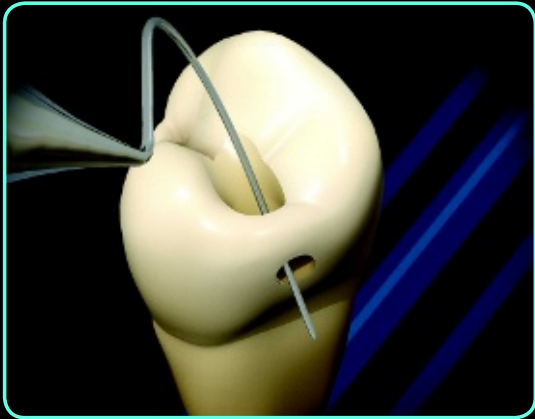
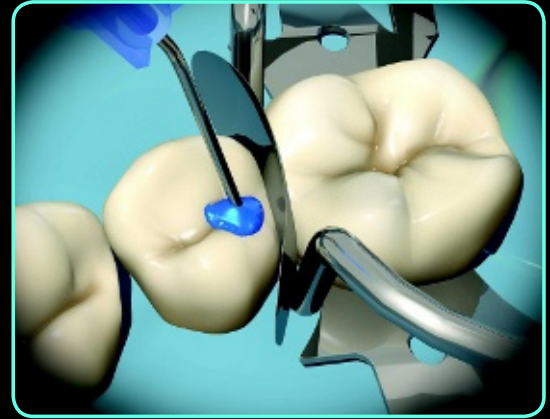
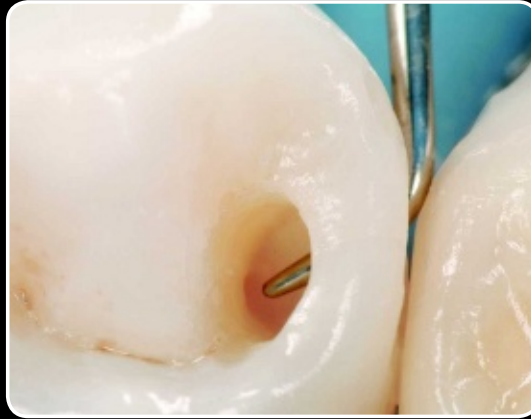
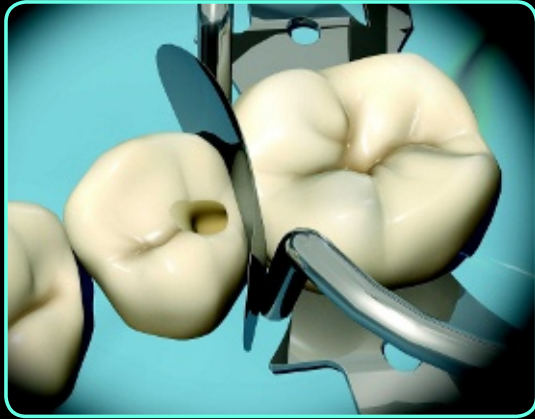In the maxillary incisors, the mesiodistal diameter is greater than the buccopalatal diameter. In the mandibular incisors the mesiodistal diameter is less than the buccopalatal diameter.

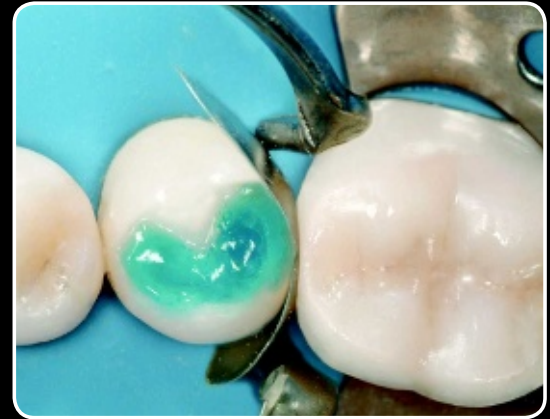

The buccopalatal and mesiodistal diameters of the maxillary incisors are greater than those of the mandibular incisors.

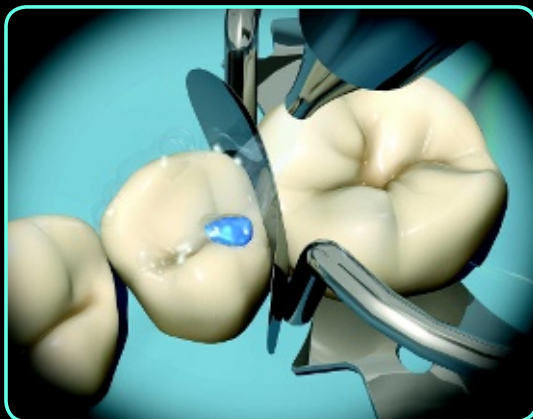




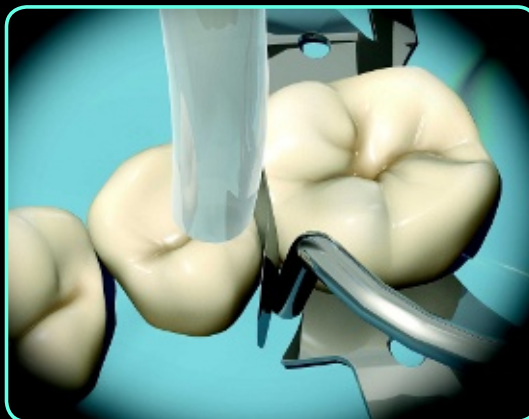Design of finished cavity preparation. Care is taken to keep the enamel bridge of the distal marginal crest intact.



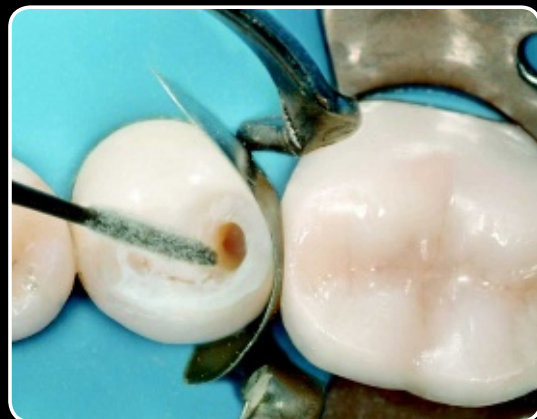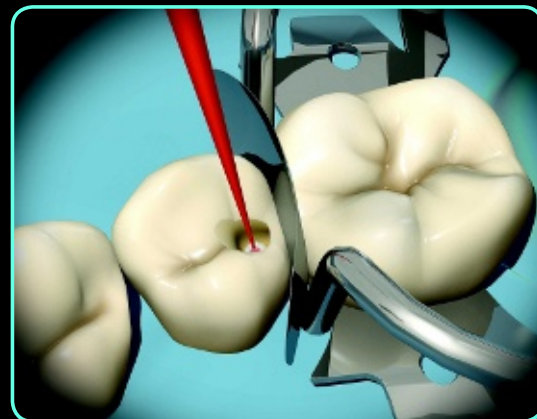Etching of hard tooth tissues with a mordant of 37% orthophosphoric acid (15 seconds for the dentin, 30 seconds for the enamel).



Removal of acid with an air-water spray.



The cavity is dried with an aspirator to avoid excessive drying of the exposed dentin. This procedure allows the next adhesive step to be carried out with the wet-bonding technique.

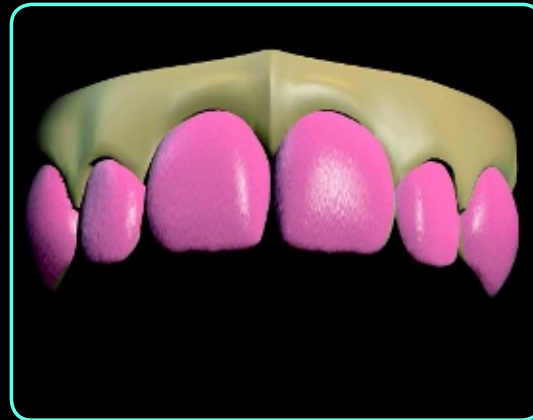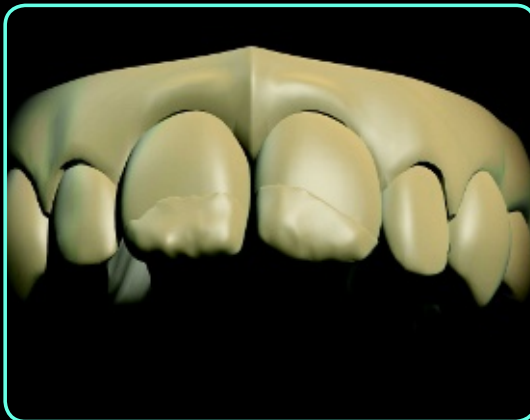


Application of primer (30 seconds).

Taking impressions necessary for making an esthetic waxup.

Plaster cast made from the impressions.

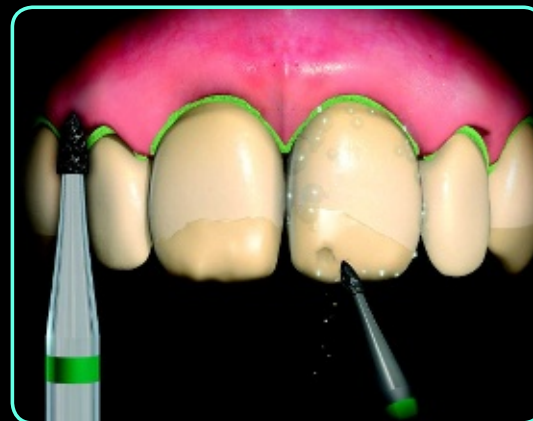
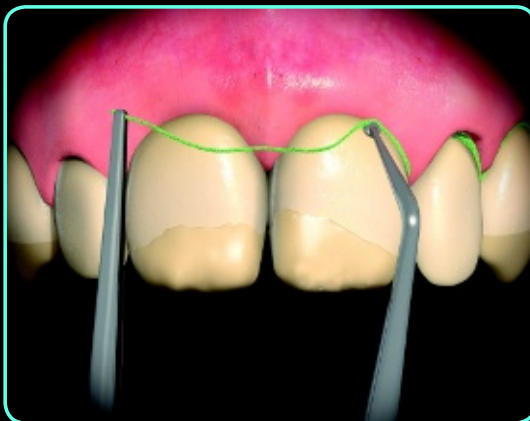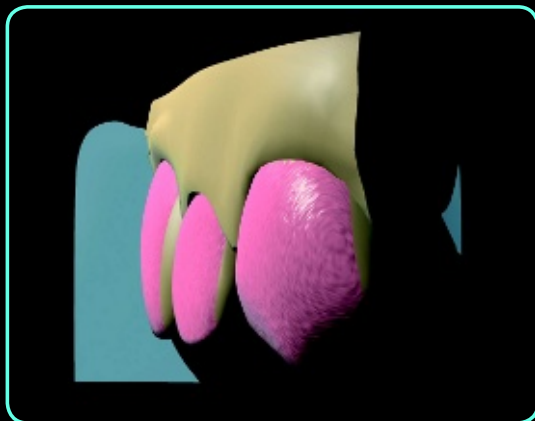
The esthetic waxup presents a treatment plan with new tooth shapes and proportions provided by indirect veneers.



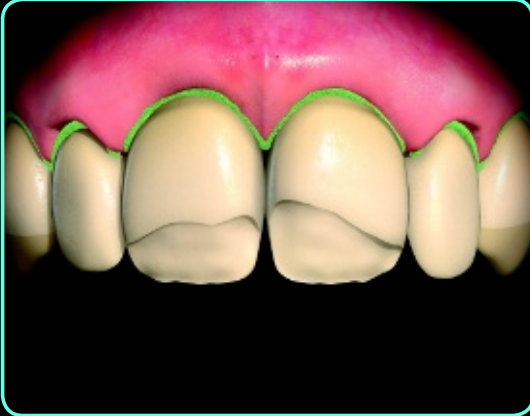Silicon index of the esthetic waxup. This step allows the construction of a guiding matrix in silicon, which is necessary to create the correct veneer thicknesses.

Placement of a retraction cord to correctly position the restoration margin at the cemento-enamel junction, with an adequate thickness of enamel.

Removal of failing restorations. In this phase, it is necessary to evaluate the quantity of residual tissue and proceed to build up necessary areas to the correct morphology.



In this case, there was no need for a structural buildup because of minimum loss of tooth structure.



Fabrication of a window-type preparation. The first step calls for the use of a buccal fissure as a guide to mark the average depth of the preparation into the enamel (0.5 to 0.6 mm). Half the depth of a round diamond bur - the maximum diameter of which is equal to 1 to 1.2 mm - is used, beginning in the cervical area and proceeding to the proximal area to finally meet occlusally.

