

---

Michael Hülsmann, Edgar Schäfer (Editors)  
Clemens Bargholz, Claudia Barthel (Associate editors)

# Problems in Endodontics

## Etiology, Diagnosis and Treatment

**With contributions from:**

Michael Arnold  
Thomas Attin  
Clemens Bargholz  
Claudia Barthel  
Hans-Willi Herrmann  
Dirk Hör  
Michael Hülsmann  
Tina Rödiger  
Edgar Schäfer



QUINTESSENCE PUBLISHING

London, Berlin, Chicago, Tokyo, Barcelona, Beijing, Istanbul, Milan,  
Moscow, Mumbai, Paris, Prague, São Paulo und Warsaw

---

# Contents

- 1 Diagnosis 1**  
Edgar Schäfer
- 2 Problems in preserving pulp vitality 33**  
Edgar Schäfer and Claudia Barthel
- 3 Problems in treatment planning 45**  
Michael Hülsmann, Edgar Schäfer and Clemens Bargholz
- 4 Health-related problems 65**  
Edgar Schäfer
- 5 Preoperative restoration and placement of rubber dam 97**  
Clemens Bargholz
- 6 Problems in dental anesthesia 115**  
Claudia Barthel, Michael Hülsmann and Edgar Schäfer
- 7 Problems in the treatment of endodontic emergencies 127**  
Michael Hülsmann and Edgar Schäfer
- 8 Problems in gaining access to the root canal system 145**  
Michael Hülsmann and Claudia Barthel
- 9 Visualization 173**  
Michael Arnold
- 10 Problems in determining endodontic working length 191**  
Dirk Hör, Tina Rödiger and Michael Hülsmann

- 11 Problems in root canal preparation 209**  
Michael Hülsmann and Edgar Schäfer
- 12 Problems in disinfection of the root canal system 253**  
Michael Hülsmann and Tina Rödiger
- 13 Problems of root canal obturation 293**  
Hans-Willi Herrmann and Michael Hülsmann
- 14 Problems in the assessment of healing, success and failure 335**  
Michael Hülsmann, Edgar Schäfer and Claudia Barthel
- 15 Vertical tooth and root fractures 353**  
Clemens Bargholz
- 16 Periodontal–endodontal lesions 371**  
Michael Hülsmann and Edgar Schäfer
- 17 Perforations 385**  
Clemens Bargholz
- 18 Instrument fractures 401**  
Michael Hülsmann
- 19 Resorption 421**  
Michael Hülsmann and Edgar Schäfer
- 20 Retreatment 435**  
Clemens Bargholz, Michael Hülsmann and Edgar Schäfer
- 21 Incomplete root formation 463**  
Edgar Schäfer
- 22 Aspiration and swallowing accidents 479**  
Edgar Schäfer
- 23 Endodontic treatment of teeth with anatomical malformations 485**  
Michael Hülsmann and Edgar Schäfer

**24 Problems in bleaching of endodontically treated teeth 515**

Thomas Attin

**Index 531**

---

# Contributors

**Michael Arnold, BDS (Stomatology)**

Königstrasse 9  
D-01097 Dresden  
Germany

**Prof. Thomas Attin**

Department of Preventive Dentistry, Periodontology  
and Cariology  
Zurich University  
Plattenstrasse 11  
CH-8028 Zurich  
Switzerland

**Dr. Clemens Bargholz**

Mittelweg 141  
D-20148 Hamburg  
Germany

**Prof. Claudia Barthel**

Department of Operative Dentistry  
Heinrich-Heine-Universität Düsseldorf  
Moorenstrasse 5  
D-40225 Düsseldorf  
Germany

**Dr. Hans-Willi Herrmann**

Zahnarztpraxis Im Dienheimer Hof  
Mannheimer Strasse 6  
D-55545 Bad Kreuznach,  
Germany

**Dr. Dirk Hör**

Oberlinxweilerstrasse 19  
D-66606 Niederlinxweiler  
Germany

**Prof. Michael Hülsmann**

Department of Operative Dentistry, Preventive  
Dentistry and Periodontology  
Georg-August-Universität Göttingen  
Robert-Koch-Strasse 40  
D-37075 Göttingen  
Germany

**Dr. Tina Rödiger**

Department of Operative Dentistry, Preventive Den-  
tistry and Periodontology  
Georg-August-Universität Göttingen  
Robert-Koch-Strasse 40  
D-37075 Göttingen  
Germany

**Prof. Edgar Schäfer**

Department of Operative Dentistry  
University of Münster  
Waldeyerstrasse 30  
D-48149 Münster  
Germany

---

# Preface

## Endodontics is enjoyable!

It seems that this view is shared by many of our colleagues – despite the difficult conditions that sometimes prevail in everyday practice – leading to a sort of “endodontics euphoria” over the past few years. As ever, when procedures are not only fascinating and absorbing, but also have good prognoses, even under ordinary practice conditions (provided that basic treatment principles are upheld), there is a tendency to go deeper and deeper into the subject and risk treating increasingly more complex and difficult cases. We often see a quick extraction being replaced by an attempt to preserve even severely compromised teeth with endodontic or surgical endodontic procedures. Retreatments now make up the majority of procedures carried out by endodontic specialists, whereas perforation repair and the removal of fractured instruments have become part of everyday practice routine for many dentists. Our aim in this book is to offer support in overcoming problems, to ensure that the enjoyment and fascination of endodontics are not lost, even in cases that cannot be described as routine.

We contribute clinically relevant information to a few of the key problem areas in endodontics, starting with the often neglected subjects such as diagnosis, preservation of tooth vitality and the treatment of pain, and also including preventive aspects and practical problem-solving tips. We felt that a “root canal cookbook” or an endodontic “DIY manual” would not be helpful, so we have made an effort to include key findings and data from the scientific literature. Of course, the reader must be aware that these are subject to constant change, and that some of the older information will need to be interpreted with some caution. However, “old” is not necessarily “bad” (and vice versa).

Of course, this book has a worthy model in *Problem Solving in Endodontics* (Gutmann, Dumsha and Lovdahl, Mosby, 2005), now in its fourth edition, which, in many ways, reflects the American treatment philosophy. Nevertheless, this compendium still offers a huge variety of material, knowledge, advice and food for thought, as well as many practical tips and tricks. Our book, in its original language, represented an effort to create a similar work for German speakers, to be regularly updated, constantly improved and enriched by future advice and by case reports from everyday dental practice.

At this point, therefore, we would like to thank not only all our many co-authors but also, in particular, all our colleagues, whether based at practices or universities, for their informative case histories.

Of course this book will not encompass every situation. So many of the clinical findings and problems have such a variety of different solutions that they cannot all be collected into one book. In addition, unfortunately, many practical procedures are difficult to describe on the page; sitting in on clinical demonstrations, attending practical courses and taking part in classic training and continuing professional

development still remain essential and irreplaceable learning media for such situations. We would therefore be very pleased to hear from interested colleagues and to receive as much as possible in the way of advice, clinical tips and even additional case reports for the next edition, which we hope to produce in due course.

This book is merely a gateway into this subject and is far from complete. Important omissions are dental traumatology, the endodontic treatment of primary teeth and (micro)surgical endodontics. We hope these will find a place in future editions.

Prof. Dr. Michael Hülsmann, Göttingen, Germany

Prof. Dr. Edgar Schäfer, Münster, Germany

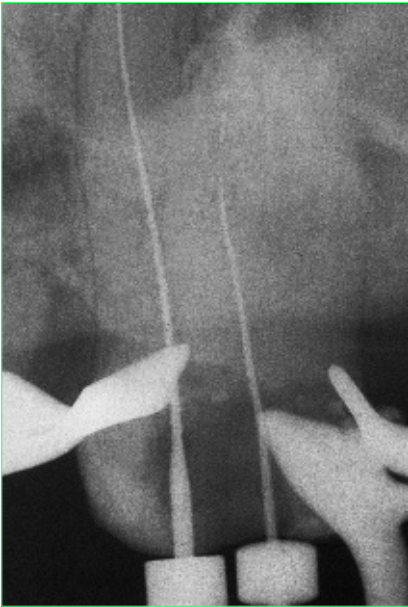


Fig. 8-11 The radiograph suggested calcification of the root canal systems, which were no longer visible in the film. Nevertheless, clinical assessment revealed two root canal systems.

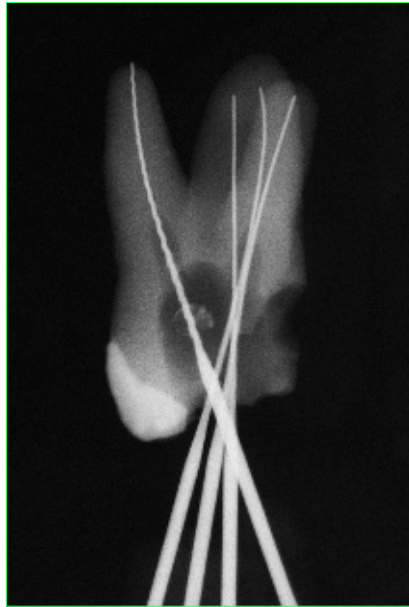


Fig. 8-12 Both of the remaining root canals are visible now that the tooth has been extracted.

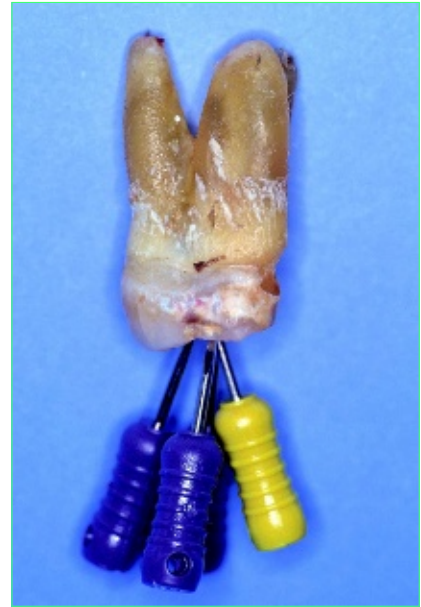

Fig. 8-13 Clinical view of the tooth.

### Nature of the problem

Calcifications completely or partially block and obscure the access into the root canal systems and can hamper preparation, disinfection and obturation. Searching for calcified root canal systems carries an increased risk of perforation.



Radiographs alone can never be used as a basis for determining whether complete calcification has taken place; these teeth always require clinical verification (Figs 8-11 to 8-13). Pulp testing ceases to have any diagnostic value once the calcification has reached an advanced stage.

### Indications for endodontic treatment of teeth with actual or suspected calcification

Periapical lesions of endodontic origin are always manifestations of a disease that develops from the presence of microorganisms in the root canal system (or, in rare cases, in the periapical region).<sup>10</sup> Healing can take place only if these bacteria are removed as completely as possible. Therefore, root canal treatment is strongly indicated in a tooth with a partially (or apparently) calcified root canal system and apical periodontitis. However, if all attempts still fail to result in complete exposure and instrumentation of the root canal system, the clinician should consider root resection, hemisection or extraction.



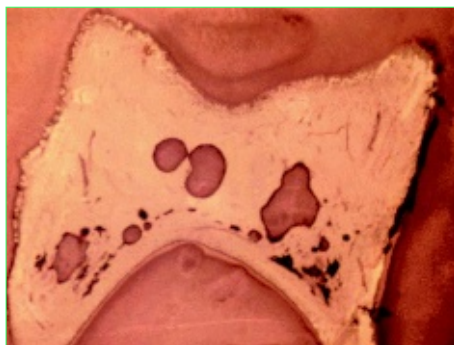


Fig. 8-9 Histological view of free pulp stones in the pulp chamber (HE stain, magnification: 16×).

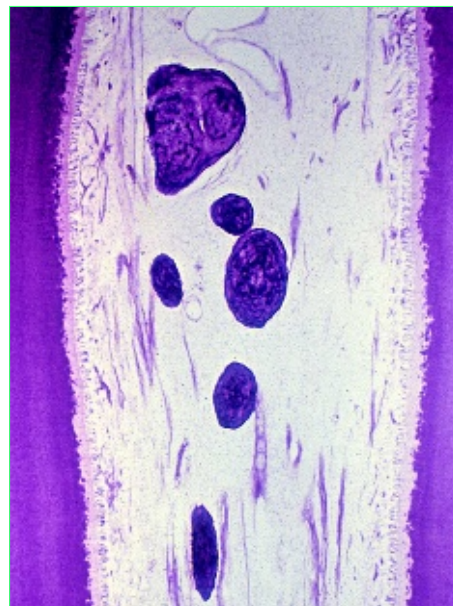


Fig. 8-10 Pulp stones may also be found in the pulp tissue in the root canals.

## Calcification

### Definition

Initially, calcification is a process involving the reduction in size of the intradental cavities as a result of hard-tissue formation by the cells of the vital pulp; it ends in complete calcification as a result of dentin deposition inside the tooth.

### Background

Hard-structure depositions of a physiological nature (secondary dentin formation) lead to slow and uniform constriction and narrowing of the pulp chamber. This process accelerates if the odontoblasts are stimulated by progressive caries. The pulp tissue reacts to this stimulus by the precipitate deposition of irregular tertiary dentin, with the aim of forming a barrier against the advancing caries. Chronic irritation caused by exposed dentin also leads to the formation of tertiary dentin, which results in a constriction in the cervical region of the tooth in many cases.<sup>4</sup> Moreover, calcifications are a common consequence of dental and occlusal trauma, certain types of maxillary surgery (e.g. Le Fort I osteotomy) and also certain kinds of orthodontic treatment.



Calcifications of varying extent develop in teeth that have been subjected to luxation trauma.<sup>5</sup> Pulpal necrosis occurs with some major delay in 20% of teeth with radiologically detectable calcifications.<sup>6</sup> Calcifications have been observed in 2.3% of patients following Le Fort I operations;<sup>7,8</sup> according to other studies, the incidence may be as high as 30%. Further causes that have been described include surgery-related changes in perfusion and in combined surgical and orthodontic treatment. Calcifications in the pulp chamber have also been observed following orthodontic treatment.<sup>9</sup>

## 15 Vertical tooth and root fractures

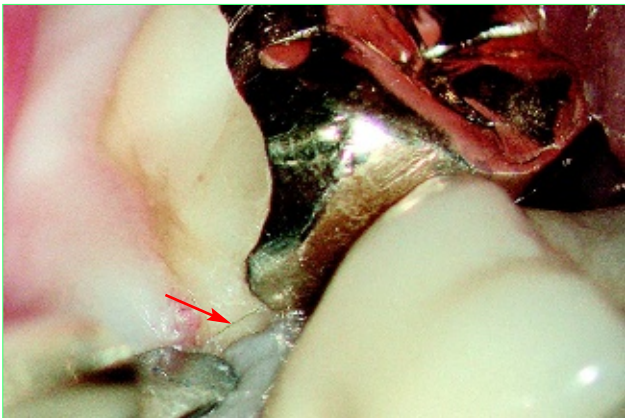


Fig. 15-25 A fine fracture line (arrow) is revealed when the marginal gingiva is retracted.

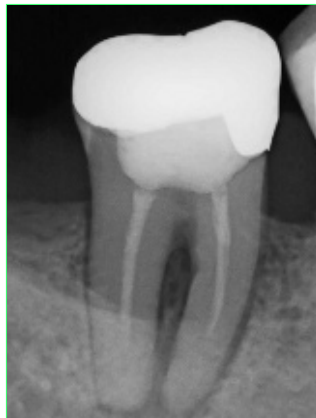

Fig. 15-26 Corresponding radiograph.

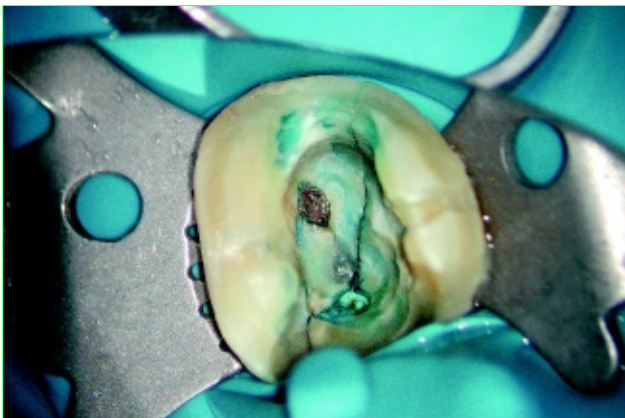


Fig. 15-27 View of the cavity after obturation of the distal root canal.

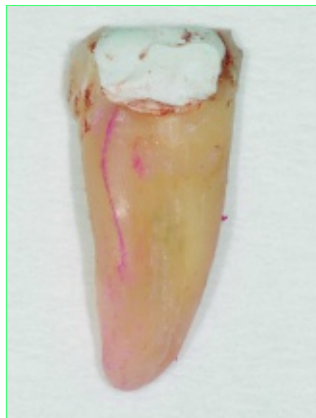

Fig. 15-28 Course of the fracture lines (mesial section).

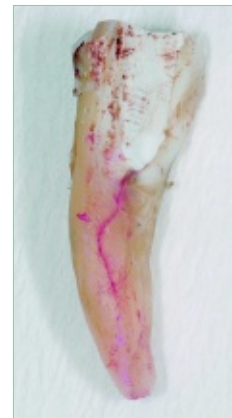

Fig. 15-29 Course of the fracture lines (lingual view).

Fig. 15-30 Situation following hemisection and removal of the mesial root.

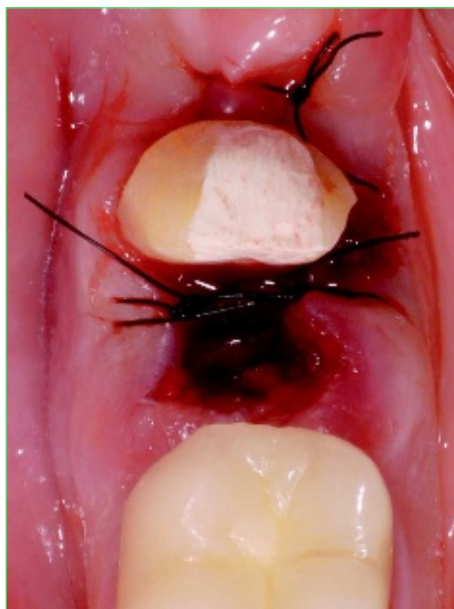
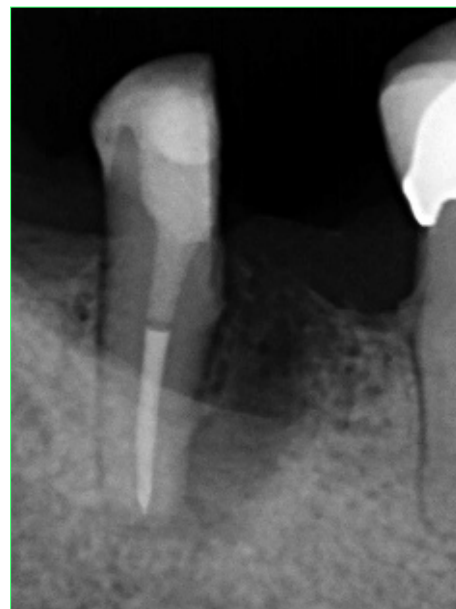
Fig. 15-31 Corresponding radiograph.



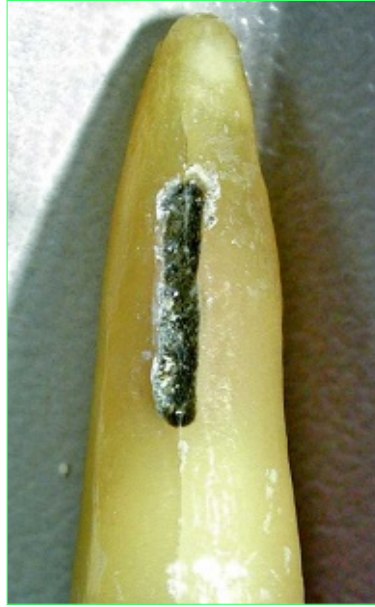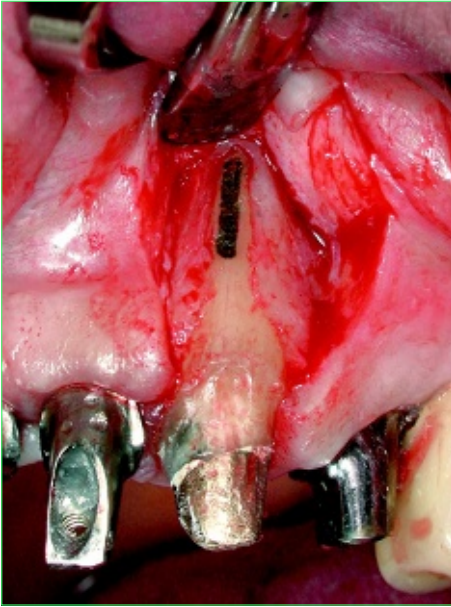


Fig. 15-32 During an extensive implant procedure, a vertical root fracture in tooth 23 was surgically exposed to enable short-term preservation of the tooth; a cavity was prepared and sealed with mineral trioxide aggregate (MTA).

Fig. 15-33 Extraction 2 months later revealed that the fracture has run through the MTA and into the apical third of the root. (Source: Dr. Albers, Norderstedt, Germany).

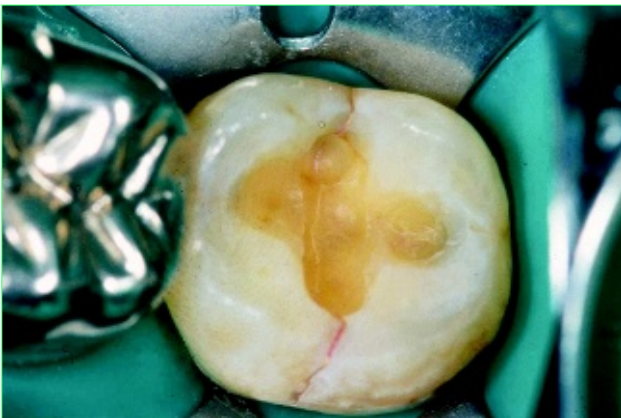

Fig. 15-34 An incomplete transverse fracture of the tooth is visible following removal of the inlay.

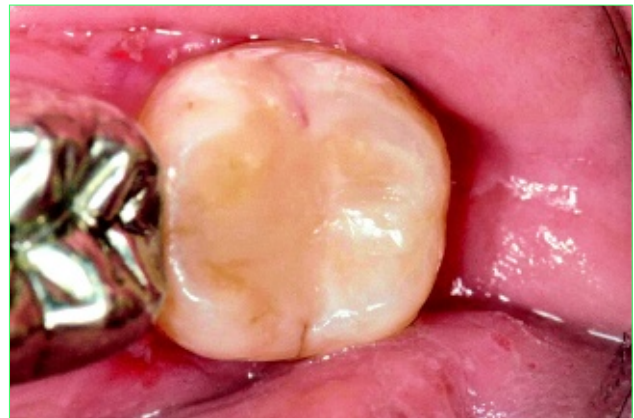
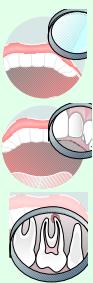
Fig. 15-35 An attempt was made to stabilize the tooth with an adhesive restoration.



**Case report**

A 59-year-old woman presented with symptoms in tooth 38, which had been restored with a gold inlay with reasonable margins. The tooth reacted negatively to the cold test and a radiograph showed apical periodontitis. Removal of the inlay revealed an incomplete transverse fracture (infracture) of the tooth running through the roof of the pulp chamber (Fig. 15-34). The crown of the tooth was stabilized with an adhesive restoration, which bonded the fragments together (Fig. 15-35), followed by root canal treatment (Fig. 15-36). Six months later, the tooth was restored with a partial porcelain crown bonded with adhesive (Fig. 15-37). The patient presented again with symptoms 2 years later. The clinical examination and a radiograph showed that the fracture had extended into the root, making extraction unavoidable (Figs 15-38 and 15-39).