




TABLE OF CONTENTS

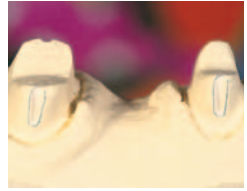



Page viii	ABOUT THE AUTHORS
Page xi	FOREWORD, by Peter Schärer
Page xii	PREFACE
Page xiv	ACKNOWLEDGMENTS
Page 1	INTRODUCTION



C H A P T E R	Managing the Treatment Plan with the Prosthetic Team	
1	Diagnosis and collection of clinical information	
PAGE 10	Prosthetic preparations	
	Communicating with the patient	
	Color matching	

C H A P T E R	Magnification Systems Used in Dentistry	
2	Types of magnifying instruments	
PAGE 64	Physiologic effects and instrument maintenance	

C H A P T E R	Tooth Preparation for Complete Crowns	
3	Anatomic limits	
PAGE 84	Scientific principles	
	Rotating instruments	
	Systematized tooth preparation	
	Selective concentration	

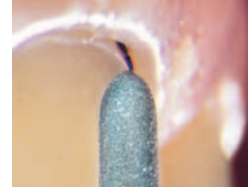C H A P T E R	Finish Line Designs for Complete Crown Preparations	
4	Characteristics of the various finish lines	
PAGE 108	Additional guidelines for tooth preparation	

CHAPTER
5

PAGE 152

Repositioning and Completing the Finish Line with Oscillating Instruments

- Oscillating instruments
- Comparing sonic and ultrasonic instruments
- Optimal use of oscillating instruments



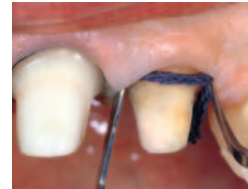CHAPTER

6

PAGE 174

Technical Considerations for Soft Tissue Retraction

- Determining the position of the restoration margin
- Gingival retraction
- Retraction procedures
- Additional guidelines



CHAPTER

7

PAGE 208

Clinical Considerations for Provisional Prostheses

- Characteristics and classification of provisional restorations
- Procedures for provisional restorations
- Clinical considerations for the working stages
- Tissue conditioning with the provisional prosthesis



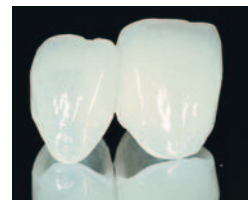CHAPTER

8

PAGE 238

Technical Considerations for Provisional Prostheses

- Diagnostic provisional elements



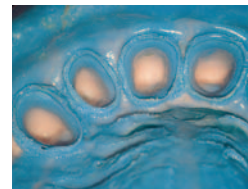CHAPTER

9

PAGE 266

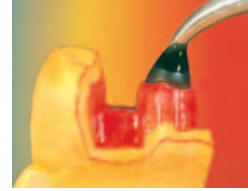Custom Impression Trays and Impression Materials

- Impression trays
- Characteristics of impression materials for fixed restorations
- Types of impression material
- Impression techniques
- Failures and their principal causes
- Impressions for implant-supported restorations



Laboratory Procedures

- Creation of the working cast
- Creation of the wax pattern
- Casting

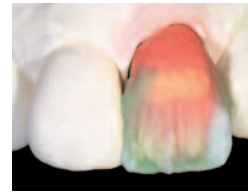


CHAPTER

11

Using Ceramic in Prosthetic Restoration

- Metal-ceramic crowns
- Ceramic material
- Treating the metal at the cervical margin
- Ceramic layering
- Heat-pressed all-ceramic restorations
- CAD/CAM technology

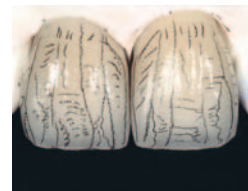


CHAPTER

12

Esthetic Considerations for Ceramic Restorations

- Stratification, light, and color
- Ceramic stratification techniques
- Bisque test and final check



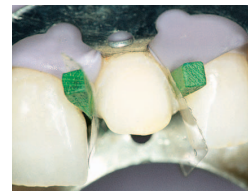CHAPTER

13

Cementation

with Federico Ferraris

- Properties of cement
- Types of cement
- Clinical problems and solutions
- Clinical procedures
- Distinctive features of cements
- Case presentations



F O R E W O R D



When this work first appeared in Italian as a two-volume set, the cover design gave the impression that the text would describe different magnification systems used in dentistry. However, the authors—a clinician and two dental technicians—have created a unique work that sets new standards of precision and performance in restorative dentistry. Every area of restoration is described in detail and illustrated with images of the highest quality.

The authors start with the initial patient examination and continue to document each clinical and laboratory step needed for precise fixed restorations. The excellent clinical chapters detail procedures such as refining the preparation margin, impression taking, fabricating master casts, creating provisional restorations, and cementation. The text covers laboratory procedures, including the creation of a diagnostic waxup and casting and veneering of the definitive framework for ceramometal restorations. The authors demonstrate their own unique way of performing each procedure, and the definitive results are so convincing that one can have no objections to their approach. Finally, the extensive literature review at the end of each chapter includes many English- and German-language articles on each topic, attesting to the internationality of this masterpiece.

Every clinician and dental technician who is interested in improving prosthetic precision should acquire this book. Even more importantly, students of dental medicine and of dental technology should use this book to learn the importance of quality in our profession.

I wish the authors great success with this book and hope that the English edition will become as widely read as the original Italian volumes.

Professor Dr Peter Schärer, DMD, MS*

Dean

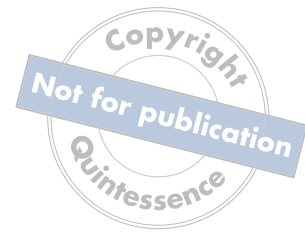School of Dental Medicine

University of Zurich

Zurich, Switzerland

*Written prior to Professor Schärer's death in December 2004.

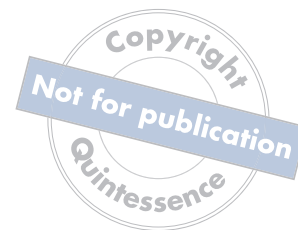P R E F A C E



Today, clinicians find themselves predominantly treating cases in which esthetics and function are of equal importance. Prosthodontic restoration, whether simple or complex, encompasses numerous phases and procedures throughout which the clinician and dental technician must work with precision to achieve the planned result. The importance of the diagnostic treatment plan cannot be overstated; the clinician's accurate interpretation of the patient's goals is the most important factor in satisfying ever-increasing patient expectations. Moreover, meeting esthetic demands presented by these cases requires a serious on-going commitment from the prosthodontic team. Clinicians and dental technicians must stay informed, in terms of both procedures and scientific principles, in order to effectively select and use materials and methods best suited to individual treatment plans.

The objective of this publication is to provide valuable information to support the prosthodontic team in the treatment of the various clinical cases and situations encountered in daily practice. This book contains a detailed analysis of the most significant clinical prosthodontic procedures (eg, tooth preparation, finish line design, soft tissue retraction), based on scientific evidence and presented in a practical framework to provide useful treatment guidelines. It also describes the essential steps involved in managing the restorative treatment, beginning with the clinical diagnosis and subsequent diagnostic waxup, then progressing to the correct use of provisional restorations, which are fundamental in the conditioning and correct development of the soft tissues, as well as in the achievement of the functional and esthetic objectives.

The chapter on cementation presents a detailed analysis of the physical and rheological characteristics of cements and the various types of adhesive and conventional

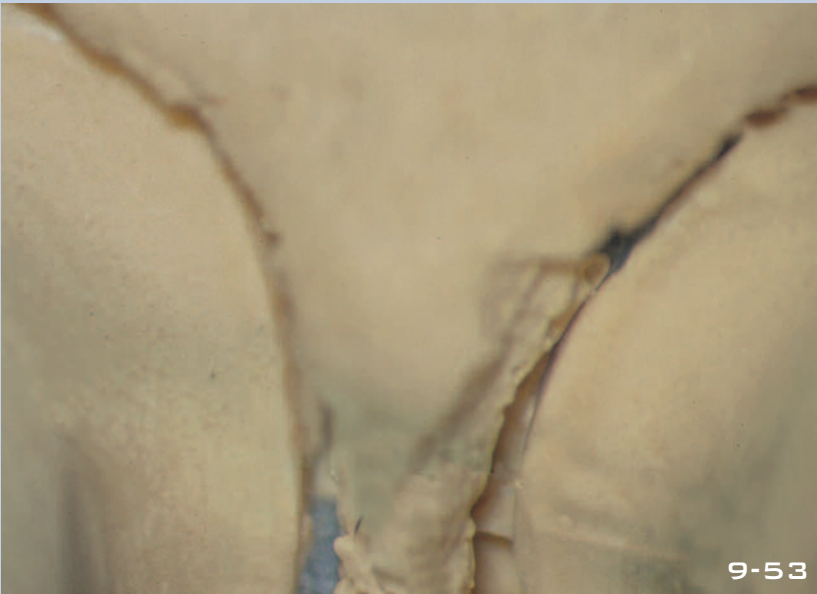
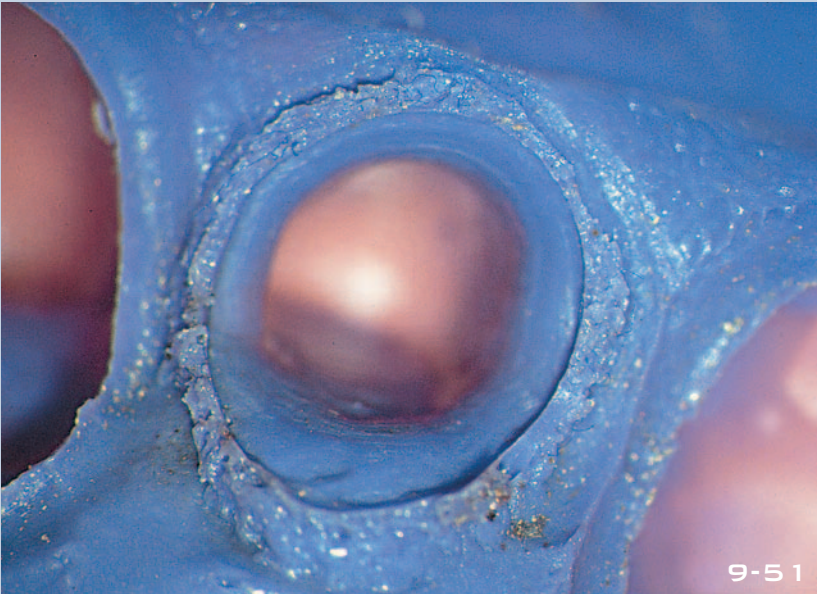
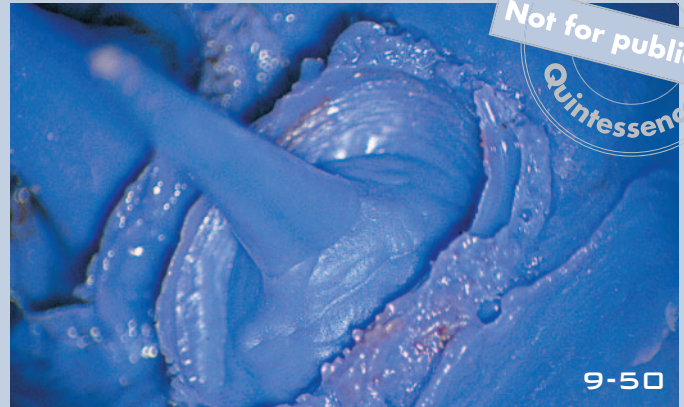
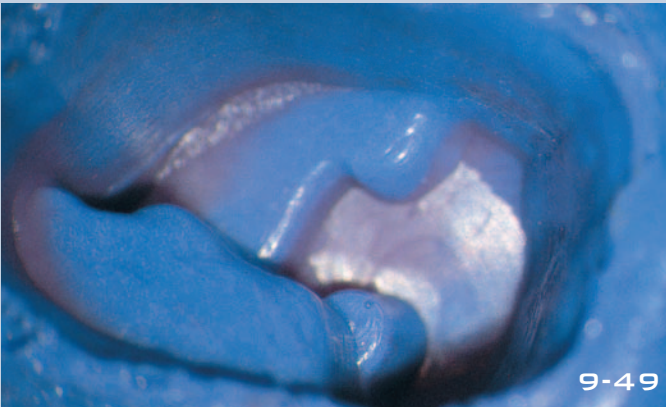


cementation. It also guides the reader in selecting the most appropriate procedures based on the prosthetic design and the correct use of the various types of cement. This chapter was prepared with the collaboration of Dr Federico Ferraris, who helped shape it into a true compendium on cements, clarifying their distinctive characteristics and the indications for their use. The chapter is an invaluable reference for determining the type of material to be used in different clinical situations.

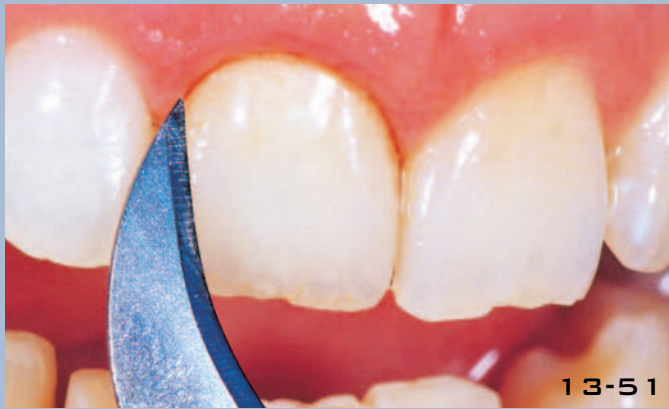The chapters on laboratory procedures related to prosthodontic treatment are written by two dental technicians, each focusing on a different aspect of dental technology in keeping with their natural predisposition and professional knowledge and experience. The practical information in these chapters can be readily applied by dental technicians. Romeo Pascetta contributed the chapters relating to accuracy with metal and ceramic materials, focusing in particular on cast ceramics and the latest CAD/CAM systems using innovative materials such as zirconium or alumina. Giuseppe Romeo is the author of the technical sections related to the esthetic implementation of prosthetic restoration, emphasizing the diagnostic waxup, communication with the patient and the clinician, and preparing all-ceramic restorations.

Our main objective in this book is to present high-quality, illustrative images and clinical cases that represent a practical point of reference and consultation for the clinician and the dental technician. It is with great pride and gratification that we present this work as a representation of our knowledge and daily practice, based on the experience gained over 15 years in the routine use of the stereomicroscope. It is our sincere hope that its publication will benefit clinicians, dental technicians, and patients worldwide.

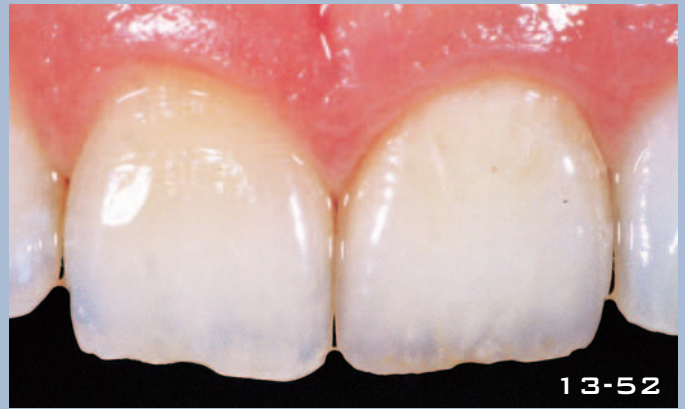Domenico Massironi



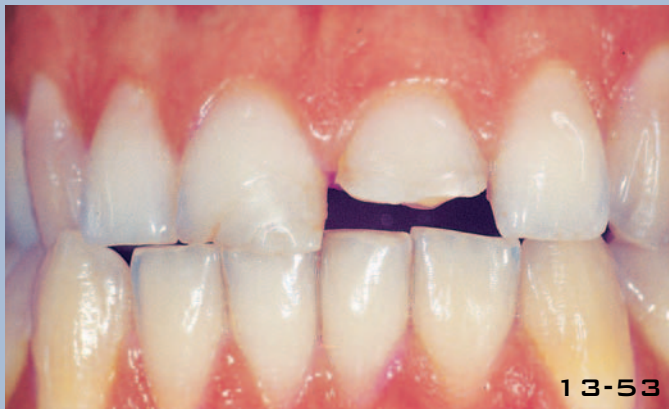Figs 9-49 to 9-51 Versatile impression materials can be used to take impressions of various restorations, including inlays, indirect gold posts and cores, and complete crowns. In the management of a professional dental office, material versatility is a considerable advantage for storage and handling. **Figs 9-52 to 9-54** Impression materials must be compatible with the other materials, such as electroplating silver, plaster, and polyurethane or epoxy resin.



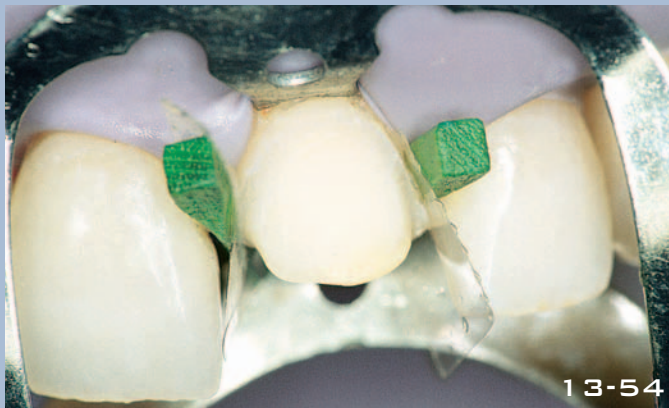
13-51



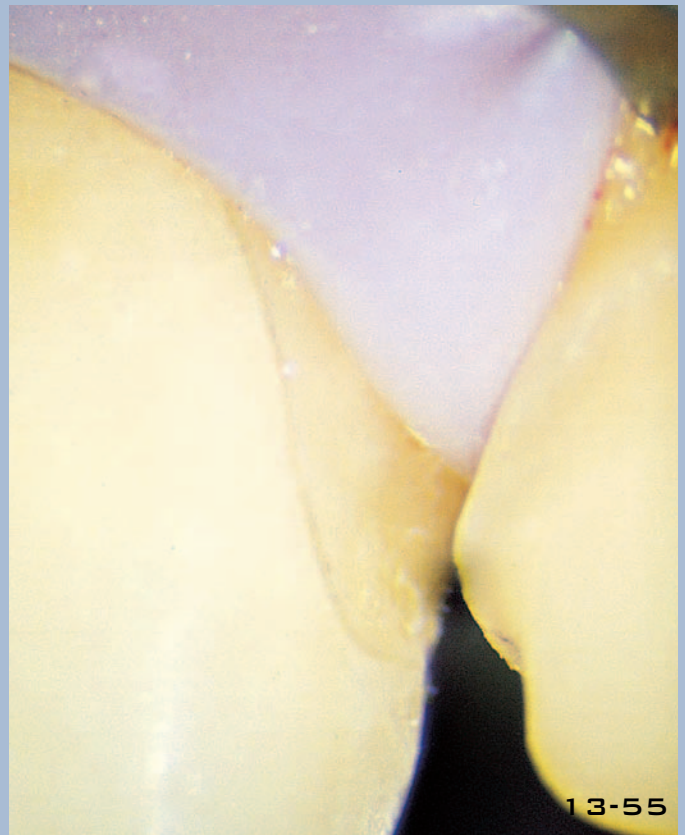13-52



13-53



13-54



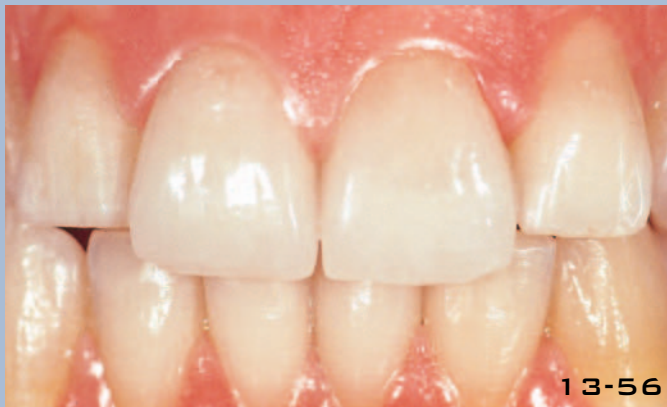13-55

Fig 13-51 Once polymerization is complete, excess bonding cement and polymerized composite are removed using a no. 12 scalpel with a curved blade.

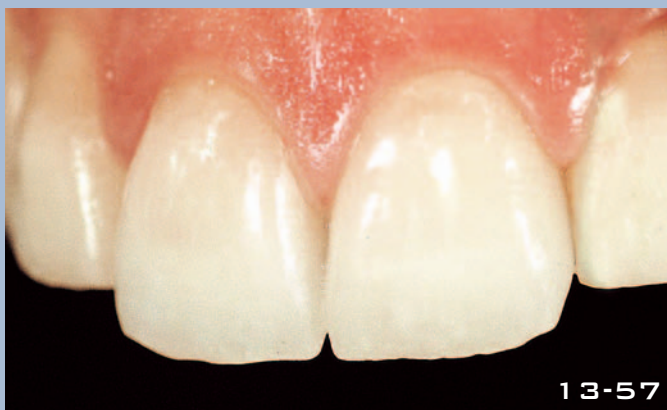Fig 13-52 Restoration is well integrated immediately after cementation.

Fig 13-53 Clinical case of two teeth fractured 8 years previously as the result of a trauma. The composite restorations were inadequate.

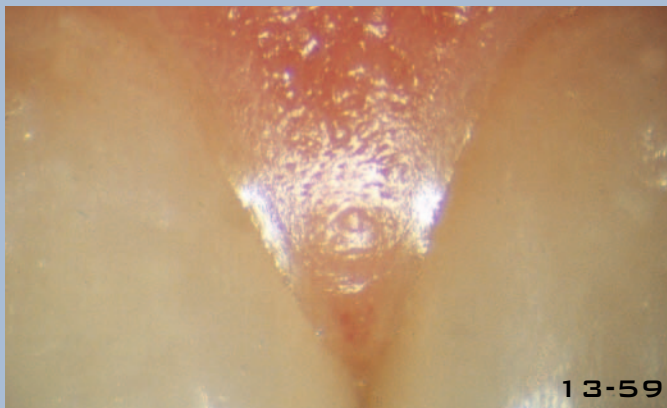
Figs 13-54 and 13-55 Cementation is performed with rubber dam isolation. The precision of the adjacent restoration, which has already been cemented, can be seen in the interproximal area shown under the stereomicroscope in Fig 13-55.



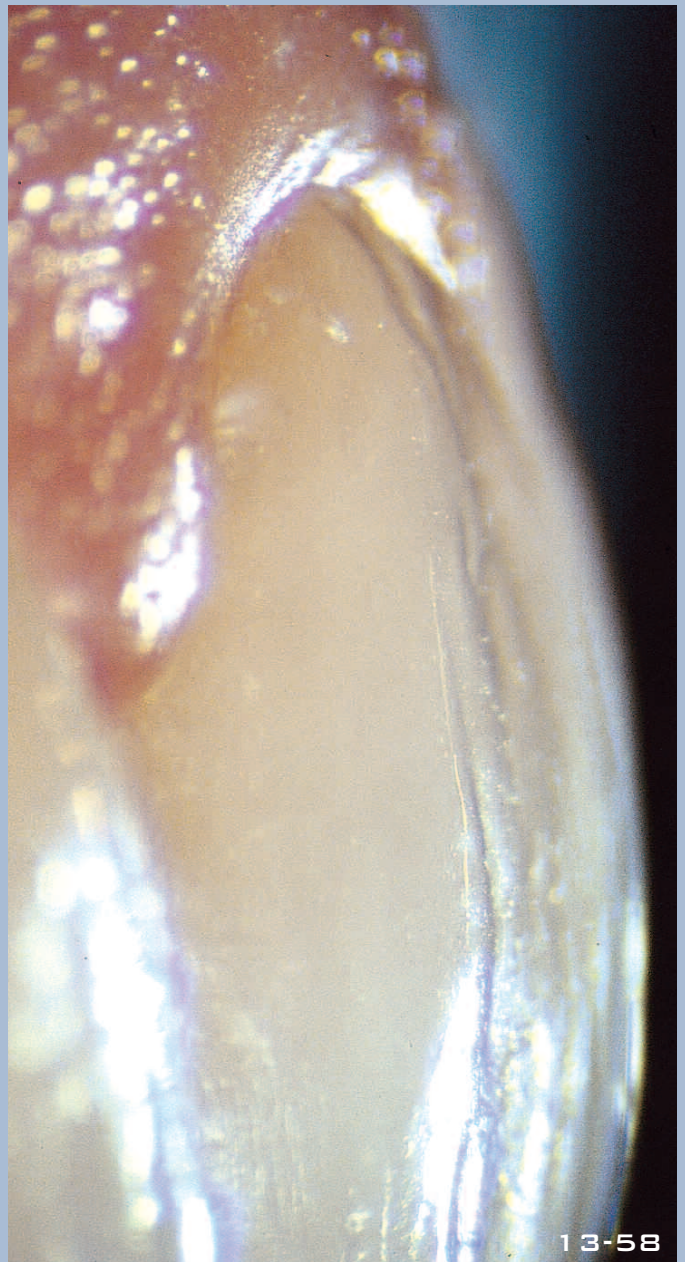
13-56



13-57



13-59



13-58

Figs 13-56 and 13-57 Definitive restorations in relation to the antagonist and adjacent teeth. The satisfactory integration of the veneers with the gingival tissues confers a pleasing appearance, despite the fact that the cervical margins of the lateral incisors are more coronal than the restorations.

Figs 13-58 and 13-59 Lateral view of the restorations seen through the stereomicroscope, and the frontal appearance of the papilla. Close adaptation of the gingival tissue to the ceramic surface is attributed to the migration of the epithelial attachment.