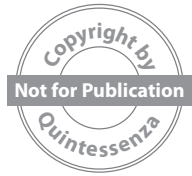

GAETANO **PAOLONE**

SALVATORE **SCOLAVINO**



ANTERIOR DIRECT RESTORATIONS

 **QUINTESSENZA PUBLISHING**

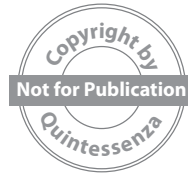Berlin | Chicago | Tokyo
Barcelona | London | Milan | Mexico City | Paris | Prague | Seoul | Warsaw
Beijing | Istanbul | Sao Paulo | Zagreb

Copyright by QUINTESSENZA EDIZIONI s.r.l. Tutti i diritti sono riservati.
È severamente vietata ogni tipo di riproduzione, copia, duplicazione, traduzione e trasmissione elettronica.



WeRestore.it

WeRestore.it (<http://werestore.it>) is an international educational project founded by Gaetano and Salvatore. The project aims at excellence, at the development of ideas, articles, videos, texts, materials, procedures, and research. The authors constantly carry out training courses in English and Italian in Rome or Milan and all over the world on request. info@werestore.it



How do you use a QR code?

Inside the book you will find several QR codes connected to related movies. To access these movies, you will need to scan each QR code. You will need to install a specific App on your device to read the code. Many of these Apps are freely available for the Android operating system on Google Play or the iOS operating system from the iTunes App Store (QR-Reader or similar). Once you have downloaded the App, hold your device so that the QR code appears in the viewfinder of the camera on your device. Your device will recognize the QR code and display a notification. Tap the notification to open the link associated with the QR code. You will then be able to view the movie.

ISBN: 978-88-7492-200-0



© 2024 Quintessenza Edizioni

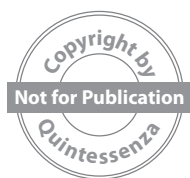Quintessenza Edizioni S.r.l.
Via Ciro Menotti, 65 - 20017 Rho (MI) Italy
Tel.: +39.02.93.18.08.21
Fax: +39.02.93.18.61.59
E-mail: info@quintessenzaedizioni.it
www.quintessenzaedizioni.com

All rights reserved.

This book or any part thereof are covered by copyright. They may not be reproduced, stored in a retrieval system, or transmitted in any form or by any means, electronic, mechanical, photocopying, or otherwise, without prior written permission of the publisher. Any unauthorized use is illegal and subject to legal proceedings. This is especially true for the reproduction of photos, copies, circulars, duplication, translations, microfilms, electronic processing, and data collection.

Printed in Italy

Copyright by QUINTESSENZA EDIZIONI s.r.l. Tutti i diritti sono riservati.
È severamente vietata ogni tipo di riproduzione, copia, duplicazione, traduzione e trasmissione elettronica.



To Isabella, Chiara and Edoardo

Gaetano

*To my sister Anna...
because those who live in the memory of those who
remain never die*

Salvatore

Foreword



When two 'young' authors, colleagues, and friends you have known and appreciated since their first steps into the world of restorative dentistry, ask you to present their book, there are two questions that naturally and automatically spring to mind: (1) Why me?; and (2) How is it possible to represent such a completely exhaustive work on the subject in just a few words? Having been called to write this presentation makes me proud; it honors me because this is nothing more than the transposition of what colleagues like Gaetano and Salvatore represent for our profession. Still young, with commitment, determination, and a lot of hard work they manage to realize and pass on their dreams; they are clinicians who can show how fascinating conservative dentistry is when applied to the sector with the highest esthetic value. They are rigorously trained clinicians, experts, and responsible for sharing the teachings acquired from others and all that they themselves have experienced. A fantastic example of what many of us have always pursued and which, today more than ever, must still represent a creed for growth and making excellence the result to be achieved every day in our work.

Scrolling through the contents of this second 'effort' by Gaetano Paolone and Salvatore Scolavino gives the idea of the completeness of their work. Thanks to the contribution of friends and talented colleagues, such as Alessandro Vichi and Giovanni Sammarco, the authors take the reader on a wonderful and rewarding journey through the fascinating world of direct esthetic restoration of the anterior teeth. Every single technique is described in detail, enriched by suggestions derived from rigorous professionalism and consolidated experience.

All of this is extraordinarily represented and characterized by impeccable scientific and clinical rigor but, at the same time, presented in a very easy understanding and transferability into daily practice, in search of that operational optimization that every operator should aim for.

To conclude this brief introduction, I sincerely congratulate to Gaetano, Salvatore, and all those who have contributed to the realization of this work, and extend my heartfelt thanks for having made available to those who love this marvelous branch of dentistry an instrument that communicates not only a message of absolute operational rigor but, above all, a wonderful enthusiasm and infinite passion for our profession. All this makes my 'young friends and colleagues' two absolute protagonists and points of reference for young professionals and all those who choose to aim for excellence, having understood that this should no longer be considered an advertising slogan, but the most powerful marketing strategy possible today.

Prof. Francesco Mangani

Professor of Restorative Dentistry Università degli Studi di Roma 'Tor Vergata', President of the Italian Academy of Conservative Dentistry 2020–2021

▶▶ Introduction



The dental profession has undergone considerable changes in the last two decades, with an important shift from the analog world to the digital one. However, regardless of the rapid development of modern digital technologies and their proven benefits in solving technical problems, simplifying the management of 'complex' cases and providing an obvious contribution to esthetic treatment planning, one should not think that that 'direct composite restorations' have consequently become a topic of minor interest. On the contrary! We have all heard of possible changes in the treatment of carious processes in the anterior sectors or esthetic deficiencies using three-dimensional printing, with an optical impression that can simultaneously detect the color of the tooth, which is then automatically reproduced by the machine. First, as yet there is no machine capable of printing a highly filled composite in a nongeometric, retentive cavity configuration; even if it were, would the eventual cost of a restoration produced from this technology be advantageous compared to that of direct composite restorations? In the coming years, not only will 'good' hands prevail over machines in such directions, but we will perpetuate the remarkable pattern of humans serving and caring for other humans! There are many indications within the smile frame where direct composites are a simple, yet effective, reliable, and cost-effective solution, with an overall pleasing esthetic outcome. Caries or fractures are still best treated with direct restorations, being the only conservative solution for these clinical situations. Young patients are also good candidates to benefit from no-preparation corrections or improvements instead of or in combination with orthodontic treatments. In a world with so much attention paid to esthetics and as modern technologies have not yet brought about

alternative treatment solutions for the aforementioned indications, it is of fundamental importance to excel in the mastery of direct restorations. However, as always, success does not happen by chance; it is the natural consequence of repeated and well-controlled procedures and an adequate selection of materials. The book by Drs Gaetano Paolone and Salvatore Scolavino is undoubtedly a valuable and complete source of information for anyone wishing to achieve excellence in the treatment of direct restorations in the anterior sectors. Whether you need to update or refresh your knowledge of shade and anatomy or want to explore detailed clinical protocols for several classes of restorations, shape corrections, and treatment of endodontically treated anterior teeth, you will find what you need in this textbook. The meticulous and inspiring documentation also supports the several layering modalities applicable to the above clinical situations, with full details of the instrumentation to be used. The many years of experience and the remarkable skills of the authors are reflected in all the chapters, and are highlighted by an exceptional photographic iconography. The whole treatment is presented in a systematic, attractive, and clinically oriented way; this textbook will undoubtedly become a classic and 'must have' in the library of any keen restorer. It has been an honor and a particular pleasure to write the preface to this outstanding textbook. With a firm belief that the pursuit of excellence is a contagious virtue, I wish all readers an inspiring and engaging learning experience!

Prof. Didier Dietschi, D.M.D, PhD,
Lecturer, University of Geneva (Switzerland) and Case
Western Reserve University (USA)

▶▶▶ Preface



We promised ourselves that we would not write another book because the making of a book takes a lot from you, both physically and mentally, taking away time for social and family relationships.

The feeling of embodying some of those writers described by Mark Twain, who manage to write two books at the same time, the first and the last, prevailed over this promise, and here we are with our second volume. Its contents, while standing on their own, find their maximum expression in synergy with the previous edition.

In a world where everything is increasingly impalpable, ephemeral, and elusive, a physical book has the purpose of giving concreteness and consistency to the professional path, of being a 'chairside' reference which, through step-by-step techniques and many clinical cases (some with follow-ups over 10 years) described, is proposed as a source of comparison with the professional experience of everyday clinical practice.

The clinical cases featured in this volume were performed with composites and adhesive systems from several different companies. However, it is not about the materials, it is about the knowledge and techniques.

▶▶▶ Acknowledgments

We thank the following individuals.

Vincenzo Musella, for having pushed us and helped us with the writing of our first book. Without him, we certainly would not have written either the first or second edition.

Lauro Dusetti for the friendly support provided and valuable advice.

Maria Grazia Monzeglio, Cristina Reina, Alessio Buono, Barbara Rossi, and all the Quintessence Publishing Italy staff for their incredible support and professionalism in managing our two editorial projects.

Sergio Ariosto Hernández Delgado DDS, MSD (Universidad Nacional Autónoma de México) for allowing us to use the photograph on the cover.

Stanislav Geranin, for the countless images of dental sections provided for our two editions.

Stefania DM, Patrizia S, Maria M, Maria C, Felicia N, Raffaella P, our irreplaceable assistants because without them nothing would have been possible.

Maria Giacinta Paolone and Roberto Kaitsas, for their synergy and common vision.

The Italian Academy of Conservative and Restorative Dentistry (AIC) for the passion, integrity, and professional rigor that it manages to convey. In a dental panorama polluted by misleading media messages, the AIC, together with other scientific societies, remains a point of reference for enthusiasts of restorative dentistry.

▶▶▶ Authors' resumes

GAETANO PAOLONE

Since 2014, Dr Paolone is a Research Professor in Restorative Dentistry, Università Vita Salute San Raffaele, Milan. He has a PhD in Dental Biomaterials (Portsmouth University, UK). He is an associate member of the American Academy of Restorative Dentistry and an active member of AIC.

Dr Paolone served on the board of AIC (as Secretary) in 2018–2019, and on its the scientific committee (2020–2022). He has his own private practice in Rome. He is a Lecturer on the Master in Esthetics and Restorative Dentistry, University of Bologna, Italy and on the Diploma in Esthetic Dentistry at Montpellier University, France. He is the author of the book 'Restauri diretti nei settori posteriori' (Direct Posterior Composite Restorations) published in 2018, which has been translated into English, German, and Chinese. He is the author of the book 'Restauri diretti nei settori anteriori' (Direct Anterior Restorations), published in 2020. He is also the author and co-author of several publications in international scientific journals and contributions in several textbooks. He has lectured on national and international courses and congresses.

SALVATORE SCOLAVINO

Dr Scolavino graduated with honors from the Federico II University of Naples, and has been an adjunct professor in Conservative Dentistry at the University of Milan for the academic year 2019–2020. He is an active member of AIC.

He works as a private practitioner in Nola (Naples) and is the author and co-author of scientific publications in national and international journals.

He is the founder of the WeRestore.it (<http://werestore.it>) project and author of the book 'Posterior Direct Restorations'. He is a Lecturer on the Master in Esthetics and Restorative Dentistry at the University of Bologna and a lecturer on the postgraduate Master in Restorative Dentistry and Aesthetic at the University of Turin.

He is a visiting lecturer on the 'Diplôme d'Odontologie Esthetique et Restauratrice', University of Montpellier, France.

He regularly carries out training activities related to restorative dentistry in Italy, abroad, and on online platforms.

▶▶▶ Contributors

This book was produced with the participation of the following contributors. Their contribution is indicated in the text.

MARIO ALLEGRI

Graduated with honors in Dentistry and Dental Prosthesis from the University of Verona in 1997. Specialized in adhesive techniques in conservative dentistry and the clinical application of new generation esthetic materials for metal-free indirect restorations. Holder of a scholarship for research on the use of composite materials reinforced with glass fibers in the construction of prosthetic structures on implants, at the same university, from 1998 to 2001. Active member of the Italian Academy of Conservative Dentistry since 2004, served as a member of the cultural commission from 2007 to 2015, and as a member of the board of directors for the biennium 2018-19. Active member of the Italian Academy of Esthetic Dentistry since 2012, served as a member of the membership acceptance committee from 2016 to 2018. In 2014, completed the Viesid Curriculum training program on “Gnathology and Occlusion in Interdisciplinary Dentistry” at the Vienna School of Interdisciplinary Dentistry (Director Prof. R. Slavicek). From 2015 to 2016, completed the Viesid Continuum training program on “Interdisciplinary Dentistry-Therapy and Treatment Concepts” at the same school. Since 2015, teaches at the Master’s program in Aesthetic-Adhesive Dentistry, University of Bologna (Director Prof. L. Breschi). Speaker at national and international congresses and author of publications on the clinical application of adhesive materials. Practicing as a freelance dentist in Verona, specializing in adhesive dentistry and the rehabilitation of complex cases with a multidisciplinary approach.

LUCIO DANIELE

University degree in Dentistry, University of L’Aquila (1994). Active member of: S.I.E. (Italian Society of Endodontology) since 1999; A.I.O.M. (Italian Academy of Microscope Dentistry) since 1999; E.S.E. (European Society of Endodontology) since 2003 (Certified Member); Past President (two terms) of A.N.D.I. L’Aquila (National Society of Italian Dentists). Currently serving as Cultural Secretary of the Abruzzo Section of S.I.E. (Italian Society of Endodontology) for the fourth term. Recipient of the Giorgio Lavagnoli Award in 2016. Speaker at numerous national and international congresses focusing on endodontics and surgical micro-endodontics. Author of the book “Direct Capping of the Dental Pulp” (EDRA, 2023). Author of the chapter “The odontogenic pain” in the textbook “Manuale di Endodonzia” (Elsevier, 2013 and 2021). Author of various scientific articles and monographs.

Instructor for basic and advanced Endodontics, as well as Endodontic Surgery, in hands-on courses in Italy and abroad. Currently practicing as a dentist in L’Aquila, Italy.

ONNY ERYANTO

Dr Onny Eryanto graduated in dentistry from University Airlangga, Surabaya, Indonesia in 2010. He is a Fellow of the Indonesian Society of Implant Dentistry. He actively attends continuing education courses on prosthodontic, restorative, and implant dentistry. He is currently a KOL and speaker in restorative dentistry nationally and internationally. He runs a private practice in Surabaya, Indonesia.

MARIA GIACINTA PAOLONE

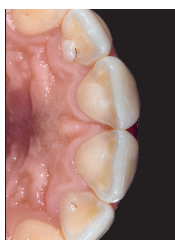Private Practitioner in Rome, Italy. Graduated from the Catholic University of the Sacred Heart, Rome, Italy. Completed postgraduate studies in Orthodontics at the same institution. Co-author of the book ‘Orthodontics & Periodontology: Combined Treatments and Clinical Synergies,’ published in 2021 with Roberto Kaitsas. Contributed a paragraph on the interactions between orthodontics and restorative dentistry in ‘Restauri Diretti nei Settori Anteriori (Direct Anterior Restorations)’ by G. Paolone and S. Scolavino. Holds certification from the European Board of Orthodontics and the Italian Board of Orthodontics. Active member of the Angle Society of Europe, the Tweed Foundation for Orthodontic Research, the World Society of Lingual Orthodontics, and the Italian Society of Orthodontics (Società Italiana di Ortodonzia). An effective member of the Italian Academy of Orthodontics and a Membre Titulaire, Collège Européen d’Orthodontie. Additionally, an active member of the European Society of Lingual Orthodontics, an International Member of the American Association of Orthodontists, and a Member of the World Federation of Orthodontists.

GIOVANNI SAMMARCO

Degree in Dentistry from the University of Verona in 1997. From 2015 to 2017, served as an adjunct professor for the entire curriculum of “Conservative Dentistry and Endodontics” at the Dentistry degree program of the University of Insubria (VA). Since 2015, he has been a lecturer in cariology at the II level Master in “Aesthetic Conservative Dentistry” (University of Bologna, directed by Prof. L. Breschi). He is an active member of AIC and IAED and the founder of the TRAP group (Tooth Respect and Prevention). He created the clinical cariology courses titled “Vincere la Carie”. He has published extensively and delivered lectures nationally and internationally on the subjects of caries, its prevention, and minimally invasive approaches. He operates in his private practice in Trento, utilizing the operating microscope.

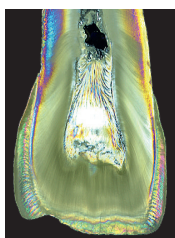
▶▶ Contents

Foreword by Prof. Francesco Mangani	IV
Introduction by Prof. Didier Dietschi	V
Preface	VI
Acknowledgments	VII
Authors' resumes	VII



CHAPTER 1 SHAPE AND ANATOMY OF THE ANTERIOR TEETH

The three-dimensionality of form	2
Cervico-incisal curvature	7
Mesiodistal curvature	8
Edges and their radius	9
Transition lines and areas	9
Coronal twist	11
Surface details	13
Vertical anatomy	16
Horizontal anatomy	17
Superficial texture (perikymata)	19
Embrasure	20
Changes in incisal edges	24
Escape routes	24
	28



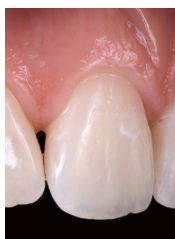CHAPTER 2 COLOR

Chromatic properties	30
Achromatic properties	34
Optical phenomena	36
Light quality	39
Resin-based composites for anterior restorations: which ones?	40
	41



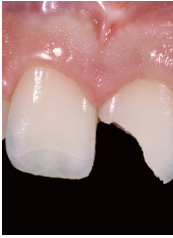CHAPTER 3 TOOLS

Tools to isolate the anterior sector	44
Ligatures	46
Tools to photograph the anterior teeth	50
Color detection tools	54
Clinical procedure: Case 1	64
Instruments for modeling composites	68
	71

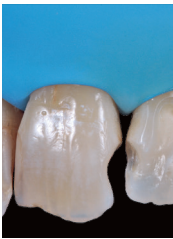

CHAPTER 4 WHITE LESIONS MINIMALLY INVASIVE TREATMENTS OF WHITE DYSCHROMIAS IN THE ESTHETIC AREA

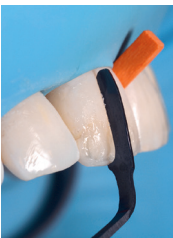Diagnostic criteria	72
Minimally invasive procedures	75
	78



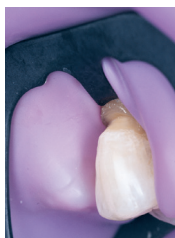CHAPTER 5	
TRAUMATOLOGY: FRAGMENT REATTACHMENT	94
Type of fracture and impairment of pulp vitality	98
Fragment storage and hydration	98
Diagnostic phase	99
Fragment cleaning and rehydration	101
Clinical procedures	101
Tooth reattachment in the presence of diastemas	103
Clinical protocol	104
Preparation of the tooth	104
Fragment preparation	105
Reattachment of the fragment	105
Preparation of the fracture gap	106
Silicone matrix-guided reattachment	108
Clinical case	108
... and what if you expose the pulp?	118
Clinical procedure	119
... and what if the fragment detaches?	123



CHAPTER 6	
CLASS III ANTERIOR INTERPROXIMAL LESIONS	128
Classification	130
Classification of class III cavities according to Paolone and Scolavino	131
Preparation	133
Class III layering	140
Division I layering	140
Division II layering	141
Division III layering	143
Division IV layering	146

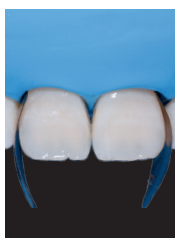

CHAPTER 7	
RESTORATION OF THE ANTERIOR TEETH INCLUDING THE INCISAL EDGE: CLASS IV	156
Shape	157
Transferring the shape information	158
Calibra	164
Translucencies	168
Preparation	171
To bevel or not to bevel the margin?	173
Preparing the margin: advantages, disadvantages, and trade-offs	174
Layering with low-CAP dentin	175
Marking boundaries on the index	176
Palatal wall and incisal edge molding	177
Solution A (recommended)	177
Solution B	179
The interproximal walls	181
Frame modification: 'pre-finishing'	183
Dentinal body	185
Translucent shade	189
Modeling liquids	193
Layering with high-CAP dentin	194
Clinical cases	197



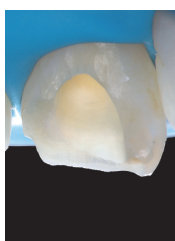
CHAPTER 8 CERVICAL LESIONS

Cavity preparation	278
Combined restorative and periodontal strategies	283
Clinical evaluation	305
Treatment plan	305
Restorative procedures	310
Periodontal procedures	310



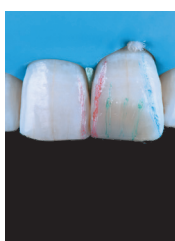CHAPTER 9 DIRECT VENEERING, DIASTEMA CLOSURE AND SHAPE MODIFICATIONS

Shape modifications with composite materials	312
Diastema closure	316
Direct veneering	319
Clinical cases	325
Interactions between orthodontics and restorative dentistry	334
Clinical cases	374
	376



CHAPTER 10 POST-ENDODONTIC RESTORATIONS

Internal whitening	394
Use of fluorescent materials	395
Texture	397
Residual structure and posts	397
Clinical cases	399



CHAPTER 11 FINISHING AND POLISHING

Tool for finishing	430
Finishing	433
Pre-Finishing: The scientific background and how-to procedure	434
Final finishing	435
Tips...	436
Contouring	437
Modification of the outline	438
Definition of the lines and transition areas	439
How to move or change a transition line	440
Definition of incisions and developmental grooves	442
Reproduction of perikymata	443
Smooth surface finish	445
Let us practice together	446
Transition lines	448
Reproduction of the engraving at the incisal edge of the developmental grooves	448
Drip depression	450
Distal depression	451
Definition of horizontal depressions	452
Perikymata	453
Selective rubbering	454
Polishing tools	455
	457

Chapter 6

Class III
anterior
interproximal
lesions



Class III cavities affect the proximal surface of the anterior teeth without involving the incisal edge. Given the difficulty in chromatically camouflaging a small composite restoration in an area where the tooth-restoration transition has a very limited extension, these cavities may represent a very complex esthetic challenge for the clinician.

Class III restorations are the restorations with the highest longevity,^{1,2} probably because they are placed in low-stress areas, are generally not large, and the cavity is completely surrounded by enamel.³

In this chapter, the classification, preparation, and layering techniques for the restoration of class III carious processes are described.

Classification

According to the cavity configuration, we classify class III cavities as follows (**Figs 1 to 3**):

- **division I:** interproximal cavity with preservation of the buccal and palatal walls;
- **division II:** interproximal cavity with palatal access and preservation of the vestibular wall;
- **division III:** interproximal cavity with vestibular access and preservation of the palatal wall;
- **division IV:** passing-through interproximal cavity (loss of palatal and buccal wall).

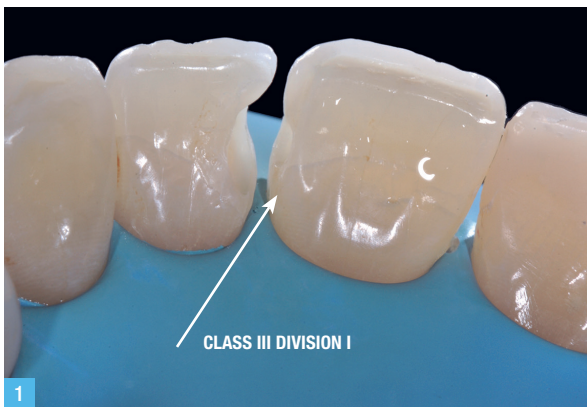

Fig 1. On tooth 1.1, class III division I.

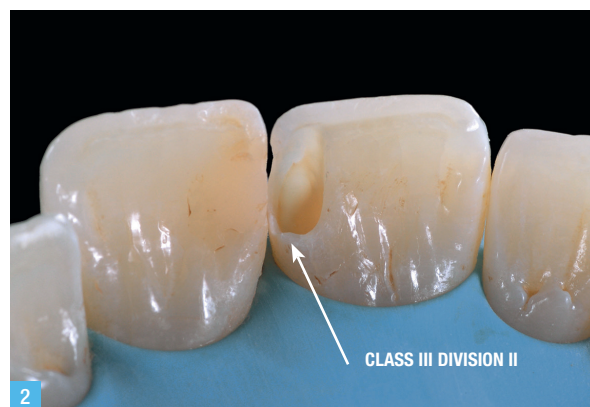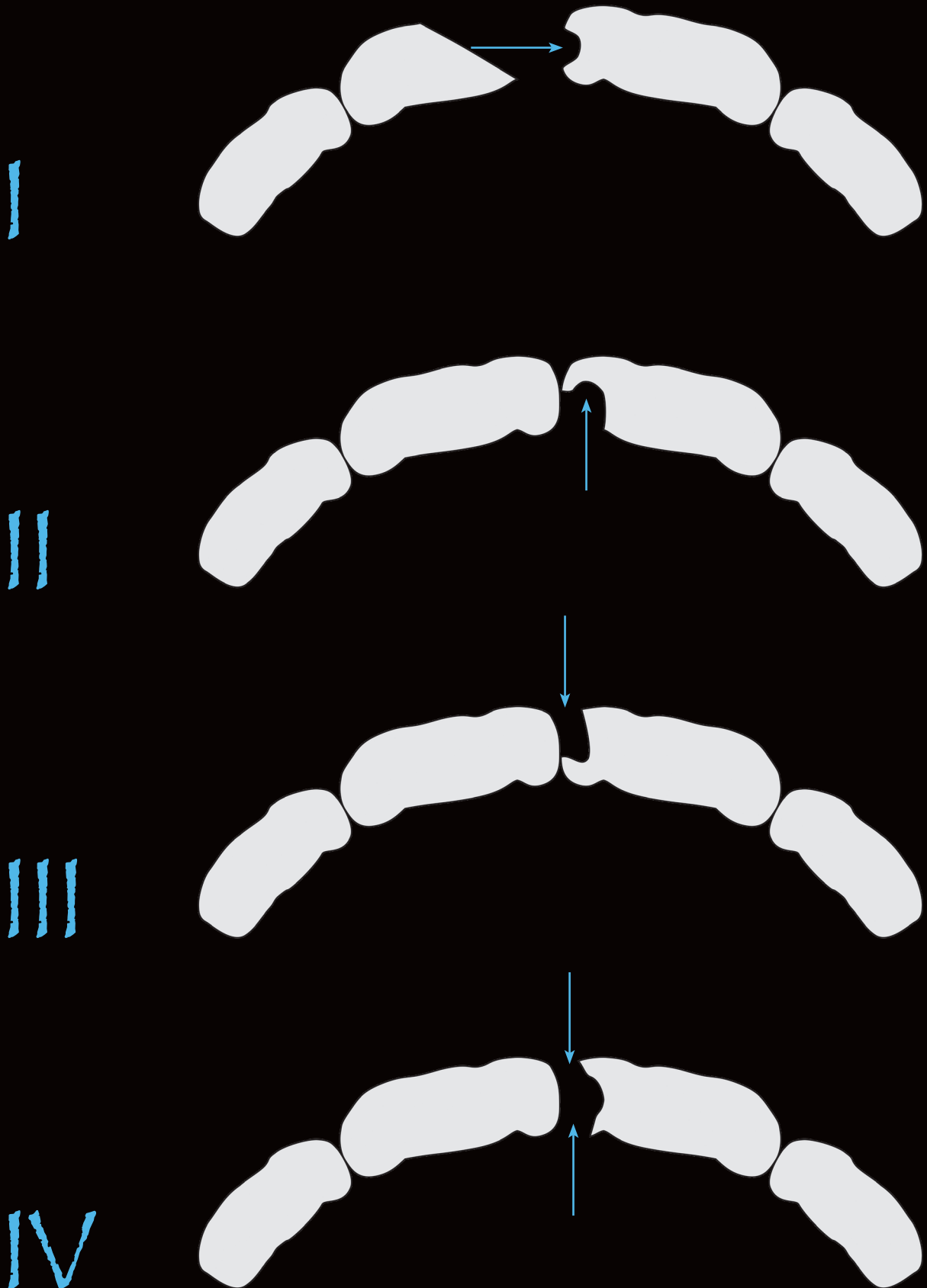


Fig 2. On tooth 2.1, class III division II.

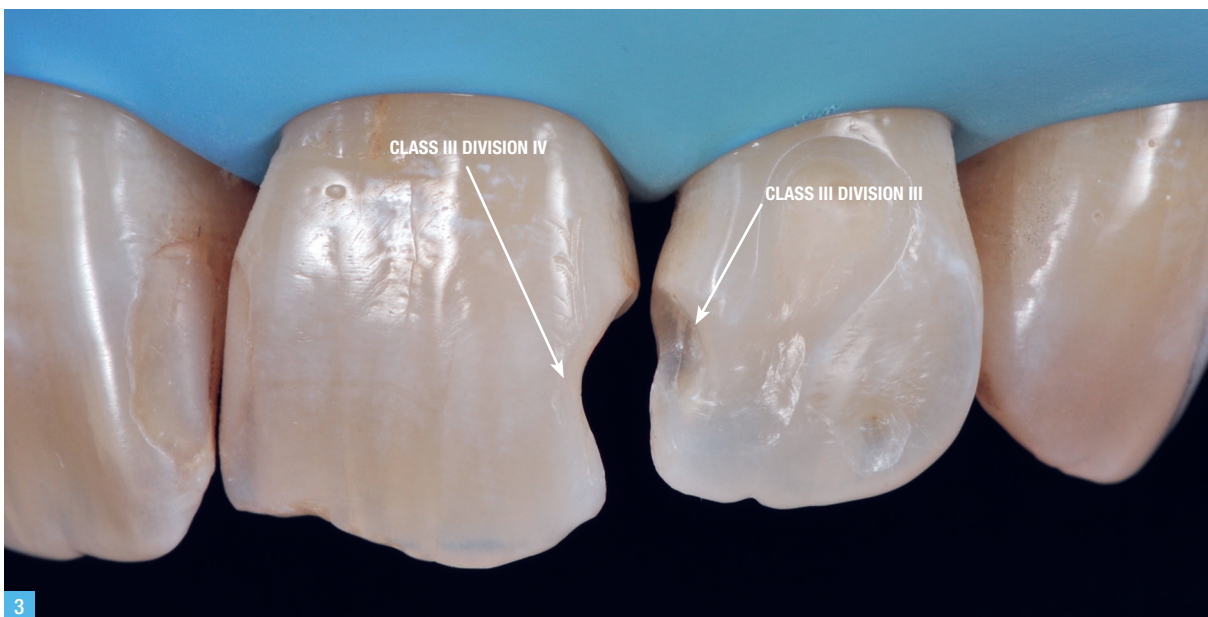

Fig 3. On tooth 2.1, class III division IV; on tooth 2.2, division III.


Classification of class III cavities according to Paolone and Scolavino





4

Fig 4. Diamond flame bur (friction grip [FG] connection).



5

Fig 5. Red contra-angle diamond round bur (FG connection).



6

Fig 6. Blue contra-angle round multi-blade bur (CA connection).



7

Fig 7. Diamond olive (FG connection).




8

Fig 8. Arkansas bur (FG connection).



9

Fig 9. Silicone rubber flame (FG connection).



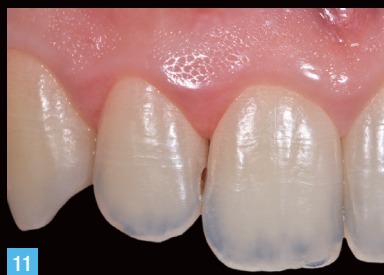10

Fig 10. Coarse abrasive disc.

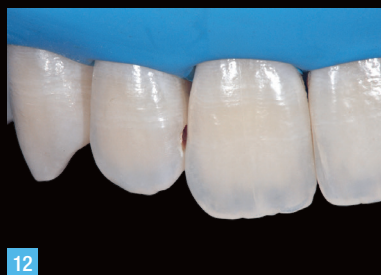Preparation

The choice of bur to prepare a class III restoration depends on the extent of the carious process. For small cavities, as in the clinical case described in **Figs 11 to 18** (class III, division III), it is advisable to carry out access using a flame diamond bur

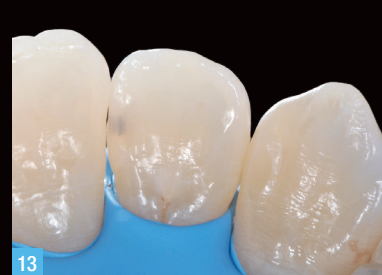(**Figs 4 to 15**); once the affected enamel has been removed, it will be possible to remove the carious dentinal tissue using a multi-bladed round bur (**Fig 6**) whose dimensions will be chosen according to the cavity width.



11

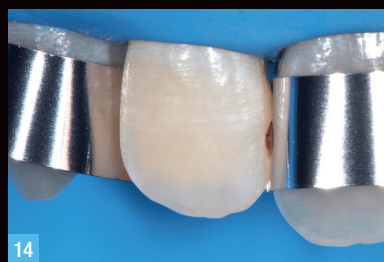

12

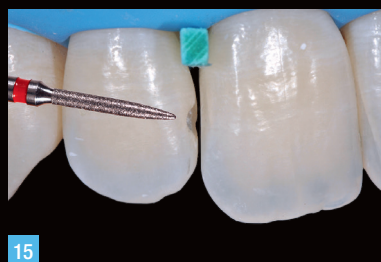

13

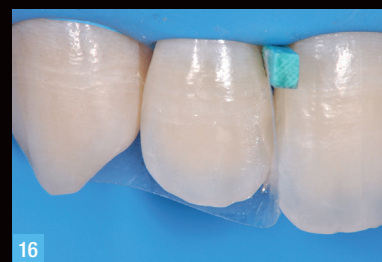Fig 11. Class III division III carious process on tooth 1.2. **Fig 12.** Isolation of the operative field. **Fig 13.** Palatal enamel preservation and the initial buccal cavity suggest to proceed with buccal access.



14

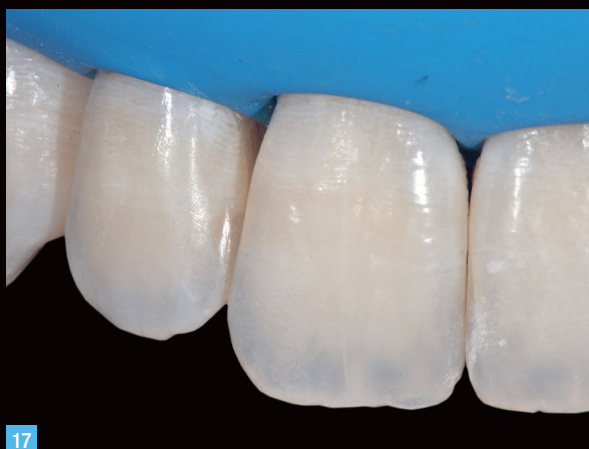

15

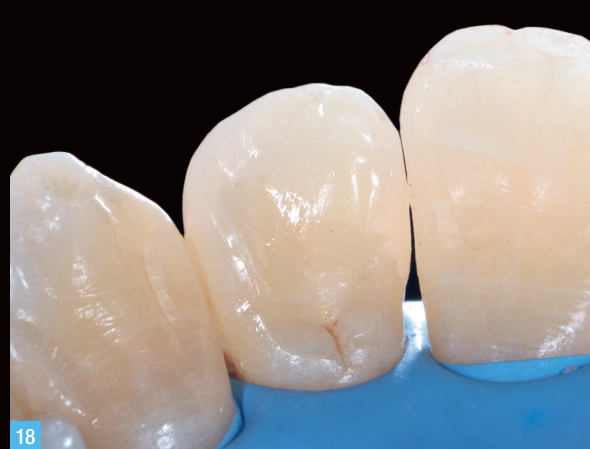

16

Fig 14. Protection of contiguous teeth from iatrogenic damage using a metal strip. **Fig 15.** Access performed with a flame diamond bur and cleaning of the cavity with a multi-bladed round bur. **Fig 16.** Restoration performed with body shade A3.

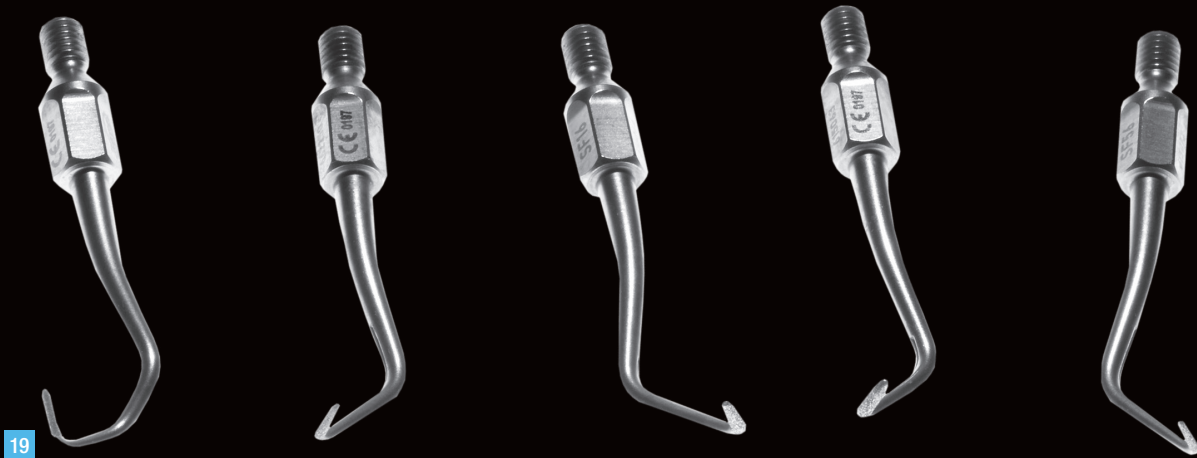


17



18

Fig 17. Class III restoration completed, finished, and polished under the rubber dam. **Fig 18.** Palatal view.



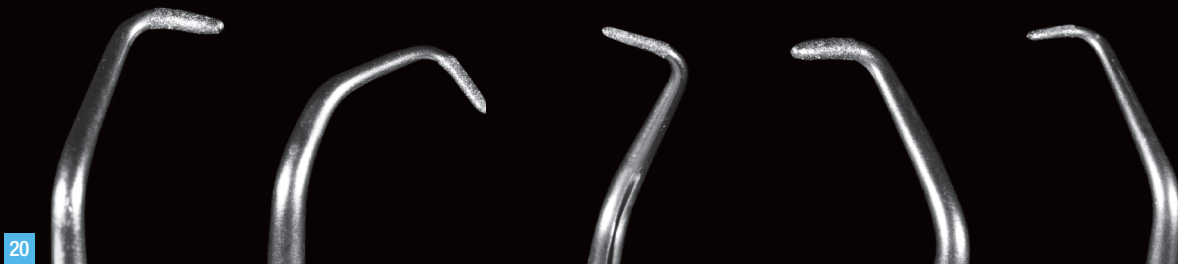19

Fig 19. Sonic diamond inserts for endodontic purposes may serve as cavity preparation.

Sometimes, difficult access to class III cavities may require the use of sonic tips (**Figs 19 and 20**) which depending on the various angles of the working tips and of variable shapes and sizes, allow reaching the most hidden and narrow areas, to be able to draw a correct finishing margin. The preparation of slot-type cavities (division I) is possible

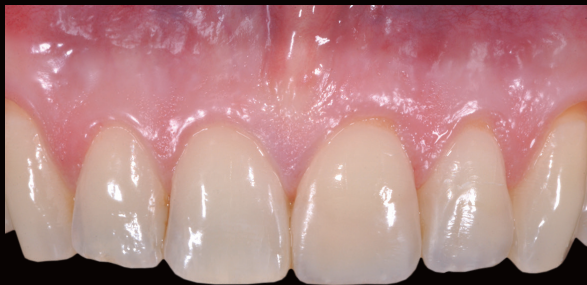only when there are two adjacent cavities, as in the case described in **Figs 21 to 26**, where two class III are involved: division I on tooth 1.1 and division IV on tooth 1.2.

In these cases, it is always preferable to first prepare the largest cavity (ie, tooth 1.2), to then find an easier access to the slot preparation on tooth .



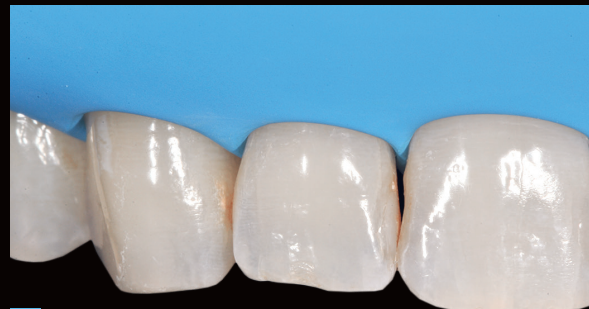20

Fig 20. Sonic diamond inserts for cavity preparation.



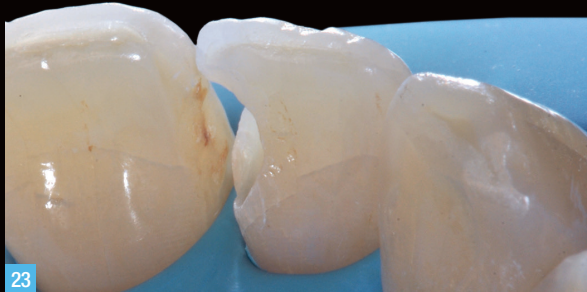21

Fig 21. Initial clinical situation of a case with classes III of teeth 1.1 and 1.2.



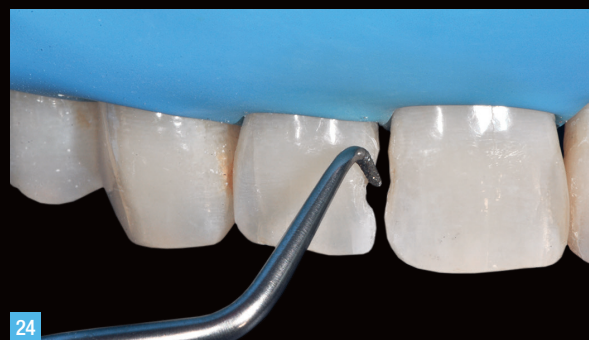22

Fig 22. Isolation of the operative field.



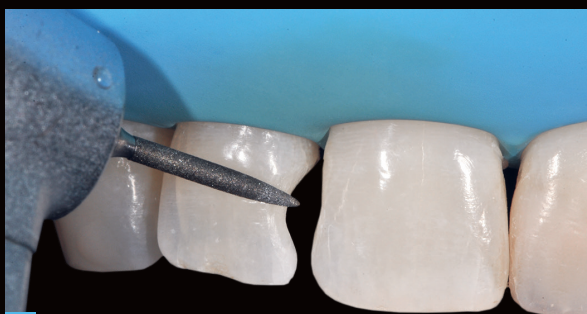23

Fig 23. Once the largest cavity was opened (the one mesial to tooth 1.2), it was possible to access class III division I of tooth 1.1.



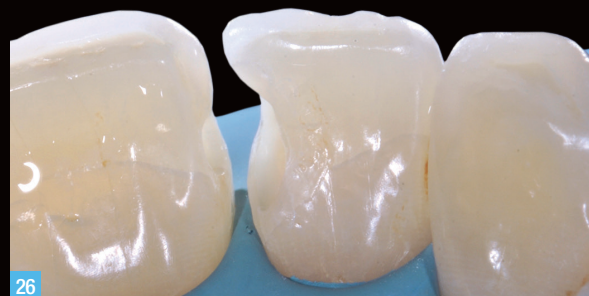24

Fig 24. To perform a slot preparation on tooth 1.1, a sonic insert was used, which simplifies access and allows for a minimally invasive approach.



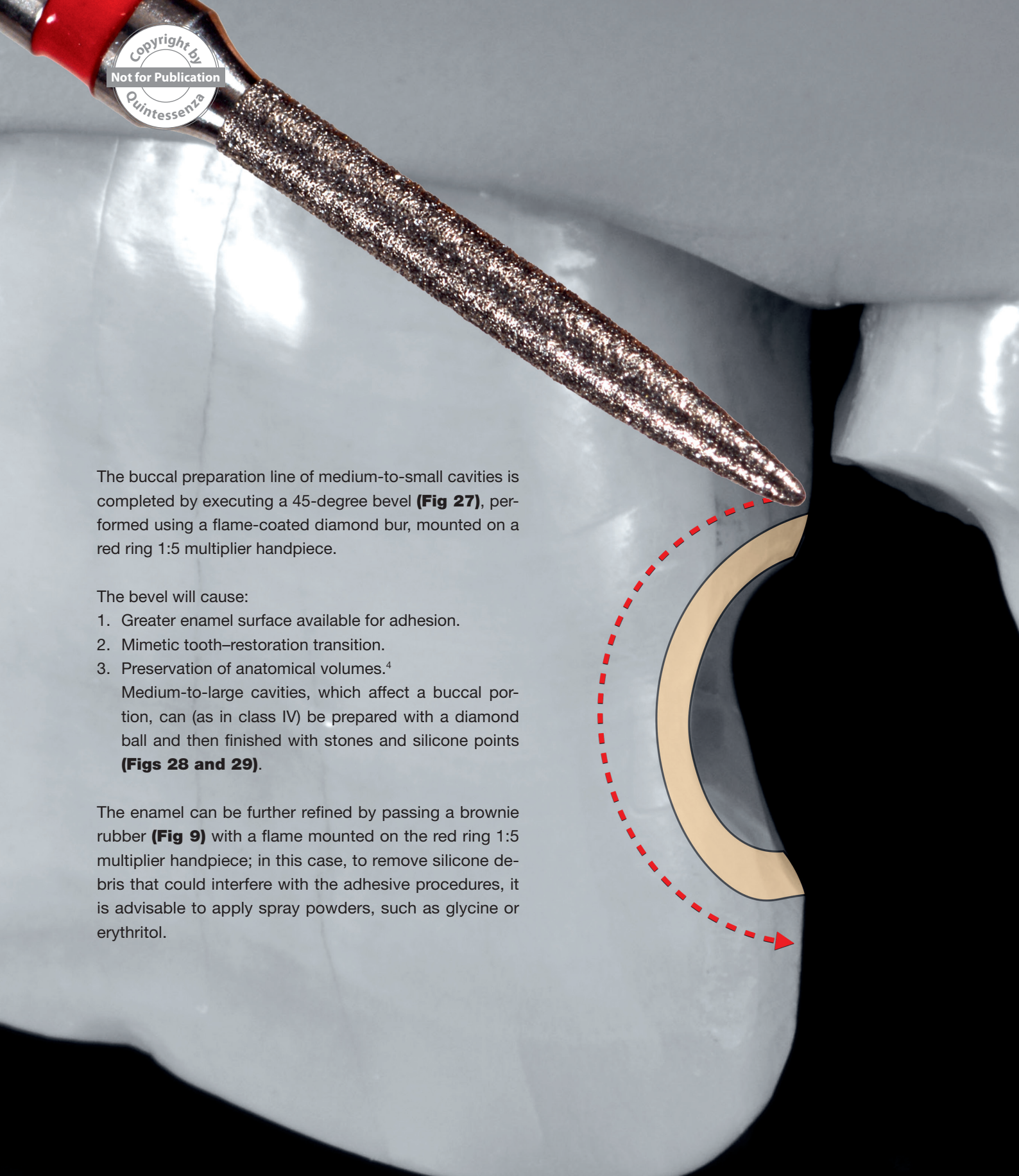
25

Fig 25. Buccal preparation of tooth 1.2 completed by creating a 45-degree bevel along the entire preparation line, which has the function of increasing the enamel available for adhesion and enhancing the tooth and restoration camouflage.



26

Fig 26. Appearance of the finished preparations.



The buccal preparation line of medium-to-small cavities is completed by executing a 45-degree bevel (**Fig 27**), performed using a flame-coated diamond bur, mounted on a red ring 1:5 multiplier handpiece.

The bevel will cause:

1. Greater enamel surface available for adhesion.
2. Mimetic tooth-restoration transition.
3. Preservation of anatomical volumes.⁴

Medium-to-large cavities, which affect a buccal portion, can (as in class IV) be prepared with a diamond ball and then finished with stones and silicone points (**Figs 28 and 29**).

The enamel can be further refined by passing a brownie rubber (**Fig 9**) with a flame mounted on the red ring 1:5 multiplier handpiece; in this case, to remove silicone debris that could interfere with the adhesive procedures, it is advisable to apply spray powders, such as glycine or erythritol.

Fig 27. Buccal 45-degree bevel made with a flame diamond bur on red contra-angle (1:5).

**“During the bevel construction phase,
the bur will always have to follow the radius
of curvature of the preparation line,
maintaining an inclination of about 45 degrees”.**

