

Eric Van Dooren | Florin Cofar
Victor Clavijo | Gustavo Giordani | Venceslav Stankov



Interdisciplinary Esthetic Dentistry

—synergies

**Optimising
complex cases**

The
big
Picture

Volume 2

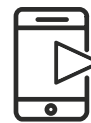
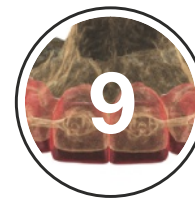
Interactive videos

Augmented reality in this book!

This book contains augmented reality videos available free of charge from your smartphone or tablet.

Easy to use, reliable, instantly accessible, and available offline, you can find selected multimedia content created by the authors to enrich your reading experience.



Download

the app “Quintessence Van Dooren-Cofar” from the Apple Store (iOS) or Google Play (Android).

Select a chapter

among those with augmented reality content.

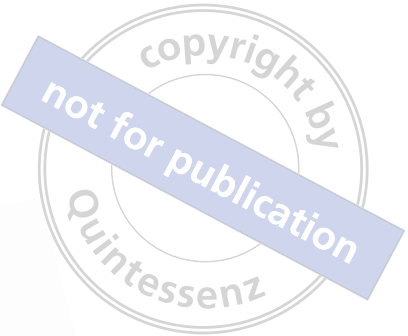Locate

clinical photographs with the augmented reality symbol.

Roll over

these photos on your smartphone or tablet using the app to play the videos.





Final prosthetic rehabilitation

This one-step protocol, the use of a dental...
is an essential element. It will allow
perfect isolation of the surgical field.
The prosthetic elements can then be
assembled in complete safety, protected
from blood and saliva. The surgical field
before guarantees the durability

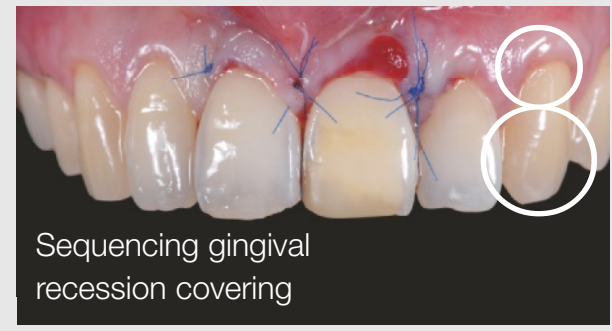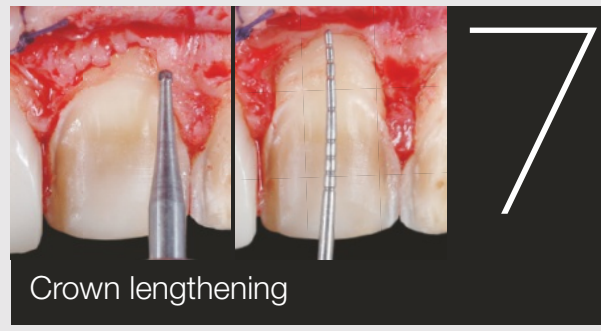
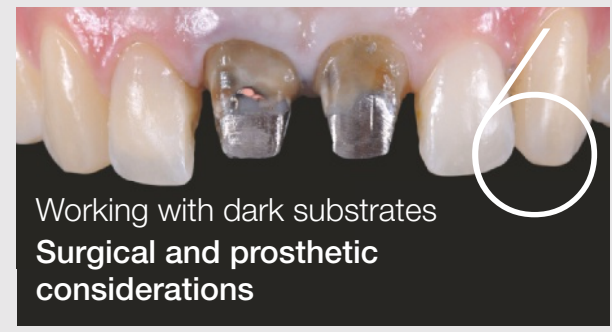
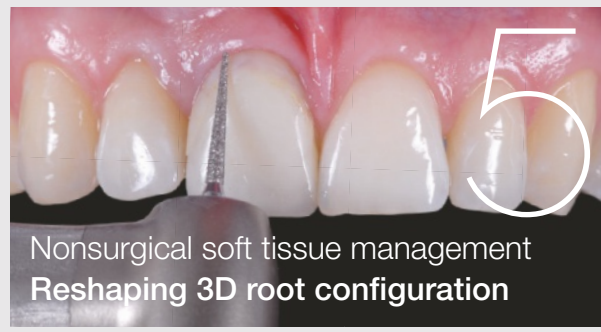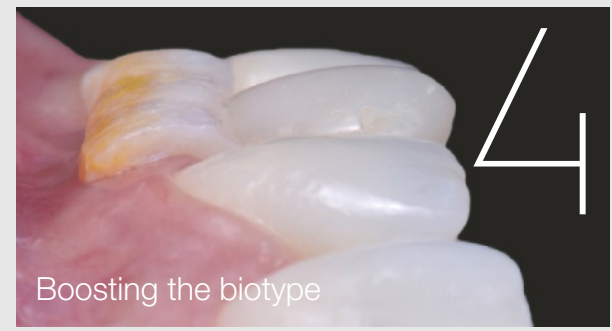


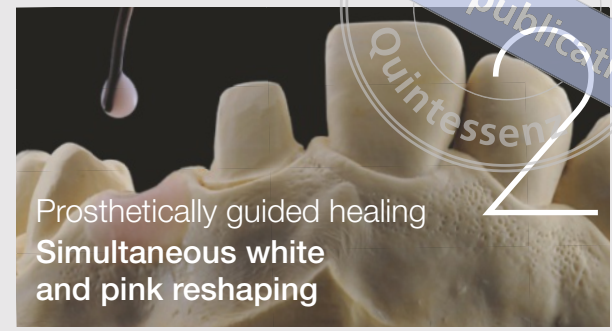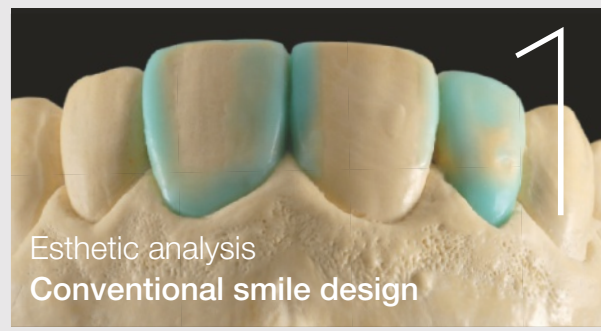copyright by
not for publication
Quintessen

_basics Planning and execution – Volume 1

Contents

Interactive videos.....IV
Suggested reading..... Volume 3



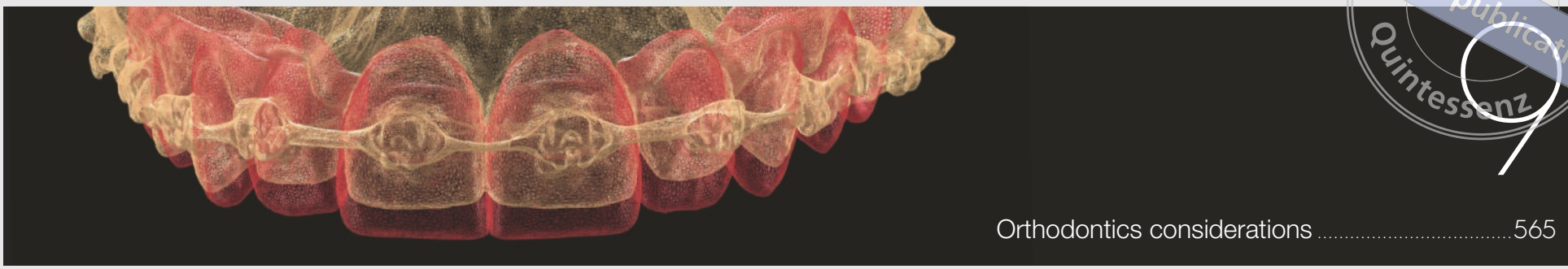
Interactive videos

This book contains augmented reality

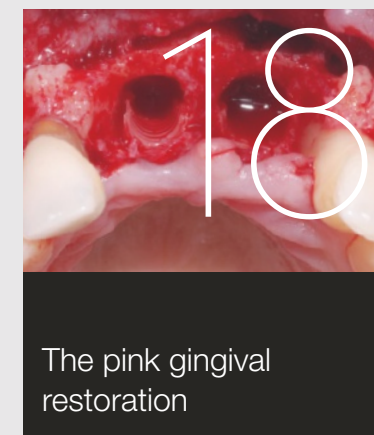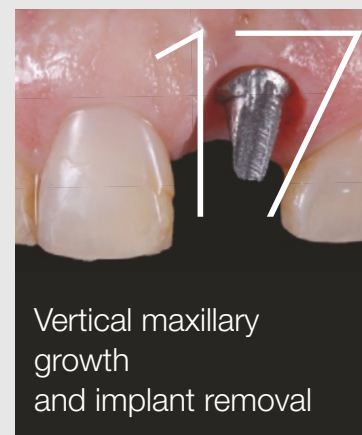
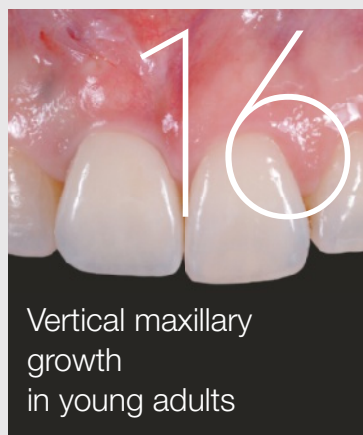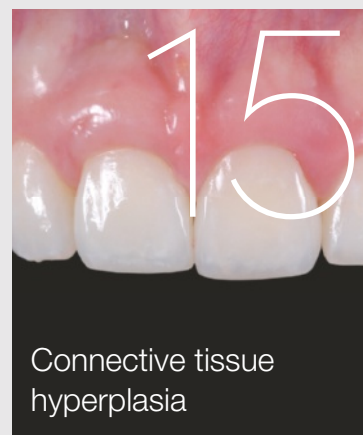
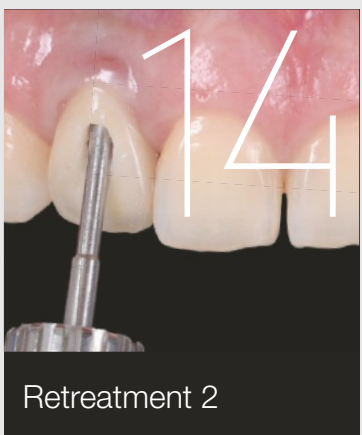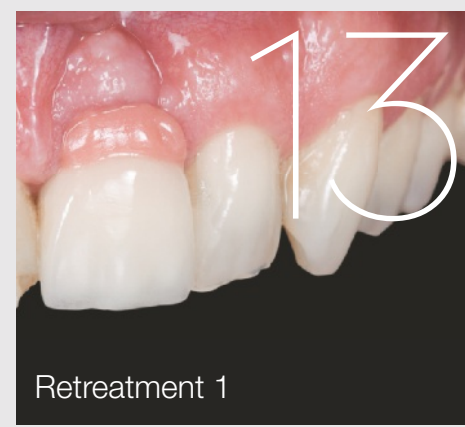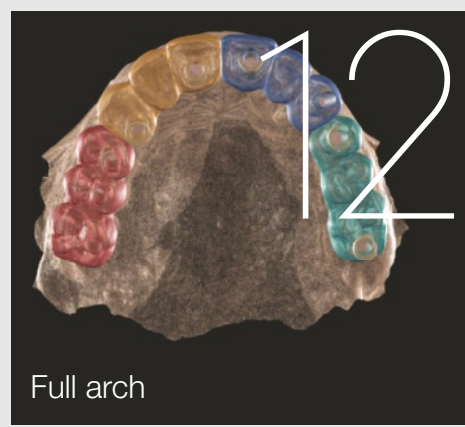
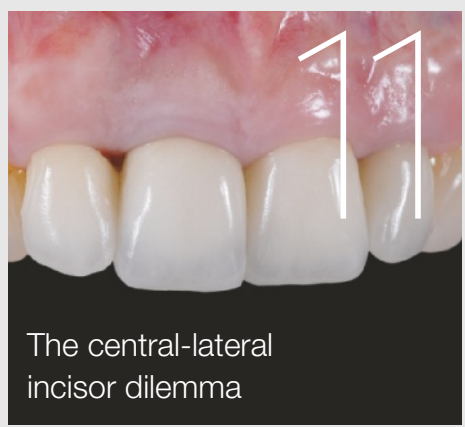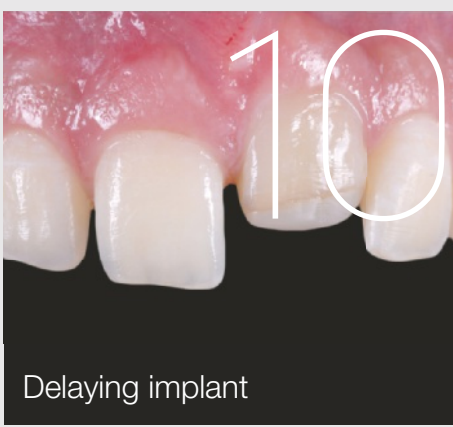
videos available for free from your smartphone or tablet.

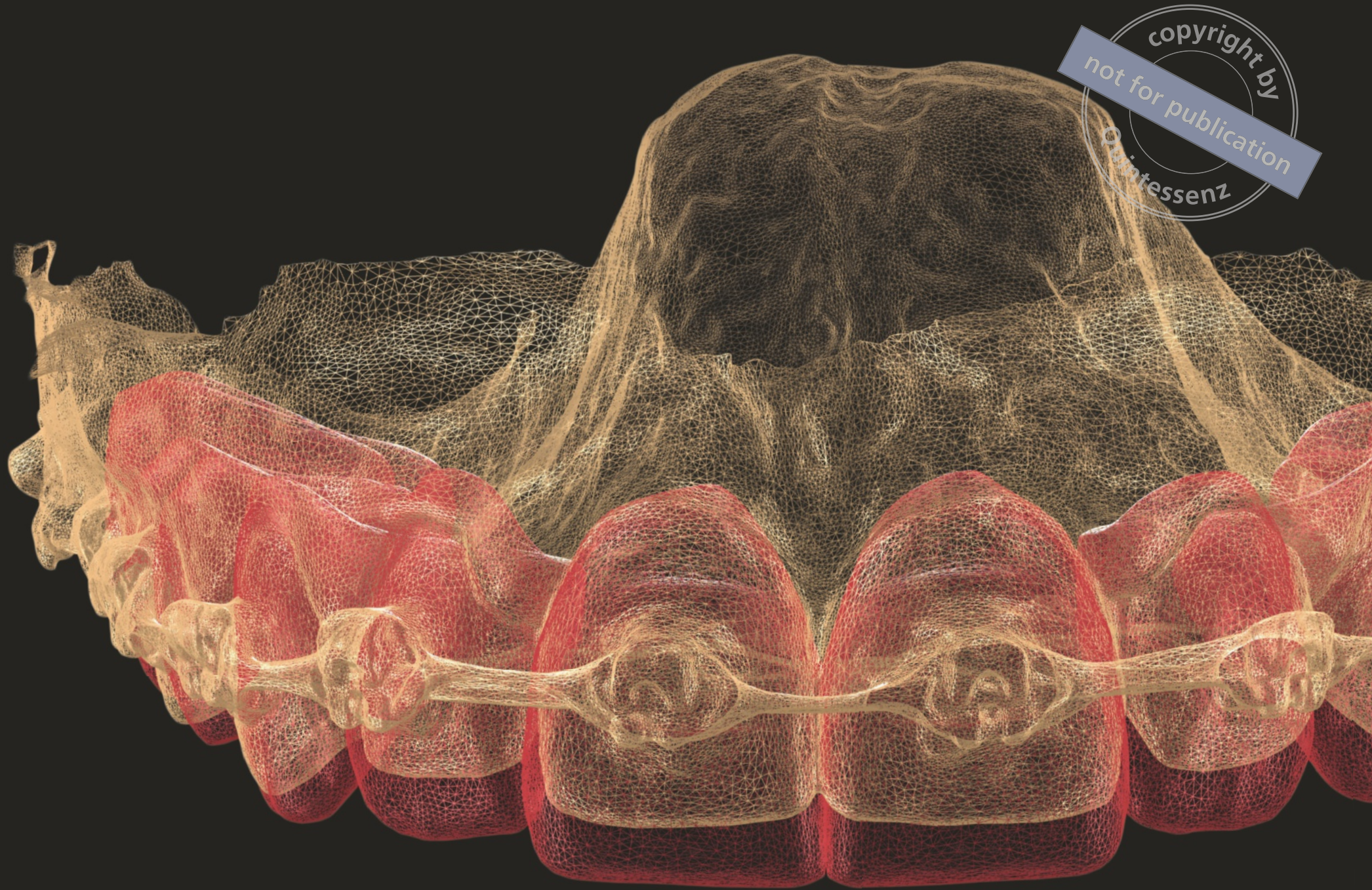
copyright by
not for publication
Quintessenz

_synergies Optimising complex cases – Volume 2

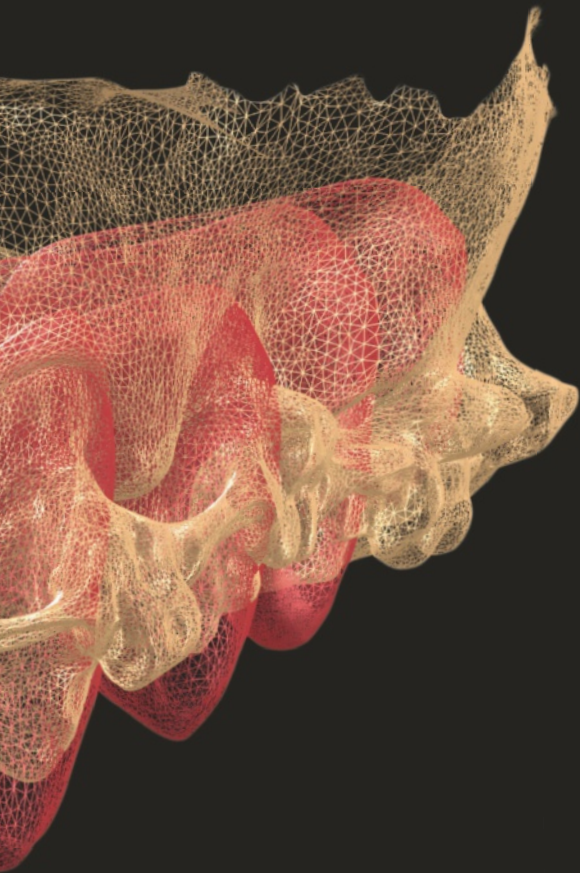


_complications Retreatments and maintenance – Volume 3

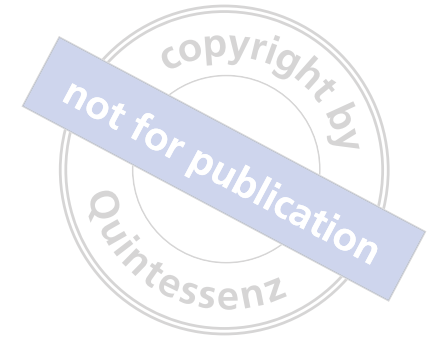



copyright by
not for publication
Quintessenz



Orthodontics considerations



Interdisciplinary orthodontics classes

This classification is meant to help define the goal of an interdisciplinary treatment that requires orthodontics. The classification can be applied at the level of a full treatment, an arch, or even a tooth.

It is a decision based on what is more important between the following four choices:

- the optimal tooth position of the natural tooth;
- the optimal position of the future restored tooth;
- the architecture of the papillae of the future restored tooth;
- moving the entire dentoalveolar complex.



Class I **Dental**

Final esthetics or function or both can be achieved with or without minimum restorative treatment.

569

Class II **Cementoenamel junction (CEJ)**

Final esthetics or function or both cannot be achieved without restorative treatment.

659

Class III **Bone levels**

Final esthetics or function or both cannot be achieved without restorative treatment; defects in the papillae or asymmetry or both are present.

695

Class IV **Skeletal**

Final esthetics or function or both cannot be achieved without skeletal or surgical orthodontics.

797



Class I

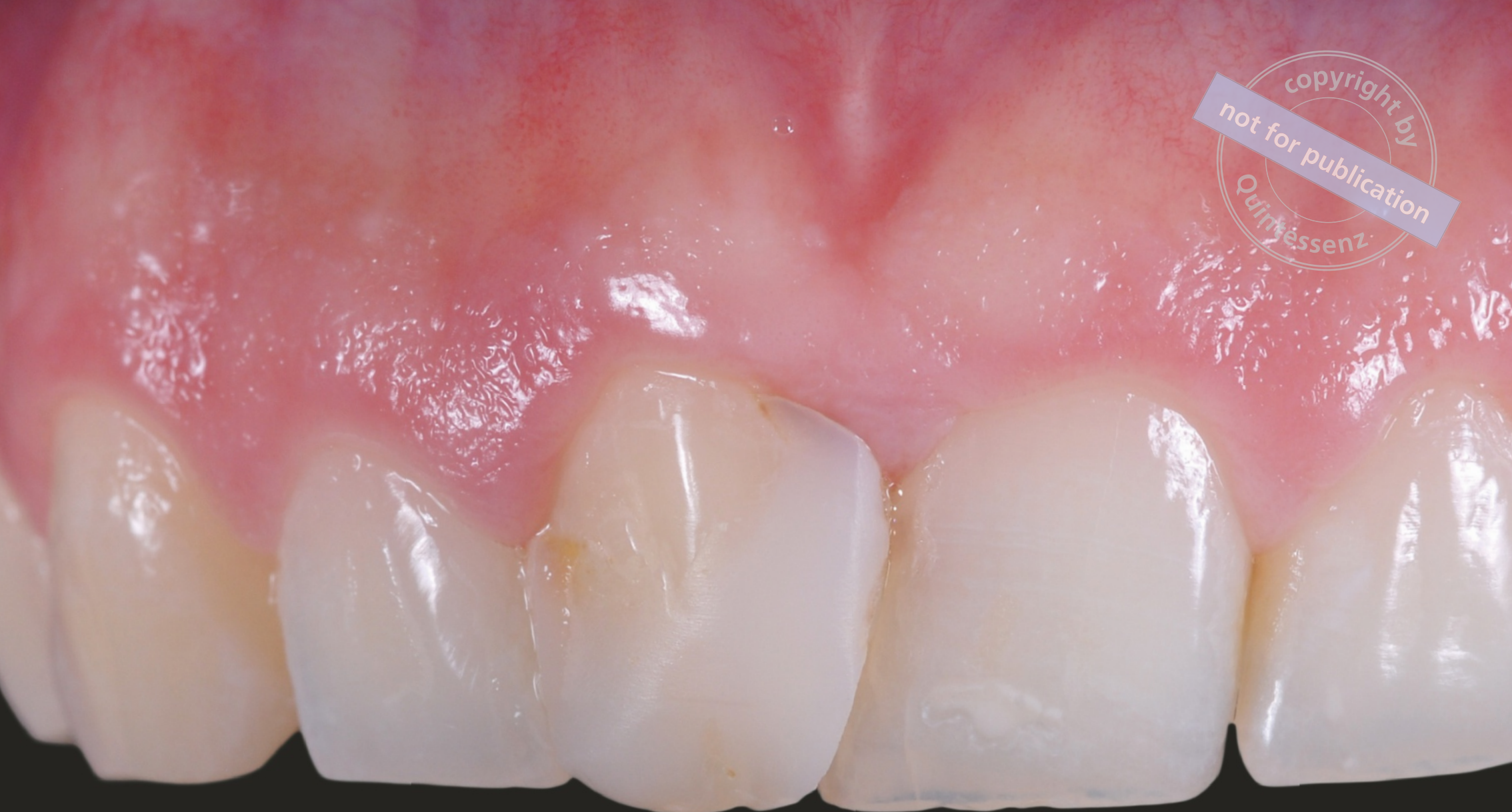

Dental

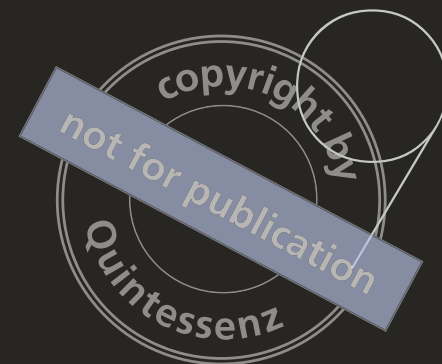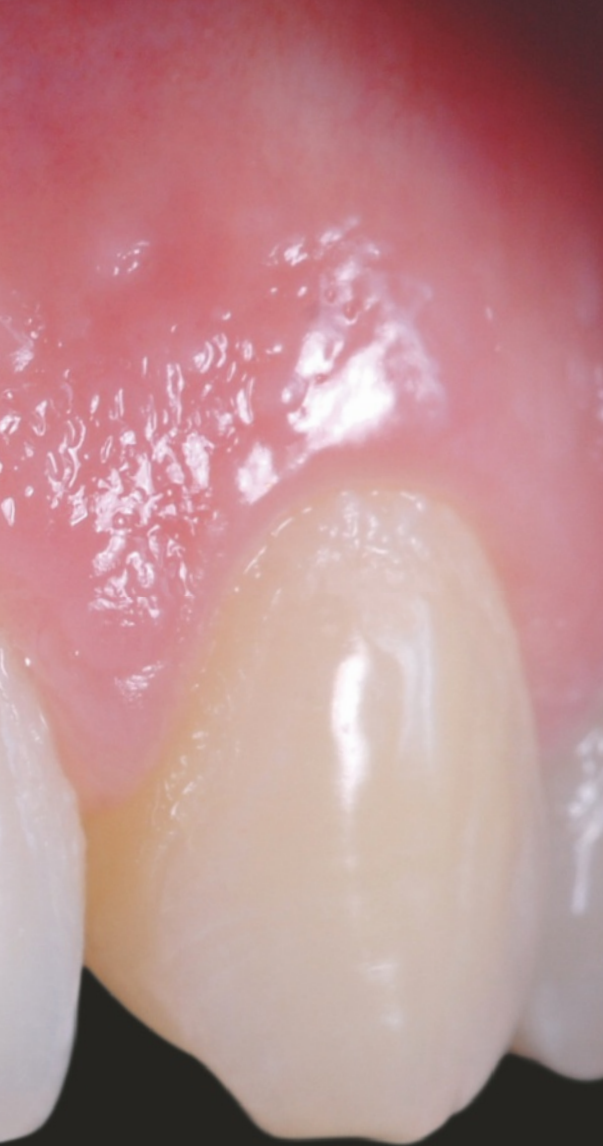Aligning teeth

Class I is the default orthodontic treatment, which focuses on aligning the existing teeth, specifically their incisal edges. This is always the case when dealing with natural dentition and where no or very minimal prosthetics is planned.

This class has minimal interdisciplinary interactions and the main problem, whether it is esthetic, functional, or both, derives from misalignment of the existing teeth. However, teeth are intact, or with minimal damage, and no major skeletal issues or tissue defects are present.



copyright by
not for publication
Quintessenz

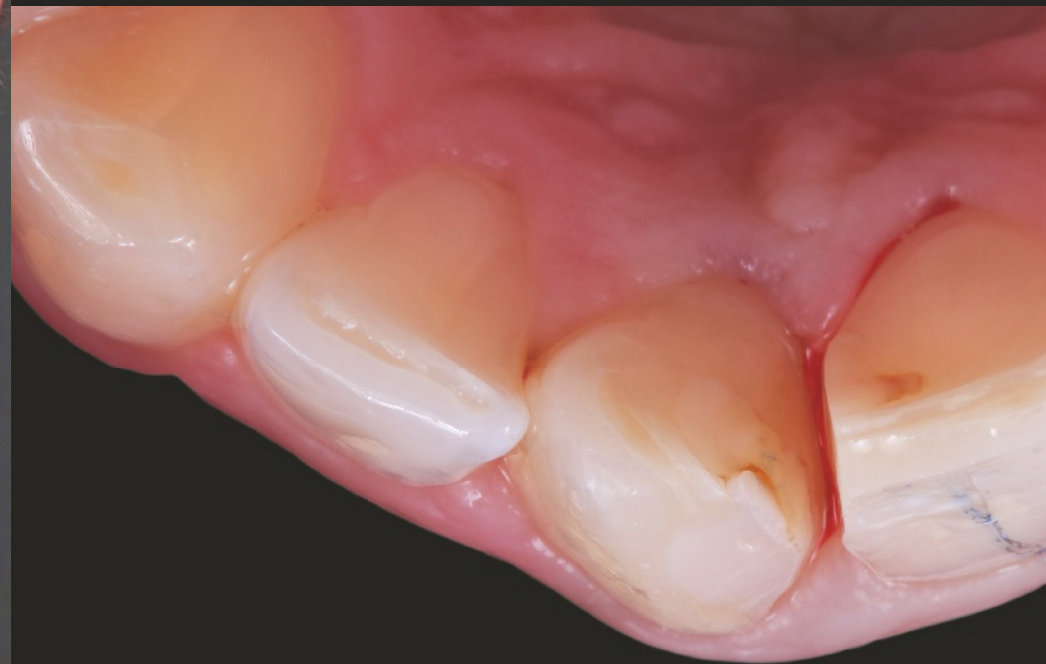
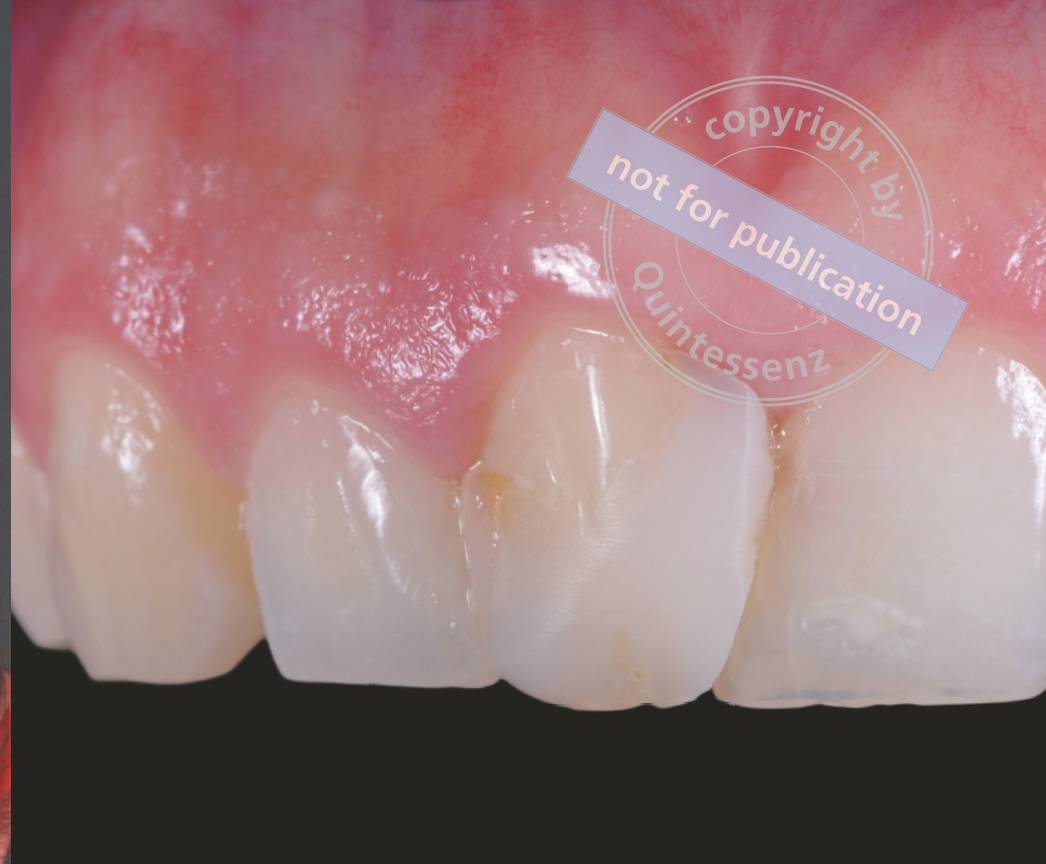
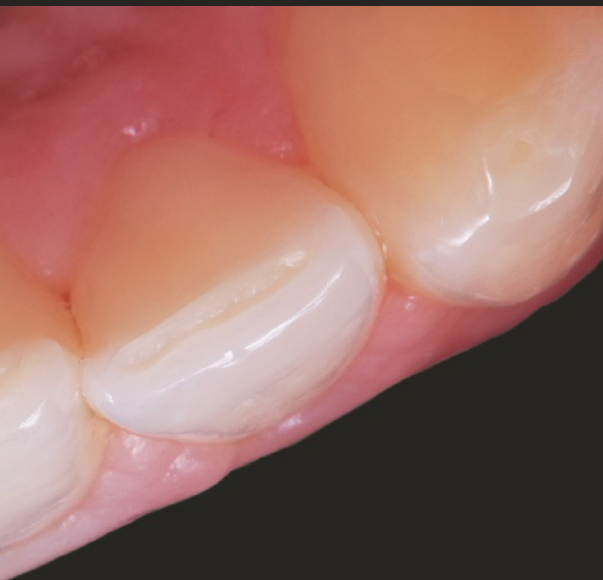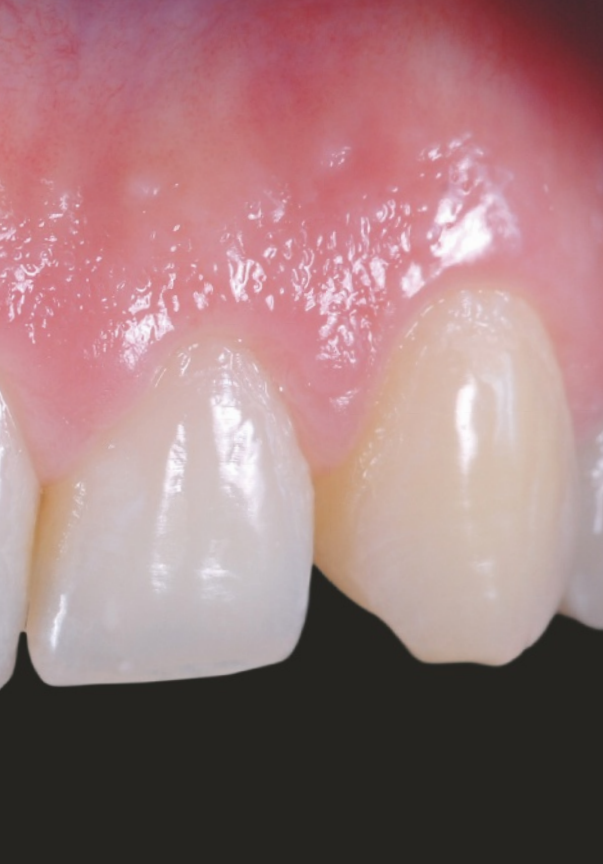Clinical situation 1

This 28-year-old patient consulted our practice with the aim of improving the aesthetics of her smile. She had undergone orthodontic treatment when she was very young, but it seems to have failed in all its objectives, and the patient is not at all happy with her aesthetic appearance.

The large crowding in the anterior teeth led her previous dentist to try to mask the problem with composites, but the result was even worse than the initial situation.

The majority of patients in this type of situation want a quick solution to their problems, because of the multiple treatments they have already undergone. In these cases, however, it's very difficult to solve the problem with a purely prosthetic approach, and it's often essential to resort to further orthodontic treatment to achieve the desired alignment. It is extremely interesting to understand the pragmatic and chronological approach to these complex situations.





Step one

Observe

Backgrounds

- 28-year-old female
- Previous dentist tried to solve the problem with composite restorations

Complaint

- Unhappy with esthetic appearance

Face



- Deviation of the midline
- Bilateral buccal corridor could be improved
- Crowding of anterior teeth with lack of restorative space

Smile

- Old composite restorations with marginal leakage
- Besides the composite restorations on the two central incisors, the patient has a virgin dentition
- Short interincisal papilla between the right and left central incisor because of lack of interdental space
- Root canal treatment on the right central incisor
- Convergent roots


Record

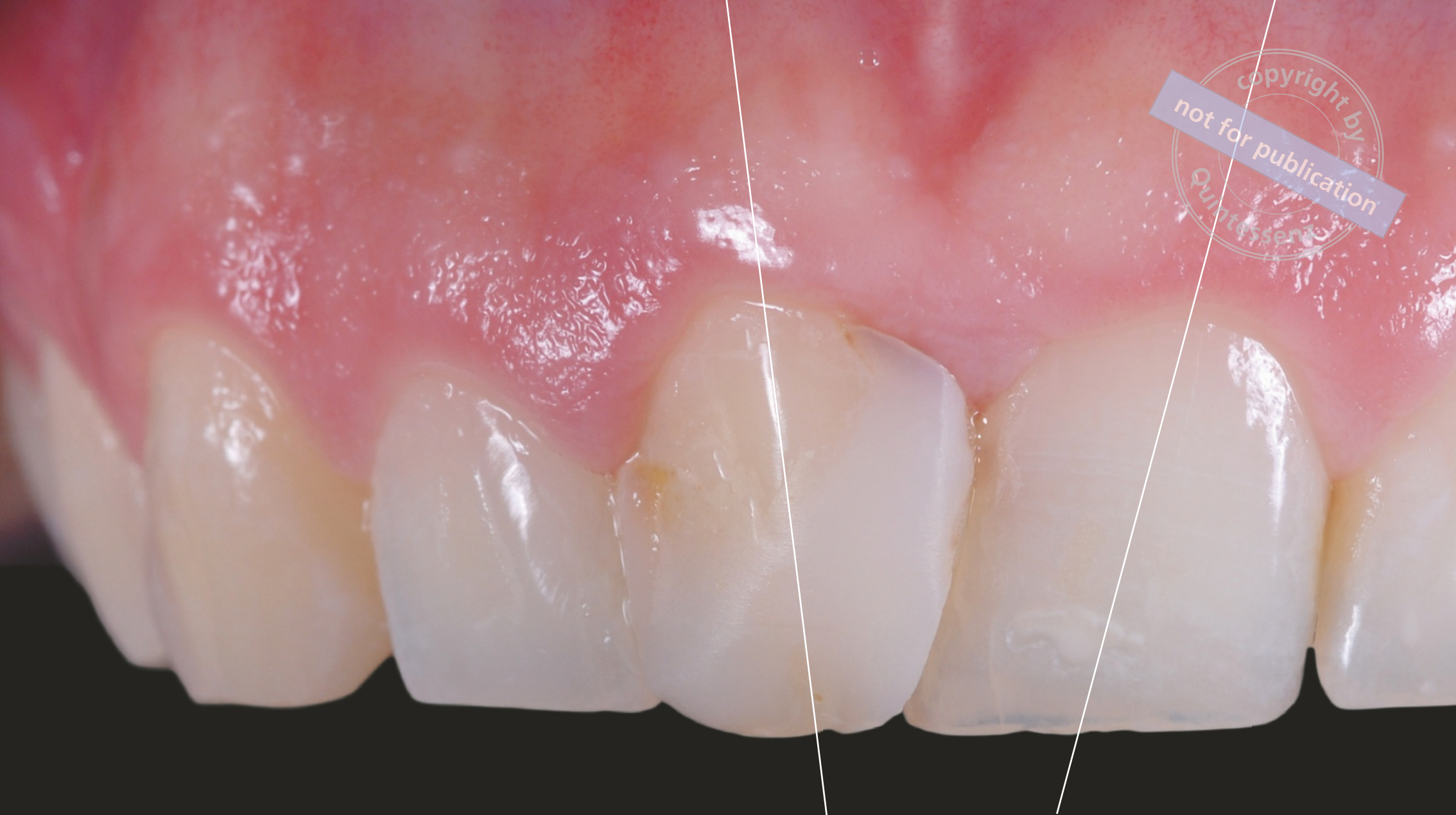Key elements for the development of the esthetic and functional treatment plan



1. Extraoral photographs

copyright by
not for publication
QuintessenZ





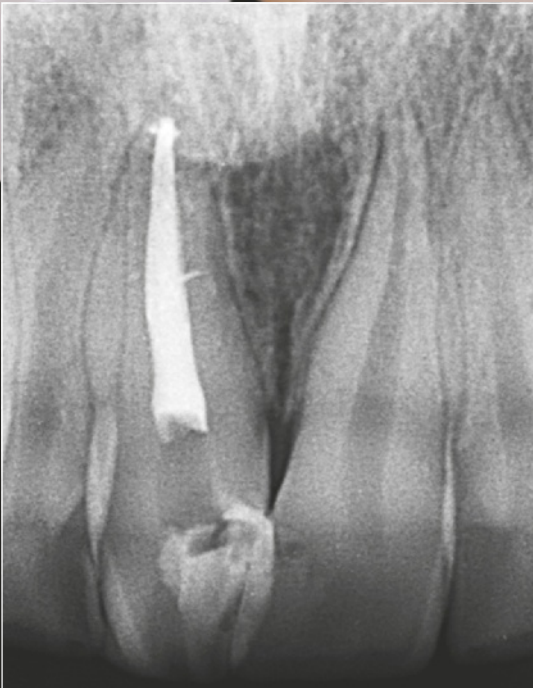Step one Record

2. Intraoral photograph

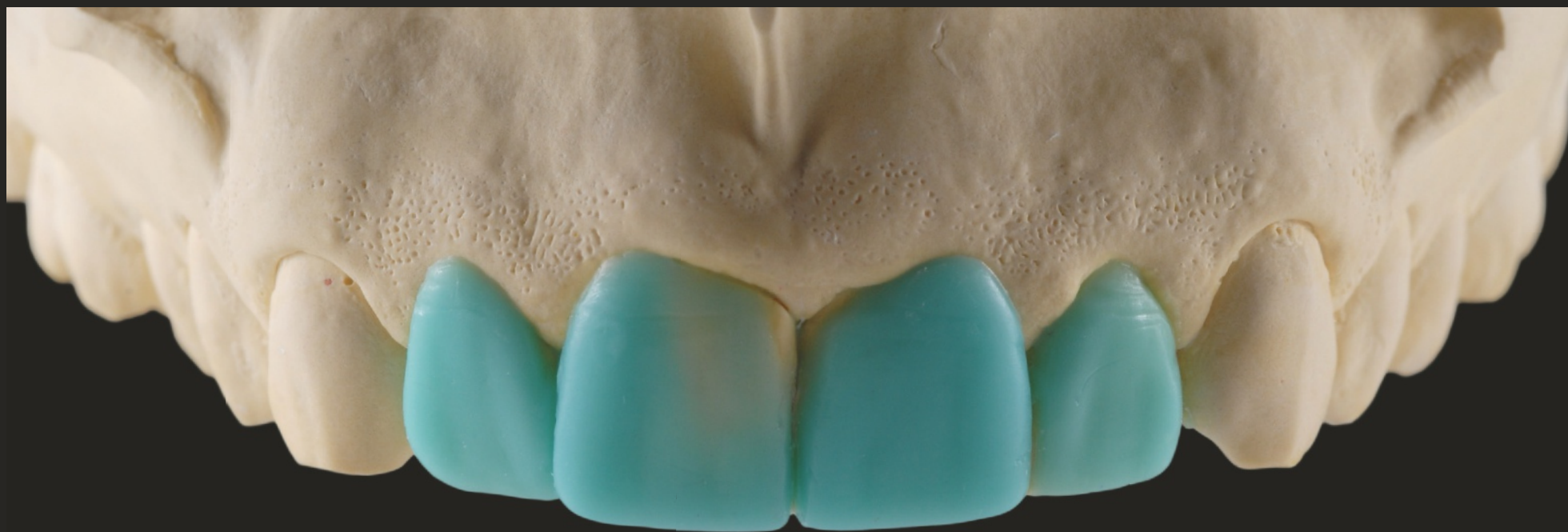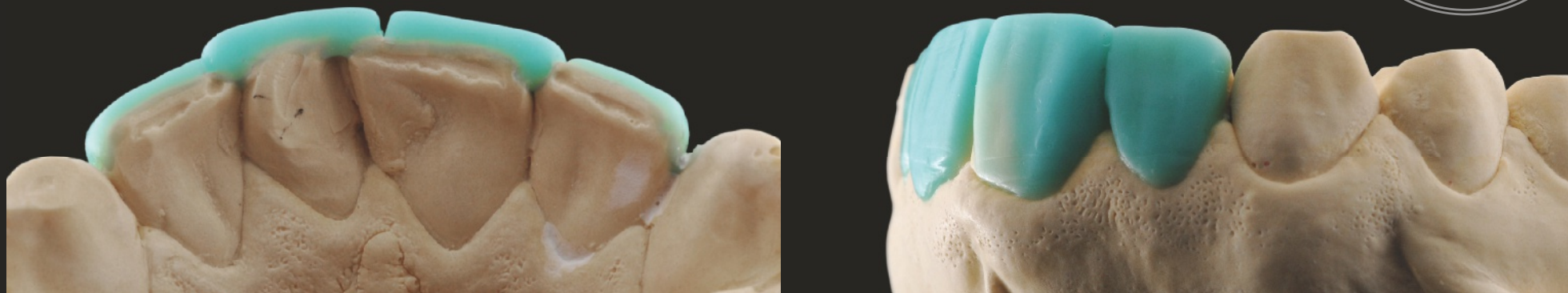
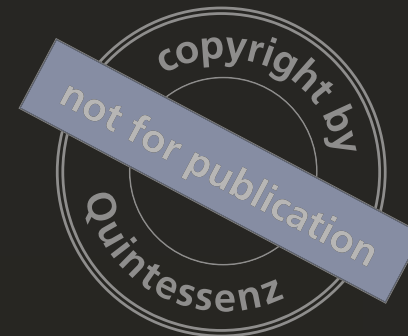- Frontal view perfectly centered to avoid any distortion
- Convergence of the centrals roots

3. Intraoral radiographs

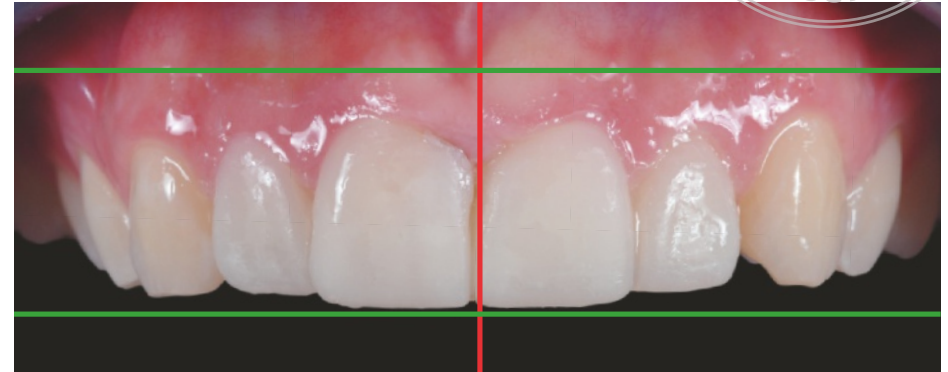

- Endodontic treatment on the right central incisor



4. Initial design



5. Facial references



“ A purely additive wax-up was made to obtain the patient’s consent and to validate the need for orthodontic treatment. The wax-up was designed according to the facial reference lines. Already on the palatal view on the model with the wax-up, it is clear that without orthodontics, it will be impossible to obtain a harmonious and acceptable esthetic result. The mock-up allows the patient to visualize the final design even before starting any treatment and will result in a comprehensive interdisciplinary treatment plan. ”

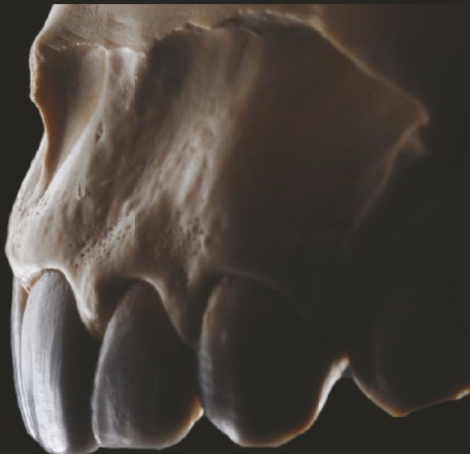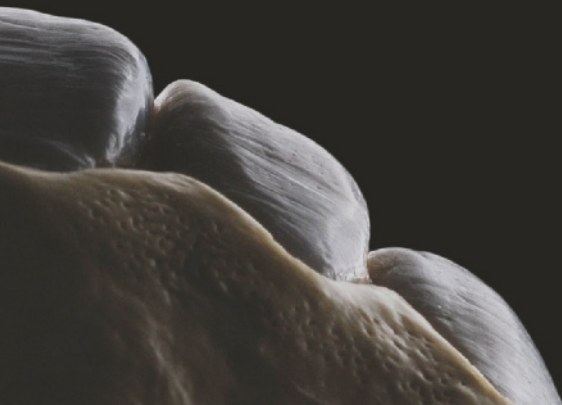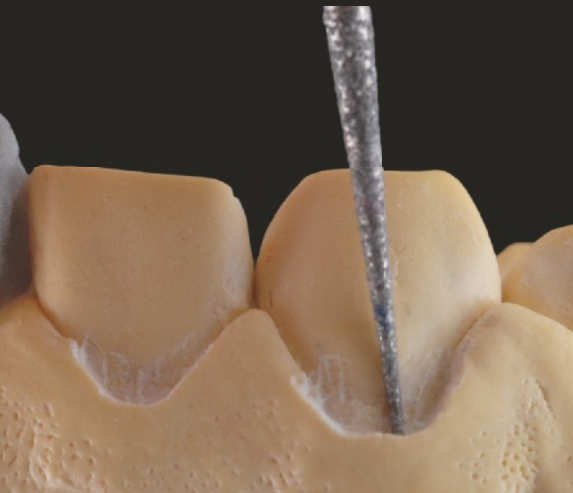


Step three

Building the final project

The changes resulting from the orthodontic treatment were obvious and the restorative space was improved. The need for flapless crown lengthening on the right lateral incisor and canine can easily be simulated. A gingival reduction on the plaster model will allow the dental technician to make the ideal wax-up.

The detail that was not optimized when finalizing the orthodontic treatment was the space between the roots of the two central incisors. We will need that space to allow the papilla height to improve.





“ In the framework of treatment in analog mode, the first visualization of the final design, which is a reactionary design, occurs at best 1 or 1.5 years after the beginning of the treatment. ”

Step three Mock-up

Visualize the project

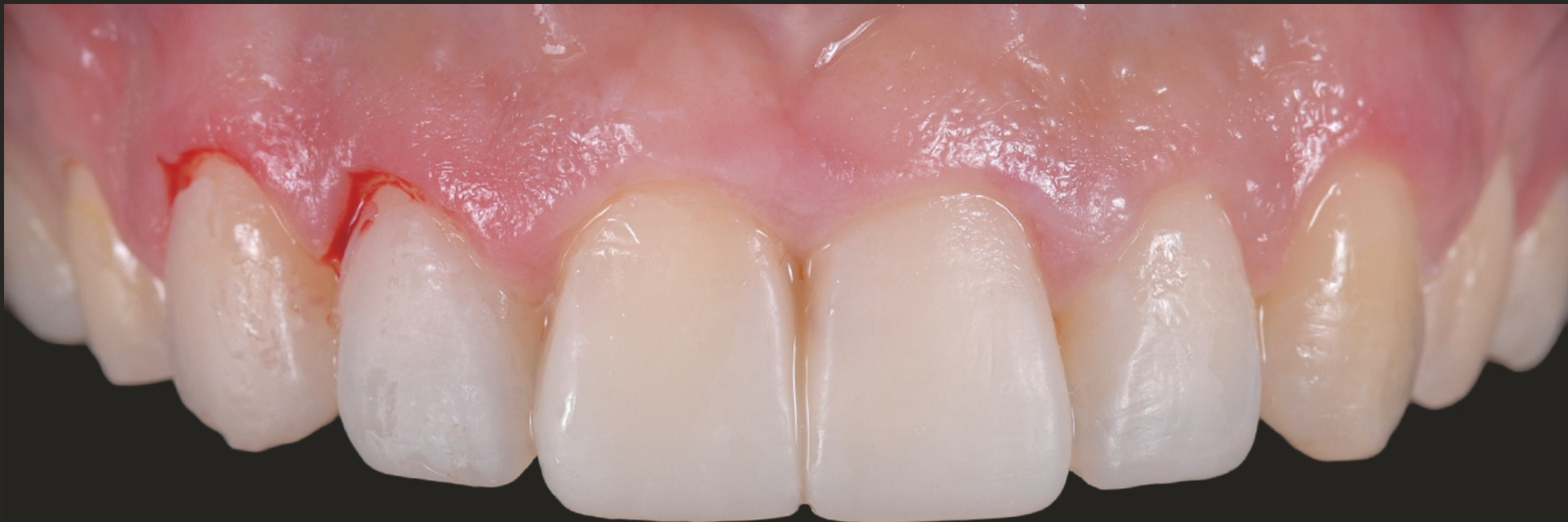Almost 1.5 years after the start of orthodontic treatment, the wax-up is transferred intraorally with a silicone key. This will allow us to visualize the final mock-up.

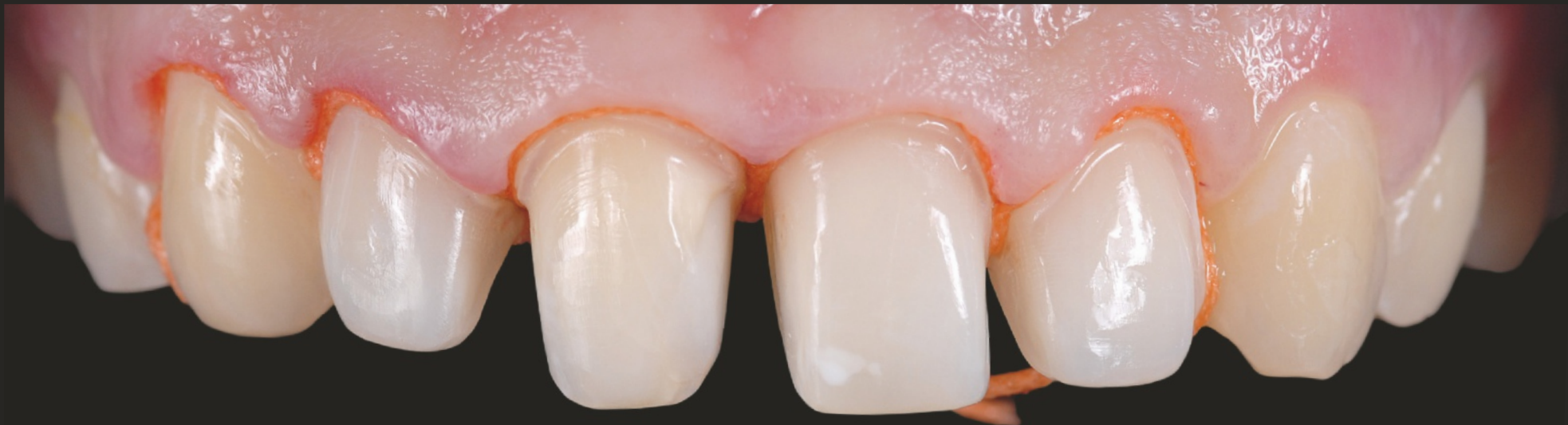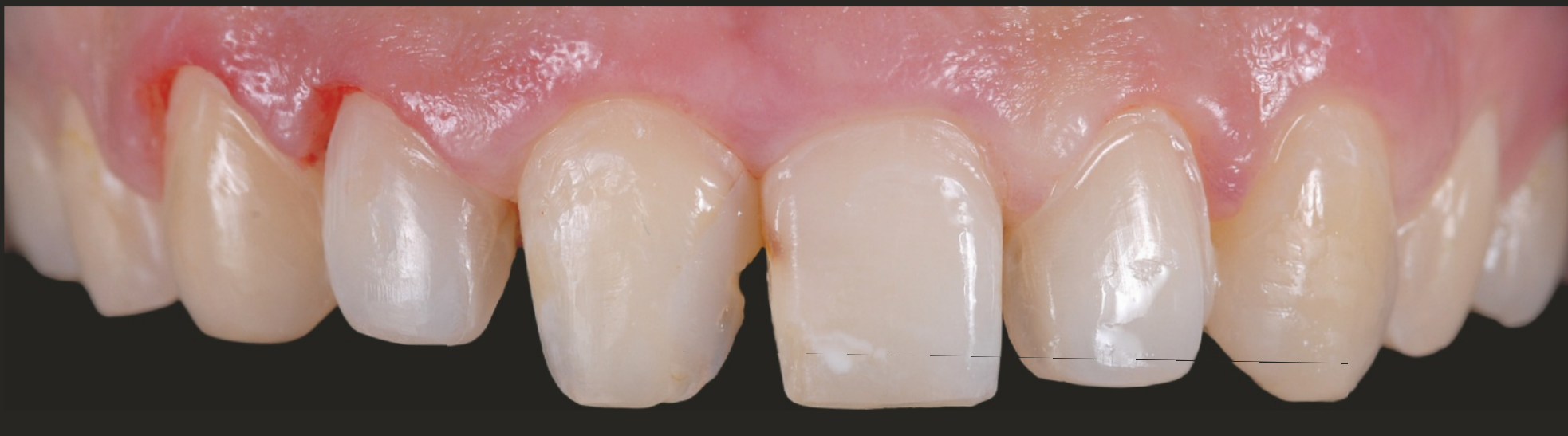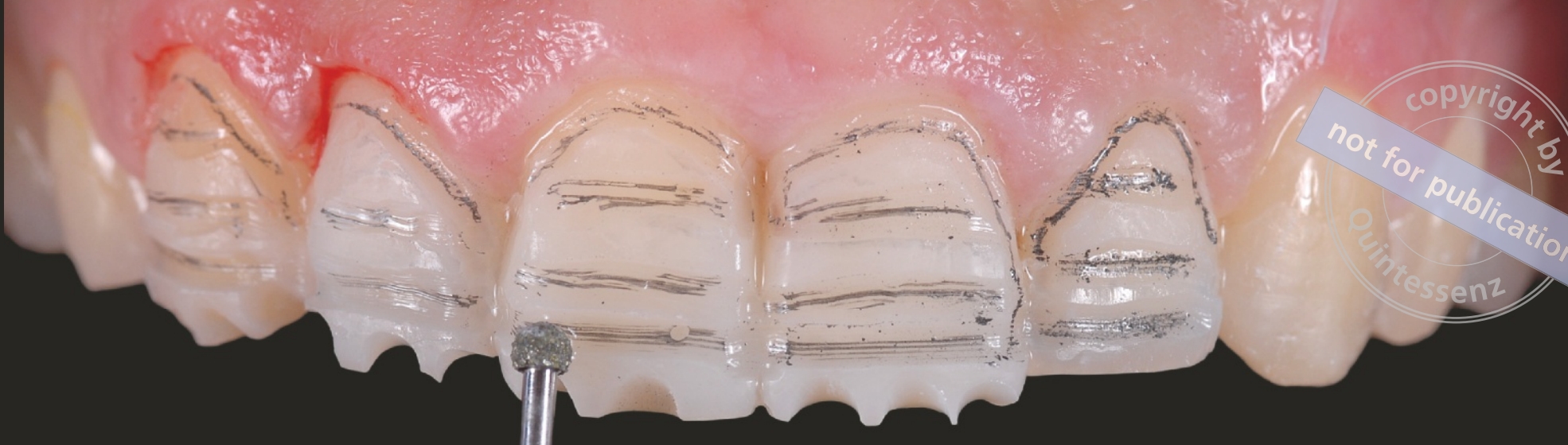
This mock-up can only be inserted precisely after minor flapless crown lengthening on the right canine and maxillary lateral incisor. Validation of the project was obtained

from the patient after comparing the face pictures. On the basis of this mock-up, it was decided not to touch the left maxillary canine. The treatment plan consists of two crowns on the central incisors, two veneers on the lateral incisors, and a partial veneer on the right central incisor.



copyright by
not for publication
Quintessenz



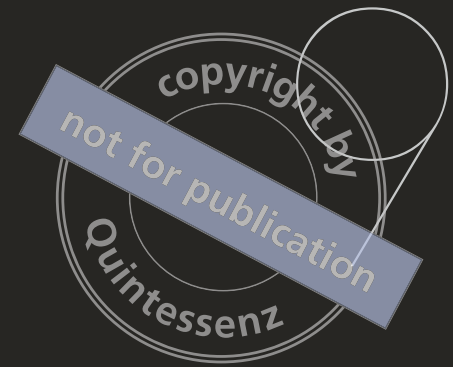
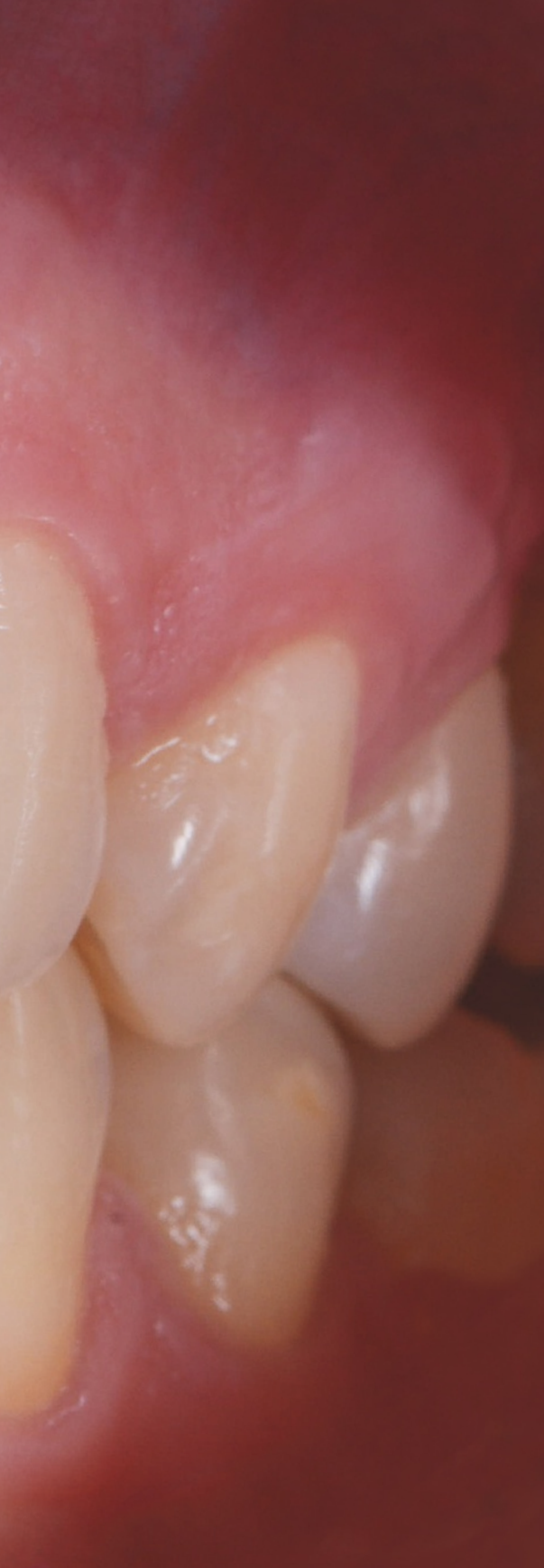
Step four

Final prosthetic rehabilitation

Final preparations are guided by the mock-up. Special attention is paid to the position of the prosthetic margins in relation to the marginal gingival levels determined by the mock-up, and must therefore take into account the crown lengthening procedure achieved on the right lateral incisor and canine. The initial preparation must follow the gingival contours and remain within 1mm of them. Once the retracting cords have been placed, the clinician must take care to follow his or her initial line and not the distortions

caused by the retracting cords. Space is created between the roots of the two central incisors at the cemento-enamel junction, and the level of proximal preparation is related to the height of the future interdental papilla. Probing the bone level at this point is crucial in determining the level of preparation. Regeneration of the interdental papilla will then be guided by the prosthetic design of the future crown and the height created between the prosthetic contact point and the interdental bone level.

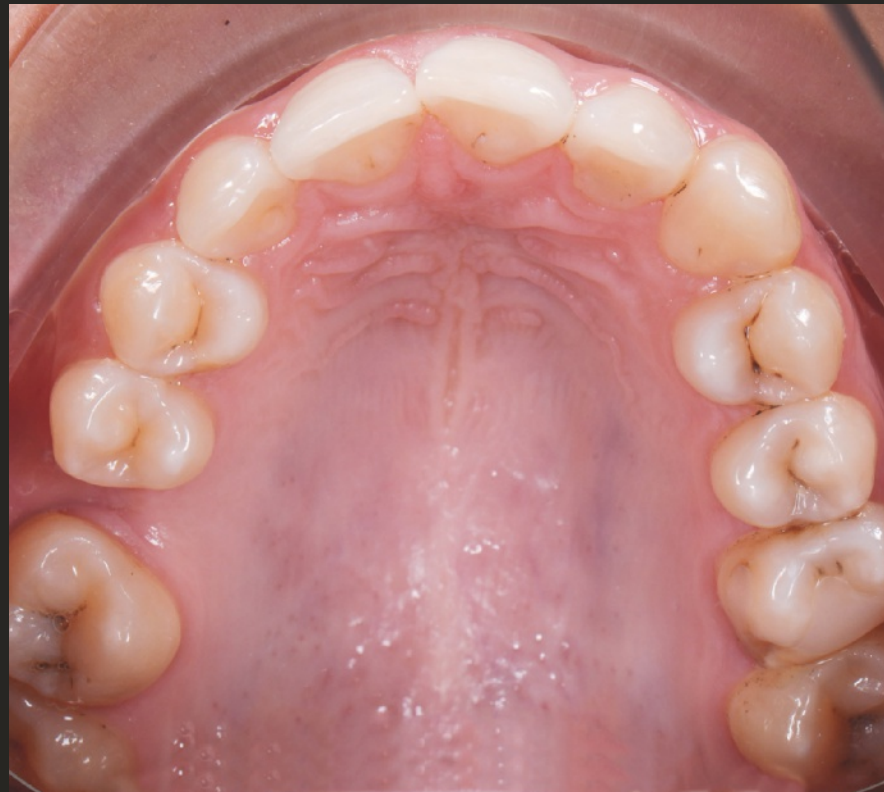
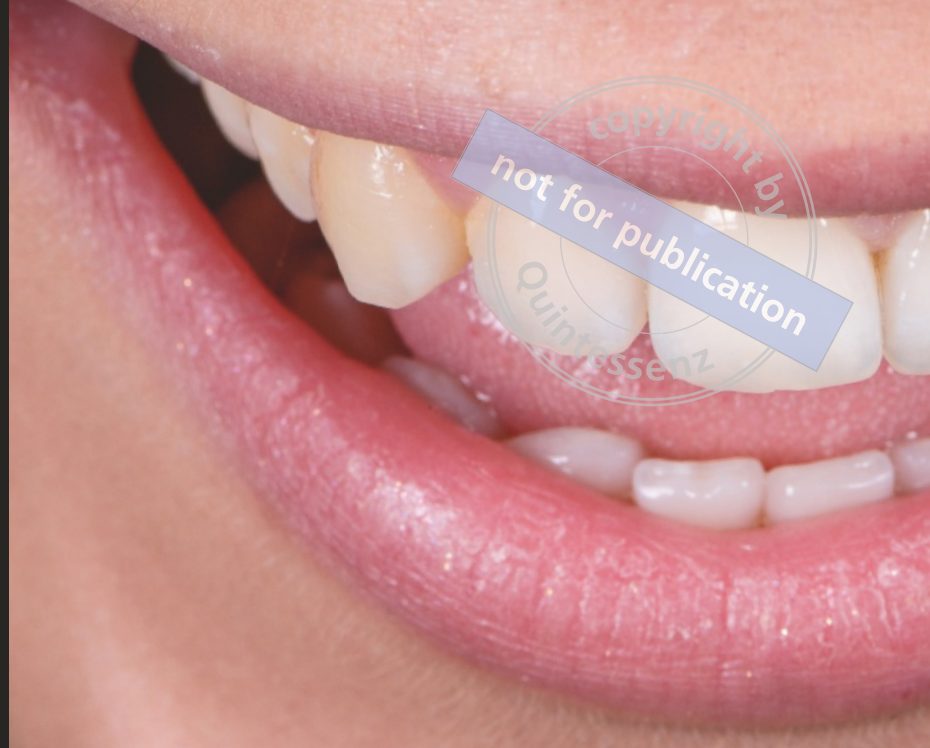
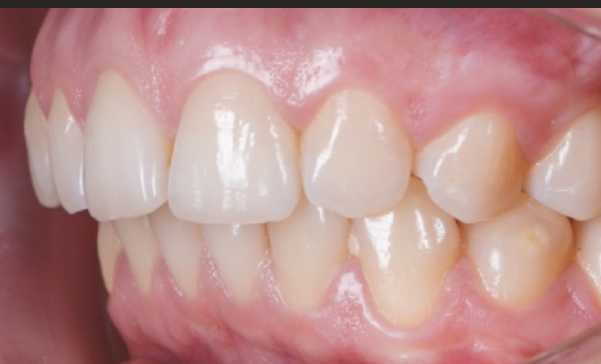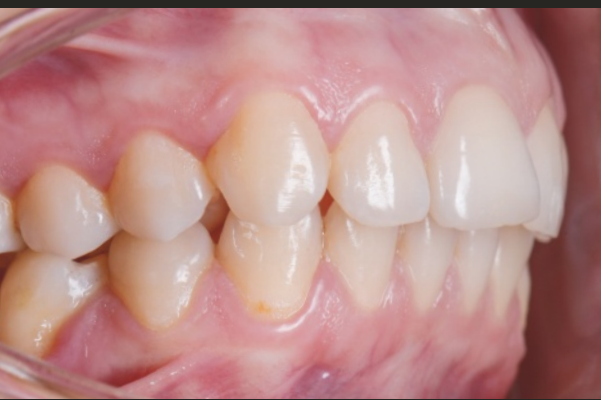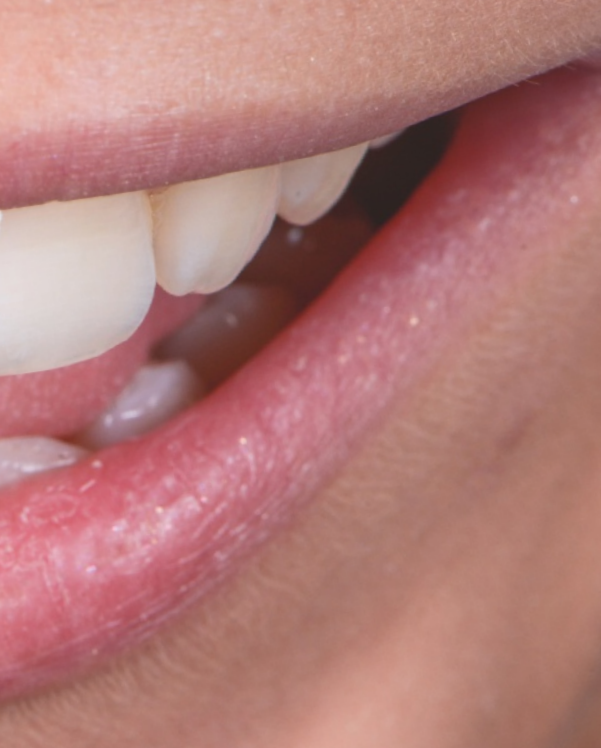Clinical situation 3



26-year-old female patient came to our practice for an esthetic consultation. She had a congenitally missing canine and a significant smile asymmetry. Her chief concern was to balance the appearance of her smile, if possible in a minimally invasive way, preserving her natural appearance.

A restorative treatment may seem like an alternative at first glance, but it is far from ideal, as it would not address the patient's main concern, namely the midline shift. In addition, it would violate her second concern, namely the minimally invasive nature of the procedure. In view of all the above, orthodontic treatment becomes mandatory to achieve the treatment objectives.





Step one

Observe

Backgrounds

- 26-year-old female
- Referred for veneers

Complaint

- Balance smile
- Minimally invasive treatment

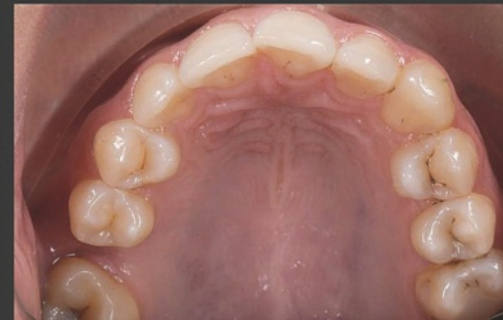
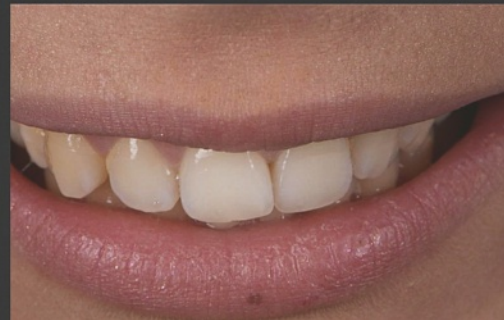
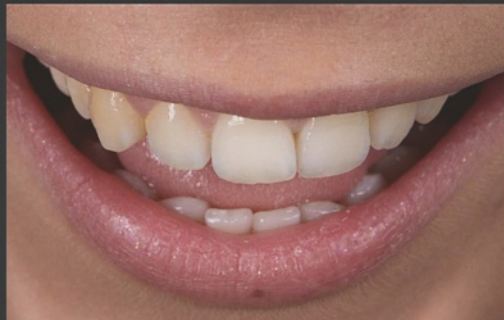
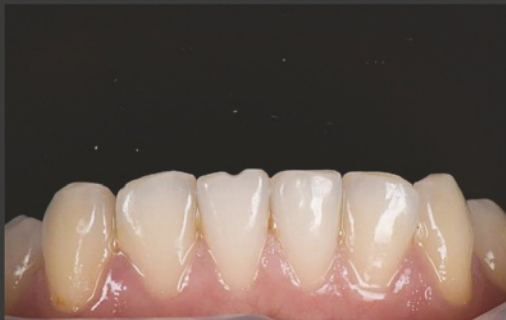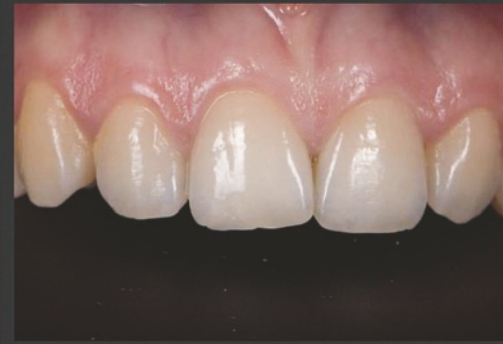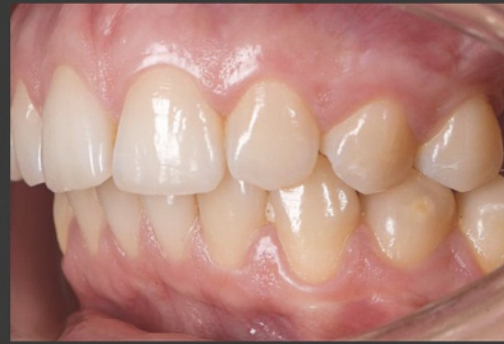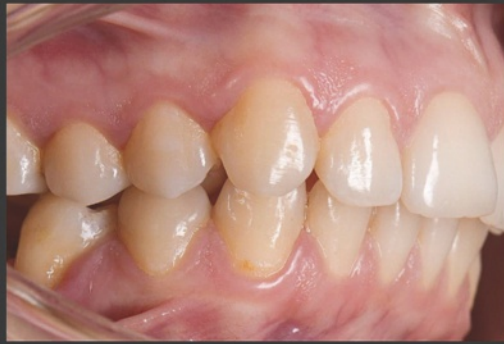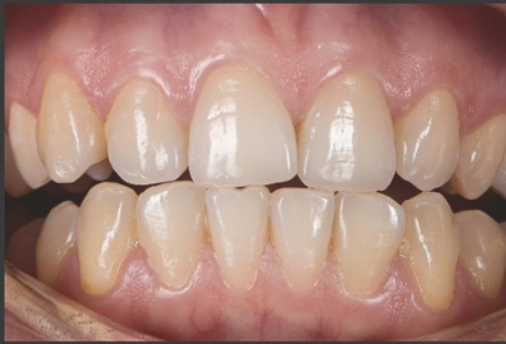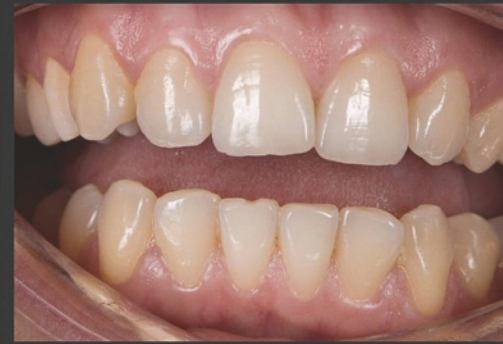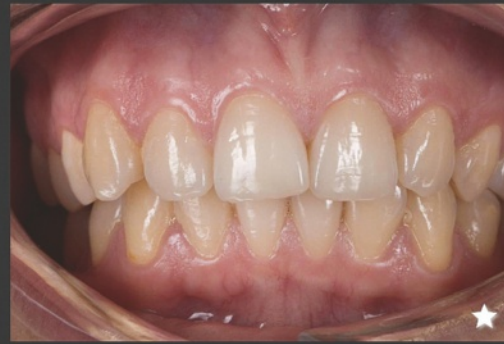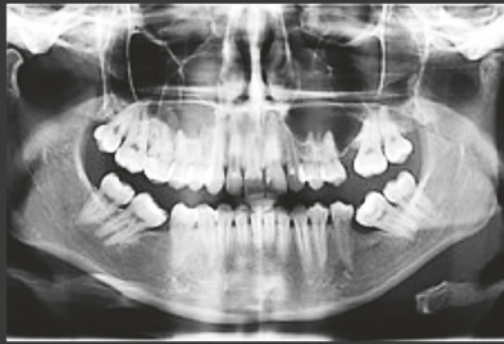Face

- Significant smile asymmetry
- Significant midline shift

Smile

- Periodontally healthy
- No functional pathology
- Congenital missing canine

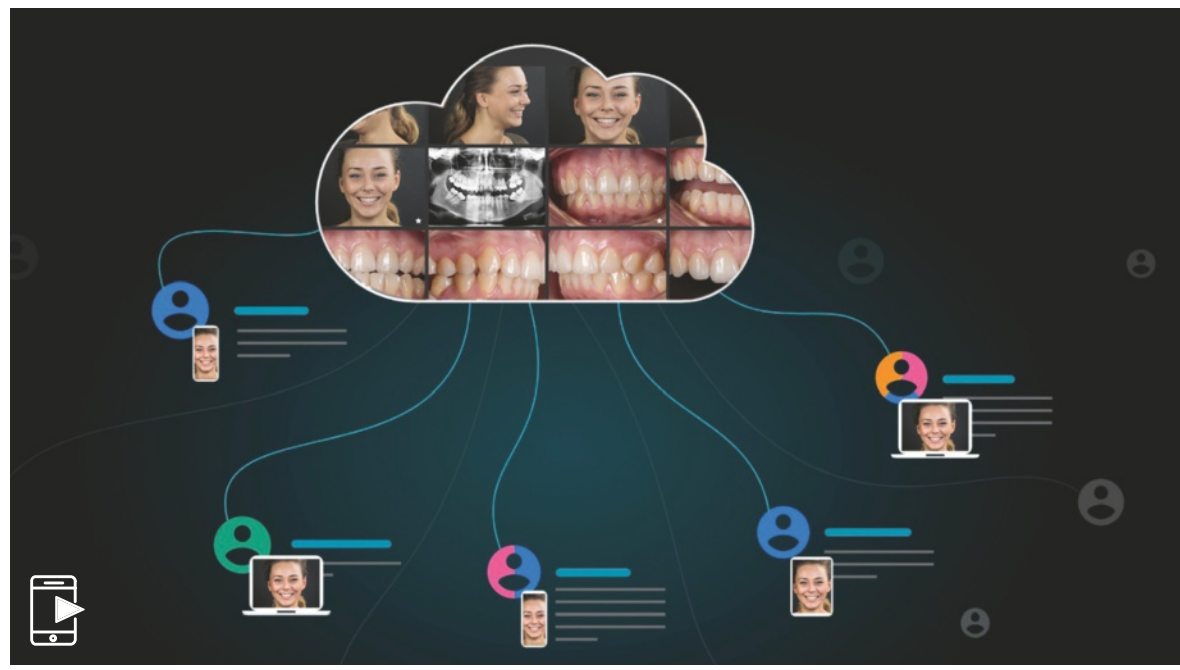copyright by
not for publication
Quintessenz





Step one Record

Standardized records are a prerequisite for interdisciplinary cases. Ideally, the records should include the standard information for all the specialties involved, which will create a common perspective of the problems between specialists, as well as saving the patient unnecessary trips. While using a centralized collaboration platform such as Smilecloud, access to data can be instantly granted to the people involved in treating the case.



Gallery Name	Date
final	2023-May-06
Untitled gallery	2023-May-06
Proba	2023-May-05
Untitled gallery	2023-May-03
pmma2	2023-Apr-07
pmma 1	2023-Apr-07
qdt edita	2023-Apr-06
graft video	2022-Oct-20
graft	2022-Oct-20
Untitled gallery	2022-Oct-18
scan 23	2022-Oct-18
re	2022-Oct-18
4k si pano	2020-Sep-18
Untitled gallery	2020-Jul-27

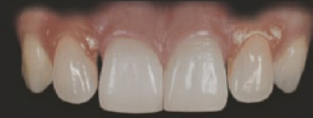
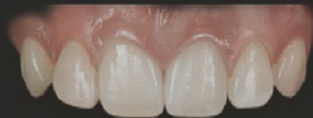
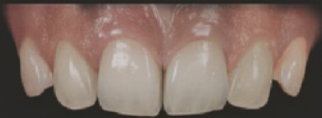
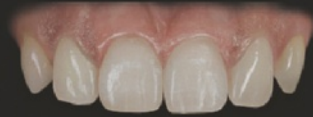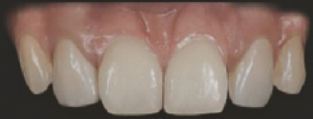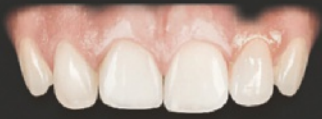Hialeah



Select Library

copyright by
not for publication
Quintessence



Step one Analyze

The scope of the smile design process in this case is to help the orthodontist plan the treatment according to the face. Smile design is equally relevant for orthodontic treatment as it is for prosthetic treatment, if not more relevant. In this scenario, the esthetic success of the treatment depends on correctly planning the relationship to the face. This is a perfect example of a class I interdisciplinary case, in which the orthodontist will focus on aligning the incised edges, as little to no restorative treatment is planned in this case.

