

Modified treatment procedure for prosthetic rehabilitation of tumor patients

Language: English

Authors:

Dr. Susanne Heberer, Dr. Katja Nelson
Dept. of Oral and Maxillofacial Surgery, Charité-Campus Virchow Clinic, Berlin

Date/Event/Venue:

05.10.-07.10.2007
Annual Meeting of the European Association of Osseointegration
Zürich

Introduction

The resection of oral cancer can result in pronounced functional interferences; do to disfigurements of the hard and soft tissue. Oral rehabilitation often requires the use of dental implants, which has been a well established treatment with adequate survival rates. The long-term success of osseointegrated implants is influenced by the situation of the peri-implant soft tissue. After reconstruction of large tissue defects attached keratinized mucosa is missing (Fig 1).

Material and Methods

Between October 2004 and July 2006, 10 patients (3 female, 7 male) were treated at the Dept. of Oral & Maxillofacial Surgery, Berlin. In all patients, a malignant tumor from the floor of the mouth was surgically removed between 21 and 110 months before implantation (mean = 47.6 months) and 41 implants (36 = Camlog Rootline, Camlog Biotechnologies; 5 = TiUnite, Nobel Biocare) were placed in the mandible. Eight of these patients were edentulous and 2 patients were partially edentulous. The mean age of the patients was 64.8 years (52-86 years) and the average observation period was 19.2 months (18-22 months). Procedure I At the time of implant placement transfer copings were seated and an impression taken using alginate (Fig2). The impression was basis for plaster model on which an individually manufactured, implant-retained splint was fabricated, after the modification of the soft and hard tissue base in the plaster model (Fig 3+4). Procedure II After a two months healing period second stage surgery was performed in combination with a vestibuloplasty, proceeding as followed: mucosal incision on the alveolar process is made to expose the implants (Fig 5), with the periosteum remaining unaffected. The mucosal flap is reflected lingually and buccally, being careful to avoid the mental nerve. After sufficient mobilisation of the tongue and an adequately deepened vestibulum the flap is sutured to the periosteum in the depth of the lingual and buccal sulcus, followed by a 0.4 mm split-thickness skin graft harvested from the upper thigh with an electric dermatome. The graft was secured with 5-0 resorbable sutures and perforated at the position of the implants. The splint was screwed to the implants to allow pressure on the graft. In order to activate the pressure the surgical splint was relined with Peripac (Dentsply) or Soft Liner (GC) (Fig 6). The splint serves as a space holder until the suprastructure is placed (Fig 7).

Results

No intraoperative and postoperative complications such as wound infections occurred. All transplants were incorporated and epithelialized. All inserted implants have been osseointegrated and were used for implant supported overdentures. The mean pocket depths measured postoperatively at 6, 12 and 18 months was 2.25mm (Tab1, Fig 8).

postoperatively		After 6 month		After 12 month		After 18 month	
mesial	distal	mesial	distal	mesial	distal	mesial	distal
2.39	2.09	2.39	2.04	2.46	2.12	2.29	2.24

Table 1: Mean Pocket depth in mm

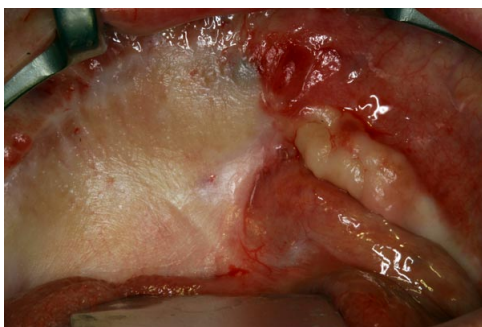

Fig. 1: Situation preoperatively often presenting non-attached tissue placed after tumor removal

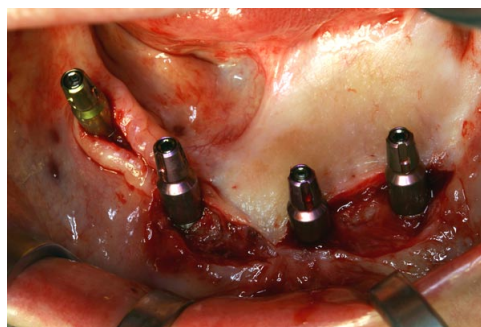


Fig. 2: At the time of implant placement transfer copings are placed for alginate impression

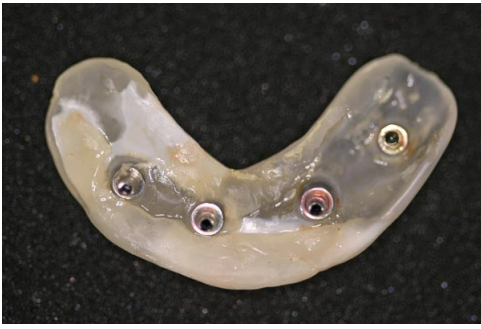

Fig. 3: Implant retained- splint

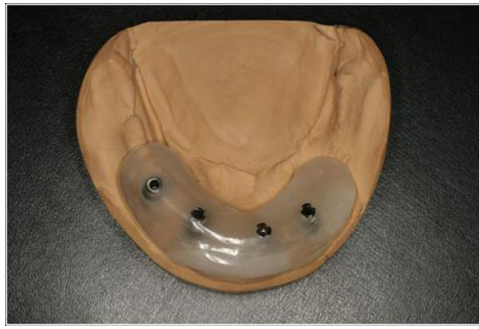

Fig. 4: Modified the plaster model

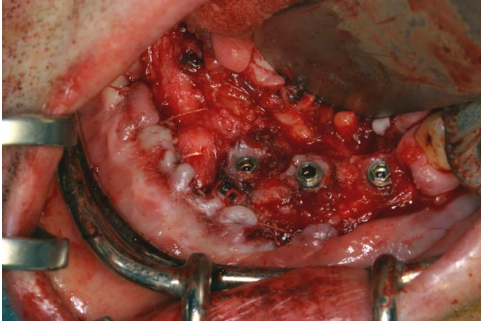


Fig. 5: Exposure of the implants and preparation of mucosal flap

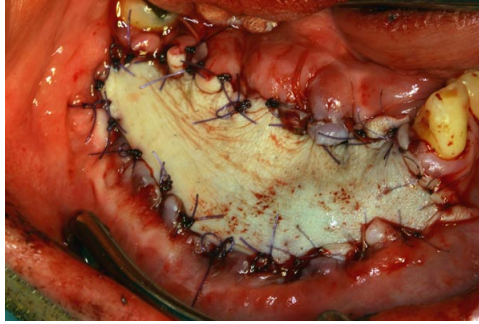


Fig. 6: Split- thickness skin graft from the upper thigh in situ

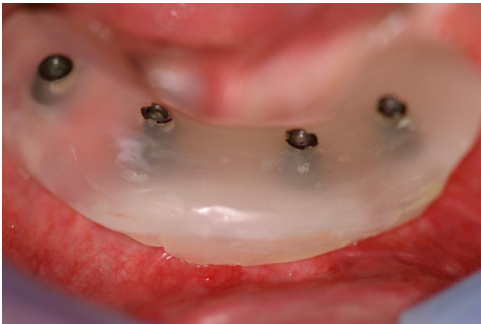

Fig. 7: The surgical splint after 4 weeks

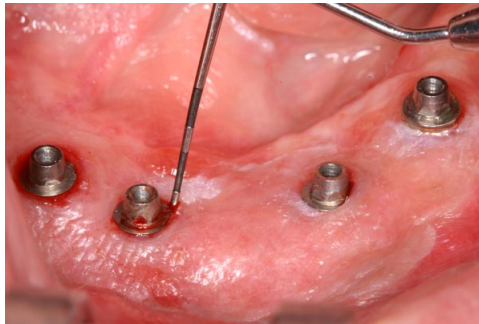


Fig. 8: Measurement of pocket depth one year postoperatively

Conclusions

After insertion of the suprastructure all patients show an improvement in speech, deglutition and oral competence. Oral hygiene can be performed easier and soft tissue inflammation as well as periimplantitis was prevented. This procedure offers a safe and convenient method to maintain the achieved mobility of the tongue and the sufficient basis for prosthetic management with minimal shrinkage.

This Poster was submitted by [Dr.Susanne Heberer](#).

Correspondence address:

[Dr.Susanne Heberer](#)

Dept. of Oral and Maxillofacial Surgery

Charité- Campus Virchow

Augustenburger Platz 1

13353 Berlin

Germany

Modified treatment procedure for prosthetic rehabilitation of tumor patients

Heberer S, Nelson K

Clinic for Oral and Maxillofacial Surgery, Clinical Navigation and Rototics

Charité - Universitätsmedizin Berlin, Campus Virchow-Klinikum, Augustenburger Platz 1, 13353 Berlin, Germany; Susanne.Heberer@charite.de

Introduction

The resection of oral cancer can result in pronounced functional interferences; do to disfigurements of the hard and soft tissue. Oral rehabilitation often requires the use of dental implants, which has been a well established treatment with adequate survival rates. The long-term success of osseointegrated implants is influenced by the situation of the peri-implant soft tissue. After reconstruction of large tissue defects attached keratinized mucosa is missing (Fig 1).

Material and methods

Between October 2004 and July 2006, 10 patients (3 female, 7 male) were treated at the Dept. of Oral & Maxillofacial Surgery, Berlin. In all patients, a malignant tumor from the floor of the mouth was surgically removed between 21 and 110 months before implantation (mean = 47.6 months) and 41 implants (36 = Camlog Rootline, Camlog Biotechnologies; 5 = Tisite, Nobel Biocare) were placed in the mandible (Fig 2). Eight of these patients were edentulous and 2 patients were partially edentulous. The mean age of the patients was 64.8 years (52-86 years) and the average observation period was 19.2 months (18-22 months).

Procedure I

At the time of implant placement transfer copings were seated and an impression taken using alginate (Fig 2). The impression was basis for a plaster model on which an individual implant-retained splint was fabricated, after the modification of the soft and hard tissue base in the plaster model (Fig 3+4).

Procedure II

After a two months healing period second stage surgery was performed in combination with a vestibuloplasty, proceeding as followed: mucosal incision on the alveolar process is made to expose the implants (Fig 5), with the periosteum remaining unaffected. The mucosal flap is reflected lingually and buccally, being careful to avoid the mental nerve. After sufficient mobilisation of the tongue and an adequately deepened vestibulum the flap is sutured to the periosteum in the depth of the lingual and buccal sulcus. Followed by a 0.4 mm split-thickness skin graft harvested from the upper thigh with an electric dermatome. The graft was secured with 5-0 resorbable sutures and perforated at the position of the implants (Fig 6). The splint was screwed to the implants to allow pressure on the graft. In order to activate the pressure the surgical splint was relined with Peripac (Dentsply) or Soft Liner (GC). The splint serves as a space holder until the suprastructure is placed (Fig 7).

Results

No intraoperative and postoperative complications such as wound infections occurred. All transplants were incorporated and epithelialized. All inserted implants have been osseointegrated and were used for implant supported overdentures. The mean pocket depths measured postoperatively at 6, 12 and 18 months was 2.25 mm (Fig 8).

Conclusion

After insertion of the suprastructure all patients show an improvement in speech, deglutition and oral competence. Oral hygiene can be performed easier and soft tissue inflammation as well as periimplantitis was prevented. This procedure offers a safe and convenient method to maintain the achieved mobility of the tongue and the sufficient basis for prosthetic management with minimal shrinkage.

Tab 1 Mean Pocket depth in mm

postoperatively		After 6 month		After 12 month		After 18 month	
mesial	distal	mesial	distal	mesial	distal	mesial	distal
2.39	2.09	2.39	2.04	2.46	2.12	2.29	2.24

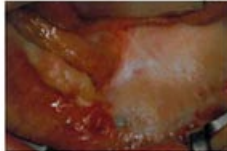

Fig 1 Situation preoperatively often presenting non-attached tissue placed after tumor removal.

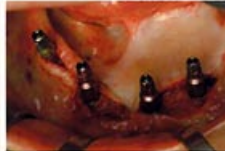

Fig 2 At the time of implant placement transfer copings are placed for alginate impression.

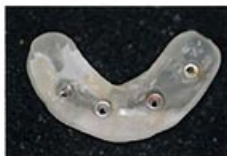

Fig 3 Implant-retained splint



Fig 4 Modified the plaster model

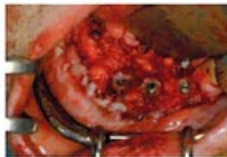

Fig 5 Exposure of the implants and preparation of mucosal flap.

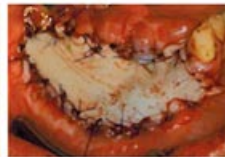

Fig 6 Split-thickness skin graft from the upper thigh in situ

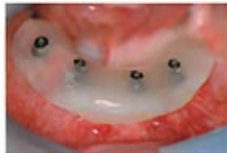

Fig 7 The surgical splint after 4 weeks.

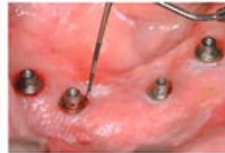

Fig 8 Measurement of pocket depths one year postoperatively.