

Early Dental Treatments for Patients with Cleidocranial Dysplasia

Chen Ying ZHANG^{1*}, Yan SI^{1*}, Xiao Zhe WANG¹, Xiang Yu SUN¹, Wen Juan YAN², Shu Guo ZHENG¹

Objective: To explore the early dental interventional strategies for adolescent patients and a child patient with cleidocranial dysplasia (CCD).

Methods: Surgical exposure using the apically repositioned flap technique combined with orthodontic traction was used in the adolescent patients whose ideal treatment time for initiating treatment was missed. For the child patient whose ideal treatment time for initiating treatment was not missed, the simple surgical exposure method was carried out in order to promote the eruption of the impacted incisors.

Results: All the impacted maxillary incisors of the three CCD patients were successfully positioned into a proper alignment either through the two stages of crown exposure and the elastic traction or simple surgical exposure.

Conclusion: Crown exposure surgery combined with light force orthodontic traction provides an effective approach to treat the typical dental abnormalities of adolescent CCD patients. Simple surgical exposure was also an effective way for a child CCD patient for whom the most ideal time for initiation of treatment was not missed.

Key words: cleidocranial dysplasia, dental treatment, orthodontic treatment

Cleidocranial dysplasia (CCD; MIM 119600) is a rare autosomal dominant skeletal disorder that is characterised by delayed closure of the cranial sutures, hypoplastic or aplastic clavicles and the presence of multiple dental abnormalities¹. Clavicular hypoplasia results in narrow, sloping shoulders that can be apposed at the midline. The fontanelles are usually wide-open at birth

and may remain open throughout life. The main oral manifestations include delayed exfoliation of primary teeth, delayed or failing eruption of the permanent dentition, multiple supernumerary teeth and malocclusion². A variety of other skeletal abnormalities are also found amongst patients such as short stature, hand abnormalities, wide pubic symphysis and so on³.

CCD is inherited in an autosomal dominant way with complete penetrance and variable expressivity. The condition is caused by mutations in the runt-related transcription factor-2 gene (RUNX2, also known as CBFA1, PEBP2aA and AML3), located on chromosome 6p21^{4,5}. The RUNX2 gene controls the differentiation of precursor cells into osteoblasts and is therefore essential for membranous as well as endochondral bone formation, which may be related to delayed ossification of the skull, clavicles, pelvis and teeth⁶.

Despite numerous skeletal deficiencies, the major concern of patients is most often the oral/dental disorder which significantly leads to a poor quality of life. The

1 Department of Preventive Dentistry, Peking University School and Hospital of Stomatology Beijing, P.R. China.

2 Outpatient Center, Peking University School and Hospital of Stomatology, Beijing, P.R. China.

* The first two authors contributed equally to this article.

Corresponding author: Shuguo Zheng, Department of Preventive Dentistry, Peking University School and Hospital of Stomatology, #22 Zhongguancun Nandajie, Haidian District, Beijing 100081, P.R. China. Tel: 86-10-82195510; Fax: 86-10-62173404. Email: zhengsg86@gmail.com

This work was supported by a grant from National Natural Science Foundation of China (81070815).

Table 1 The clinical features of the three CCD patients.

Case	Family history	Sex ^a (F/M)	Age (years)	Patent fontanelles	Hypoplastic clavicles ^b	Dental anomalies ^c	RUNX2 Mutation
1	-	F	16	+	+	++	T200I
2	-	M	15	+	+	++	214fs
3	+	M	10	+	+	++	172fs

^a F: female; M: male.

^b +: hypoplastic clavicles; ++: aplastic clavicles.

^c ++: supernumerary teeth and delayed eruption of permanent teeth.

early diagnosis is of vital importance for the successful treatment of CCD. However, there are many difficulties in the early diagnosis of CCD as a result of the genetic and developmental characteristics of the disorder. Approximately one third of the cases are sporadic and have unaffected parents^{1,7}. Furthermore, the most typical CCD marker which causes extreme shoulder mobility, is not always expressed and the majority of craniofacial findings are age related and become obvious only during adolescence¹. Consequently, the most favorable treatment time which is limited by root development and bone quantity is frequently missed in most of the patients. So the treatment strategies may be different according to the age of the patients.

In this article, different early intervention strategies for the dental abnormalities of CCD patients were presented based on their age and intervention time.

Materials and methods

Patients

Three patients with similar phenotypes came to the Department of Preventive Dentistry, Peking University School and Hospital of Stomatology in order to treat their dental anomalies. Their primary issue was the failure of eruption of the upper permanent incisors. The basic information and clinical features of the three patients are shown in Table 1. All of the patients were diagnosed based on the clinical findings and molecular analysis for RUNX2 gene. Three different RUNX2 gene mutations were detected from the three CCD patients in our previous study and this confirmed the clinical diagnosis⁸.

Early intervention strategies for adolescent patients

The patients in case 1 and case 2 were both 15 years old. The appearance and mastication function of the two adolescent patients were seriously impaired as a result of the unerupted maxillary permanent incisors. Both of them had a strong desire to make their maxillary incisors erupt as soon as possible, whereby the optimal treatment time for CCD had been missed when the root development of their teeth should be two thirds of expected length of the impacted permanent incisors. Therefore, our overall treatment strategy for the patients involved timely extraction of deciduous teeth, the staged surgical removal of supernumerary teeth, the exposure of selected unerupted permanent teeth and orthodontic forced eruption. The treatment plan and objectives were explained to the patients and their guardians; and their consent was obtained.

Case 1

Case 1 was a sporadic case in which the patient had all the typical features of CCD including hypoplastic clavicle, craniofacial and dental abnormalities (Fig 1). A concave profile due to maxillary hypoplasia was noted (Fig 1a). The patent cranial sutures and frontal bossing were indicated in the lateral cephalometric radiograph (Fig 1b). The clavicles of both sides were hypoplastic and a cone-shaped thorax with narrow upper thoracic diameter was also identified in the chest radiograph (Fig 1c). There were five supernumerary teeth in total in the maxillary and mandibular anterior area; and the roots of some permanent teeth were curved as shown in the panoramic radiograph (Fig 1d). The maxillary arch was constricted and both anterior and posterior crossbite

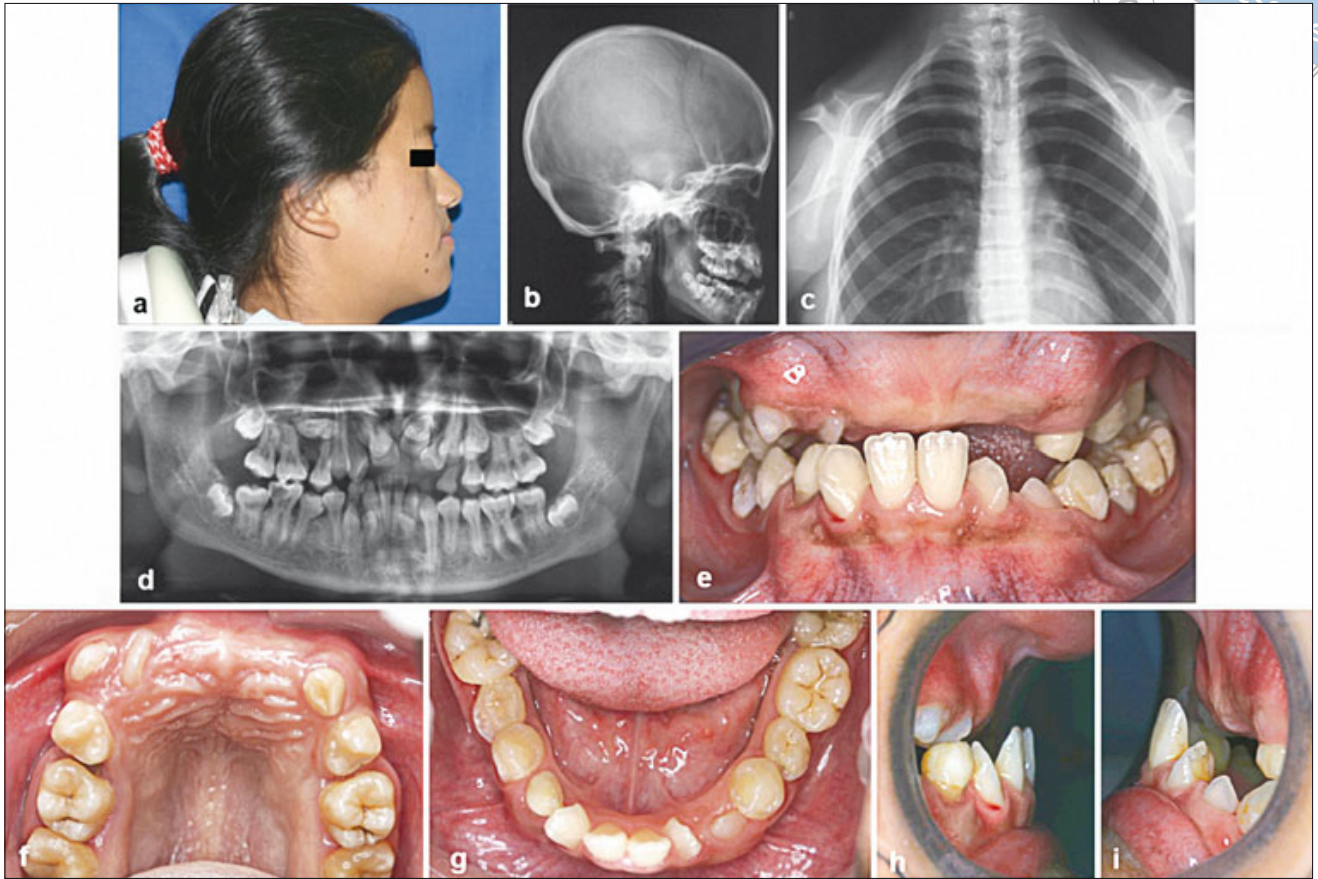


Fig 1 Clinical and radiographic findings in case 1: a) profile photograph pre-treatment; b) lateral cephalometric radiograph; c) chest radiograph; d) panoramic radiograph pre-treatment; e to i) intraoral photographs pre-treatment demonstrate the dental condition.

were present (Fig 1e). Two primary maxillary canines were still retained in the mouth and numerous permanent teeth were unerupted though this patient was only 16 years old (Figs 1f and 1g). Severe class III malocclusion was more obvious from intraoral lateral photographs (Figs 1h and 1i).

By using local anesthesia, a full mucoperiosteal flap was raised. The crowns of the maxillary central incisors and left lateral incisor; and supernumerary teeth were exposed after removal of the bone covering the unerupted teeth. The morphology of the three incisor crowns was normal with no enamel defects. In order to avoid the contamination of blood resulting from extraction, brackets were bonded to the labial surface of the impacted incisors before removal of the supernumerary teeth (Fig 2a). After removal of the supernumerary teeth, elastomeric power chains were placed on the brackets. Then using closed eruption technique, the gingival flap

was repositioned and sutured back in such a way that the bracketed crown was not exposed to the oral cavity, leaving the elastomeric power chains protruding through the mucosa. A removable traction apparatus with traction hooks, which were fabricated pre-operation, was used to guide the impacted incisors into the correct position in the mouth (Fig 2b). Orthodontic traction was initiated on the same day with a light orthodontic force of about 60 to 90 g (Fig 2c). As the impacted teeth moved downwards, the elastomeric power chains were cut shorter to maintain the effective traction. Oral hygiene instructions were given and a high level of patient compliance was demanded pre-operation and followed through during the subsequent visits. Three months later, the maxillary central incisors and the left lateral incisor were partially erupted (Fig 2d). Oral hygiene instruction and fluoride application were given and emphasised again in view of the poor gingival status. Two months later, the maxil-

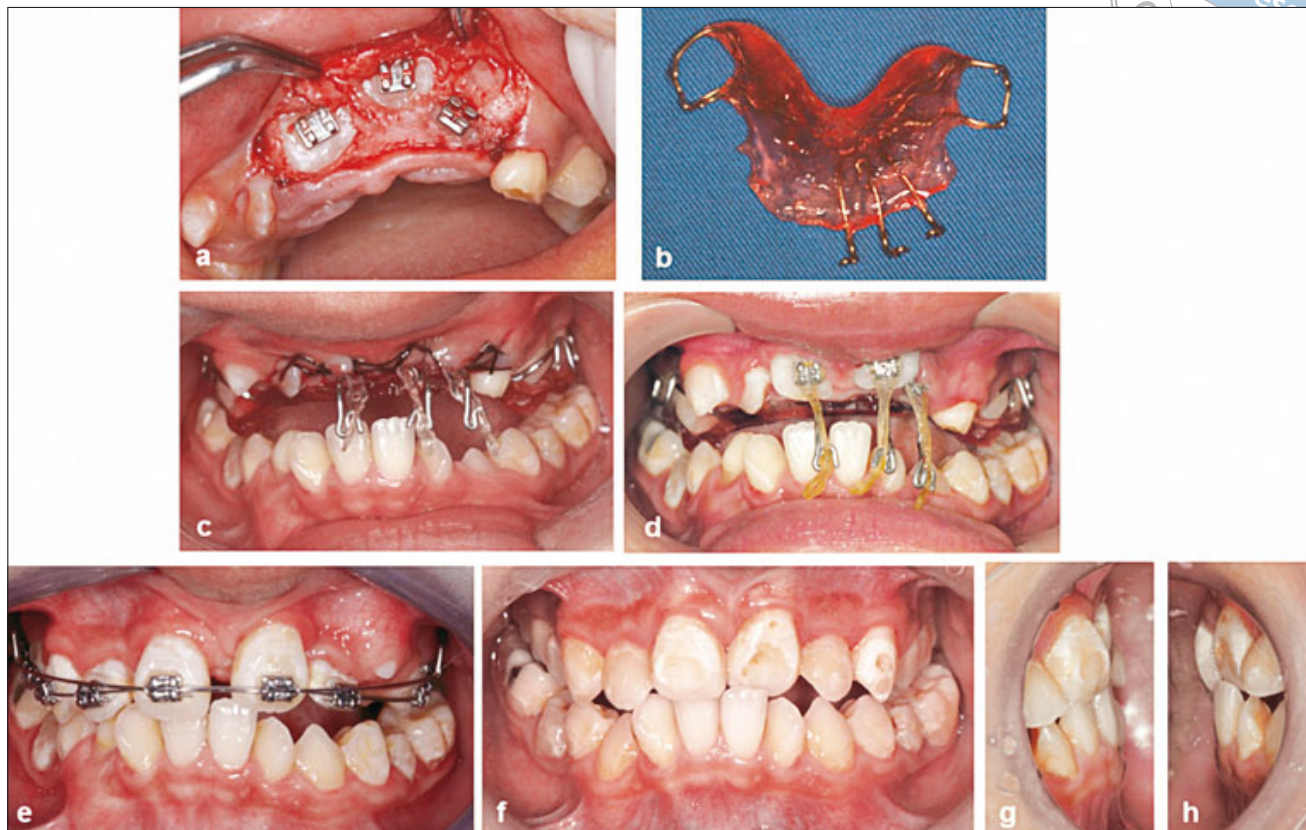



Fig 2 Documentations of the surgical and orthodontic treatment in case 1: a) surgical exposure of the impacted teeth with closed-eruption technique; b) the removable traction apparatus used in orthodontic treatment; c) the intraoral photograph showed immediate post-surgical orthodontic traction; d) 3 months after surgical exposure combined with orthodontic traction; e) 10 months after surgical exposure; f to h) 24 months after surgical exposure.

lary incisors continued erupting and a fixed orthodontic appliance was used in order to correct the anterior crossbite and align the maxillary arch. Seven months later, a good arch alignment of the anterior teeth was achieved (Fig 2e). Twenty-four months after surgery, all the anterior teeth were successfully erupted (Fig 2f), although posterior crossbite remained due to the maxillary hypoplasia. The face type of the patient was evidently improved from the intraoral lateral photographs (Figs 2g and 2h) compared with the pre-treatment (Figs 1h and 1i). The patient was referred to the orthodontist and the next treatment plan was made in order to treat the Class III malocclusion.

Case 2

The phenotype of case 2 was similar to case 1. The global treatment procedures of case 2 were similar to case 1. Most notably, there were two supernumerary

teeth which existed in the palatal side of the incisors in case 2, therefore surgical exposure and removal of the supernumerary teeth were also undertaken in case 2 (Fig 3a). After the brackets had bonded and the removal of the supernumerary teeth were complete, the mucoperiosteal flap was repositioned and sutured, then the orthodontic traction was initiated immediately after operation (Fig 3b). After 4 months, the four maxillary anterior teeth were erupted and the segmented arch technique was then used to align the maxillary anterior teeth (Figs 3c to 3e). Twelve months after surgical exposure, the anterior crossbite was obvious; this was corrected by a removable maxillary appliance with occlusal pad and armature tensioning spring in case 3 (Figs 3f and 3g). The obvious improvement of the anterior occlusion was noted after using a removable maxillary appliance (Fig 3h) compared to the pre-treatment (Fig 3i). Subsequently, this patient was referred to the orthodontist to treat the Class III malocclusion.

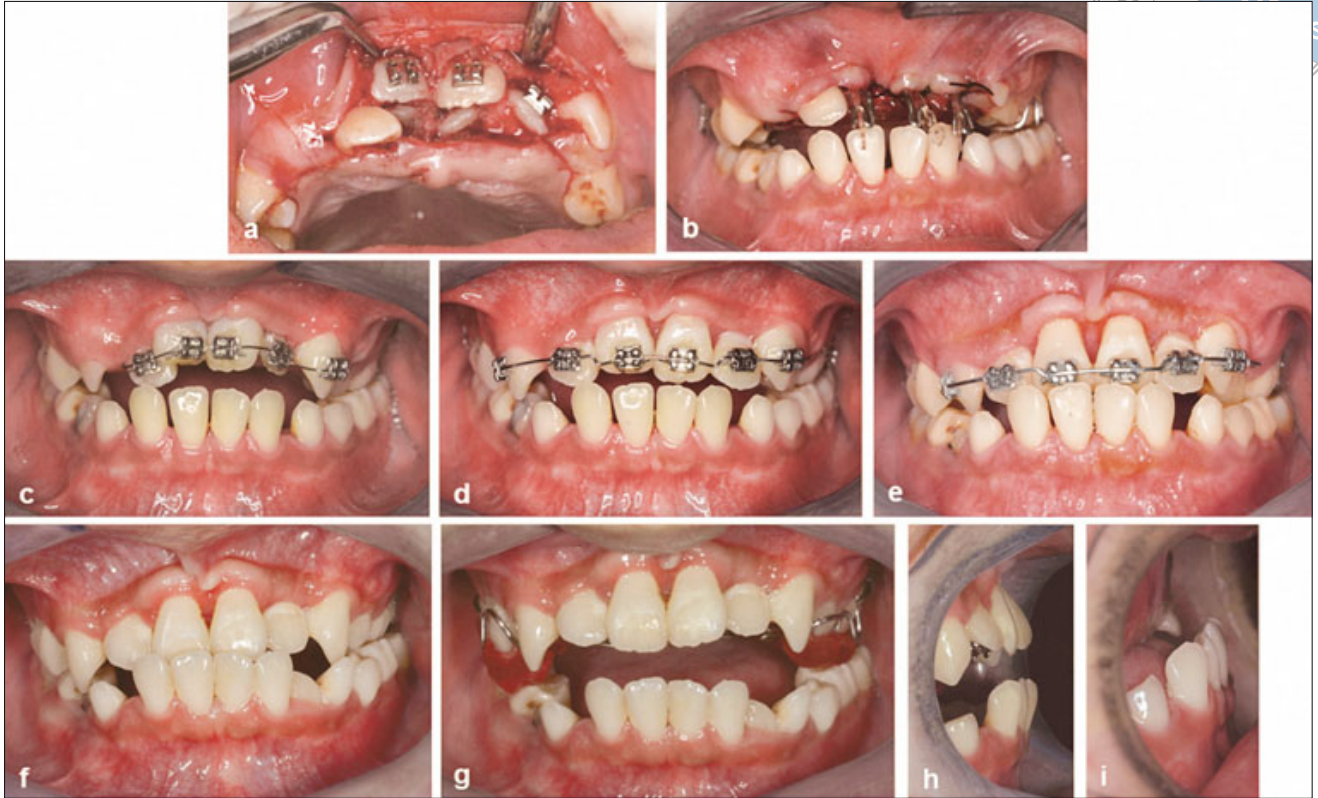

Fig 3 Intraoral photographs during treatment in case 2: a) surgical exposure of the impacted teeth and supernumerary teeth; b) immediate post-surgical orthodontic traction; c) 4 months after surgical exposure using the segmented arch technique; d) 6 months after surgical exposure; e) 8 months after surgical exposure; f) 12 months after surgical exposure; g) a removable maxillary appliance used to treat the anterior crossbite; h) intraoral lateral photograph during the use of the removable maxillary appliance; i) intraoral lateral photograph pre-treatment.

Early intervention strategies for a child patient (case 3)

Case 3 was a 10-year-old boy whose father was also a CCD patient. He had typical CCD features including delayed closure of the cranial sutures, hypoplastic clavicles and dental abnormalities. As this patient was diagnosed as CCD much earlier than the adolescent patients, the early intervention for this patient was also easier. Simple surgical exposure was carried out for this patient in order to promote the eruption of the incisors.

Although this patient was already 10 years old, all the permanent incisors were still unerupted except the mandibular left central incisor (Fig 4a). In order to remove the resistance force for the eruption of the permanent incisors, all the retained primary incisors were extracted. A full-thickness mucoperiosteal buccal flap was then raised in the maxillary anterior area and the crowns of the maxillary central incisors were exposed after the bone and dental sac were removed in order to

relieve the resistance force for eruption (Fig 4b). After hemostasis, the gingival flap was repositioned and sutured back (Fig 4c). Notably, there was a hypomineralised chalk spot in the enamel of the maxillary right central incisor (Fig 4b). After 10 months, all the permanent incisors were partially erupted except the maxillary lateral incisors (Fig 4d). Therefore, the crowns of the maxillary lateral incisors were also exposed after the gingiva was removed by the electrosurgical knife, in order to remove the resistance force of eruption. Six months later, all the permanent incisors were erupted and an anterior crossbite was indicated (Fig 4e). During this period, the maxillary and mandibular primary canines and molars were also timely extracted, based on the stage of root development of the succeeding permanent teeth, in order to promote the eruption of the lateral teeth (Fig 4f). The anterior occlusion of the patient was evidently improved from the intraoral lateral photographs (Fig 4g) compared with pre-treatment

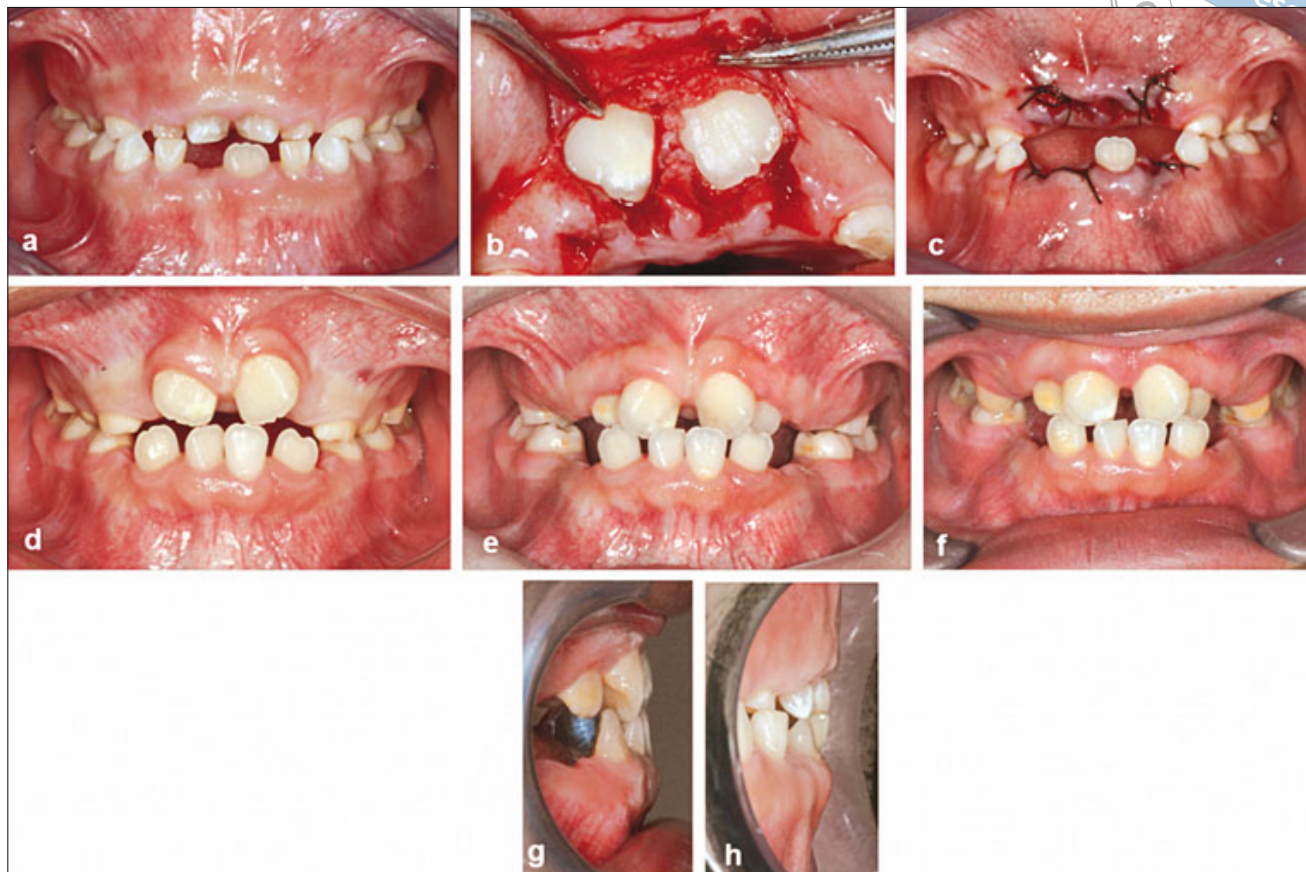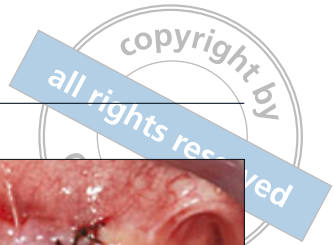


Fig 4 The intraoral photographs of case 3: a) the intraoral photograph pre-treatment; b) surgical exposure of the crowns of the maxillary central incisors during operation; c) immediate post-surgical; d) 10 months after surgical exposure; e) 16 months after surgical exposure; f and g) 24 months after surgical exposure; h) intraoral lateral photograph pre-treatment.

(Fig 4h). A long-term treatment plan was made for this patient along with his growth in order to ensure the timely eruption of the premolars and in order to correct anterior crossbite.

Results

Eventually, all the impacted maxillary incisors of the three CCD patients were successfully positioned into proper alignment either through the two stages of crown exposure and elastic traction or by simple surgical exposure. Some patients had compromised oral health during the period of treatment, which resulted in cervical decalcification of the maxillary anterior teeth and mild gingival inflammation. However, this situation was reversible. After educating the patients, with the main emphasis on the importance of oral health, this problem disappeared. Finally, the exposed incisors had an accept-

able gingival contour and attached gingiva, although parts of them had a slightly longer crown height. All the patients and their parents were satisfied with the treatment results of the incisors.

Discussion

Dental treatment planning for CCD patients is related to a number of factors. Among them, the chronological and dental ages of the patients are most important in global treatment planning. The timing of the diagnosis is not only important in choosing an appropriate treatment plan but also in attaining a successful treatment result for CCD patients². However, the typical extraoral symptoms of CCD are rarely manifested in early childhood and patients are usually undiagnosed until during adolescence, when the most ideal time for initiation of treatment is frequently missed in most patients^{1,9}. There-

fore, CCD patients always present many treatment challenges to the dental team.

Surgical exposure of unerupted permanent teeth with orthodontic guided eruption was the choice for the present two adolescent CCD patients given that the most ideal time for initiation of treatment had been missed. This ensured these patients kept their own teeth and avoided the need for prostheses that would have to be maintained or replaced several times during their lifetime. The orthodontic and surgical method applied to the present adolescent patients was similar to the Jerusalem approach presented by Becker, which emphasised that the initial efforts should be concentrated towards bringing anterior teeth into the mouth early for the patients' self-image¹⁰. For this reason, our protocol involved timely extraction of deciduous teeth, the staged surgical removal of supernumerary teeth, the exposure of selected unerupted permanent teeth and orthodontic forced eruption. Following alignment of all the permanent teeth, any underlying skeletal discrepancy (most commonly a class III skeletal malocclusion) can be corrected through orthognathic surgery after completion of growth^{11,12}. The obvious disadvantage of this approach is the extensive duration of the treatment, requiring multiple surgical procedures and the excellent cooperation of the patients.

In this study, the visiting time of case 3 was much earlier than the two adolescent patients. And the age of case 3 was in the most ideal time for initiation of the treatment when the age of patients are usually around 10 to 12 years old and the root development of the impacted incisors should be two thirds of their expected length⁹. In general, the removal of deciduous and supernumerary teeth will improve the possibility of spontaneous eruption¹⁰. In addition, bone overlying the normal permanent teeth should also be removed as it has been shown histologically that the alveolar bone in CCD has abnormal dense trabeculation with multiple reversal lines¹³. There was no supernumerary tooth in the anterior area of case 3, therefore the impacted anterior incisors of this patient successfully erupted merely through simple surgical exposure after removal of the deciduous teeth and the bone overlying the permanent teeth. Furthermore the orthodontic traction of the impacted anterior teeth was not carried out in this patient due to the timing of the intervention. Therefore, much earlier intervention will reduce the extent of the surgical and orthodontic intervention and the timing of intervention seems to be of the utmost importance for a successful result.

With respect to the uncovering flap design, all three patients used the closed eruption surgical technique, which returned the flap to its original location following the placement of an attachment on the impacted tooth¹⁴. This technique induced natural tooth eruption of the impacted tooth rather than the conventional design of the apically positioned flap. In the three cases, the periodontal status of the exposed incisor after orthodontic treatment revealed an acceptable gingival contour and attached gingiva. No further mucogingival surgery was recommended.

Acknowledgements

We are grateful to the patients and their families for their support and participation.

References

- Mundlos S. Cleidocranial dysplasia: clinical and molecular genetics. *J Med Genet* 1999;36:177–182.
- Jensen BL, Kreiborg S. Development of the dentition in cleidocranial dysplasia. *J Oral Pathol Med* 1990;19:89–93.
- Cooper SC, Flaitz CM, Johnston DA, et al. A natural history of cleidocranial dysplasia. *Am J Med Genet* 2001;104:1–6.
- Lee B, Thirunavukkarasu K, Zhou L, et al. Missense mutations abolishing DNA binding of the osteoblast-specific transcription factor OSF2/CBFA1 in cleidocranial dysplasia. *Nat Genet* 1997;16:307–310.
- Mundlos S, Otto F, Mundlos C, et al. Mutations involving the transcription factor CBFA1 cause cleidocranial dysplasia. *Cell* 1997;89:773–779.
- Komori T, Yagi H, Nomura S, et al. Targeted disruption of *Cbfa1* results in a complete lack of bone formation owing to maturational arrest of osteoblasts. *Cell* 1997;89:755–764.
- Otto F, Kanegane H, Mundlos S. Mutations in the *RUNX2* gene in patients with cleidocranial dysplasia. *Hum Mutat* 2002;19:209–216.
- Zhang C, Zheng S, Wang Y, et al. Mutational analysis of *RUNX2* gene in Chinese patients with cleidocranial dysplasia. *Mutagenesis* 2010;25:589–594.
- Becker A, Lustmann J, Shteyer A. Cleidocranial dysplasia: Part I--General principles of the orthodontic and surgical treatment modality. *Am J Orthod Dentofacial Orthop* 1997;111:28–33.
- Becker A, Shteyer A, Bimstein E, Lustmann J. Cleidocranial dysplasia: Part 2 – Treatment protocol for the orthodontic and surgical modality. *Am J Orthod Dentofacial Orthop* 1997;111:173–183.
- Farrar EL, Van Sickels JE. Early surgical management of cleidocranial dysplasia: a preliminary report. *J Oral Maxillofac Surg* 1983;41:527–529.
- Trimble LD, West RA, McNeill RW. Cleidocranial dysplasia: comprehensive treatment of the dentofacial abnormalities. *J Am Dent Assoc* 1982;105:661–666.
- Hitchin AD, Fairley JM. Dental management in cleidocranial dysostosis. *Br J Oral Surg* 1974;12:46–55.
- Vermette ME, Kokich VG, Kennedy DB. Uncovering labially impacted teeth: apically positioned flap and closed-eruption techniques. *Angle Orthod* 1995;65:23–32.