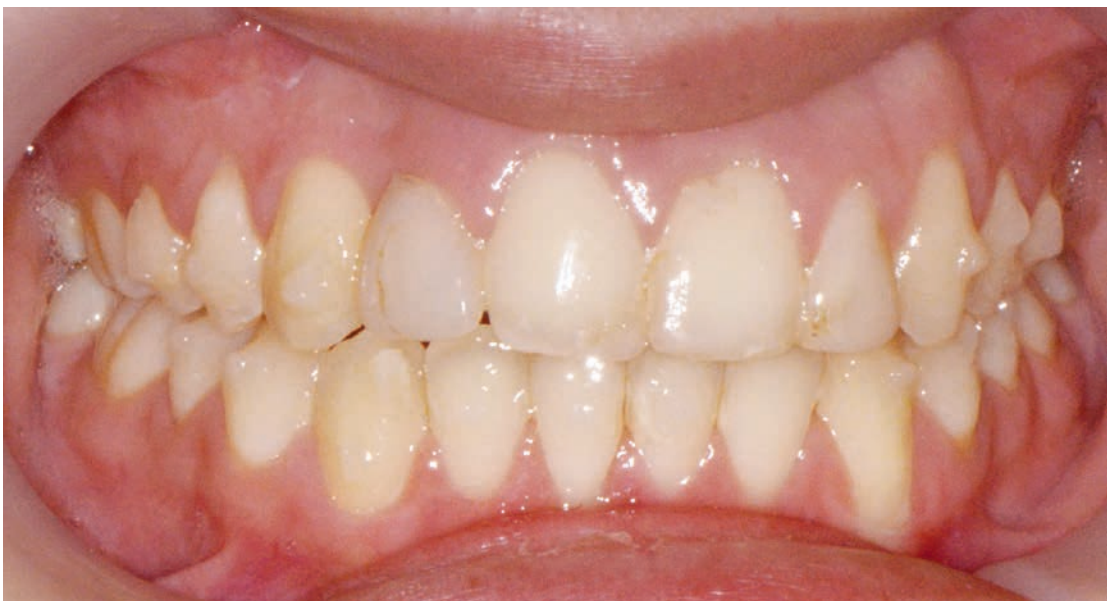
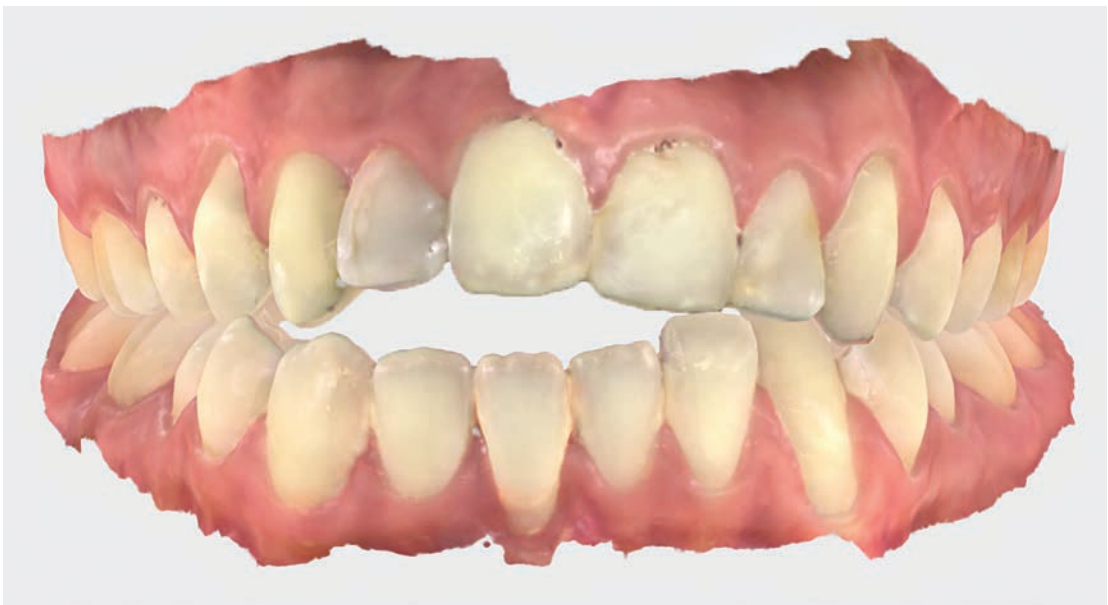
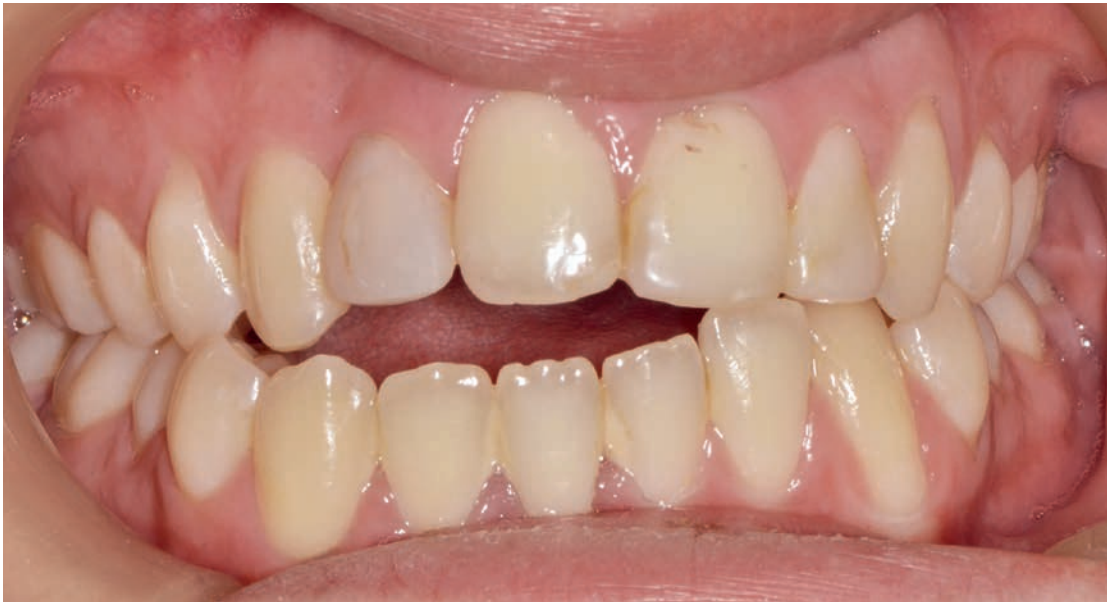

Rafi Romano, DMD, MSc

Lihi Keren, DMD

The Risks Behind Fixed Retainers After Orthodontic Treatment

Bonded fixed retainers are frequently used nowadays as the main—and often the only—retention protocol after orthodontic treatment. The expectations for long-lasting lifetime stability of the occlusion led orthodontists to seek the ultimate retention protocol with minimal patient compliance, including fixed retainers. However, fixed retainers have many disadvantages and risks that should be considered in advance. Different failures of fixed retainers are described and categorized, and the workflow for the retreatment of poor occlusion after relapse, despite the fixed retainers, is described. Three case presentations (open bite, root movement, and maxillomandibular protrusion) are described, and all received clear aligner treatment. A revised retention protocol is suggested. *Int J Periodontics Restorative Dent* 2025;45:263–275. doi: 10.11607/prd.7083

Keywords: clear aligners, fixed retainers, retention, stability

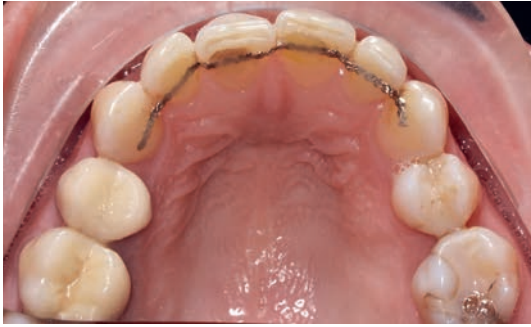It is common knowledge nowadays that patients expect their teeth to remain stable, both esthetically and functionally, for many years after completing their orthodontic treatment. Therefore, orthodontists are compelled to do endless follow-ups, basically for a lifetime.

The stability of orthodontic treatment is affected by numerous factors, including the type of initial malocclusion, age, gender, pathology of the surrounding soft tissues, patient compliance, and the retention protocol applied.¹

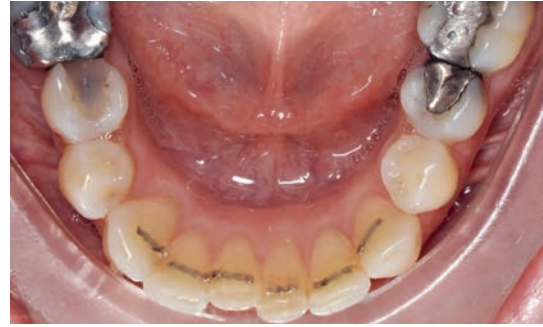Most orthodontic treatments are performed during the teen years, when most of the teeth are healthy and in their original form, while in adulthood they endure many changes such as attrition, abrasion, fillings, crowns, periodontal issues, and extractions, in addition to being influenced by the entire muscular behavior, including the lips and tongue.

The long-term prescription of bonded retainers started in the 1980s after Little's work in which retainers were prescribed for up to 2 years.² Maturation changes, physiologic effects, and true orthodontic relapse result in intra-arch and inter-arch relationship changes.^{3,4} Therefore, long-term retention has been recommended to conceal these posttreatment dental changes. Many orthodontists use permanent retention devices, especially in the anterior maxilla, and many of combine the fixed retention with a removable retention device.^{6,7}

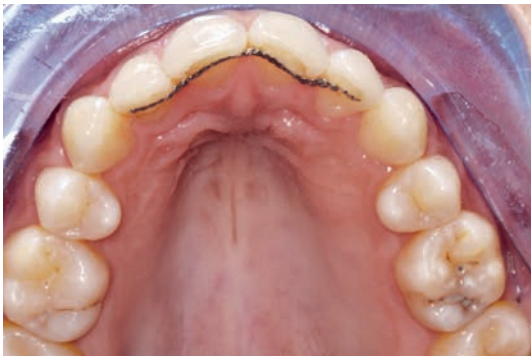Fixed retainers have become a standard routine in almost all orthodontic treatments; in most cases, they remain the only mode of retention. Although orthodontists usually prescribe removable aligners for nightwear retention in addition to fixed retainers, most patients reduce the time and duration they wear aligners and, slowly but surely, cease to wear them. It is frustrating for patients



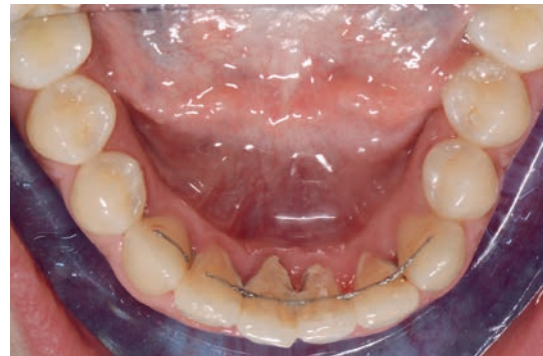▲ **Fig 1** Fixed retainer that was detached from teeth 11 and 21 (FDI numbering system), moving lingually (tooth 11) and buccally (tooth 21). The bonding material is still bonded to the wire, and thus the patient did not notice that the wire was detached from the tooth.



▲ **Fig 2** Mandibular occlusal view of a broken fixed retainer. The retainer did not detach from the tooth but broke due to extensive occlusal forces.



▲ **Fig 3** Maxillary occlusal view showing movement of the anterior teeth when the fixed retainer was still bonded and remained untouched.



▲ **Fig 4** Mandibular occlusal view showing accumulation of plaque and calculus around the fixed retainer and wire breakage on the right canine.

to be obligated to endure another treatment, and even when they opt for retreatment, there is again the dilemma of proper retention protocol.

For the best compliance, the patient should attend regular appointments several times a year during the retention phase.⁸ The use of removable retainers mostly depends on the patient's self-discipline, and the doctor's influence remains limited. No fixed retainer can guarantee the alignment stability after orthodontic treatment.⁹ It is common knowledge that early detection of bonding failures, wire breakage, and tooth movement created by the retainer is critical in preventing major problems.¹⁰

The present article describes the numerous risks behind fixed retainers when not combined with nighttime removable retainers and annual clinical follow-ups, regardless of whether the retainer broke, debonded, or remained untouched.

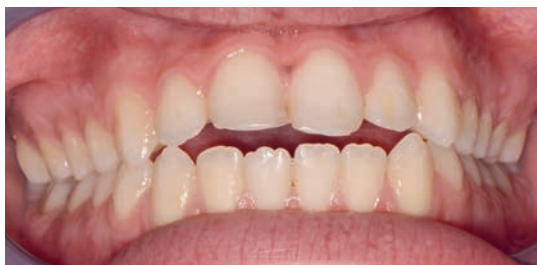Fixed Retention

Failures

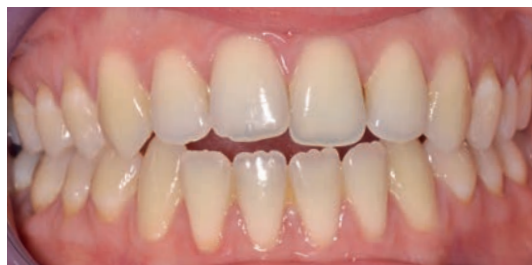Failures of fixed retention can be categorized as follows¹¹:

- Detached wire. Sometimes the wire does not break, but the bonding material will detach from the tooth, which will consequently move. Most of the time, the order is reversed: The tooth wants to move and then detaches from the bonding (Fig 1).
- Broken or missing fixed retainer (Fig 2).
- Tooth movement when the fixed retainer is still bonded and remains untouched (Fig 3).
- Higher calculus accumulation, greater marginal recession, and increased probing depth (Fig 4).¹²

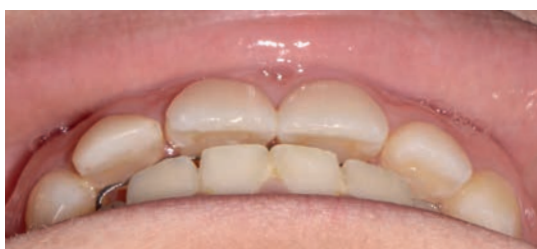The failure of the fixed retainer is rarely due to an incorrect technique, but if that is the reason



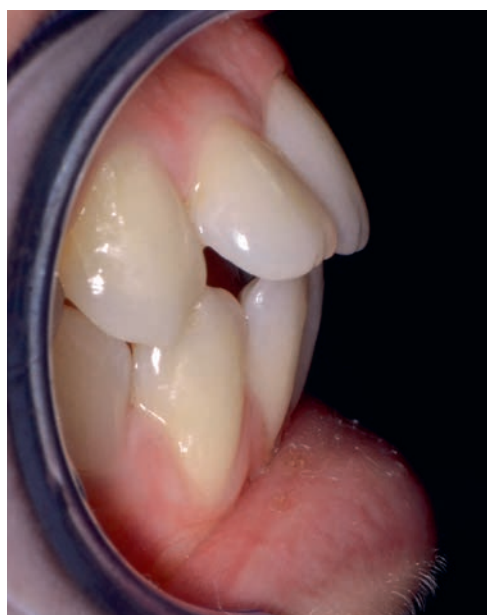▲ **Fig 5** Frontal view of teeth with a symmetrical anterior open bite that formed a few years after completing orthodontic treatment. The fixed retainers (Reliance Bond-A-Braid) remained complete and fully bonded to the teeth.



▲ **Fig 6** Frontal view of teeth with an asymmetrical anterior open bite that formed a few years after completing orthodontic treatment due to tongue thrust during rest and swallowing. The fixed retainers (Ortho FlexTech) became deformed due to movement of the anterior teeth but remained bonded to the teeth.



▲ **Fig 7** Oblique view of the occlusion showing the movement of the maxillary anterior teeth due to occlusal forces. The fixed retainer (Dental Straight Twist Wires Lingual Retainer Flex 3 Strand, 0.175-inch) remained complete and fully bonded to the teeth.



▲ **Fig 8** Lateral view of teeth with maxillomandibular protrusion. All anterior teeth moved buccally as one unit because they were connected with a fixed retainer.

for the failure, it will happen within the first weeks after bonding.

Recently, reports of unwanted tooth movements have increased, despite intact orthodontic bonded retainers. These movements are not subject to relapse but are classified as a newly developed malocclusion.

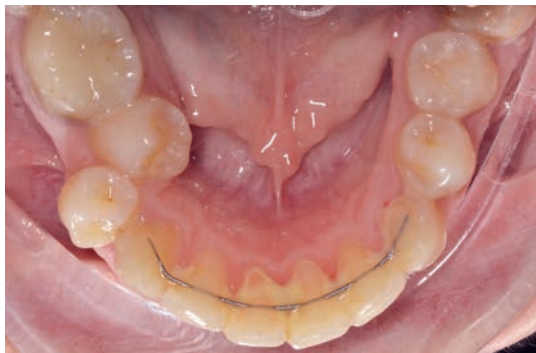The prevalence of patients with unwanted tooth movements in one or both arches has been reported as 27.0%, with maxillary retainers affected more often (20.9%) than mandibular retainers (14.1%).^{13,14}

Some articles claim that the mechanical properties of retention wires may play a role in tooth movement and should be examined.¹⁵ Many dental displacements of teeth contained by an intact orthodontic retainer wire without detachment or fracture can be qualified as aberrant, unexpected, and unexplained. Such displacements lead to esthetic and/or functional consequences, both dental and periodontal.^{16,17}

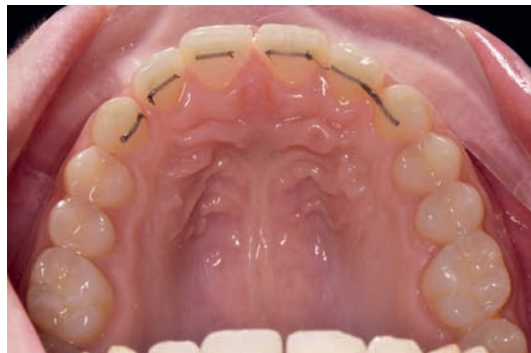Relapse and Movement

Relapse, unwanted, and undesired tooth movements during the retention period can be categorized as follows:

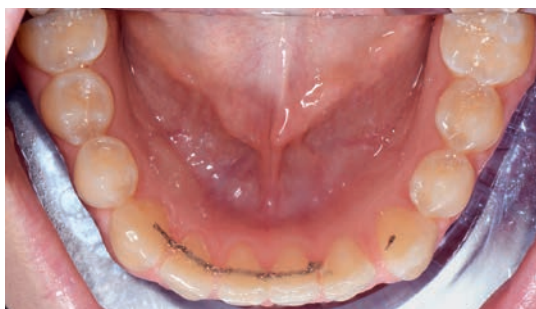- Symmetrical (Fig 5) and asymmetrical bite opening (Fig 6), usually due to the tongue thrust during rest, swallowing, and speech
- One-arch tooth proclination (Fig 7) or dual-arch proclination (Fig 8)
- Crowding of all remaining teeth, which do not have a fixed retainer (Fig 9)



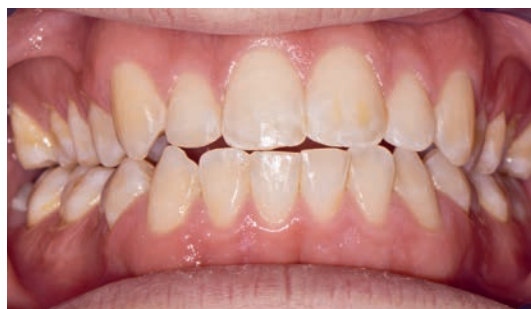▲ **Fig 9** Mandibular occlusal view showing posterior crowding and lingual movement of the premolar while the anterior teeth remained aligned with the fixed retainer, which was still bonded to the teeth.



▲ **Fig 10** Occlusal view of a maxilla. Note the spaces that opened in the arch, mainly between the central incisors and the broken fixed retainer. Because the retainer broke and was not detached, the patient did not notice it.



▲ **Fig 11** Occlusal view of a mandible. A space formed near the left canine, causing the breakage of the retainer.



▲ **Fig 12** Frontal view. Note the constriction of both arches and the posterior palatal/lingual crown torque.

- Spaces opened between the teeth, including median diastema (Fig 10), and spaces distal to the fixed retainers (Fig 11)
- Constriction of both arches and posterior palatal/lingual crown torque (Fig 12)
- Root movement while crowns remain aligned (Fig 13)
- Root resorption at teeth that have the bonded fixed retainer (Fig 14)
- Attrition and abrasion of incisal edges, which cause esthetic and functional problems (Fig 15)
- Periodontal problems associated with plaque accumulation around the fixed retainers (Fig 16)
- Alveolar bone loss around the teeth with the bonded retainers (Fig 17)

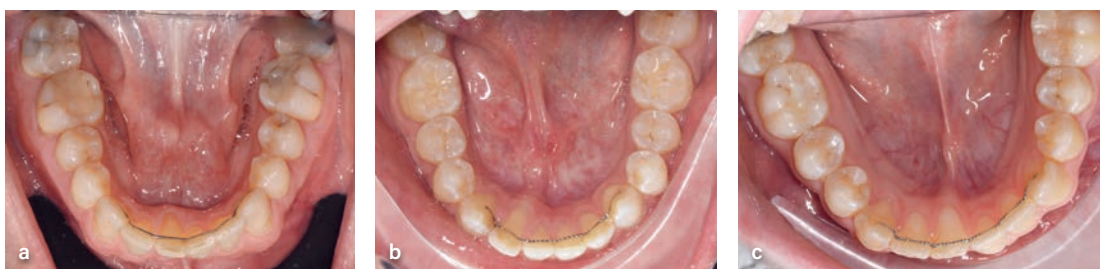The changes that occur over time can and should be monitored and treated all the time. Patients constantly use their teeth, which are supported by the bone and gingiva and are influenced

by the myofunctional envelope (the tongue, lips, and facial muscles). Retreatment after orthodontic treatment relapse should start with a proper and thorough diagnosis. Tooth movement will always occur as a consequence of unbalanced forces that change the equilibrium of teeth, bone, and muscles.

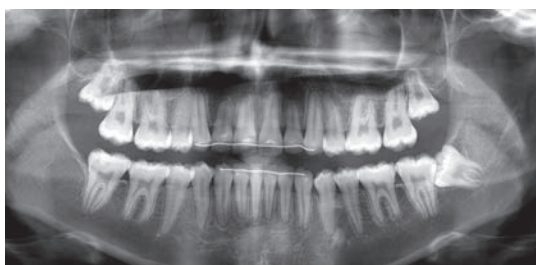
Retreatment Workflow

The workflow for the retreatment is as follows:

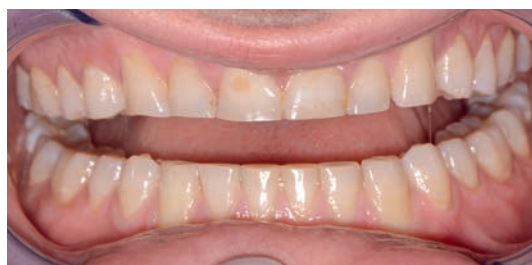- A. Time-lapse superimposition. Intraoral scanners (IOSs) are used to analyze the magnitude and type of tooth movements that occurred after orthodontic treatment ended. Therefore, IOS scans and photos are done during every follow-up visit.
- B. Simulating the movements needed to resolve the relapse and correct the occlusion both esthetically and functionally.



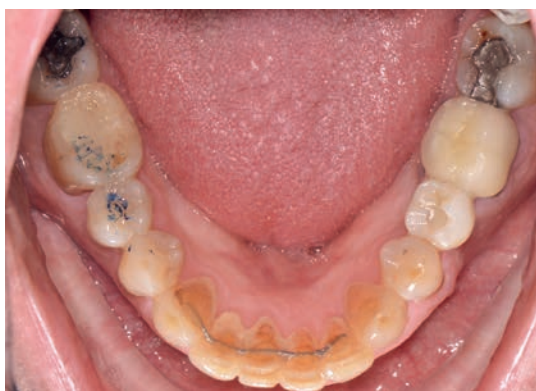▲ **Fig 13** Mandibular occlusal views of three different cases. In all of them, the fixed retainer is bonded and untouched, but the root of one incisor moved lingually.



▲ **Fig 14** Panoramic radiograph of a patient 4 years after retention. Note the flattening of tooth 12's root tip due to the occlusal forces created by a relapse of the mandibular incisor position. The fixed retainer held the maxillary tooth and prevented its movement, and thus the force was delivered to the root, which started the resorption.

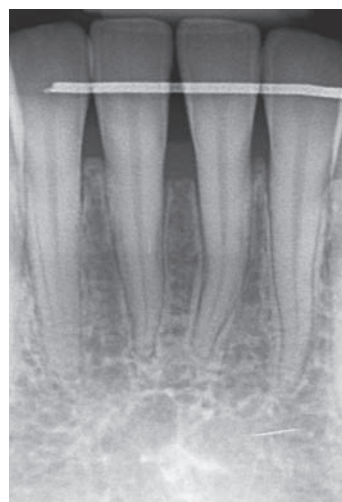


▲ **Fig 15** Frontal view of the teeth with extensive attrition. The fixed retainer did not help prevent the attrition and actually worsened it because the teeth could not protect themselves by moving forward.



▲ **Fig 16** Mandibular occlusal view showing periodontal problems associated with plaque accumulation around the fixed retainers. The fixed retainer did not prevent the progress of the massive attrition at the incisal edges.

▶ **Fig 17** Periapical radiograph of mandibular incisors taken 8 years after retention. Note the alveolar bone loss, mainly between the central incisors.

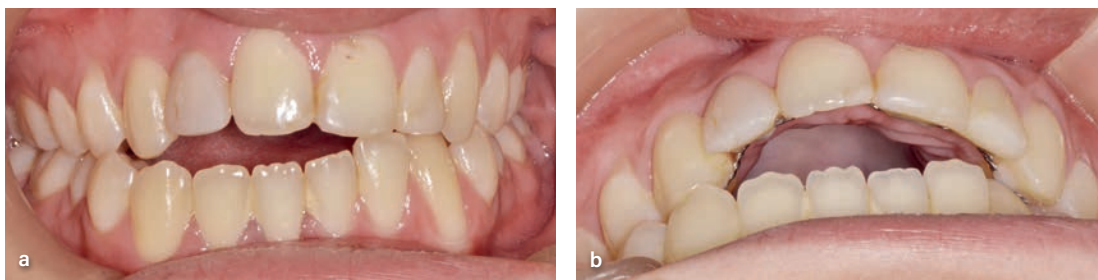


- C. Assessing the biomechanics and anchorage needed to execute the planned movements.
- D. Selecting the treatment technique and defining the staging and the speed of movement for each tooth or group of teeth.
- E. Establishing a newly revised retention protocol that also addresses the parameters that led to the relapse.

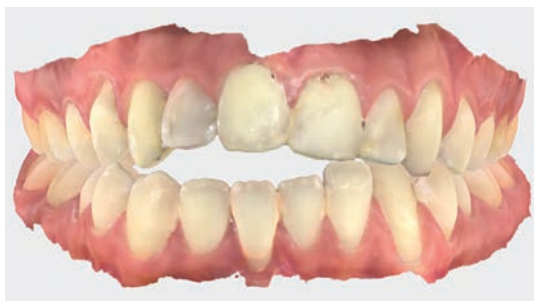Clear Aligner Treatment

In the last few years, clear aligner treatment (CAT) has been preferred over braces for the following reasons¹⁸:

1. 3D planning with precise and accurate forces and more predicted movement



▲ **Fig 18** (*a and b*) Frontal and occlusal views, respectively, of the teeth with an asymmetrical open bite caused by tongue thrust in all functional activities. The overjet is also big and asymmetrical. The maxillary left canine moved palatally due to the buccal movement of the anterior incisors, creating a lateral crossbite.



▲ **Fig 19** Case 1. An IOS image (iTero Plus Align technologies) shows loss of attached gingiva and buccal recessions around the mandibular incisors.

2. Decreased levels of periodontopathic bacteria when compared with treatment by fixed buccal orthodontic appliances¹⁹
3. Better anchorage when aligners are covering all aspects of the teeth and part of the gingiva and when composite attachments are added on the buccal or palatal/lingual surface or both²⁰
4. Staging of the treatment according to the dental condition of the moving and anchored teeth
5. Fewer emergencies
6. Better esthetics and patient compliance

Case Reports

The following cases describe the treatment of relapses that happened due to occlusal and functional forces. All cases were treated with CAT.

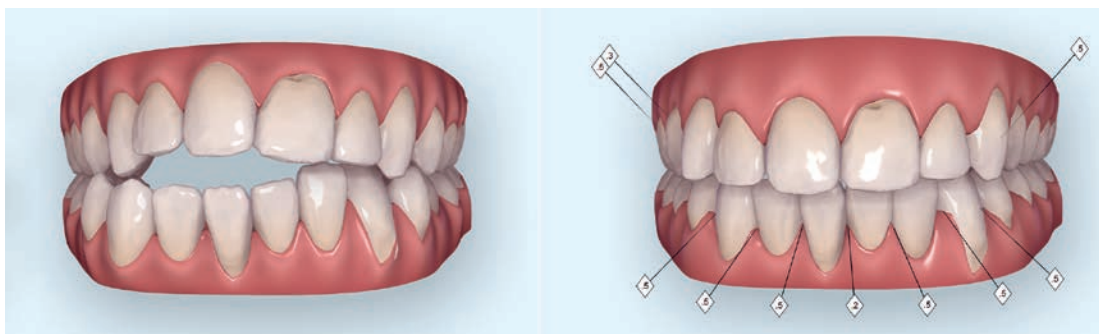
Case 1: Open Bite

A 24-year-old woman presented to the clinic 6 years after completing her orthodontic treatment. Like most patients, she stopped wearing her

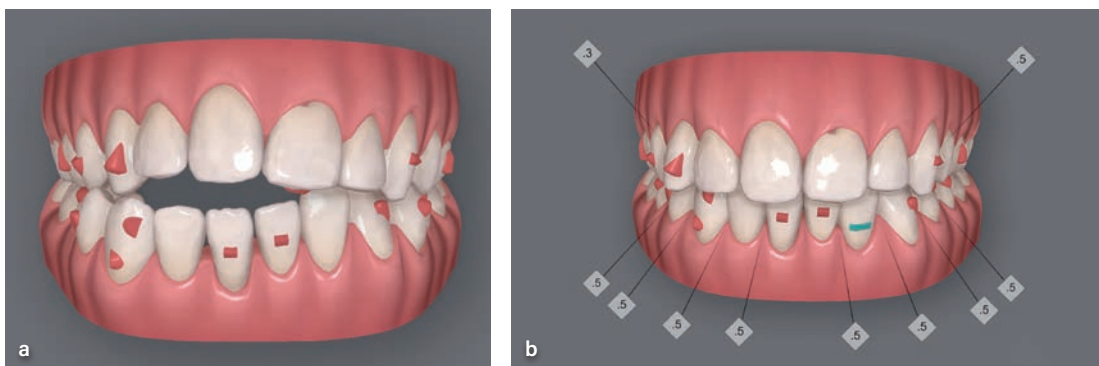
removable retainers over time, and the bonded fixed retainers were the only mode of retention. She had class I malocclusion, an asymmetrical front and lateral open bite, an enlarged overjet, and canting of the occlusal plane. The fixed retainers were still bonded and looked untouched (Fig 18). The malfunction of the tongue and consequent constriction of both arches (although rapid maxillary expansion [RPE] was used during treatment as a teenager) with the lack of a removable clear retainer caused these undesired relapse movements.

The IOS scan shows loss of attached gingiva and buccal recessions around the mandibular incisors due to the proclination of the teeth (Fig 19). The virtual simulation enabled the clinicians (R.R. and L.H.) to both simulate the treatment as well as guide the technicians (R.R. and L.H.) to the ideal end result, the amount and the location of the interproximal reduction (IPR), and the root movement needed for the mandibular incisors (Fig 20). The simulation was copied by the technician to ClinCheck planning software (Invisalign). The total planned movement was divided into 40 aligners to minimize the force and allow simultaneous myofunctional therapy (Fig 21). The superimposition of the planned movements shows the magnitude of the relapse and its direction (Fig 22). The tongue also caused constriction of the arch, which was corrected with the CAT (Fig 23).

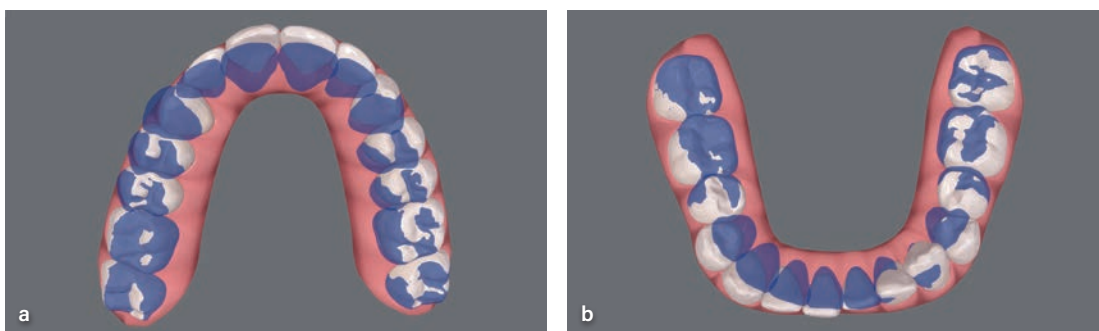
The final result showed complete and satisfactory closure of the open bite, a reduced overjet, and improved buccal recession in the mandibular incisors. The retention protocol was clear aligners (1 mm) every night for an unlimited time. Palatal attachments were kept on the maxillary incisors



▲ **Fig 20** Case 1. Outcome simulator before (left) and after treatment (right), done with iTero Plus. Note the slight expansion of and planned IPR in both arches, closure of the open bite, and regained midline.

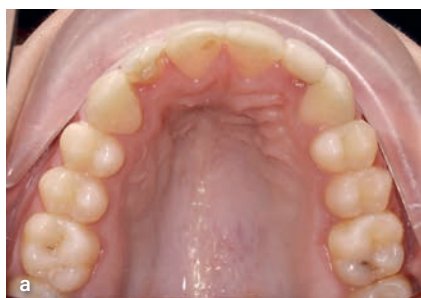


▲ **Fig 21** Case 1. (a and b) Treatment planning software of the patient before and after treatment, respectively. Note that all movements are copied by the technician from the simulation done by the orthodontist with the same IPR values. The case was divided into 40 aligners to allow small and controlled tooth movements. The plan included lingually moving the root of tooth 41 (with the buccal recession) to enable alveolar bone augmentation around it.

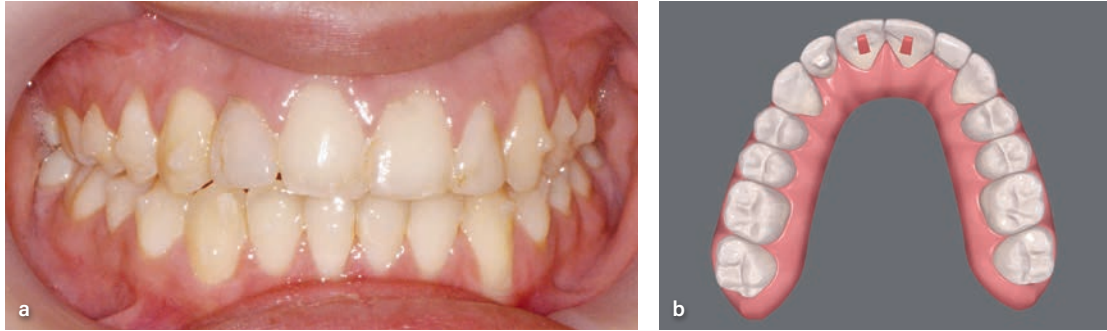


▲ **Fig 22** Case 1. (a and b) Superimposition of the movement planned for the maxilla and mandible, respectively. Note the amount of retrusion of the anterior teeth, indicating the magnitude of the relapse caused by tongue malfunction.

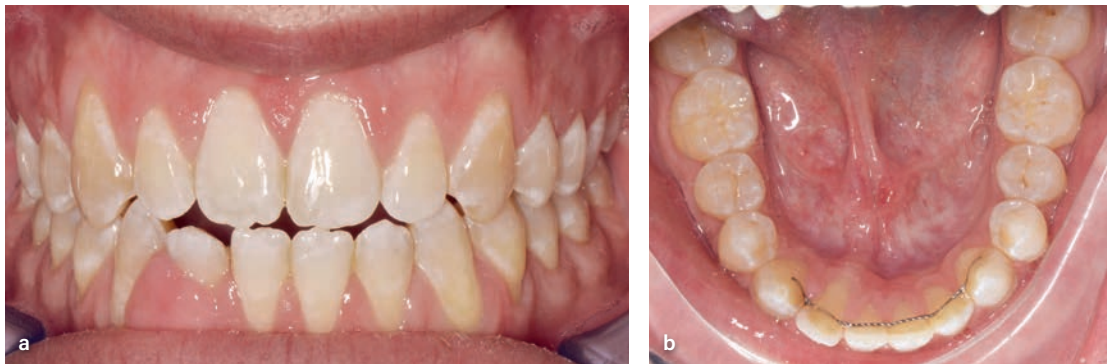► **Fig 23** Case 1. (a) The treatment included reshaping the maxilla, mainly at the premolar area. (b) Values after planned movements compared to initial values.



Arch width (mm)			
Upper arch			
Teeth	Initial	Align final	
1.3 - 2.3	33.5	37.2	+3.7
1.4 - 2.4	37.0	37.2	+0.2
1.5 - 2.5	41.5	41.6	+0.1
1.6 - 2.6	45.1	44.6	-0.5



▲ **Fig 24** Case 1. (a and b) Frontal and digital views, respectively, of the occlusion at treatment completion. Note the improved bite and smile. Palatal attachments remained bonded during the retention period to help avoid the tendency for relapse.



▲ **Fig 25** Case 2. (a to c) Frontal, mandibular occlusal, and CBCT views, respectively, show the root movement of tooth 42 almost completely out of the bone. The root of tooth 43 moved buccally and created a gingival recession. Note the fibrous epulis around tooth 2 due to the lingual root position.

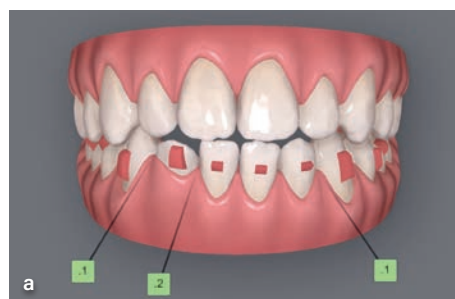
to increase the aligner retention and avoid the intrusion tendency (Fig 24).

Case 2: Root Movement

A 31-year-old man presented to the clinic 15 years after completing his orthodontic treatment. The patient had a mandibular fixed retainer bonded canine to canine. The root of tooth 42 (FDI numbering system) had moved lingually, and CBCT images showed that it was almost out of the alveolar bone envelope. The epithelium around tooth 42 proliferated and created fibrous epulis. The root of tooth 43 had moved buccally (Fig 25). The case

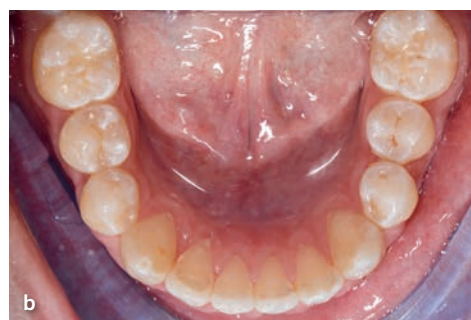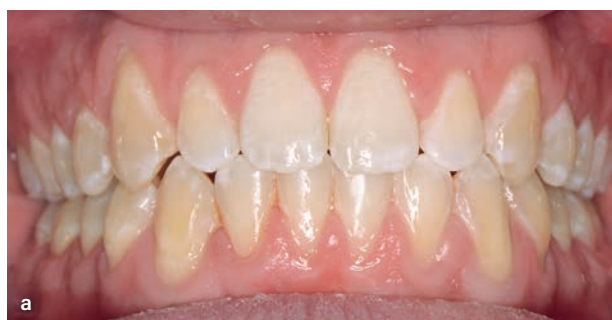was treated with CAT, as it provides an improved control of the magnitude and direction of movement of the crowns and the roots. The CAT plan included only 19 aligners (each one worn for 10 to 14 days) with reciprocal root movement. The root of 42 was planned to move buccally (17.5 degrees), and the root of 43 was planned to move lingually (Fig 26). The fibrous epulis was removed by a periodontist. After 8 months of treatment the correct root position was achieved, as shown in the clinical and CBCT records (Fig 27). The retention protocol was clear aligner removable retainers (1 mm) with no fixed retainers for unlimited time.

► **Fig 26** Case 2. (a) Treatment planning software of the patient. Optimal and conventional attachments were combined to improve the aligner retention and direct the forces that they apply. The movement was divided into 19 aligners. (b) Values after planned movements compared to initial values. The situation required 17.5 degrees of root movement to move tooth 42 back to its original position, parallel to the adjacent teeth.

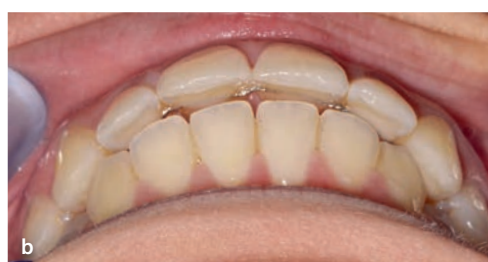
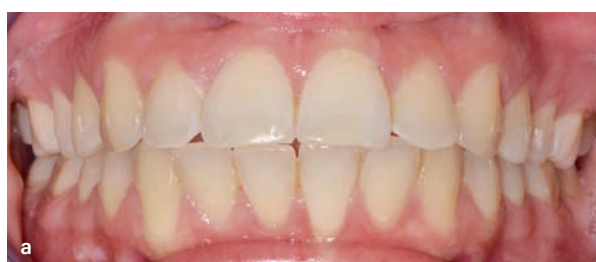
Tooth movements table

	4.3	4.2	4.1	3.1	3.2	3.3
Extrusion/Intrusion, mm	0.1 E	0.7 E	0.8 E	1.0 E	1.3 E	0.4 E
Relative Ext/Int, mm	0.2 E	1.6 E	1.7 E	1.8 E	1.3 E	0.2 I
Translation, B/L, mm	0.3 L	1.5 L	1.3 L	1.4 L	0.2 L	1.1 B
Translation, M/D, mm	0.1 D	0.2 D	0.1 D	0.1 D	0.1 D	0
Rotation, °	1.9 M	8.6 M	3.5 D	2.2 M	18.3 M	8.2 M
Angulation, °	6.9 D	6.5 D	5.7 D	5.9 M	4.2 M	3.8 D
Inclination, °	3.6 B	<u>17.5 L</u>	6.4 L	6.2 L	1.9 L	8.4 B



▲ **Fig 27** Case 2. (a and b) Frontal and mandibular occlusal views, respectively, at treatment completion. Note the improved bite and corrected root position of tooth 42.

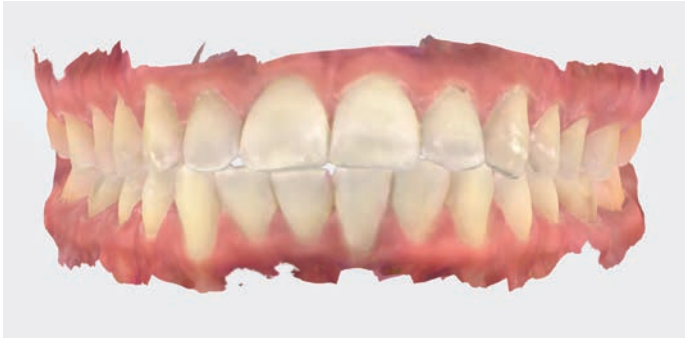

▲ **Fig 28** Case 3. (a and b) Frontal and oblique views, respectively, of the occlusion. Note the movement of maxillary and mandibular anterior teeth, which are now tilted and create an unaesthetic smile that continues to worsen over time.

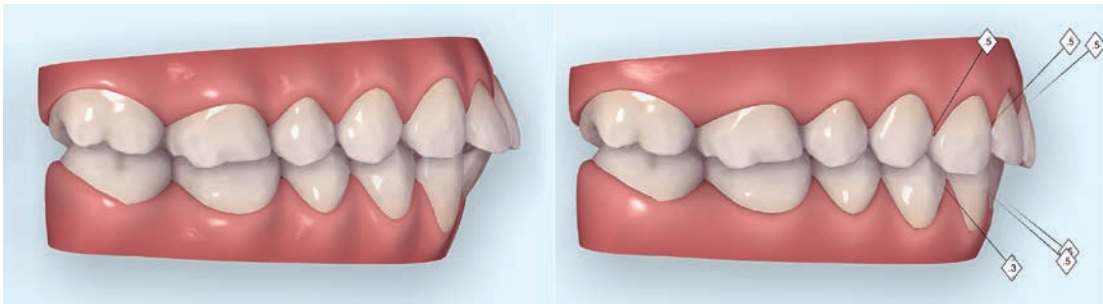
Case 3: Maxillomandibular Protrusion

A 34-year-old woman presented to the clinic 20 years after completing her orthodontic treatment. According to her report, she previously had braces on both arches, RPE for the maxilla, and myofunctional therapy. Her main complaint was that her teeth kept moving forward, creating an

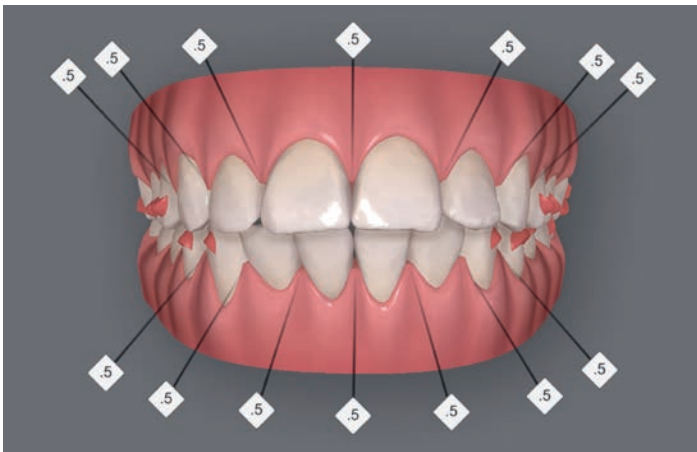
unaesthetic appearance and smile. The maxillary and mandibular incisors were tilted buccally, while the posterior occlusion were class I, with firm and tight occlusal contacts. All of these movements happened regardless of the bonded fixed retainers on both arches, which were bonded 20 years ago (Fig 28).



◀ **Fig 29** Case 3. An IOS scan shows the thin attached gingiva and the beginning of buccal recessions around the mandibular incisors.



▲ **Fig 30** Case 3. Simulation before (*left*) and after treatment (*right*), done with IOS. Note that the amount of IPR planned for all anterior teeth was limited to 0.5 mm.

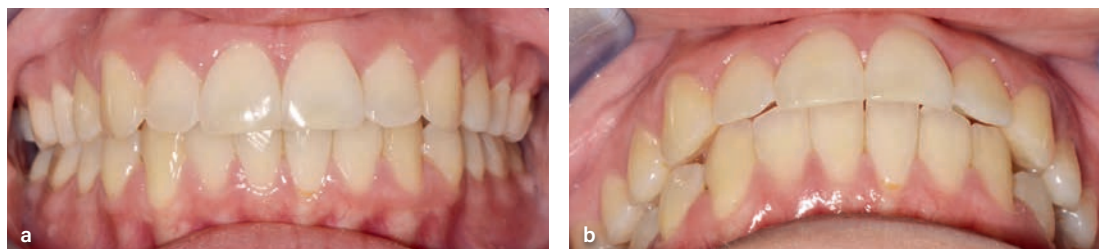
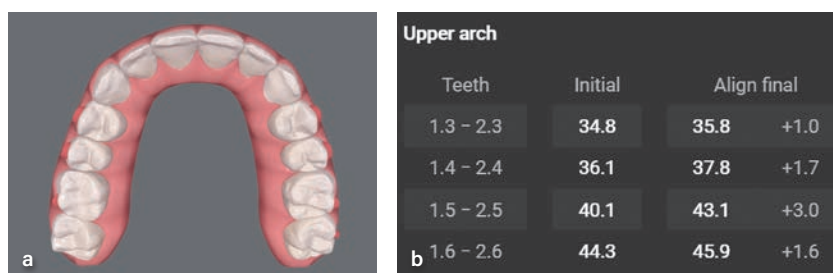


◀ **Fig 31** Case 3. Treatment planning software view. All movements were copied by the technician from the simulation done by the orthodontist with the same IPR values. The case was divided into 20 aligners.

The IOS scans showed thin attached gingiva and the start of buccal recession in the mandibular incisors (Fig 29). The simulation included an IPR of 0.5 mm from distal canine to canine in both arches (Fig 30) and was copied to the CAT plan (Fig 31), creating with 20 aligners (7 days each). The maxillary arch shape was modified to be broader, mainly at the premolar area (Fig 32). After 5 months of treatment, the angulation of the anterior teeth in both arches improved, achieving an esthetic smile

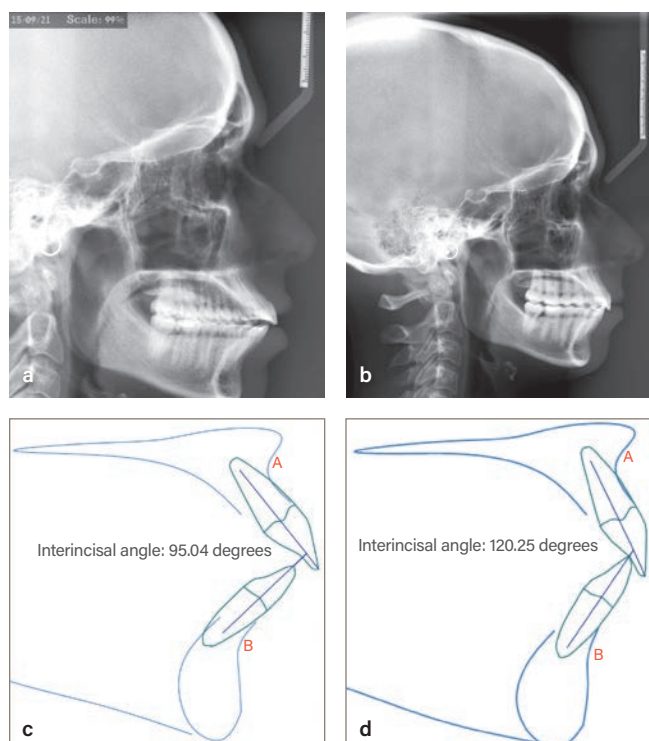
and improved lip support (Fig 33). When comparing the cephalometric radiographs taken before and after treatment, considerable improvement of the incisor proclinations can be seen, and the interincisal angle was changed from 95 to 120 degrees (Fig 34). The retention protocol in this case, as in all previous ones, was clear aligners (1 mm) for nighttime wear for an unlimited time and no bonded fixed retainer. Clinical follow-ups every 6 months were recommended.

► **Fig 32** Case 3. (a) The maxilla shape was modified with expansion at the premolar area. (b) Values after planned movements compared to initial values.



▲ **Fig 33** Case 3. (a and b) Frontal and oblique views, respectively, of the occlusion at treatment completion. Note the improved proclination of the teeth and the coverage of the mandibular incisors with attached gingiva.

► **Fig 34** Case 3. (a and b) Lateral cephalometric radiographs before and after treatment, respectively. (c and d) The interincisal angle was improved from 95 to 120 degrees, respectively.



Discussion

The need for lifetime retention due to high esthetic and functional demands and expectations from patients led orthodontists to seek the ultimate retention device and protocol. In 1999, Vanarsdall concluded that retreatment of 100 cases with

surgical rapid maxillary expansion (SARPE) led to impressive long-term stability.²¹ He also recommended that mandibular bonded retainers are kept in place for an indefinite time. Two cases presented in the article²¹ reported having RPE during their orthodontic treatment, yet considerable relapse had occurred over time.

The cases described in the present article demonstrate that failure of a fixed retainer is multifactorial. Therefore, skeletal transverse deficiency should definitely be considered as a factor, as well as others like attrition or abnormal function of the facial and tongue muscles. Retreatment of such cases should consider all factors that led to the relapse, including use of miniscrew-assisted rapid palatal expansion or SARPE to solve the skeletal discrepancy.

Fixed retainer failure has been described in the literature for a long time, and a systematic review published in 2022 called it *wire syndrom*.²² This iatrogenic phenomenon is responsible for significant dental and periodontal complications. Since the introduction of fixed bonded retainers by Zachrisson in the 1970s, fixed retainers have been progressively preferred to removable thermoplastic applications by patients and practitioners.²³ It has been recommended that the patient must also be actively involved in monitoring for and alerting clinicians to the occurrence of any adverse effects related to the presence of the retainer wire. This is, of course, a great challenge for the orthodontist who usually completes treatment when the patient is a teenager but must monitor the patient as an adult. There are some clinicians who claim that, compared to multi-strand, a flat retention wire is less prone to failures and consequent root or crown movement, but this statement was not clinically significant.^{24,25} All cases described in the present article had a flat retention wire, yet none of them could avoid the teeth or root movement, even when the retainer remained bonded and intact.

Recent articles have investigated the potential correlation between fixed orthodontic retention failure and treatment-related factors. One study suggests a correlation between fixed retention failure and parafunctional habits, such as abnormal tongue function.²⁶

The orthodontic relevance of nasal obstruction and tongue malfunction has been extensively investigated in the last 20 years. A 2002 study found a significant association between nasal resistance and increased overjet ($P = .042$), open bite ($P = .033$), and maxillary crowding ($P = .037$).²⁷ In one study, compared to the nasal-breathers

group, mouth-breathers demonstrated considerable backward and downward rotation of the mandible, increased overjet, an increased mandibular plane angle, a higher palatal plane, and narrowing of both dental arches at the canine and first-molar levels.²⁸ Airway constrictions, sleep apnea, and extraction of premolars and its effect on a patient's facial profile are all highly polarizing and debatable subjects among orthodontists.²⁹

Indeed, some cases need no retention at all. Some cases with fixed retainers remain stable and serve as the only retention device, and some cases do not need to use removable retainers more than one or two times per week. Can clinicians foresee and predict in which category their patient will fall? Most orthodontic treatments are done during the teenage years. Can clinicians expect patients to come for follow-up for many decades? On the other hand, it is important to share the present information about what can and what probably will happen if patients keep their fixed retainers without any support from removable retainers and without proper follow-up. The frustration from a second treatment, the commitments behind it, the time needed to correct the relapse, and the fee associated with it—not to speak of irreversible bone loss, root resorption, and more—led clinicians to adopt very strict and uncompromised retention protocols. Use of an IOS allows clinicians to not only scan the patient but also to print 3D models. These models are given to the patients and provides them with the option to come anytime for immediate removable retainer production in case they are lost or broken.

The active treatment (braces or CAT) can be over, but as long as the patient keeps using their teeth, they will tend to move and grind, and this will definitely change the way the teeth interact with others in the opposite arch, with the alveolar bone that hold them, and with the facial muscles that create additional forces on them.

Conclusions

The relevance of a fixed retainer should be questioned, especially because many clinicians believe that removable clear retainers are essential and

should be prescribed for every patient. Fixed retainers that are not supported by removable retainers bear many risks and can create more damage than benefits. It is the orthodontist's responsibility to provide a feasible and affordable retention protocol. Clear vacuum retainers (0.75 to 1.0 mm wide) for nighttime wear for an indefinite time is probably the most comfortable and affordable method to avoid unwanted and unexpected tooth movement and to reduce attrition and abrasion, which may happen over time.

Acknowledgments

The authors declare no conflicts of interest.

References

- Johnston CD, Littlewood SJ. Retention in orthodontics. *Br Dent J* 2015;218:119–122.
- Little RM. Stability and relapse of dental arch alignment. *Br J Orthod* 1990;17:235–241.
- Horowitz SL, Hixon EH. Physiologic recovery following orthodontic treatment. *Am J Orthod* 1969;55:1–4.
- Little RM, Riedel RA, Artun J. An evaluation of changes in mandibular anterior alignment from 10 to 20 years postretention. *Am J Orthod Dentofacial Orthop* 1988;93:423–428.
- Jedliński M, Grocholewicz K, Mazur M, Janiszewska-Olszowska J. What causes failure of fixed orthodontic retention?—Systematic review and meta-analysis of clinical studies. *Head Face Med* 2021;17:32.
- Andriekute A, Vasiliauskas A, Sidlauskas A. A survey of protocols and trends in orthodontic retention. *Prog Orthod* 2017;18:31.
- Lai CS, Grossen JM, Renkema AM, Bronkhorst E, Fudalej PS, Katsaros C. Orthodontic retention procedures in Switzerland. *Swiss Dent J* 2014;124:655–661.
- Valiathan M, Hughes E. Results of a survey-based study to identify common retention practices in the United States. *Am J Orthod Dentofac Orthop* 2010;137:170–177.
- Al-Dboush, Al-Zawawai E, El-Bialy T. Do orthodontic fixed retainers guarantee the stability of dental alignment at the end of orthodontic treatment? *Evid Based Dent* 2021;22:148–149.
- Shaughnessy TG, Proffit WR, Samara SA. Inadvertent tooth movement with fixed lingual retainers. *Am J Orthod Dentofacial Orthop* 2016;149:277–286.
- Kartal Y, Kaya B. Fixed orthodontic retainers: A review. *Turk J Orthod* 2019;32:110–114.
- Abu Arqub S, Al-Moghrabi D, Tsihaki A, Sanders D, Uribe F. The dark side of fixed retainers: Case series. *Am J Orthod Dentofacial Orthop* 2023;164:e72–e88.
- Klaus K, Xirouchaki F, Ruf S. 3D-analysis of unwanted tooth movements despite bonded orthodontic retainers: A pilot study. *BMC Oral Health* 2020;20:308.
- Katsaros C, Livas C, Renkema AM. Unexpected complications of bonded mandibular lingual retainers. *Am J Orthod Dentofacial Orthop* 2007;132:838–841.
- Kučera J, Marek I. Unexpected complications associated with mandibular fixed retainers: A retrospective study. *Am J Orthod Dentofacial Orthop* 2016;149:202–211.
- Charavet C, Israël N, Vives F, Dridi SM. Importance of early detection of wire syndrome: A case series illustrating the main stages of the clinical gradient. *Clin Pract* 2023;13:1100–1110.
- Martin C, Littlewood SJ, Millett DT, et al. Retention procedures for stabilizing tooth position after treatment with orthodontic braces. *Cochrane Database Syst Rev* 2023;5:CD002283.
- Weir T. Clear aligners in orthodontic treatment. *Aust Dent J* 2017;62(suppl 1):58–62.
- Karkhanechia M, Chow D, Sipkin J, et al. Periodontal status of adult patients treated with fixed buccal appliances and removable aligners over one year of active orthodontic therapy. *Angle Orthod* 2013;83:146–151.
- Cowley DP, Mah J, O'Toole B. The effect of gingival-margin design on the retention of thermoformed aligners. *J Clin Orthod* 2012;46:697–702.
- Vanarsdall RL Jr. Transverse dimension and long-term stability. *Semin Orthod* 1999;5:171–180.
- Charavet C, Vives F, Aroca S, Dridi SM. "Wire syndrome" following bonded orthodontic retainers: A systematic review of the literature. *Healthcare (Basel)* 2022;10:379.
- Klaus K, Xirouchaki F, Ruf S. 3D-analysis of unwanted tooth movements despite bonded orthodontic retainers: A pilot study. *BMC Oral Health* 2020;20:308.
- Al-Maaitah EF, Alomari S, Al-Nimri. Comparison between round multi-strand wire and rectangular wire bonded retainers: A randomized clinical trial. *Dental Press J Orthod* 2023;28:e2321101.
- Mheissen S, Spinel LM. Is there a difference among different bonded retainers in regard to survival rate? *Evid Based Dent* 2022;23:156–157.
- Verschueren K, Rajbhoj AA, Begnoni G, Willems G, Verdonck, de Llano-Pérula MC. Risk factors for orthodontic fixed retention failure: A retrospective controlled study. *Korean J Orthod* 2023;53:365–373.
- Lopatiene K, Babarskas A. Malocclusion and upper airway obstruction [in Lithuanian]. *Medicina (Kaunas)* 2002;38:277–283.
- Harari D, Redlich M, Miri S, Hamud T, Gross M. The effect of mouth breathing versus nasal breathing on dentofacial and craniofacial development in orthodontic patients. *Laryngoscope* 2010;120:2089–2093.
- Berant D, Velicu DB. More than straightening teeth: The orthodontist's role in sleep dentistry. *Compend Contin Educ Dent* 2023;44:340–342.

Rafi Romano, DMD, MSc

Lihi Keren, DMD

Private practice, Tel Aviv, Israel.

Correspondence to:

Dr Rafi Romano, rafi@drromano.com