

Effect of Intact Periosteum on Alveolar Ridge Contour Stability after Horizontal Guided Bone Regeneration in the Posterior Region: a Retrospective and Radiographical Cohort Study

Deng Hui DUAN¹, Hom Lay WANG², En Bo WANG¹

Objective: To radiographically evaluate the effect of intact periosteum in guided bone regeneration (GBR) for the treatment of peri-implant ridge defects in posterior region.

Methods: Twenty-eight patients who satisfied the criteria were included in this study. Buccal dehiscence defects were regenerated using demineralised bovine bone mineral (DBBM). Subjects were divided into two groups: the control group (conventional GBR, buccal trapezoidal flap and DBBM with collagen membrane coverage, $n = 14$) and the test group (modified GBR, buccal pouch and DBBM with collagen membrane coverage, $n = 14$). CBCT images obtained immediately after and 3 to 7 months following GBR were used to assess buccal bone thickness (BBT) at a level of 0, 2, 4 and 6 mm below the implant platform.

Results: Immediately after surgery, BBT at 0 mm and 2 mm below the implant platform presented a significant difference between the two groups ($P < 0.05$) with significantly thicker buccal bone in the control group in terms of BBT-0 (3.83 ± 1.01 mm) and BBT-2 (4.88 ± 1.15 mm) than in the test group (2.33 ± 0.66 mm and 3.60 ± 1.10 mm, $P = 0.000$ and $P = 0.008$, respectively). After 3 to 7 months of healing, the BBT at all levels showed no significant difference between the two groups ($P > 0.05$), but more bone graft resorption (BBR) in the control group in terms of BBR-0 (2.45 ± 1.14 mm), BBR-2 (2.09 ± 0.94 mm) and BBR-0% ($65.37\% \pm 26.62\%$) than the test group (BBR-0 1.07 ± 0.51 mm, $P = 0.001$; BBR-2, 1.22 ± 0.63 mm, $P = 0.008$; BBR-0% $45.70\% \pm 15.52\%$, $P = 0.024$).

Conclusion: In the short term, all treatment modalities achieved similar coronal BBT and the intact periosteum had a positive effect on keeping ridge dimensions even.

Key words: alveolar ridge augmentation, bone regeneration, CBCT, dental implants
Chin J Dent Res 2023;26(4):227–233; doi: 10.3290/j.cjdr.b4784067

Guided bone regeneration (GBR) using particulate bone graft with a collagen membrane is commonly employed to resolve peri-implant ridge defects¹⁻³; however, the stability of alveolar ridge contour after GBR surgery is unpre-

dictable, as up to 68.9% of the augmented alveolar ridge dimension may collapse horizontally.⁴⁻⁷ The potential mechanisms were apical displacement of bone graft^{5,8,9} and its accelerated resorption^{10,11} for an unstable mechanical environment in the augmented implant sites generated due to pressure from the perioral muscles.

The periosteum is a specialised, vascularised connective tissue anchored to the surface of bone and has two distinct layers: the outer fibrous layer containing fibroblasts, nerves, vessels and Sharpey fibres, and the inner cambium layer containing the osteoprogenitors¹²⁻¹⁵. Due to the lower elasticity of its fibrous layer, a buccal trapezoidal mucoperiosteal flap with a periosteal incision at the mesial, distal and apical sites is needed to achieve primary tension-free wound closure in GBR surgery^{16,17}. Consequently, the buccal

1 Department of Oral and Maxillofacial Surgery, Peking University School and Hospital of Stomatology, National Clinical Research Centre for Oral Diseases & National Engineering Research Centre of Oral Biomaterials and Digital Medical Device, Beijing Key Laboratory of Digital Stomatology, Beijing, P.R. China.

2 Department of Periodontics and Oral Medicine, School of Dentistry, University of Michigan, Ann Arbor, MI, USA.

Corresponding author: Dr En Bo WANG, Department of Oral and Maxillofacial Surgery, Peking University School and Hospital of Stomatology, #22, Zhongguancun South Avenue, HaiDian District, Beijing, 100081, P.R. China. Tel: 86-10-82195382; Fax: 86-10-62173402. Email: ebwang-hlg@163.com.

trapezoidal flap cannot withstand the pressure from the perioral muscles, forcing the bone graft materials to be displaced apically during healing^{5,8,9}. In addition, the mesio, distal and apical tension-releasing incisions not only increase the postoperative reaction and nerve injury complications¹⁸, but also reduce the blood supply from the buccal soft tissue flap to the bone graft material underneath.

The application of a buccal trapezoidal mucoperiosteal flap has been challenged recently by the subperiosteal tunnelling technique¹⁹⁻²² and the intrabony defect reconstruction associated with peri-implantitis²³⁻²⁵, through which successful bone regeneration has been achieved with a punch flap^{19,20,23-25}. Successful bone regeneration may be attributed to the intact periosteal fibrous layer in the tunnelling technique and the intrabony defect within peri-implantitis to confine the bone graft within the pocket or defect.

To take advantage of the properties of the periosteum to perform GBR in a minimally invasive manner, this study proposes a modified GBR procedure: after making an incision at the bone crest, a mucoperiosteal flap is elevated buccally to form a pouch between the buccal bone plate and the elevated periosteum. The particulate bone graft with collagen membrane is grafted into the pocket after implant placement. The mucoperiosteal flap is sutured with a transmucosal healing abutment. The purpose of the present study was to retrospectively and radiographically investigate the role of the intact periosteum on the stability of alveolar ridge contour after GBR; that is, whether there were differences in ridge contour between the conventional GBR procedure (control group) and the modified GBR procedure (test group).

Materials and methods

Patient selection

All patients were informed of the treatment protocol and signed an informed consent form. The study was conducted in accordance with the 1975 Declaration of Helsinki as revised in 2013. The study protocol was approved by the Institutional Review Board of Peking University School and Hospital of Stomatology, Beijing, China (approval no. PKUSSIRB-202385015), and the Strengthening the Reporting of Observational Studies in Epidemiology (STROBE) guidelines were followed.

A total of 61 consecutive patients who underwent GBR during implant placement at the Department of Oral and Maxillofacial Surgery of Peking University

School and Hospital of Stomatology in Beijing, China from January 2019 to April 2023 were included in this retrospective study. The inclusion criteria were as follows:

- aged 19 years or older;
 - a single missing maxillary or mandibular posterior tooth with intact mesial and distal adjacent teeth;
 - a buccal dehiscence defect at the time of implant placement;
 - three sets of CBCT data available (T0, preoperative; T1, immediately after dental implantation and GBR surgery; and T2, 3 to 7 months after surgery).
- The exclusion criteria were as follows:
- more than one missing tooth at the surgical site;
 - combined horizontal and vertical peri-implant defect at the buccal site;
 - palatal or lingual peri-implant bone defect;
 - CBCT data with severe artifacts or not available;
 - ongoing use of immunosuppressants, corticosteroids or bisphosphonates;
 - smoking more than 10 cigarettes per day.

GBR procedures

All surgical procedures in this study were performed by one oral surgeon (Duan DH). In the control group, GBR was performed using a conventional trapezoidal flap with vertical and periosteal releasing incisions. After local infiltration anaesthesia, a mid-crestal incision was made at the edentulous site, and vertical releasing incisions were placed at the line angles of the immediately adjacent mesial and distal teeth. Full-thickness buccal and oral flaps were raised. According to the manufacturer's instructions, a 10-mm-long tissue-level implant (Standard Plus, Straumann, Basel, Switzerland) was placed in a prosthetically driven position with a cover screw placed. A collagen membrane (Bio-Gide, Geistlich, Wolhusen, Switzerland) was trimmed, placed buccal to the ridge and fixed apically with a minimum of two titanium tacks. Deproteinised bovine bone mineral (DBBM) (Bio-Oss, Geistlich) was placed over the buccal dehiscence defect up to the smooth-rough implant interface. The membrane was stretched tightly over the graft and fixed with titanium pins. Periosteal releasing incisions were made along the buccal flap to achieve passive primary wound closure along with resorbable sutures (Jiahe Medical Materials, Changsha, China) (Fig 1).

In the test group, a buccal pouch design without periosteal or vertical releasing incisions was used. After administering local infiltration anaesthesia, a mid-crestal incision was made at the edentulous site, and a minimally invasive full-thickness buccal flap was

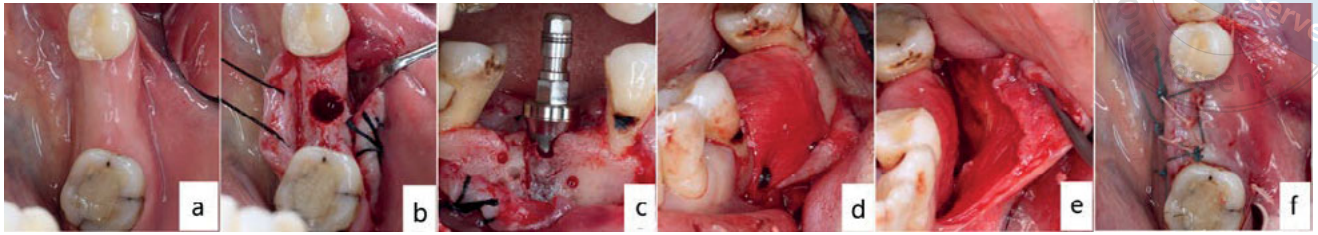


Fig 1 Surgical protocol for the control group. (a) Occlusal view of the mandibular left first molar implant site. (b) Thin buccal bone plate after implant osteotomy site preparation. (c) Buccal dehiscence defect after implant placement. (d) Bone graft covered by collagen membrane. (e) Buccal trapezoidal flap with periosteal releasing incision. (f) Primary wound closure with resorptive suture.

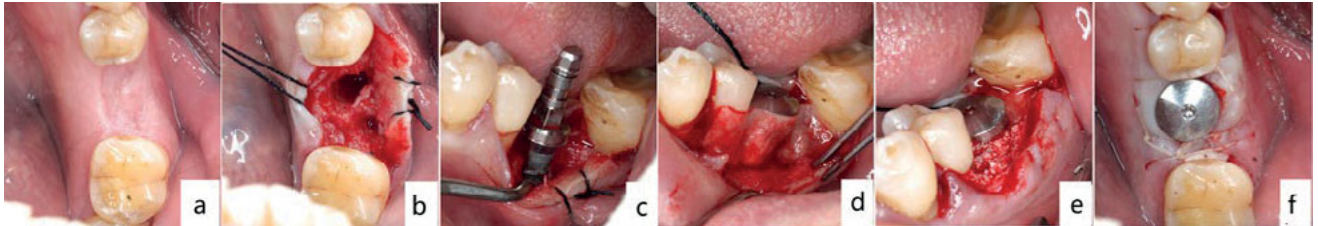


Fig 2 Surgical protocol for the test group. (a) Occlusal view of the mandibular left first molar implant site. (b) Buccal bone defect after implant osteotomy site preparation. (c) Buccal dehiscence defect after implant placement. (d) Collagen membrane inserted into the buccal pouch. (e) Bone graft covered with collagen membrane and restricted within the buccal pouch. (f) Non-primary wound closure with resorbable suture.

elevated mesially, distally and apically to form a pouch with an approximate dimension of 12 mm (apicocoronal) by 15 mm (mesiodistal). Following the manufacturer's instructions, a 10-mm-long tissue-level implant was placed in a prosthetically driven position (Standard Plus), and a 3-mm-tall healing abutment was placed. The buccal dehiscence defect was grafted over with DBBM up to the smooth-rough implant interface. A collagen membrane (Bio-Gide) was inserted between the flap and the graft. The site was sutured (Vicryl Rapide, Ethicon, Somerville, MA, USA), leaving the healing abutment exposed (Fig 2).

Following surgery, patients were prescribed an antibiotic (500 mg amoxicillin, p.o, b.i.d) and an analgesic (600 mg ibuprofen p.o, t.i.d) for 7 days. They were instructed to rinse twice daily for 30 seconds with 0.12% chlorhexidine gluconate. Sutures were removed 7 to 14 days after surgery. Patients were recalled on a monthly basis after implantation to monitor healing. In the control group, re-entry surgery was performed after 3 to 7 months, and taller healing abutments were placed as needed. All patients were referred to their prosthetic dental practitioner for restoration 3 to 7 months after surgery.

Radiographic evaluation

CBCT scans were taken of all sites using a CBCT machine (3DX Accuitomo, Morita, Kyoto, Japan) with a field of

view (FOV) with a diameter of 10 cm and height of 5.6 cm, acceleration voltage of 90 kV, beam current of 8.0 mA and voxel size of 0.2 mm at three different time points: preoperatively (T0), immediately after implant placement/GBR (T1) and 3 to 7 months after implant placement/GBR (T2) (Fig 3). The data were exported as DICOM files and a CBCT measurement protocol was established. To determine the preoperative alveolar ridge contour with respect to the implant position, the T1 DICOM data set was transferred to Mimics software (version 15.0, Materialise, Leuven, Belgium). After segmentation, the 3D models of the arch and implant were exported as stereolithography (STL) files and superimposed with the T0 DICOM data to calculate the implant-relative buccal contour at T0. A reference plane was set at the smooth-rough implant interface (Fig 4).

The following variables were measured on the bucco-oral cross-section perpendicular to the central axis of the implant^{26,27}:

- Buccal bone thickness (BBT-0 to BBT-6), which was the bone thickness buccal to the implant surface at 0, 2, 4 and 6 mm coronal to the reference plane), measured at T0, T1 and T2. Negative values were used for alveolar positions palatal or lingual to the buccal implant surface at T0.
- Buccal bone level (BBL), which was the vertical distance from the reference plane to the alveolar crest at the mid-buccal implant surface, measured at T0, T1 and T2. The virtually derived implant was used for the

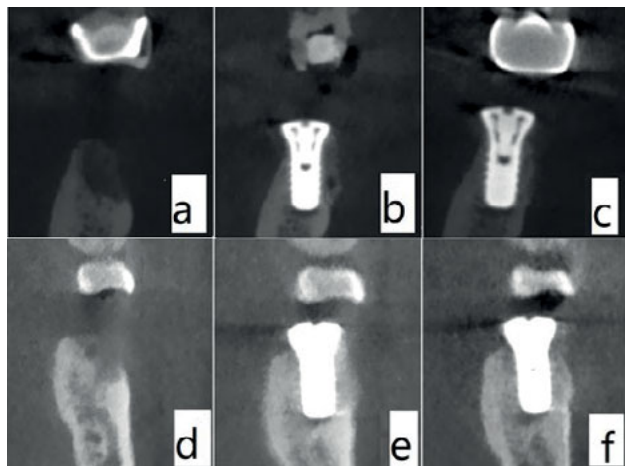


Fig 3 Alveolar ridge contour on the bucco-oral section at T0 (a and d), T1 (b and e) and T2 (c and f) in the control group (a to c) and test group (d to f).

T0 measurement. Negative values were used for hard tissue levels coronal to the reference plane.

- Buccal bone resorption (BBR-0 to BBR-6), which was the change in BBT from T1 to T2 at 0, 2, 4 and 6 mm coronal to the reference plane.
- BBL change (BBLC), which was the change in BBL from T1 to T2.

An experienced and calibrated assessor (Duan DH) performed the CBCT measurements, which were repeated twice and then averaged. Calibration was performed using 20 implant sites. The coefficients of intra-examiner repeatability for BBT and BBL were at least 0.90.

Statistical evaluation

Data from a previous study²⁸ were used to calculate the necessary sample size. In that study, the final horizontal bone thickness at 6 months was 1.66 mm in the membrane group and 1.02 mm in the non-membrane group²⁸. Using a free online calculator (<http://powerandsamplesize.com/Calculators/Compare-2-Means/2-Sample-Equality>) with a significance level of 0.05, standard deviation of 0.59 and a power of 80%, the number of patients per group required in this study was determined to be 14, to give a total of 28 patients.

Statistical analysis was performed using SPSS software (version 22.0, IBM, Armonk, NY, USA). The mean and standard deviation (SD) for each parameter were calculated for each of the three treatment groups. Parametric (Student *t* test, one-way analysis of variance [ANOVA]) or non-parametric tests (Mann-Whitney) were used to test the differences between the two groups, depending on the normal distribution of data. For cat-

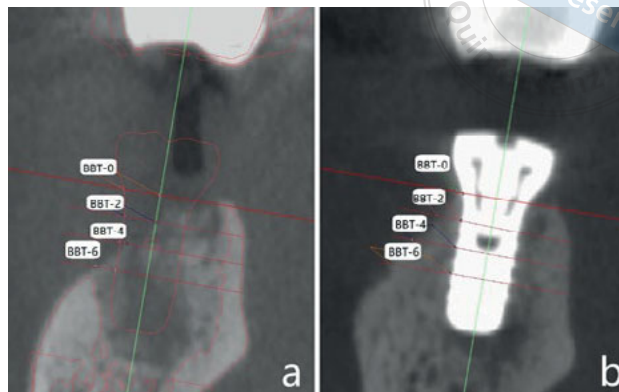


Fig 4 Measurement of the thickness of the buccal bone plate at different levels below the smooth-rough implant interface. (a) Measurement before surgery (registration with the CBCT mandible and implant model immediately after surgery). (b) measurement immediately and 5 months after surgery.

egorical variables, a chi-square analysis was used. The level of statistical significance was set at $P < 0.05$.

Results

The flowchart for the experiment is shown in Fig 5. A total of 61 patients were included in the initial screening, but 33 were excluded due to incompatibility with the eligibility criteria. A total of 28 patients with 28 implants were included for statistical analysis (control group, $n = 14$; test group, $n = 14$). The study population included 10 men (35.71%) and 18 women (64.29%), with a mean age of 44.11 ± 11.91 years (range 24 to 74 years) and a mean T1 to T2 interval of 5.21 ± 1.50 months (range 3 to 7 months) showing no significant differences between the two groups ($P > 0.05$). There were no significant differences in age, sex or healing time between the two groups ($P > 0.05$). Of the 28 dental implants, two were placed in maxillary molar sites (control group, $n = 0$; test group, $n = 2$), four in mandibular premolar sites (control group, $n = 1$; test group, $n = 3$), and 22 in mandibular molar sites (control group, $n = 13$; test group, $n = 9$); there were no significant differences in implant site distribution between the groups.

Table 1 presents the outcomes at each time point. At baseline (T0), there were no significant differences in BBT at any level or in BBL ($P > 0.05$) between the groups. The mean BBT-0 was -1.28 ± 0.91 mm in the control group and -1.37 ± 1.38 mm in the test group. The corresponding values for BBT-2 were 0.62 ± 0.90 mm and -0.30 ± 1.50 mm, respectively. The BBL, equivalent to the dehiscence length (apicocoronally), was -2.15 ± 2.45 mm in the control group and -1.53 ± 4.56 mm in the test group.

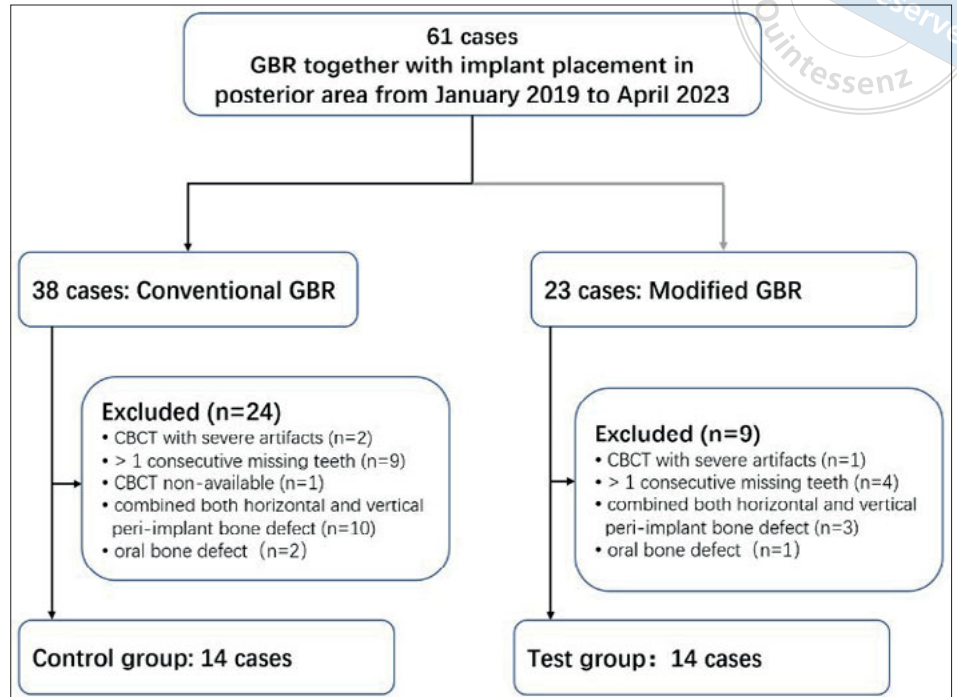


Fig 5 Experimental flowchart.

Table 1 Mean alveolar ridge dimensions at different time points.

Time point	Variable	Control group (n = 14)	Test group (n = 14)	Difference between groups	P value
T0	BBT-0, mm	-1.28 ± 0.91	-1.37 ± 1.38	0.10	0.828
	BBT-2, mm	0.62 ± 0.90	-0.30 ± 1.50	0.91	0.063
	BBT-4, mm	1.67 ± 1.29	0.94 ± 1.58	0.72	0.197
	BBT-6, mm	2.70 ± 1.61	1.74 ± 1.84	0.96	0.156
	BBL, mm	-2.15 ± 2.45	-1.53 ± 4.56	-0.62	0.661
T1	BBT-0, mm	3.83 ± 1.01	2.33 ± 0.66	1.50	0.000**
	BBT-2, mm	4.88 ± 1.15	3.60 ± 1.10	1.28	0.006**
	BBT-4, mm	5.34 ± 1.34	4.40 ± 1.44	0.93	0.088
	BBT-6, mm	5.18 ± 1.67	4.51 ± 1.63	0.67	0.292
	BBL, mm	1.80 ± 1.22	1.38 ± 0.59	0.42	0.266
T2	BBT-0, mm	1.38 ± 1.24	1.26 ± 0.55	0.11	0.755
	BBT-2, mm	2.79 ± 1.16	2.38 ± 0.94	0.41	0.318
	BBT-4, mm	3.97 ± 1.43	3.51 ± 1.32	0.46	0.388
	BBT-6, mm	4.39 ± 1.80	3.91 ± 1.48	0.48	0.450
	BBL, mm	0.49 ± 0.76	0.77 ± 0.71	-0.27	0.335
T1-T2	BBR-0, mm	2.45 ± 1.14	1.07 ± 0.51	1.38	0.001**
	BBR-2, mm	2.09 ± 0.94	1.22 ± 0.63	0.87	0.008**
	BBR-4, mm	1.36 ± 1.14	0.89 ± 0.75	0.48	0.202
	BBR-6, mm	0.79 ± 1.46	0.60 ± 0.55	0.19	0.649
	BBLC, mm	1.31 ± 1.10	0.62 ± 0.67	0.69	0.057
	BBR-0%	65.37 ± 26.62	45.70 ± 15.52	19.67	0.024*
	BBR-2%	43.49 ± 15.55	34.86 ± 15.39	8.62	0.152
	BBR-4%	25.56 ± 19.22	20.75 ± 15.43	4.81	0.472
BBR-6%	12.46 ± 33.63	12.74 ± 11.54	-0.29	0.976	

*P < 0.05, **P < 0.01

Immediately after surgery (T1), BBT-0 and BBT-2 were significantly different between groups ($P < 0.05$), with the control group showing statistically significantly greater BBT-0 (3.83 ± 1.01 mm) and BBT-2 (4.88 ± 1.15 mm) than the test group (2.33 ± 0.66 mm and 3.60 ± 1.10 mm, respectively). There was no significant difference in BBL between the groups at T1.

After 3 to 7 months (T2), there were no differences in BBT at any level or BBL between the groups ($P > 0.05$). From T1 to T2, the control group demonstrated statistically greater graft resorption in millimetres (BBR-0, 2.45 ± 1.14 mm and BBR-2, 2.09 ± 0.94 mm) and as a percentage (BBR-0% $65.37\% \pm 26.62\%$) than the test group (BBR-0 1.07 ± 0.51 mm, BBR-2 1.22 ± 0.63 mm, BBR-0% $45.70\% \pm 15.52\%$; $P = 0.001$, 0.008 and 0.024 , respectively); however, there were no differences in the percentage of buccal graft resorption or in BBL between the groups.

Discussion

This retrospective cohort study investigated the impact of intact periosteum on buccal ridge dimensions in the short term after simultaneous GBR and implant placement in single posterior sites. The conservative buccal pouch approach, introduced in this study, successfully increased BBT and resolved dehiscence defects, similar to the conventional flap design.

Designing flaps with vertical and periosteal releasing incisions for the purpose of achieving primary wound closure has been the preferred approach to GBR^{16,17}; however, incising the periosteum may have negative effects on GBR as it is composed of two layers: an inner cambium layer containing vascular and osteogenic cells, and an outer inelastic fibrous layer¹²⁻¹⁵. Additionally, violating the periosteal outer layer can result in a flap that is too weak to withstand pressure from the perioral muscles, potentially leading to apical graft displacement^{5,8,9}. Thus, surgeons may try to over-augment sites to compensate for bone graft resorption or use rigid support structures such as tenting screws, titanium plates and titanium mesh to mitigate bone graft displacement^{10,29,30}.

In the present study, over-augmentation in the test group was restricted due to the taut nature of the intact periosteal fibrous layer compared with the control group. This was reflected by significantly thicker buccal bone in the control group in terms of BBT-0 (3.83 ± 1.01 mm) and BBT-2 (4.88 ± 1.15 mm) than in the test group (2.33 ± 0.66 mm and 3.60 ± 1.10 mm, $P = 0.0000$ and $P = 0.006$, respectively); however, after 3 to 7 months of healing (T2), the BBT at all levels showed no significant

difference between the two groups with BBT-0 of less than 2 mm (1.38 ± 1.24 mm and 1.26 ± 0.55 mm in the control group and test group, respectively) and BBT-2 more of than 2 mm (2.79 ± 1.16 and 2.38 ± 0.94 mm in the control group and test group, respectively). From T1 to T2, patients with periosteal tension-reducing incisions (control group) showed more bone graft resorption in terms of BBR-0 (2.45 ± 1.14 mm), BBR-2 (2.09 ± 0.94 mm) and BBR-0% ($65.37 \pm 26.62\%$) than the test group (BBR-0 1.07 ± 0.51 mm, $P = 0.001$; BBR-2 1.22 ± 0.63 mm, $P = 0.008$; BBR-0% $45.70 \pm 15.52\%$, $P = 0.024$). These results indicated that the modified GBR technique could achieve comparable BBT, with less over-augmentation but in a minimally invasive manner, compared with the conventional approach. This difference in resorption could be due to the greater vascularisation and protection of the graft from the elements provided by an intact and inflexible periosteum.

As the present study was retrospective and non-randomised, with a limited number of patients, varying healing time intervals due to a delay in follow-ups caused by the COVID-19 pandemic and a disproportionate distribution of mandibular versus maxillary sites, caution is advised when interpreting the results. Additionally, the short follow-up period and lack of evaluation after re-entry further limit the study's findings. Thus, future randomised controlled trials with larger sample sizes and longer follow-up periods are needed to validate these findings and provide more conclusive evidence.

Conclusion

GBR can be performed using a surgically simple buccal pouch to treat dehiscence defects during implant placement in single posterior sites, and this technique may augment sites as well as GBR using a conventional flap; however, before recommending this technique for daily practice, long-term data after functional loading are necessary.

Conflicts of interest

The authors declare no conflicts of interest related to this study.

Author contribution

Dr Deng Hui DUAN performed the study and drafted the manuscript; Dr Hom Lay WANG revised the manuscript; Dr En Bo Wang supervised the study and all the authors approved the final submission.

(Received May 21, 2023; accepted Aug 21, 2023)

References

- Jung RE, Fenner N, Hämmerle CHF, Zitzmann NU. Long-term outcome of implants placed with guided bone regeneration (GBR) using resorbable and non-resorbable membranes after 12-14 years. *Clin Oral Implants Res* 2013;24:1065-1073.
- Thoma DS, Bienz SP, Figuero E, Jung RE, Sanz-Martin I. Efficacy of lateral bone augmentation performed simultaneously with dental implant placement: A systematic review and meta-analysis. *J Clin Periodontol* 2019;46(suppl 21):257-276.
- Hämmerle CHF, Jung RE, Feloutzis A. A systematic review of the survival of implants in bone sites augmented with barrier membranes (guided bone regeneration) in partially edentulous patients. *J Clin Periodontol* 2002;29(suppl 3):226-231; discussion 32-33.
- Fu JH, Oh TJ, Benavides E, Rudek I, Wang HL. A randomized clinical trial evaluating the efficacy of the sandwich bone augmentation technique in increasing buccal bone thickness during implant placement surgery: I. Clinical and radiographic parameters. *Clin Oral Implants Res* 2014;25:458-467.
- Benic GI, Thoma DS, Jung RE, et al. Guided bone regeneration with particulate vs. block xenogenic bone substitutes: a pilot cone beam computed tomographic investigation. *Clin Oral Implants Res* 2017;28:e262-e270.
- Jung EH, Jeong SN, Lee JH. Augmentation stability and early wound healing outcomes of guided bone regeneration in peri-implant dehiscence defects with L- and I-shaped soft block bone substitutes: A clinical and radiographic study. *Clin Oral Implants Res* 2021;32:1308-1317.
- Ye GH, Duan DH, Wang EB. Ridge volume stability of maxillary anterior implants placed with simultaneous lateral guided bone regeneration during healing: A radiographic analysis. *Chin J Dent Res* 2021;24:251-256.
- Mir-Mari J, Wui H, Jung RE, Hämmerle CHF, Benic GI. Influence of blinded wound closure on the volume stability of different GBR materials: An in vitro cone-beam computed tomographic examination. *Clin Oral Implants Res* 2016;27:258-265.
- Araújo MG, Carmagnola D, Berglundh T, Thilander B, Lindhe J. Orthodontic movement in bone defects augmented with Bio-Oss. An experimental study in dogs. *J Clin Periodontol* 2001;28:73-80.
- Duan DH, Wang HL, Xiao WC, Liu Z, Wang EB. Bone regeneration using titanium plate stabilization for the treatment of peri-implant bone defects: A retrospective radiologic pilot study. *Clin Implant Dent Relat Res* 2022;24:792-800.
- Nagy P, Molnar B, Nemes B, Schupbach P, Windisch P. Histologic evaluation of human intrabony periodontal defects treated with deproteinized bovine bone mineral in combination with orthodontic tooth movement: A case series. *Int J Periodontics Restorative Dent* 2019;40:321-330.
- Simon TM, Van Sickle DC, Kunishima DH, Jackson DW. Cambium cell stimulation from surgical release of the periosteum. *J Orthop Res* 2003;21:470-480.
- Al-Qtaitat A, Shore RC, Aaron JE. Structural changes in the ageing periosteum using collagen III immuno-staining and chromium labelling as indicators. *J Musculoskelet Neuronal Interact* 2010;10:112-123.
- Siems WF, Viehland LA, Hill HH Jr. Improved momentum-transfer theory for ion mobility. I. Derivation of the fundamental equation. *Anal Chem* 2012;84:9782-9791.
- Lin Z, Fateh A, Salem DM, Intini G. Periosteum: biology and applications in craniofacial bone regeneration. *J Dent Res* 2014;93:109-116.
- Arnal HM, Angioni CD, Gaultier F, Urbinelli R, Urban IA. Horizontal guided bone regeneration on knife-edge ridges: A retrospective case-control pilot study comparing two surgical techniques. *Clin Implant Dent Relat Res* 2022;24:211-221.
- Benic GI, Thoma DS, Muñoz F, Sanz Martin I, Jung RE, Hämmerle CHF. Guided bone regeneration of peri-implant defects with particulated and block xenogenic bone substitutes. *Clin Oral Implants Res* 2016;27:567-576.
- Urban IA, Sommer C, Wang IC, Wang HL. Periosteum classification and flap advancement techniques around the mental foramen. *Int J Periodontics Restorative Dent* 2022;42:753-759.
- Lee EA. Subperiosteal minimally invasive aesthetic ridge augmentation technique (SMART): A new standard for bone reconstruction of the jaws. *Int J Periodontics Restorative Dent* 2017;37:165-173.
- Kakar A, Kakar K, Sripathi Rao BH, et al. Lateral alveolar ridge augmentation procedure using subperiosteal tunneling technique: A pilot study. *Maxillofac Plast Reconstr Surg* 2018;40:3.
- Block MS, Degen M. Horizontal ridge augmentation using human mineralized particulate bone: Preliminary results. *J Oral Maxillofac Surg* 2004;62:67-72.
- Jeong SM, Choi BH, Li J, Xuan F. Simultaneous flapless implant placement and peri-implant defect correction: An experimental pilot study in dogs. *J Periodontol* 2008;79:876-880.
- Regidor E, Ortiz-Vigón A, Romandini M, Dionigi C, Derks J, Sanz M. The adjunctive effect of a resorbable membrane to a xenogeneic bone replacement graft in the reconstructive surgical therapy of peri-implantitis - A randomized clinical trial. *J Clin Periodontol* 2023;50:765-783.
- Monje A, Pons R, Vilarrasa J, Nart J, Wang HL. Significance of barrier membrane on the reconstructive therapy of peri-implantitis: A randomized controlled trial. *J Periodontol* 2023;94:323-335.
- Roos-Jansäker AM, Renvert H, Lindahl C, Renvert S. Surgical treatment of peri-implantitis using a bone substitute with or without a resorbable membrane: A prospective cohort study. *J Clin Periodontol* 2007;34:625-632.
- Benic GI, Bienz SP, Song YW, et al. Randomized controlled clinical trial comparing guided bone regeneration of peri-implant defects with soft-type block versus particulate bone substitutes: Six-month results of hard-tissue changes. *J Clin Periodontol* 2022;49:480-495.
- Jiang X, Zhang Y, Di P, Lin Y. Hard tissue volume stability of guided bone regeneration during the healing stage in the anterior maxilla: A clinical and radiographic study. *Clin Implant Dent Relat Res* 2018;20:68-75.
- Park SH, Lee KW, Oh TJ, Misch CE, Shotwell J, Wang HL. Effect of absorbable membranes on sandwich bone augmentation. *Clin Oral Implants Res* 2008;19:32-41.
- César Neto JB, Cavalcanti MC, Sapata VM, et al. The positive effect of tenting screws for primary horizontal guided bone regeneration: A retrospective study based on cone-beam computed tomography data. *Clin Oral Implants Res* 2020;31:846-855.
- Naenni N, Schneider D, Jung RE, Hüsler J, Hämmerle CHF, Thoma DS. Randomized clinical study assessing two membranes for guided bone regeneration of peri-implant bone defects: clinical and histological outcomes at 6 months. *Clin Oral Implants Res* 2017;28:1309-1317.