

Management of Separated Instruments Extruded into the Maxillary Sinus and Soft Tissue: a Case Series

Qian LIAO¹, Zi Meng HAN¹, Ru ZHANG¹, Ben Xiang HOU¹

Extrusion of separated endodontic instruments is a frustrating complication that can occur during root canal treatment and is difficult to handle. This report aimed to introduce different methods to retrieve such separated instruments through three cases with different locations of fragments. Fragments extruded completely into the maxillary sinus, partially into the maxillary sinus and lying in the soft tissue were retrieved using a lateral window approach, ultrasonic method and minimally invasive surgery, respectively. These methods can be recommended for retrieving fragments in certain cases.

Key words: lateral wall approach, maxillary sinus, separated instrument, soft tissue, ultrasonic technique

Chin J Dent Res 2022;25(1):67–73; doi: 10.3290/j.cjdr.b2752707

One of the complications involved endodontic therapy is instrument separation within root canals, or worse, extruded out of the apical foramen¹. Instruments may include dental burs, barbed broaches, Gates-Glidden drills, tips of hand instruments, lentulo paste fillers, files and reamers². Instrument separation causes stress to clinicians and anxiety in patients³. It often occurs in the mandibular molars due to the poor access, small diameter and sharp curvature of the root canals⁴. The separation rate has been reported in the range of 0.25% to 6.00% for stainless steel instruments, and 1.30% to 10.00% for NiTi rotary instruments^{1,5}. Instrument separation happens even to experienced clinicians and can frustrate both practitioners and patients.

Conventionally, several techniques have been attempted for removal of separated instruments, such as

the use of chemical solvent, micro forceps, wire loops, hypodermic surgical needles, file braiding, Masseran extractors (Micro-Mega, Besancon, France), the Canal Finder system (FaSociete Endo Technique, Marseille, France), lasers, electrochemical procedures and ultrasonic techniques⁶. The success rate of retrieval of separated instruments ranges between 66.6% and 100.0%⁷⁻⁹. It depends on many factors, such as tooth location, the separated instrument, the patient and the technique used^{1,10}. Unpredictable complications may occur during the retrieval of separated instruments¹¹.

Extrusion of separated instruments is a severe complication that is extremely difficult to handle, especially when fragments extrude into the maxillary sinus or soft tissue. Foreign bodies in the maxillary sinus can cause significant complications such as inflammatory reactions, sinusitis and fungal infections¹²⁻¹⁵, and these complications tend to aggravate if the foreign bodies are not removed^{12-14,16,17}. If the fragment migrates into the soft tissue, inflammation, infection and secondary trauma may occur. In general, prompt removal is necessary to avoid further damage to the surrounding tissues, particularly the vital nerves and blood vessels¹⁸⁻²¹.

This report aimed to discuss the management of separated instruments extruded into the maxillary sinus cavity and soft tissue using different methods.

¹ Department of Endodontics, School of Stomatology, Capital Medical University, Beijing, P.R. China.

Corresponding author: Dr Ben Xiang HOU, Department of Endodontics, School of Stomatology, Capital Medical University, No 4 Tian Tan XiLi, DongCheng District, Beijing 100050, P.R. China. Tel: 86-10-57099230. Email: Endohou@163.com

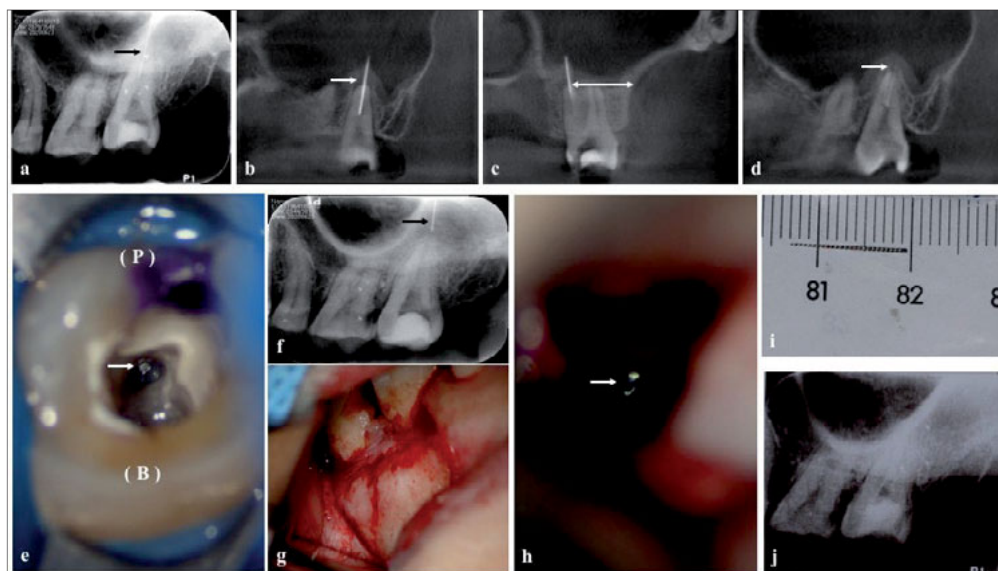


Fig 1 (a) A periapical radiograph revealed a fragment in the maxillary left second molar (black arrow). (b) Half of the fragment (approximately 6 mm) was extruded into the maxillary sinus (white arrow). (c) The distance between the root apex and the buccal cortex was 12.6 mm (white arrow). (d) Periapical periodontitis and fenestration of the maxillary floor could be observed (white arrow). (e) The fragment was located in the palatal canal (white arrow). (f) The fragment was extruded completely beyond the apex (black arrow). (g) The lateral wall of the maxillary sinus was

exposed after flap elevation. (h) The fragment was located in the maxillary sinus (white arrow). (i) Removal of the fragment. (j) A postoperative periapical radiograph revealed complete removal of the fragment. B, buccal; P, palatal.

Case reports

Case 1

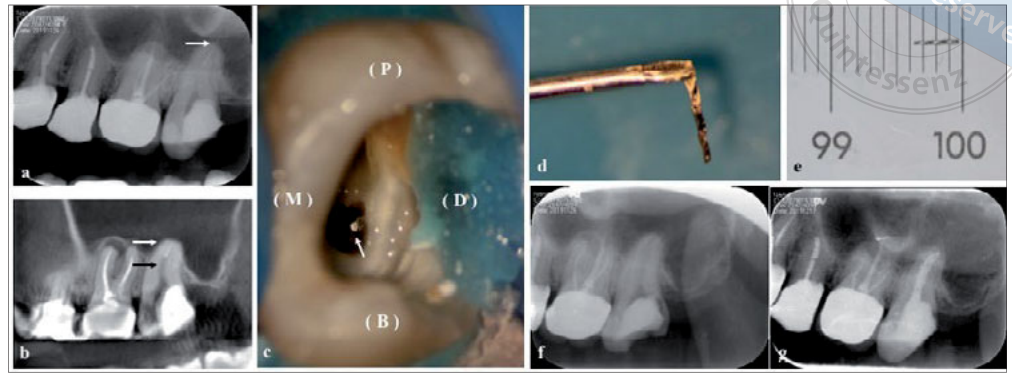
A 33-year-old woman was referred to the Department of Endodontics at Beijing Stomatological Hospital, Capital Medical University, for retrieval of a separated ultrasonic K15 file fragment. Her primary care dental practitioner had tried to retrieve the fragment but failed. Moreover, half of the fragment was extruded out of the apex (maxillary left second molar). The patient felt discomfort while chewing. Upon examination, the access cavity of the maxillary left second molar was filled with temporary material and was sensitive to percussion. The periapical radiograph and CBCT images revealed the presence of a fragment approximately 12.0 mm in size in the palatal canal, and half of it was in the maxillary sinus (Figs 1a and b). The measurement between the palatal root apex and the buccal cortex was approximately 12.6 mm (Fig 1c). Periapical periodontitis had resulted in bone loss between the palatal root apex and the maxillary sinus floor, and fenestration of the latter (Fig 1d).

The maxillary left second molar was isolated using rubber dam. After removal of the temporary filling, a straight-line access was modified so that the fragment could be seen through a dental operating microscope (Opmi 111, Carl Zeiss, Oberkochen, Germany) (Fig 1e). A staging platform was then prepared using a Satelec ET40 ultrasonic tip (Satelec Acteon, La Ciotat, France) until 2 to 3 mm of the fragment was exposed. An attempt

to grasp the fragment using endodontic micro forceps (Broken Instrument Removal Kit, Zumax, Jiangsu, China) was unsuccessful, and moreover, the fragment moved forwards apically. The staging and exposure steps were repeated, and an ET25 ultrasonic tip (Satelec Acteon) was placed between the fragment and the surrounding root canal dentinal wall and circulated around the fragment in an anticlockwise motion. The vibration transmitted to the fragment was supposed to loosen it and make it jump out, but unfortunately, the fragment extruded beyond the apex completely, which was confirmed on the periapical radiograph (Fig 1f). Due to the location of the fragment, a lateral window approach was chosen instead of conventional apical surgery. Prior to surgery, the canals were irrigated using 2.5% sodium hypochlorite and dried with paper points. The palatal canal was obturated with mineral trioxide aggregate and the buccal canals were filled with calcium hydroxide. The cavity was filled with glass ionomer.

Surgery was performed under local anaesthesia (4% articaine with 1:100,000 adrenaline). Horizontal incision was made in the sulcus from the mesiobuccal margin of the maxillary left first molar to the distobuccal margin of the maxillary left second molar, and a releasing incision was made on the mesial aspect of the maxillary left first molar. The mucoperiosteal flap was elevated to expose the lateral wall of the sinus (Fig 1g). Piezoelectric instruments (Piezosurgery; Mectron, Genoa, Italy) and a steel fissure bur were used to create a 1.0 × 0.8 cm bony window, including the

Fig 2 (a) A periapical radiograph revealed that there was a fragment in the maxillary left second molar, and it was extruded partly into the maxillary sinus (white arrow). (b) There was a curvature in the middle third of the buccal canal (black arrow) and the maxillary sinus floor was covered directly on the apical part of the maxillary left second molar (white arrow). (c) The fragment was against the distal wall of the buccal canal because of the curvature (black arrow). (d and e) Retrieval of the fragment. (f) A radiographic examination revealed complete removal of the fragment. (g) A periapical radiograph revealed obturation of the canals.



bony wall of the sinus and the underlying sinus membrane. The sinus cavity was directly under vision, and the fragment could be seen through a dental operating microscope (Fig 1h). The fragment was then removed using endodontic micro forceps (Fig 1i) and a radiograph was taken to confirm that removal had occurred (Fig 1j). The incision was closed with sutures, which were removed 1 week later. Oral antibiotics (250 mg Cefaclor, three times per day for 7 days) and analgesics (400 mg Ibuprofen sustained-release capsules, once a day if necessary) were prescribed postoperatively. After 2 weeks, the buccal canals were obturated with gutta percha, and full crown restoration was recommended.

Case 2

A 30-year-old woman with a separated file in the maxillary left second molar was referred to our department for retrieval of the fragment. It was a NiTi rotary file (25/0.06) that had fractured during a canal enlarging procedure. According to her dental history, the tooth was diagnosed as suffering from chronic pulpitis. The patient had no symptoms but felt anxious about future complications. The access of the tooth cavity was filled with temporary filling. The radiographic examination revealed a fragment in the apical part that was partially extruded into the maxillary sinus (Fig 2a). The CBCT images revealed a curvature in the middle third of the palatal canal, and the fragment was beneath the curvature (Fig 2b). There was no noticeable periapical periodontitis.

The ultrasonic method was chosen to retrieve the fragment. The tooth was isolated with rubber dam, the temporary filling was removed, and modification was performed to gain a straight-line access, as described in

case 1. The end of the file was against the mesial wall of the buccal canal because of the curvature (Fig 2c). The dentine of the inner wall was partly removed to ensure that the end of the fragment could be free in the canal, then a staging platform was prepared using an ET40 ultrasonic tip until 2 to 3 mm of the coronal fragment was exposed. The fragment was vibrated using an ET25 ultrasonic tip as described in case 1 until it jumped out (Figs 2d and e). Radiographic examination confirmed retrieval of the fragment (Fig 2f). Irrigation was done with 2.5% NaOCl, and canal shaping, cleaning and obturation were performed 1 week later (Fig 2g). All the procedures were performed with the aid of a dental operating microscope.

Case 3

A 45-year-old woman with a separated barbed broach lying in the soft tissue was referred to our department to retrieve the fragment. Her dental history revealed that she had suffered from crown fractures of the maxillary central incisors, and root canal treatment had been completed on both teeth. Instrument separation occurred during root canal treatment of the maxillary right central incisor (Fig 3a). The fragment migrated into labial or palatal tissue of the maxillary left central incisor (Figs 3a and b). Both teeth had temporary filling material (Fig 3c), with negative reactions to percussion and palpation. A CBCT scan taken 2 weeks previously revealed that the fragment was 8.5 mm in length, 0.8 mm (cervical point) and 3.6 mm (apical point) labially to the convex surface of the labial cortical plate of the maxillary left central incisor, respectively; 2.9 mm (cervical point) and 4.3 mm (apical point) perpendicularly to the incisive canal, respectively; and 11.7 mm (cervical point) and 20.2 mm

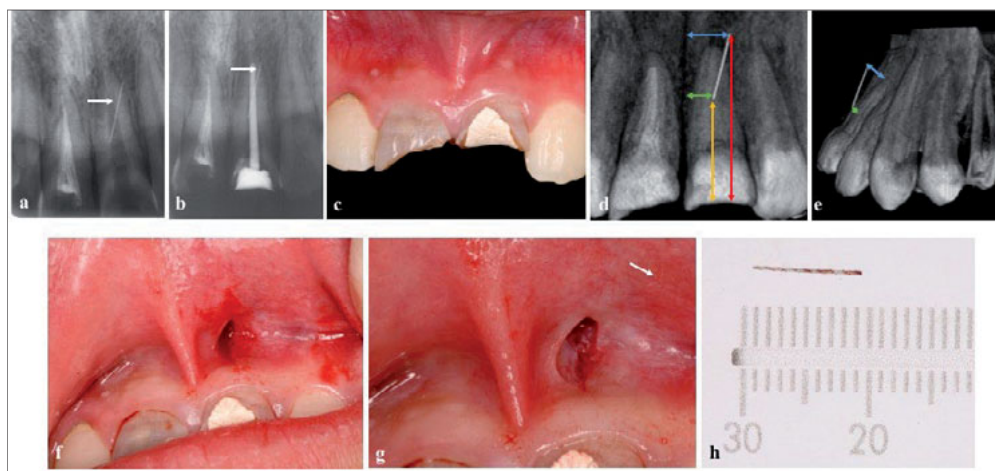
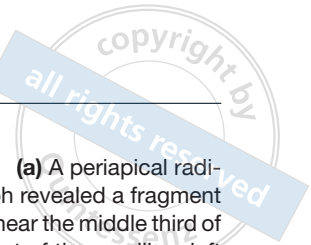


Fig 3 (a) A periapical radiograph revealed a fragment lying near the middle third of the root of the maxillary left central incisor (white arrow). (b) The fragment remained in the same position after root canal treatment on the maxillary left central incisor (white arrow). (c) The maxillary central incisors had crown fractures, and temporary filling material could be seen. (d) The measurements between the fragment and the incisive canal were 2.9 mm (green arrow) and 4.3 mm (blue arrow), and those between the fragment and the fractured margin were 11.7 mm (orange arrow) and 20.2 mm (red arrow). (e) The measurements between the fragment and the convex surface of the labial cortical plate of the maxillary left central incisor were 0.8 mm (green arrow) and 3.6 mm (blue arrow). (f) A small vertical incision was made based on the CBCT images. (g) The fragment was located in the mucosa (white arrow). (h) Retrieval of the fragment.

and those between the fragment and the fractured margin were 11.7 mm (orange arrow) and 20.2 mm (red arrow). (e) The measurements between the fragment and the convex surface of the labial cortical plate of the maxillary left central incisor were 0.8 mm (green arrow) and 3.6 mm (blue arrow). (f) A small vertical incision was made based on the CBCT images. (g) The fragment was located in the mucosa (white arrow). (h) Retrieval of the fragment.

(apical point) perpendicularly to the fractured margin, respectively (Figs 3d and e).

After confirming the location on the CBCT scan, a minimally invasive approach was designed to expose the apical part of the fragment. After rinsing the patient's mouth with 0.2% chlorhexidine solution, local anaesthesia (4% articaine with 1:100,000 adrenaline) was administered. A small vertical incision was made, measuring approximately 10.0 mm from the buccal vestibule of the maxillary left central incisor to the upper lip (Fig 3f); however, the fragment could not be found with the aid of a dental operating microscope as it had migrated further. Thus, another CBCT examination to relocate it was considered. Suddenly, part of the fragment was seen in the mucosa of the upper lip (Fig 3g), and the fragment was clamped out (Fig 3h). Sutures were performed, and were removed 7 days postoperatively.

Discussion

No agreement has been reached with regard to whether separated instruments have an effect on prognosis, but they do compromise the effectiveness of cleaning, shaping and obturation procedures¹. A study suggested that retained instruments do not affect the outcome of root canal treatment, but the presence of a preoperative periapical lesion reduces the rate of healing²². The presence of a separated instrument in the root canal makes patients anxious, and this can have a significant impact

on treatment outcomes and lead to treatment failure²³. A separated instrument lying in the soft tissue may migrate along with the muscle movement of the upper lip; this migration is particularly dangerous in the maxillofacial soft tissue. Thus, if periapical periodontitis exists, the patient is anxious or the separated instrument migrates into the soft tissue, it is advisable to remove the fragment.

There are various methods for retrieving separated instruments. Among them, the ultrasonic technique has been reported to be safe and successful^{8,24,25}. This technique can be used to retrieve instruments both from within the canals and partly extruded in the apical region²⁶. In case 1, the primary care dental practitioner had attempted to retrieve the fragment using the ultrasonic method; however, half of the fragment was extruded into the maxillary sinus. After clinical and CBCT examinations, we found that the palatal canal was large in diameter; thus, we tried using endodontic micro forceps and the ultrasonic method, but the separated file continued to move forwards into the sinus cavity. This may be due to the large diameter of the apical foramen and loss of the periapical bone.

The diameter of the palatal canal foramen of the maxillary left second molar has been reported to vary from 0.16 to 1.16 mm, with a mean diameter of 0.44 mm²⁷. In this case, the palatal canal foramen had a large diameter, as visualised through a dental operating microscope. This may be because of development and enlargement by periapical periodontitis or previ-

ous canal enlarging and shaping procedures. Loss of periapical bone due to periapical periodontitis was confirmed on the CBCT images. The diameter of the ultrasonic K15 file was also much smaller than that of the apical foramen. A large apical foramen and loss of periapical bone provide little resistance to the fragment; thus, the fragment was pushed out easily using the ultrasonic method.

In case 2, the separated instrument was also extruded partially into the sinus cavity, but the ultrasonic method was a good management option in this case. The main reasons for this may have been as follows: the mean diameters of the mesiobuccal and distobuccal canal foramen are 0.24 and 0.26 mm, respectively²⁷, smaller than that of the palatal canal. According to the patient's dental history, the tooth was diagnosed as affected by chronic pulpitis, which means that no periapical lesion existed as shown by the CBCT images, and there was no inflammatory destruction of the root apex. The NiTi fragment (25/0.06) was larger in diameter than that in case 1. Thus, the foramen and periapical bone could prevent the fragment from continuing to slip out of the apex in ultrasonic retrieval procedures.

If separated files extruded into the maxillary sinus cavity cannot be retrieved using an orthograde approach or conventional apical surgery, other methods can be attempted. Many effective methods to retrieve foreign bodies from the maxillary sinus have been reported^{17,28-30}. The Caldwell-Luc approach is the most commonly recommended method. It is a safe and fast procedure to open the canine fossa and gain access to the foreign body within the maxillary sinus^{30,31}. The lateral window approach, commonly used to increase bone height in dental implant surgery, is also considered safe, although complications may arise during or after surgery³². In case 1, the location and the small diameter of the fragment made it impossible to be seen using a Caldwell-Lu approach; thus, the lateral window approach was chosen. In this case, osteotomy was performed using a piezoelectric saw. Piezoelectric osteotomy has many advantages such as speed, precision and minimal bone loss³³⁻³⁵.

Endoscopy, also known as functional endoscopic surgery, is an important alternative to remove a foreign body from the maxillary sinus. There are two approaches for endoscopy: the nasal cavity approach³⁶ and the oral cavity approach³⁷⁻³⁹. The nasal cavity approach, by the middle nasal meatus or inferior nasal meatus, is minimally invasive, whereas the oral cavity approach requires a small incision in the canine fossa for the endoscope²⁸. The excellent illumination and magnification of the monitoring system makes the

surgical field clearly visible. Moreover, the technique offers the advantages of minimal surgical trauma, quick recovery and fewer complications⁴⁰⁻⁴². Wang et al⁴³ reported the successful removal of a pulp needle extruded in the maxillary sinus using this technique. In practice, however, control of the surgical field might be limited, and foreign bodies displaced in the posterior and/or upper part of the maxillary sinus are not easily reachable⁴⁴.

To retrieve separated instruments, the first step is to locate the fragment. CBCT examination can provide an accurate assessment of tooth morphology⁴⁵⁻⁴⁷ and locate fractured instruments^{48,49}. In case 1, CBCT images revealed the location of the palatal root apex and the fragment and aided in choosing the lateral window approach to remove the fragment. In case 2, the CBCT images revealed the curvature of the canal and the location of the fragment; thus, complications such as perforation were avoided during the retrieval procedure. In case 3, CBCT images revealed the precise location of the fragment, which helped to make a minimally invasive incision to remove the fragment. Unexpectedly, the fragment could not be found through the incision, as it had migrated further after CBCT examination, probably during surgery for retraction of the upper lip. Any movement of the upper lip such as talking may also lead to migration. If the fragment cannot be located during surgery, another CBCT examination is necessary. During surgery, violent retraction should be avoided in case the separated fragment migrates to another place. Fortunately, in the present case, the fragment migrated to the mucosa of the upper lip and could be seen and removed easily.

Conclusion

When separated instruments are partially extruded into the maxillary sinus, the ultrasonic method can be used in cases where the apical foramen has a small diameter, the fragment has a large diameter, and periapical bone exists. Surgery is required when fragments have been extruded completely into the maxillary sinus. If conventional apical surgery is not possible, the lateral window approach is a management option. When separated files migrate into the soft tissue, minimally invasive surgery can be an option, to try to prevent the separated fragments from migrating to other places during surgery.

Conflicts of interest

The authors declare no conflicts of interest related to this study.

Author contribution

Drs Qian LIAO and Zi Meng HAN took part in the surgical procedures and drafted the manuscript; Dr Ru ZHANG revised the manuscript; Dr Ben Xiang HOU performed all the surgical procedures and approved the final manuscript.

(Received Mar 26, 2021; accepted Sep 07, 2021)

References

- Madarati AA, Hunter MJ, Dummer PM. Management of intracanal separated instruments. *J Endod* 2013;39:569–581.
- McCoy T. Managing endodontic instrument separation. *J Vet Dent* 2015;32:262–265.
- Pine J. What happens if you break a file during a root canal procedure? *Oral Health* 1996;86:29.
- Yousuf W, Khan M, Mehdi H. Endodontic procedural errors: Frequency, type of error, and the most frequently treated tooth. *Int J Dent* 2015;2015:673914.
- Cohen S, Hargreaves K (eds). *Pathways of the pulp*, ed 11. Kansas: Elsevier, 2016.
- Pruthi PJ, Nawal RR, Talwar S, Verma M. Comparative evaluation of the effectiveness of ultrasonic tips versus the Terauchi file retrieval kit for the removal of separated endodontic instruments. *Restor Dent Endod* 2020;45:e14.
- Gencoglu N, Helvacioğlu D. Comparison of the different techniques to remove fractured endodontic instruments from root canal systems. *Eur J Dent* 2009;3:90–95.
- Shahabinejad H, Ghassemi A, Pishbin L, Shahravan A. Success of ultrasonic technique in removing fractured rotary nickel-titanium endodontic instruments from root canals and its effect on the required force for root fracture. *J Endod* 2013;39:824–828.
- Ward JR, Parashos P, Messer HH. Evaluation of an ultrasonic technique to remove fractured rotary nickel-titanium endodontic instruments from root canals: An experimental study. *J Endod* 2003;29:756–763.
- Iqbal MK, Kohli MR, Kim JS. A retrospective clinical study of incidence of root canal instrument separation in an endodontics graduate program: A PennEndo database study. *J Endod* 2006;32:1048–1052.
- Souter NJ, Messer HH. Complications associated with fractured file removal using an ultrasonic technique. *J Endod* 2005;31:450–452.
- Burnham R, Bridle C. Aspergillosis of the maxillary sinus secondary to a foreign body (amalgam) in the maxillary antrum. *Br J Oral Maxillofac Surg* 2009;47:313–315.
- Selmani Z, Ashammakhi N. Surgical treatment of amalgam fillings causing iatrogenic sinusitis. *J Craniofac Surg* 2006;17:363–365.
- Macan D, Cabov T, Kobler P, Bumber Z. Inflammatory reaction to foreign body (amalgam) in the maxillary sinus misdiagnosed as an ethmoid tumor. *Dentomaxillofac Radiol* 2006;35:303–306.
- Ueda M, Kaneda T. Maxillary sinusitis caused by dental implants: Report of two cases. *J Oral Maxillofac Surg* 1992;50:285–287.
- Felisati G, Lozza P, Chiapasco M, Borloni R. Endoscopic removal of an unusual foreign body in the sphenoid sinus: An oral implant. *Clin Oral Implants Res* 2007;18:776–780.
- Ucer TC. A modified transantral endoscopic technique for the removal of a displaced dental implant from the maxillary sinus followed by simultaneous sinus grafting. *Int J Oral Maxillofac Implants* 2009;24:947–951.
- Callegari L, Leonardi A, Bini A, et al. Ultrasound-guided removal of foreign bodies: Personal experience. *Eur Radiol* 2009;19:1273–1279.
- Lammers RL. Soft tissue foreign bodies. *Ann Emerg Med* 1988;17:1336–1347.
- Lammers RL, Magill T. Detection and management of foreign bodies in soft tissue. *Emerg Med Clin North Am* 1992;10:767–781.
- Yang XJ, Xing GF, Shi CW, Li W. Value of 3-dimensional CT virtual anatomy imaging in complex foreign body retrieval from soft tissues. *Korean J Radiol* 2013;14:269–277.
- Spili P, Parashos P, Messer HH. The impact of instrument fracture on outcome of endodontic treatment. *J Endod* 2005;31:845–850.
- Chatzopoulos GS, Koidou VP, Lunos S, Wolff LF. Implant and root canal treatment: Survival rates and factors associated with treatment outcome. *J Dent* 2018;71:61–66.
- Fu M, Zhang Z, Hou B. Removal of broken files from root canals by using ultrasonic techniques combined with dental microscope: A retrospective analysis of treatment outcome. *J Endod* 2011;37:619–622.
- Fu M, Huang X, Zhang K, Hou B. Effects of ultrasonic removal of fractured files from the middle third of root canals on the resistance to vertical root fracture. *J Endod* 2019;45:1365–1370.
- Agrawal V, Kapoor S, Patel M. Ultrasonic technique to retrieve a rotary nickel-titanium file broken beyond the apex and a stainless steel file from the root canal of a mandibular molar: A case report. *J Dent (Tehran)* 2015;12:532–536.
- Wolf TG, Paqué F, Sven Patyna M, Willershausen B, Briseño-Marroquín B. Three-dimensional analysis of the physiological foramen geometry of maxillary and mandibular molars by means of micro-CT. *Int J Oral Sci* 2017;9:151–157.
- Hara Y, Shiratsuchi H, Tamagawa T, et al. A large-scale study of treatment methods for foreign bodies in the maxillary sinus. *J Oral Sci* 2018;60:321–328.
- Kim SM. The removal of an implant beneath the optic canal by modified endoscopic-assisted sinus surgery. *Eur Arch Otorhinolaryngol* 2017;274:1167–1171.
- Huang IY, Chen CM, Chuang FH. Caldwell-Luc procedure for retrieval of displaced root in the maxillary sinus. *Oral Surg Oral Med Oral Pathol Oral Radiol Endod* 2011;112:e59–e63.
- Ong JC, De Silva RK, Tong DC. Retrieval of a root fragment from the maxillary sinus--An appreciation of the Caldwell-Luc procedure. *N Z Dent J* 2007;103:14–16.
- Tikel HC, Tatli U. Risk factors and clinical outcomes of sinus membrane perforation during lateral window sinus lifting: Analysis of 120 patients. *Int J Oral Maxillofac Surg* 2018;47:1189–1194.
- Sohn DS, Ahn MR, Lee WH, Yeo DS, Lim SY. Piezoelectric osteotomy for intraoral harvesting of bone blocks. *Int J Periodontics Restorative Dent* 2007;27:127–131.
- Sohn DS. *Color Atlas, Clinical Applications of Piezoelectric Bone Surgery*. Seoul: Kunja Publishing Co, 2008.
- Lee HJ, Ahn MR, Sohn DS. Piezoelectric distraction osteogenesis in the atrophic maxillary anterior area: A case report. *Implant Dent* 2007;16:227–234.
- Kitamura A, Zeredo JL. Migrated maxillary implant removed via semilunar hiatus by transnasal endoscope. *Implant Dent* 2010;19:16–20.
- Pagella F, Emanuelli E, Castelnovo P. Endoscopic extraction of a metal foreign body from the maxillary sinus. *Laryngoscope* 1999;109:339–342.
- Iida S, Tanaka N, Kogo M, Matsuya T. Migration of a dental implant into the maxillary sinus. A case report. *Int J Oral Maxillofac Surg* 2000;29:358–359.
- Nogami S, Yamauchi K, Tanuma Y, et al. Removal of dental implant displaced into maxillary sinus by combination of endoscopically assisted and bone repositioning techniques: A case report. *J Med Case Rep* 2016;10:1.

40. Matti E, Emanuelli E, Pusateri A, Muniz CC, Pagella F. Transnasal endoscopic removal of dental implants from the maxillary sinus. *Int J Oral Maxillofac Implants* 2013;28:905–910.
41. Manfredi M, Fabbri C, Gessaroli M, Morolli F, Stacchini M. Surgical fenestrated approach to the maxillary sinus like alternative to Caldwell-Luc technique. *Minerva Stomatol* 2019;68:308–316.
42. Levin M, Sommer DD. Endoscopic removal of ectopic sinonasal teeth: A systematic review. *J Otolaryngol Head Neck Surg* 2019;48:30.
43. Wang Y, Zhu J, Ma Z. Two rare case report of maxillary sinus foreign body [in Chinese]. *Lin Chung Er Bi Yan Hou Tou Jing Wai Ke Za Zhi* 2015;29:2011–2012.
44. Biglioli F, Chiapasco M. An easy access to retrieve dental implants displaced into the maxillary sinus: The bony window technique. *Clin Oral Implants Res* 2014;25:1344–1351.
45. Patel S, Dawood A, Ford TP, Whaites E. The potential applications of cone beam computed tomography in the management of endodontic problems. *Int Endod J* 2007;40:818–830.
46. Patel S. New dimensions in endodontic imaging: Part 2. Cone beam computed tomography. *Int Endod J* 2009;42:463–475.
47. Venskutonis T, Plotino G, Juodzbaly G, Mickevičienė L. The importance of cone-beam computed tomography in the management of endodontic problems: A review of the literature. *J Endod* 2014;40:1895–1901.
48. Tyndall DA, Kohltfarber H. Application of cone beam volumetric tomography in endodontics. *Aust Dent J* 2012;57(suppl 1):72–81.
49. American Association of Endodontists, American Academy of Oral and Maxillofacial Radiology. Use of cone-beam computed tomography in endodontics Joint Position Statement of the American Association of Endodontists and the American Academy of Oral and Maxillofacial Radiology. *Oral Surg Oral Med Oral Pathol Oral Radiol Endod* 2011;111:234–237.