



Werner Schupp

Werner Schupp, Julia Haubrich, Kenji Ojima, Chisato Dan, Yuriko Kumagai, Sumimasa Otsuka

Accelerated Invisalign treatment of patients with a skeletal Class III

Key words *accelerated aligner treatment, aligner treatment, Class III treatment, distalization in the mandibular arch, Invisalign, skeletal anchorage*

In skeletal Class III patients, severe disharmony of the maxilla and mandible is corrected surgically. However, there is a wide variety of criteria for this surgery and practitioners must often select a non-surgical treatment if requested by the patient. In such a situation, in patients where anterior crowding is accompanied by anterior crossbite, a common treatment involves improvement through mandibular pre-molar extraction and lingual inclination of the mandibular incisors¹. In addition, expansion of the maxillary dental arch is an effective technique. However, from an aesthetic point of view, patients occasionally choose a multi-bracket appliance, even on the lingual side, in favour of a removable device. Just a few years ago, when compared with multi-bracket treatments, aligners usually required longer treatment times and the lack of precise control of axial movement

led some to suggest that cases treated with aligners must be chosen carefully².

Since 2010, when Schupp et al presented a successful treatment of class II relationship using the Invisalign system with non-extraction, but molar distalization³, more and more practices have begun to treat patients previously believed to need extraction with a non-extraction distalization approach⁴⁻⁶. Compared with case reports on the distalization of maxillary molars, the number of mandibular-molar distalization case reports is lower⁷, and clear data (molar distalization distance limits) have not yet been presented.

This article reports two patient examples. In the first, we used the Invisalign technique only, changing the aligners every 7 days. The second patient example shows a non-surgical treatment of a severe skeletal Class III using a combination of aligners with temporary anchorage devices (TADs)⁸ and AcceleDent⁹⁻¹¹ (OrthoAccel Technologies, Inc, 6575 West Loop South, USA)] obtaining more effective and faster mandibular molar distalization.

Werner Schupp, Dr. med. dent
Fachpraxis für Kieferorthopädie, Hauptstraße 50, 50996, Köln

Julia Haubrich, Dr. med. dent.
Fachpraxis für Kieferorthopädie, c/o Schupp, Hauptstraße 50, 50996 Köln

Kenji Ojima, D.D.S
2-39-5-2F Kataoka Build. Hongo, Bunkyo-Ku/Tokyo/Japan

Chisato Dan, D.D.S
2-39-5-2F Kataoka Build. Hongo, Bunkyo-Ku/Tokyo/Japan

Yuriko Kumagai, D.D.S
2-39-5-2F Kataoka Build. Hongo, Bunkyo-Ku/Tokyo/Japan

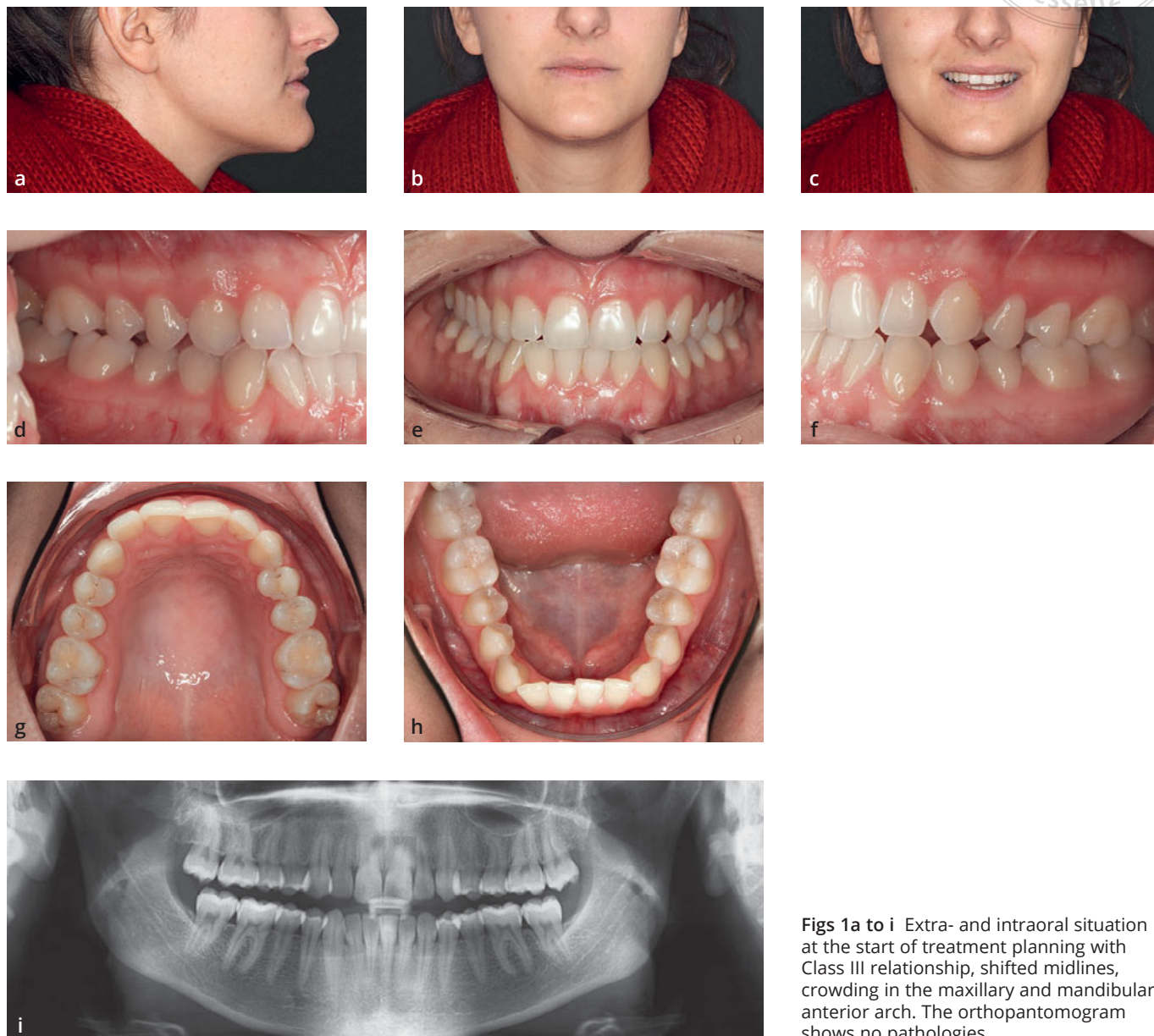Sumimasa Otsuka, D.D.S, PhD.
1-22-5-3F Nakazawa Build. Higashi Gotanda/Shinagawa-ku/Tokyo/Japan

Correspondence to: Dr Werner Schupp
E-Mail: schupp@schupp-ortho.de

Example 1 (Team Schupp/Haubrich)

Diagnosis

The 26-year old female patient presented herself with a skeletal Class III relationship, crowding in the maxillary and mandibular arches, with restricted maxillary arch forms and retrally inclined maxillary and mandibular



Figs 1a to i Extra- and intraoral situation at the start of treatment planning with Class III relationship, shifted midlines, crowding in the maxillary and mandibular anterior arch. The orthopantomogram shows no pathologies.

incisors. The mandibular midline was shifted to the right. As shown in Figure 2, the patient had severe incisor contacts on the lateral and frontal incisors. The patient's mouth opening was 48 mm without deviation. The manual examination of the TMJ did not show clicking, crepitation or pain with palpation in the *porus acusticus externus*. The extraoral pictures demonstrate a concave face with a prognathic chin. The lower lip is protrusive to the upper lip. From the anterior view the face is symmetrical, with the chin in the facial midline.

Treatment goal

The patient is a professional singer and asked for non-surgical treatment. The orthodontic treatment plan included alignment of the arches, distalization of the mandibular molars, premolars and canines into a class I relationship and creating space for alignment of mandibular anteriors to obtain a physiological overjet and overbite, as well as midline correction. The maxillary arch needed expansion and the maxillary incisors were planned to torque.

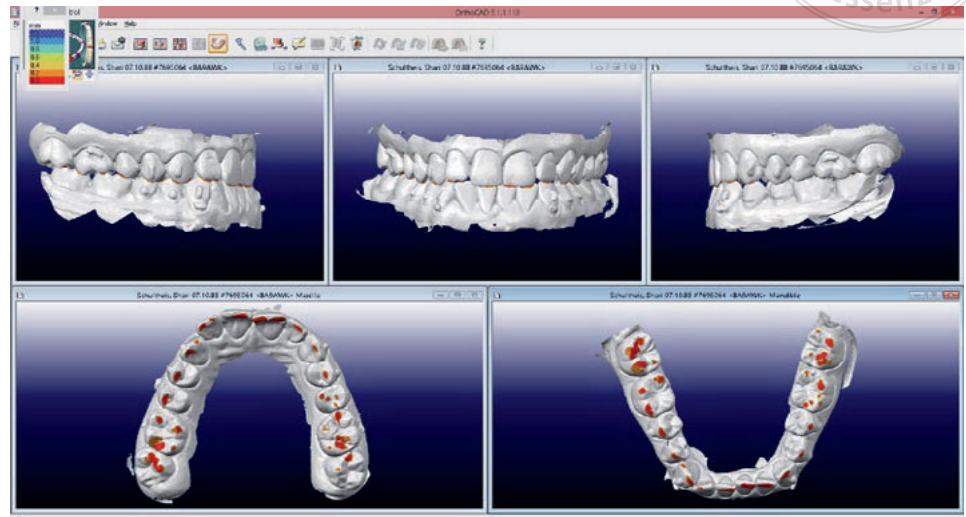
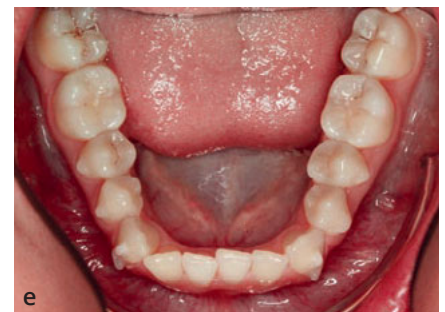
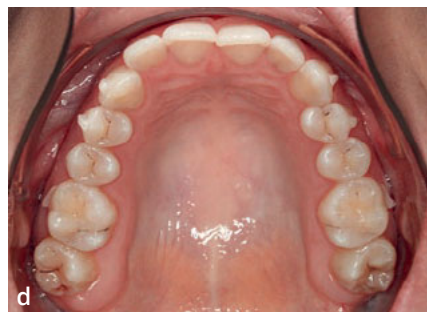
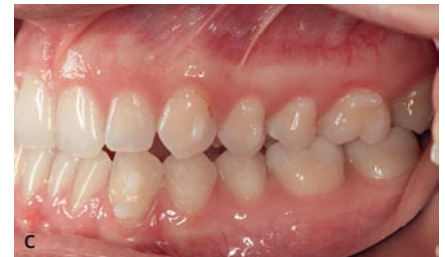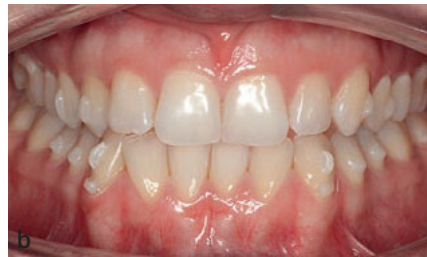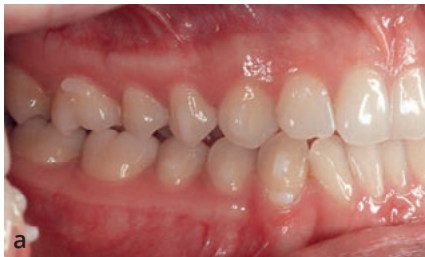Fig 2 Initial scan with occlusal contact points on all teeth with malocclusion contacts on all incisors.



Figs 3a to e Intraoral situation with bonded attachments on teeth 13, 14, 23, 24, 33, 34, 35, 43, 44, 45 and hooks on teeth 16, 26, 33, 43 for Class III elastics.

Treatment alternatives

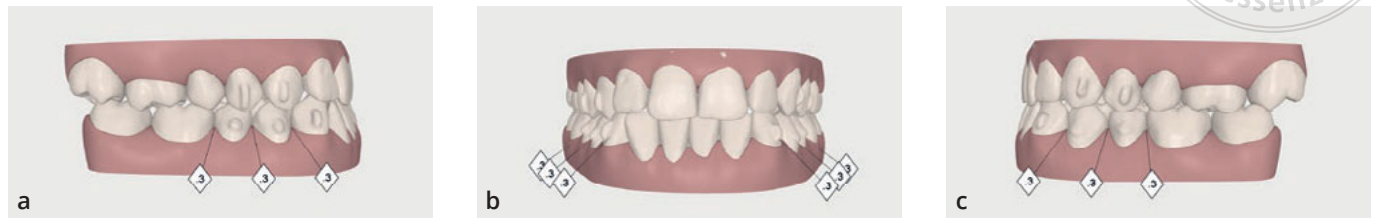Obviously, an orthognathic surgical procedure would have been possible for this patient, and bimaxillary surgery would have altered her profile into a standard aspect. If the patient had desired such a procedure, the "Surgery First" procedure proposed by Sugawara¹² would have been an option. Another alternative would be extraction therapy in the mandible.

Because of the patient's career as a professional singer, a multi-bracket appliance was not an alternative either lin-

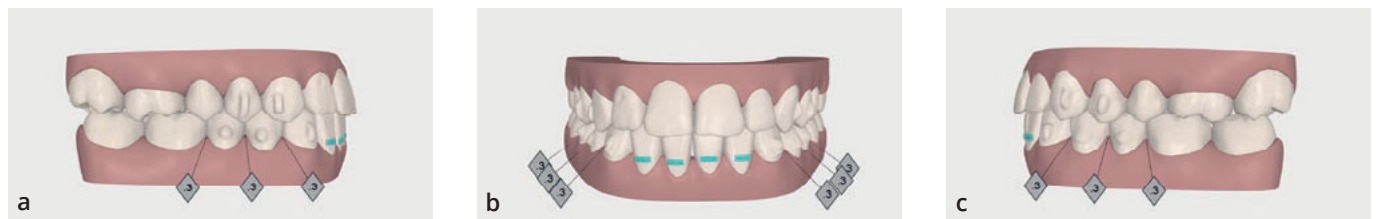gually or buccally. The patient did not want to change her extraoral appearance; a fixed appliance was not possible due to her profession, so the only possible alternative was aligner therapy.

Treatment progression

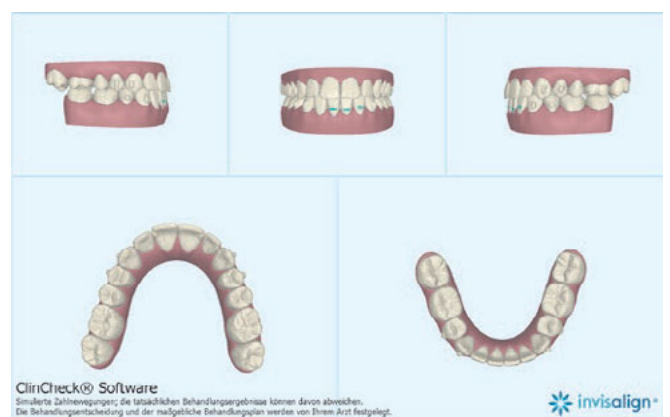
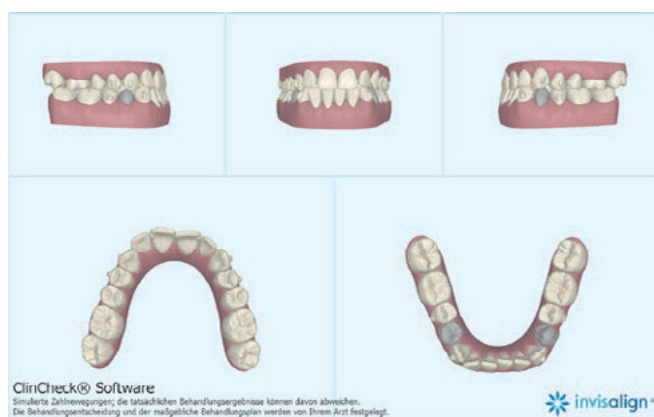
The treatment was planned with the Invisalign technique, including Class III elastics for anchorage on mandibular canines to maxillary first molars. The treatment consisted of 30 aligners in the maxillary and 60 aligners in the mandibular



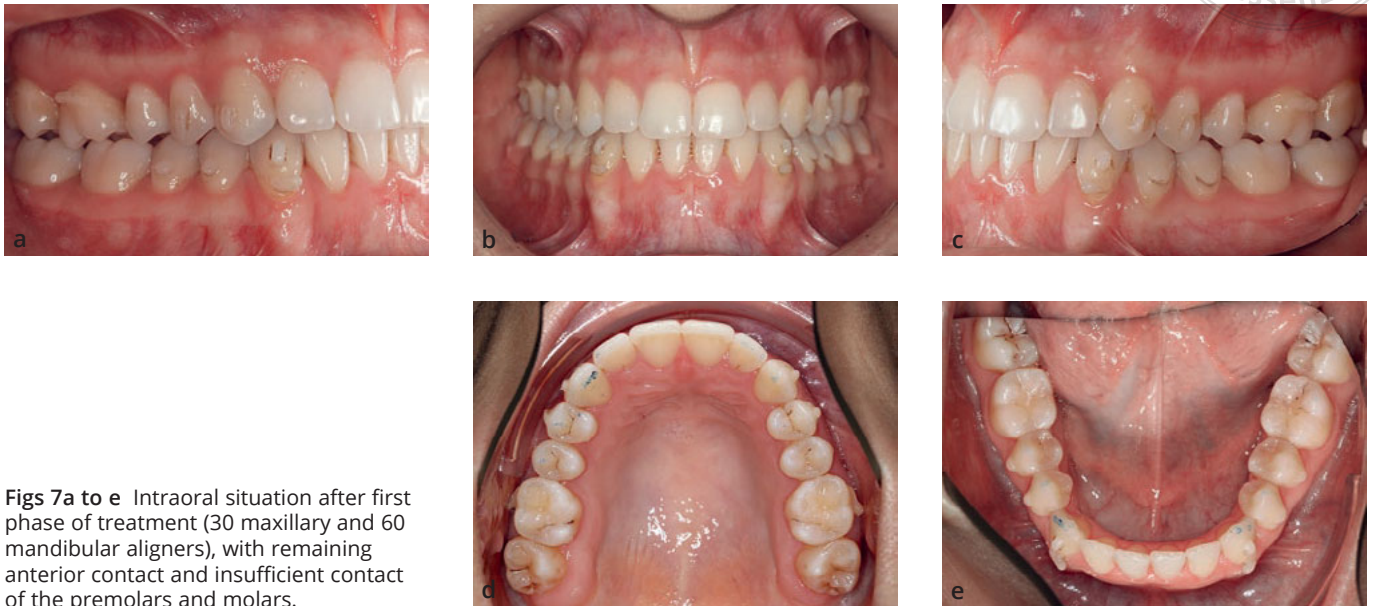Figs 4a to e ClinCheck software showing the initial intraoral situation in Class III relationship and planned IPR on mandibular premolars with a maximum of 0.3 mm.



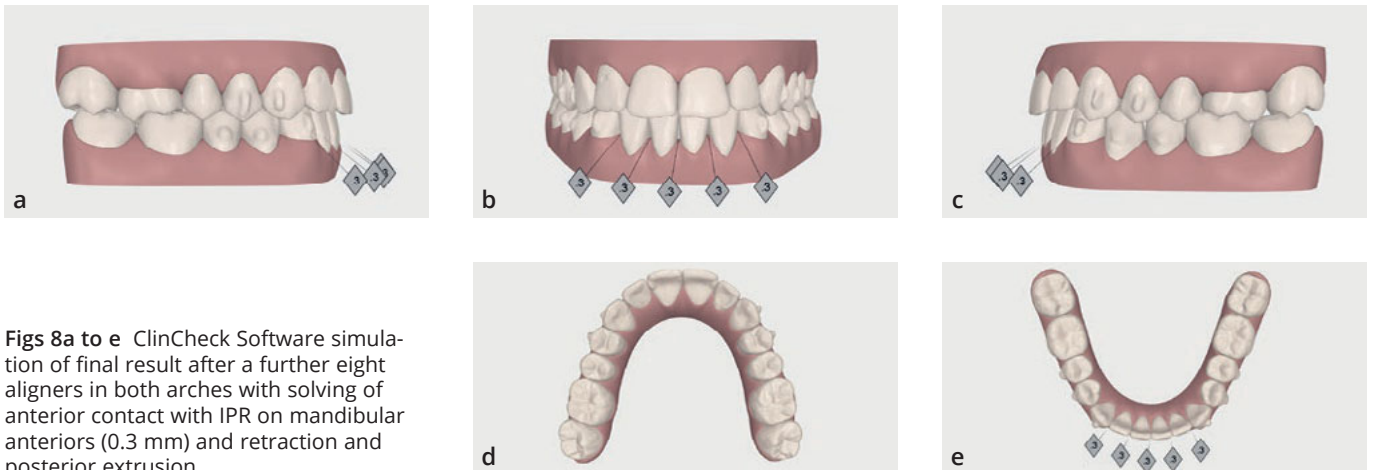
Figs 5a to e Planned final situation in the ClinCheck Software after 30 aligners in the maxillary arch and 60 aligners in the mandibular arch after distalization in the mandibular arch and additional IPR on mandibular premolars with a maximum of 0.3 mm.



Figs 6a and b Non-accepted ClinCheck Software alternative with planned extraction of teeth 34, 44. The planned extraction of teeth 34, 44 counted 48 aligners with reciprocal space closure in the mandibular arch to end in a class I canine relationship. Due to the mesial movement of the mandibular molars, maxillary second molars would not have shown occlusal contact as a final result. The mesial movement of mandibular molars as shown in this ClinCheck Software version is not predictable and needs additional skeletal anchorage to obtain a more predictable movement. The planned treatment with extraction of mandibular first premolars as shown in this ClinCheck Software version was not accepted, as it did not seem a valuable alternative treatment plan in this patient.



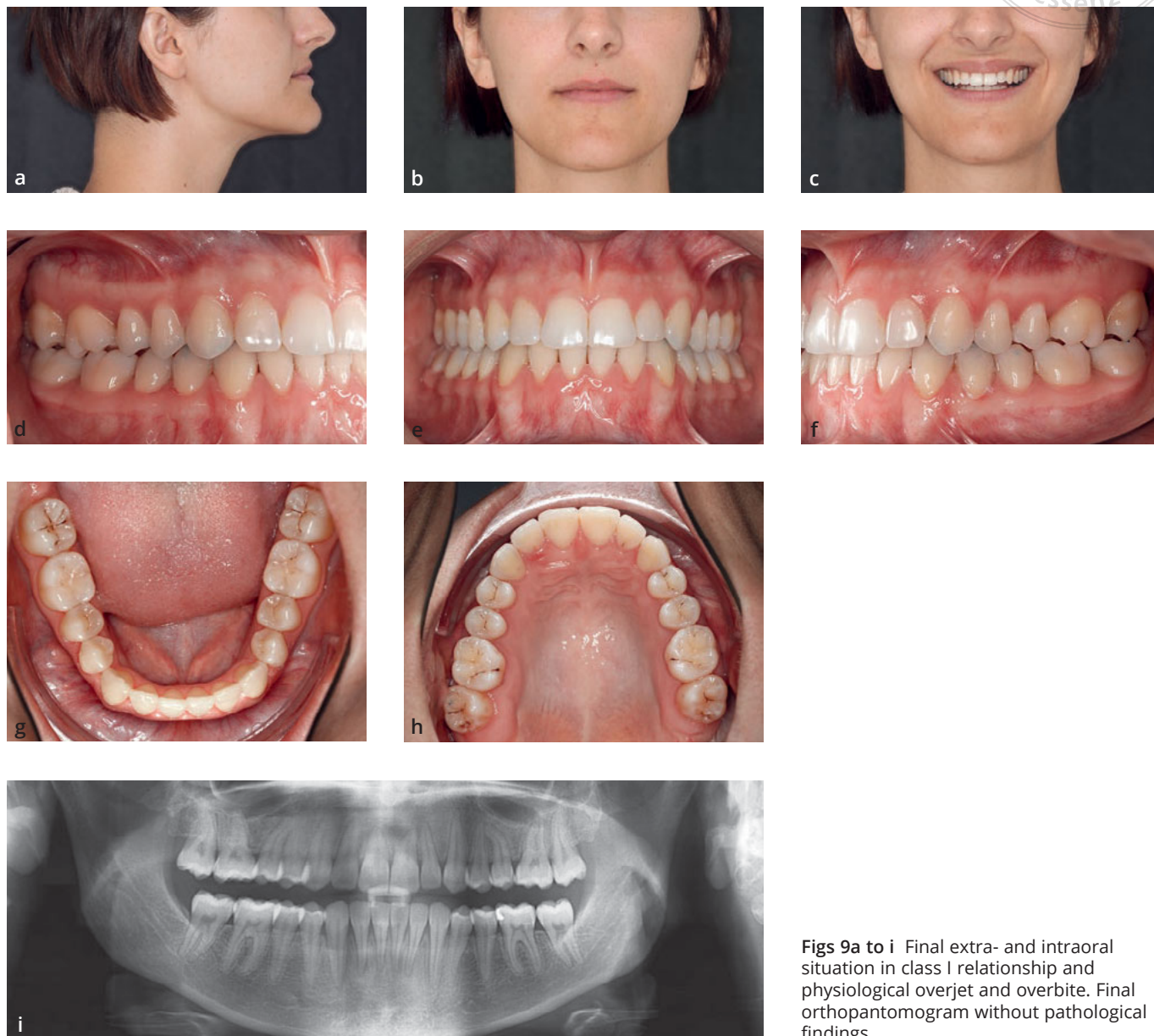Figs 7a to e Intraoral situation after first phase of treatment (30 maxillary and 60 mandibular aligners), with remaining anterior contact and insufficient contact of the premolars and molars.



Figs 8a to e ClinCheck Software simulation of final result after a further eight aligners in both arches with solving of anterior contact with IPR on mandibular anteriors (0.3 mm) and retraction and posterior extrusion.

arch for phase one and another eight aligners added in the second phase. This is rather a high number of aligners due to the complex distalization in the mandibular arch. The patient did not receive TADs, which might have improved the anchorage, but the patient was asked to wear Class III elastics at night and for 3 h during the day. To avoid a potentially heavy load on the TMJ, elastics with minimal force were used (0.8 Ng). Temporary anchorage devices can avoid potential load on the TMJs in Class III patients with craniomandibular disorders (CMD), and are therefore highly recommended for these patients.

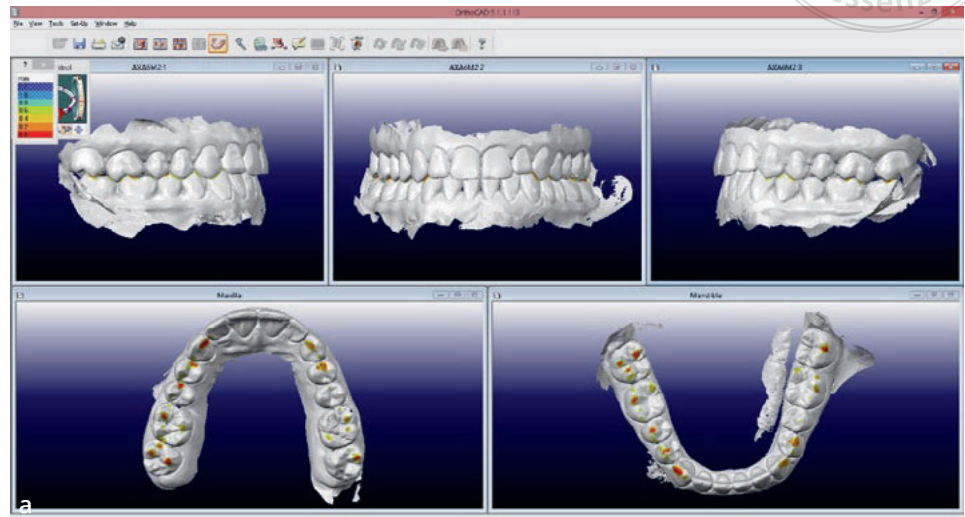
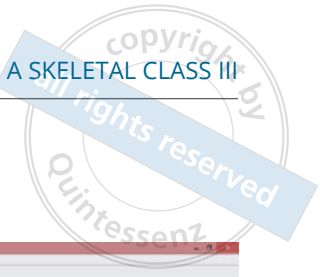
Figure 1 shows the intraoral situation with skeletal Class III relationship, crowding in the maxillary and mandibular arches with restricted maxillary arch form and retraction of maxillary and mandibular incisors and a mandibular midline shift to the right at the start of treatment. As shown in Figure 2, the patient had severe incisor contacts on the lateral and anterior incisors. The initial orthopantomogram showed no pathologies (Fig 1). Figure 2 shows the situation accordingly in the initial scan with occlusal contacts on all posteriors and non-physiological contacts on the incisors. There were bonded



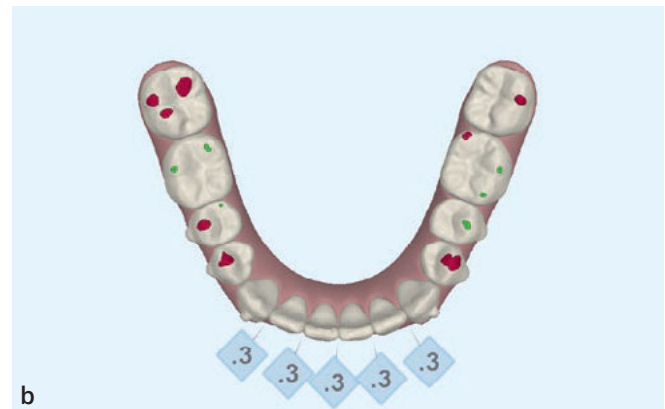
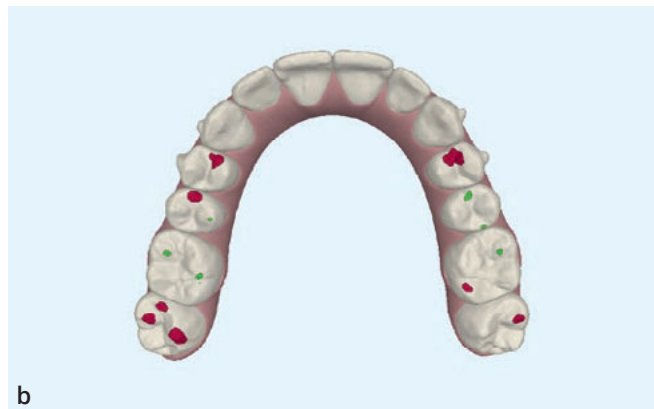Figs 9a to i Final extra- and intraoral situation in class I relationship and physiological overjet and overbite. Final orthopantomogram without pathological findings.

attachments on teeth 13, 14, 23, 24, 33, 34, 35, 43, 44, 45 and hooks on teeth 16, 26, 33, 43 for Class III elastics. The hooks and attachments shown in Figure 3 are made individually using OptiBond FL (Kerr Dental, Biberach, Germany) and built with the composite Enamel Plus HFO (GDF?). The initial ClinCheck Software situation (Align Technology, San Jose, California, USA) is shown in Figure 4. Figure 5 demonstrates the planned final situation in the ClinCheck Software (Align Technology) after planned distalization in the mandibular arch into a full class I relation-

ship and alignment of the arches. Figure 6 shows an additional treatment plan simulated in the ClinCheck Software with planned extraction of mandibular premolars, to obtain an alternative treatment option for the patient. The planned extraction of teeth 34 and 44 included 48 aligners with reciprocal space closure in the mandibular arch to end in a class I canine relationship. There is a great need for mesial movement of the mandibular molars. This movement, as shown in this planned version of the ClinCheck Software, is not predictable and would need



Figs 10a and b Final Scan situation with occlusal contact points. a) Compared to final planned ClinCheck Software with same according contact point situation; b) Showing a predictable outcome of the planned treatment in the ClinCheck Software.

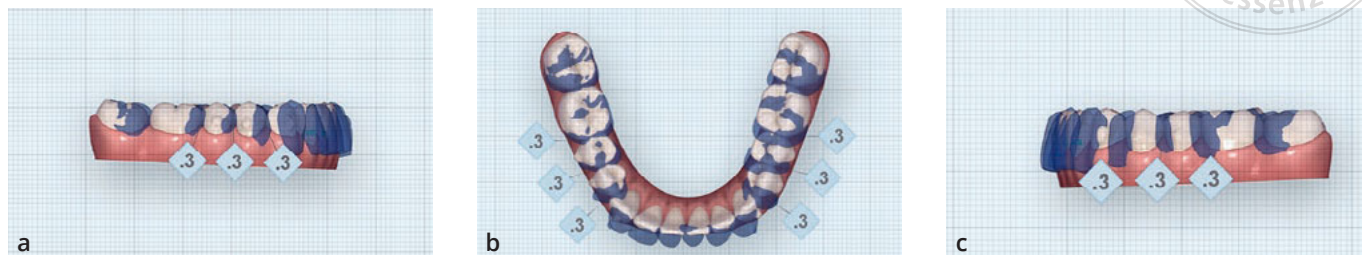


additional skeletal anchorage to become more so. The final result shows the occlusal antagonist to the maxillary second molars to be missing due to the need for mesialisation of mandibular molars and second molars, leading in this treatment plan including extraction to a suboptimal result. Other alternatives simulated in the ClinCheck Software with the extraction of second premolars or extraction of a mandibular incisor also did not lead to satisfying results. The ClinCheck situation shown in Figure 6 was therefore not accepted, as it did not seem a valuable alternative treatment plan for this patient.

Figure 7 shows the intraoral situation after 60 weeks, with the patient changing the aligners every 7 days. There was still anterior contact and missing posterior contact, leading to the addition of eight additional aligners for finishing in both arches for mandibular anterior retraction with IPR and posterior extrusion for occlusal contact of all

premolars and molars (red/green contact points in the ClinCheck Pro software). Figure 8 shows the final planned ClinCheck Software result for phase 2. Figure 9 demonstrates the final extra- and intraoral result of the full class I relationship and physiological incisor relationship. The orthopantomogram shows no root resorption and exhibits parallel roots.

For a radiograph to be taken, there must be medical grounds in our country for a justification under the Ordinance on the Protection of X-Ray Radiation (X-Ray Regulation of the Federal Republic of Germany). A radiograph is not permitted for forensic reasons alone. Documentation of the final result is sufficient in many cases, as a lateral radiograph at the close of treatment has no effect on the finished therapy, so an increase of information is questionable. As this patient did not undergo any surgical procedure, we did not use a cephalometric image in the sense of



Figs 11a to c Superimposition of the ClinCheck Software showing the amount of planned distalization and retraction in the mandibular arch (blue = initial situation, white = planned outcome).

the radiograph regulation for the protection of the patients from damages by radiographs and can therefore not present it in this article.

The final scan demonstrates the occlusal contact point situation with posterior contacts and a physiological anterior relationship without contact points, showing the according contact points in the planned result in the ClinCheck software (Fig 10). Retention was obtained with removable splints (Vivera Retainer, Align Technology) in both arches at night.

Example 2 (Team Ojima/Dan)

Diagnosis

The patient was a 27-year-old female whose chief complaint was a lateral open bite, leading to impaired mastication and mandibular anterior crowding, as well as a desire to improve her facial profile.

The patient's facial configuration displayed anterior symmetry with a slight protrusion of the lower lip. Intraorally, the maxillary and mandibular midline were approximately in line, central incisors displayed edge-to-edge bite, the maxillary and mandibular canines and first molars were in Class III relationship with anterior crowding, and there was an excessive curve of Spee with a pronounced lateral open bite. Furthermore, compared with the mandibular dentition, the maxillary dental arch was contracted. Occlusion was unstable (Fig 12). Results of the cephalometric analysis showed that the ANB was -1.1 degrees, Wits -10.0 , compared with the maxilla, the mandible was further forward, and the mandibular plane was open in a skeletal Class III relationship. With regard to the incisor tooth axis, both maxillary and mandibular incisors displayed lingual inclination. A panoramic radiograph showed no patholo-

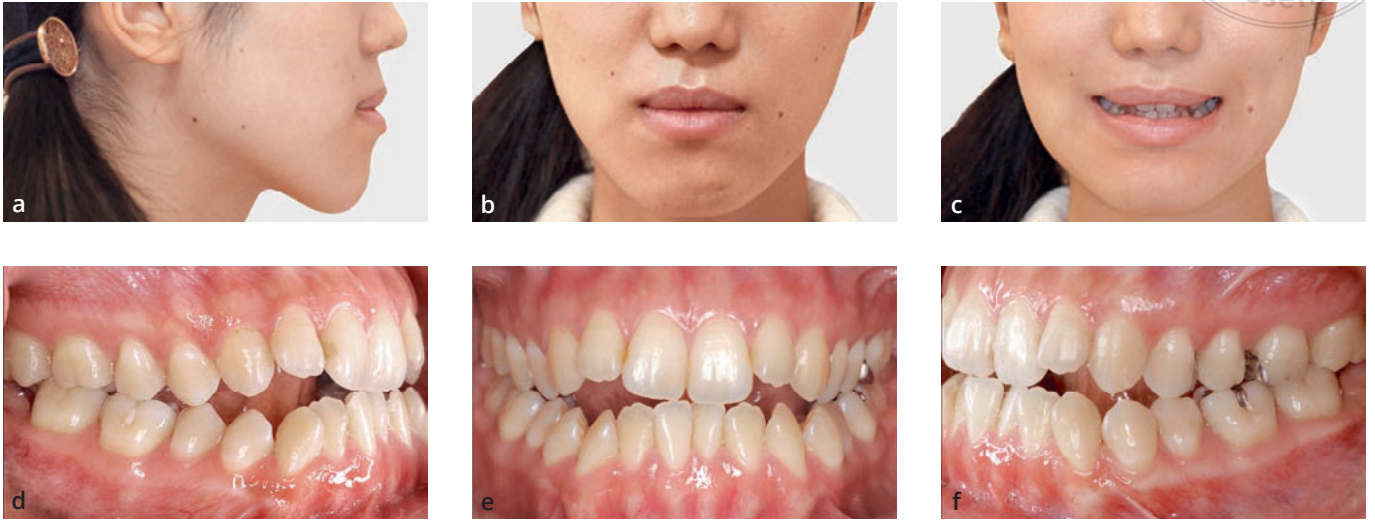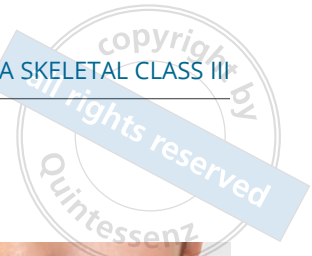gies, the maxillary and mandibular third molars on both sides had been extracted and no pathological root resorption was identified (Figs 13 to 15 and Table 1).

Treatment goals

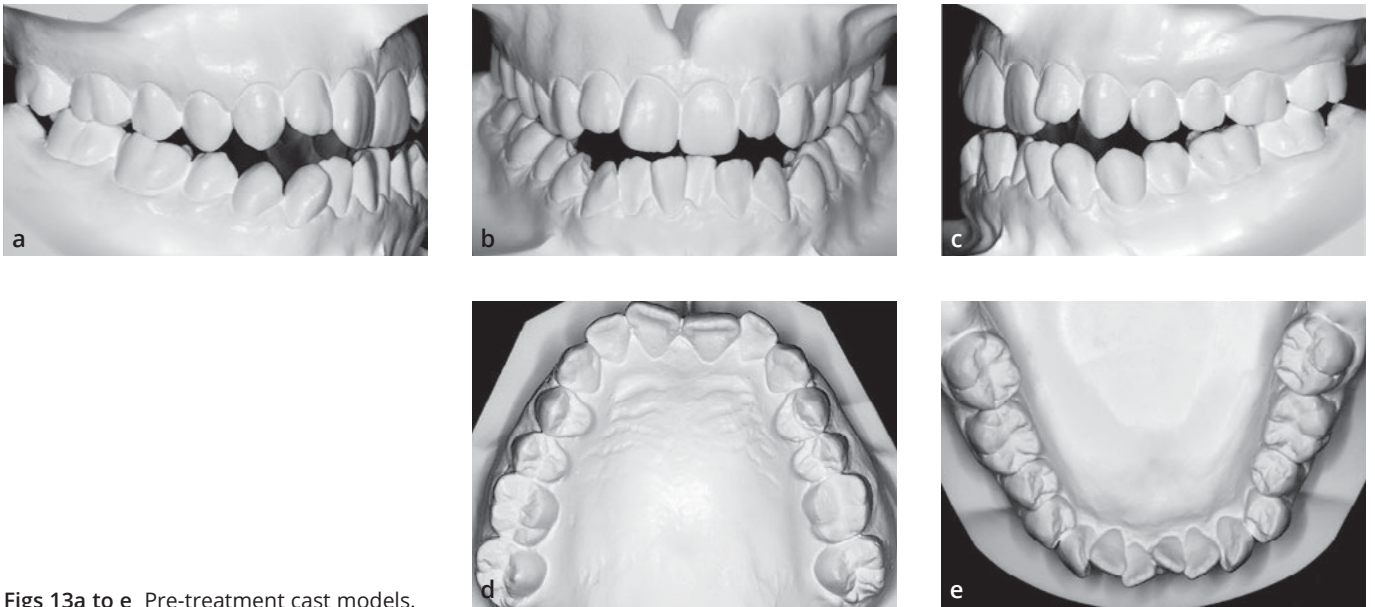
With treatment, we planned to improve the patient's profile through improvement of the molar relation, edge-to-edge bite of the incisors and the lateral open bite due to distalization in the mandibular arch.

Treatment alternatives

There were three possible ways of achieving the treatment goals. The first was a combined orthodontic treatment option including a bilateral sagittal split osteotomy (BSSO). Treatment would include a multi-bracket attachment and no extraction. Treatment time would be 24 months. The second option, while non-surgical, included extraction of all four maxillary and mandibular premolars (treatment time up to 24 months). The third option was the most ambitious: non-extraction distalization of the posterior and lateral mandibular teeth using a removable aligner (predicted treatment time of between 30 and 36 months). The patient was informed about partial improvements of her profile with the surgery correction at a high level, and also in a mandibular amount with extraction, while the distalization alone would lead to the least improvement of the three options. After explaining the benefits and drawbacks of each option in detail, the patient expressed interest in the option that was the least conspicuous, less invasive, non-surgical, non-extraction, with the lowest chance of making a large change to her profile and the potential to finish in two years. Following a comprehensive examination of the patient's needs and treatment wishes, the third option, treatment with Aligner Technology's Invisalign system¹³⁻²⁸, was chosen.



Figs 12a to h Pre-treatment facial and intraoral photographs.



Figs 13a to e Pre-treatment cast models.

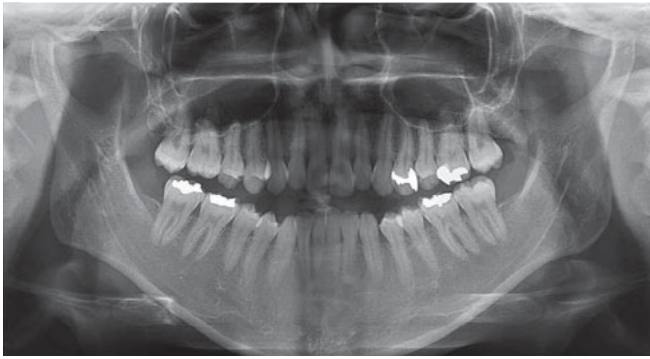


Fig 14 Pre-treatment panoramic radiograph.

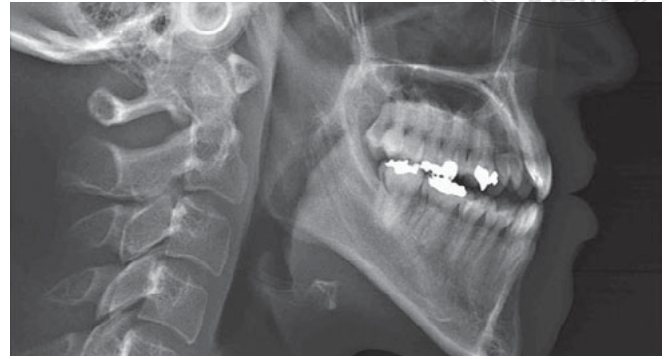
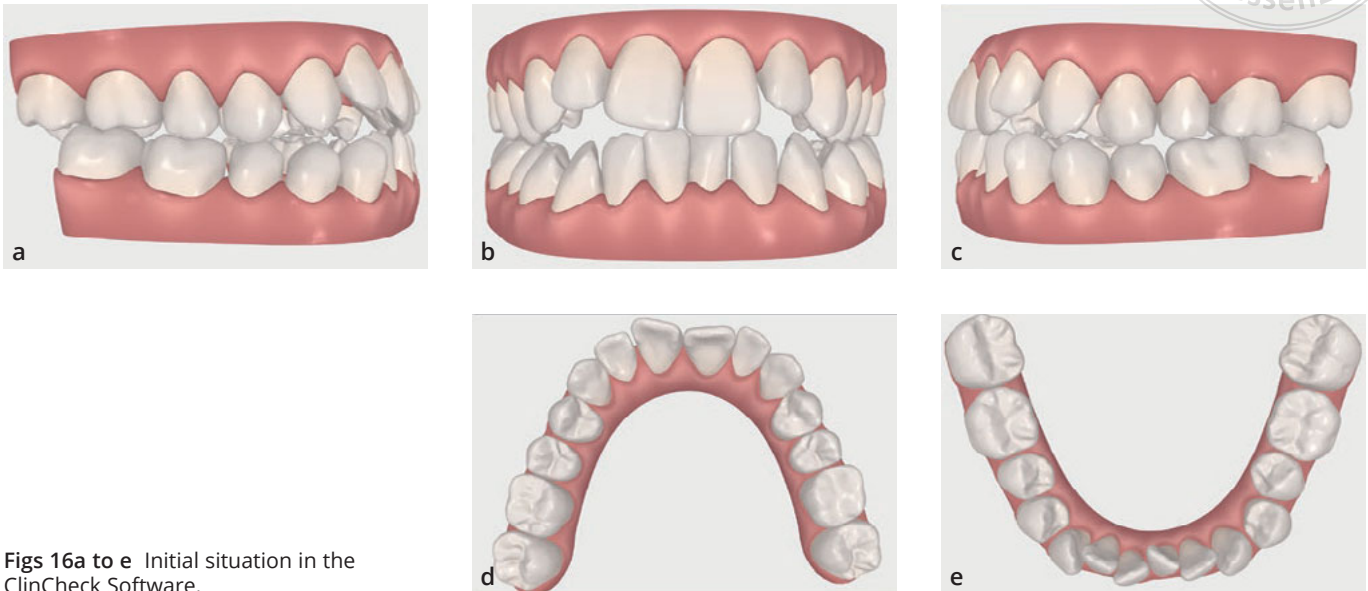


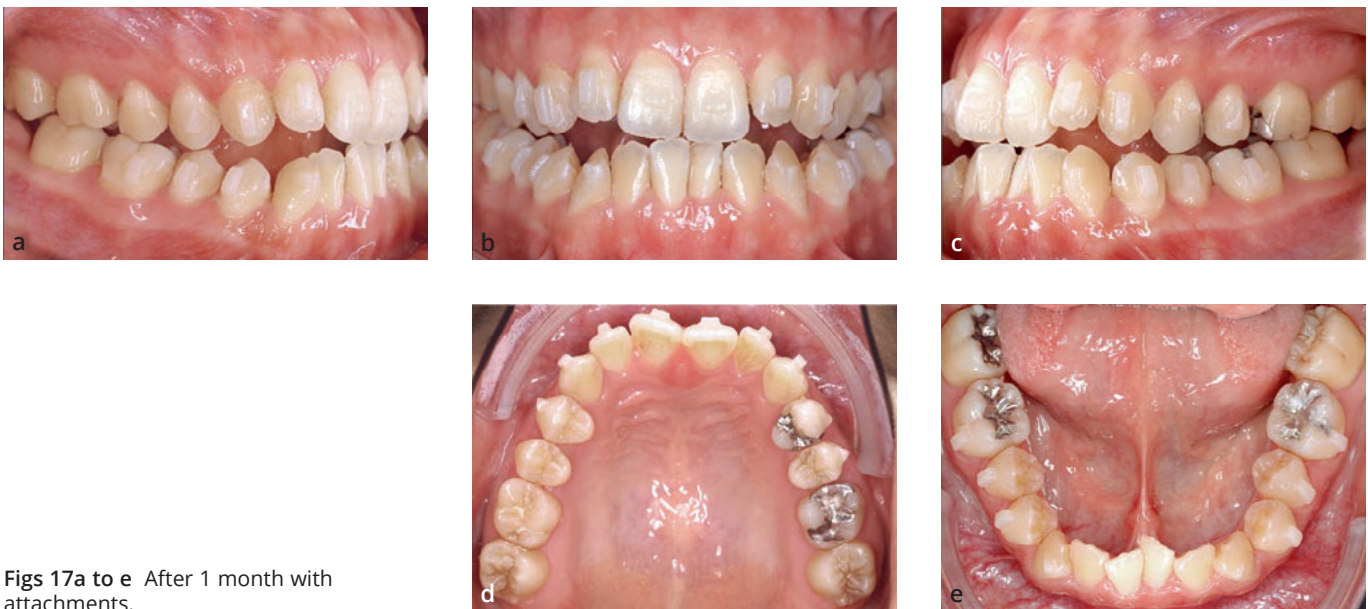Fig 15 Pre-treatment lateral cephalogram.

Table 1 Summary of cephalometric analysis

Measurement	Normal	ISD	Pre-treatment	Post-treatment
Maxillomandibular relationships				
SNA (°)	83.1	2.8	80.7	80.7
SNB (°)	79.5	2.7	81.8	81.6
ANB (°)	3.6	2.7	-1.1	-0.9
Wits appraisal (mm)	-1.3	2.6	-10.0	-8.2
Vertical skeletal relationships				
FMA (°)	29.0	3.6	33.7	33.3
Y-axis	65.4	5.6	65.8	65.5
Gonial angle (°)	126.6	6.0	130.9	130.9
N-ANS (mm)	55.3	2.7	48.0	48.0
ANS-Me (mm)	72.2	3.7	73.8	73.5
Dental relationships				
UI to FH (°)	112.3	5.1	105.7	106.6
FMIA (°)	60.3	5.4	69.9	75.8
IMPA (°)	90.7	5.6	76.4	70.9
Interincisal angle (°)	128.0	8.0	144.1	149.3
Occulusal PI	11.4	3.6	13.1	11.1



Figs 16a to e Initial situation in the ClinCheck Software.



Figs 17a to e After 1 month with attachments.

Treatment progression

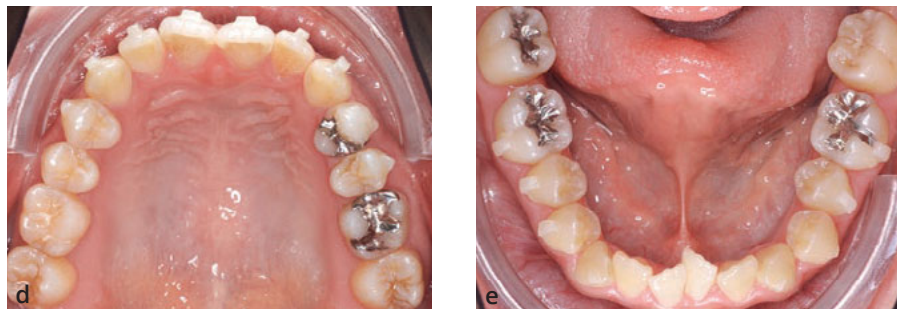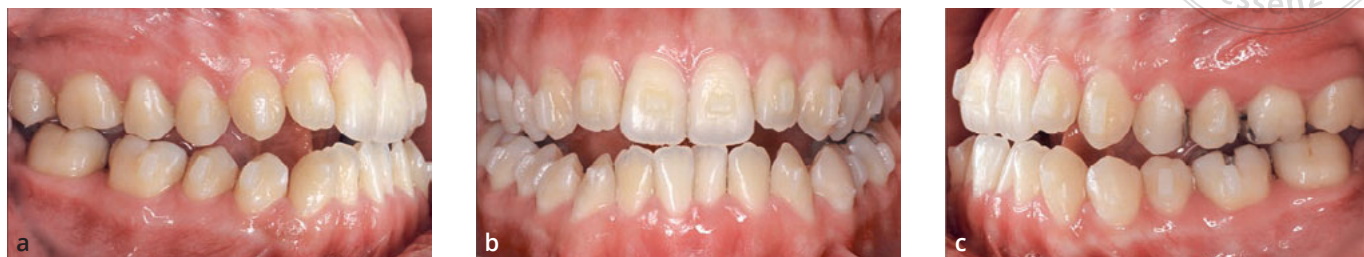The aligner treatment began with a three-dimensional intraoral scan of the teeth and occlusion, followed by a treatment simulation using the ClinCheck Software. The treatment plan was decided based on this simulation (Fig 16).

The main tooth movements were as follows:

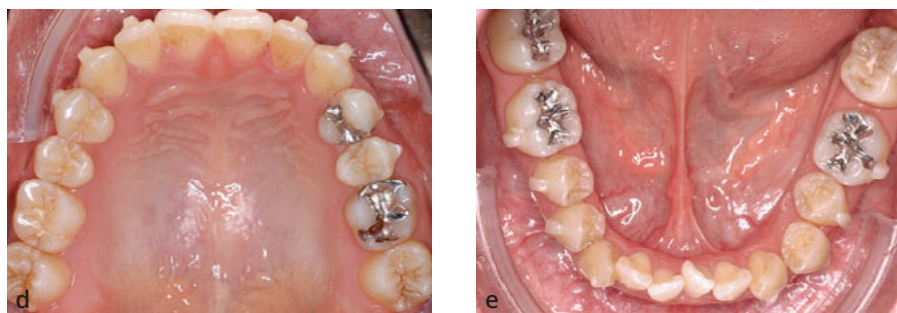
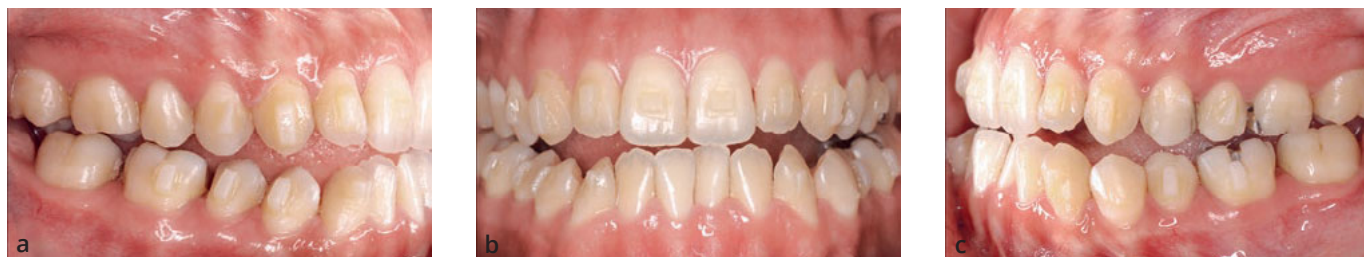1. Distalization of the mandibular molars (approximately 4 mm) to achieve a class I relation.
2. Intruding of the mandibular molars to produce an appropriate overbite.

3. Lateral expansion of the maxillary dental arch (approximately 7 mm)

Attachments were not used until 1 month after the aligner was initially inserted. Rectangular attachments were affixed to the mandibular teeth from the molars to the canines (Fig 17). After the second month, distalization of the mandibular molars started, planned in the ClinCheck Software to move one tooth at a time in sequence, beginning with the rearmost molars.



Figs 18a to e Start of mandibular molar distalization and intrusion of maxillary molars.



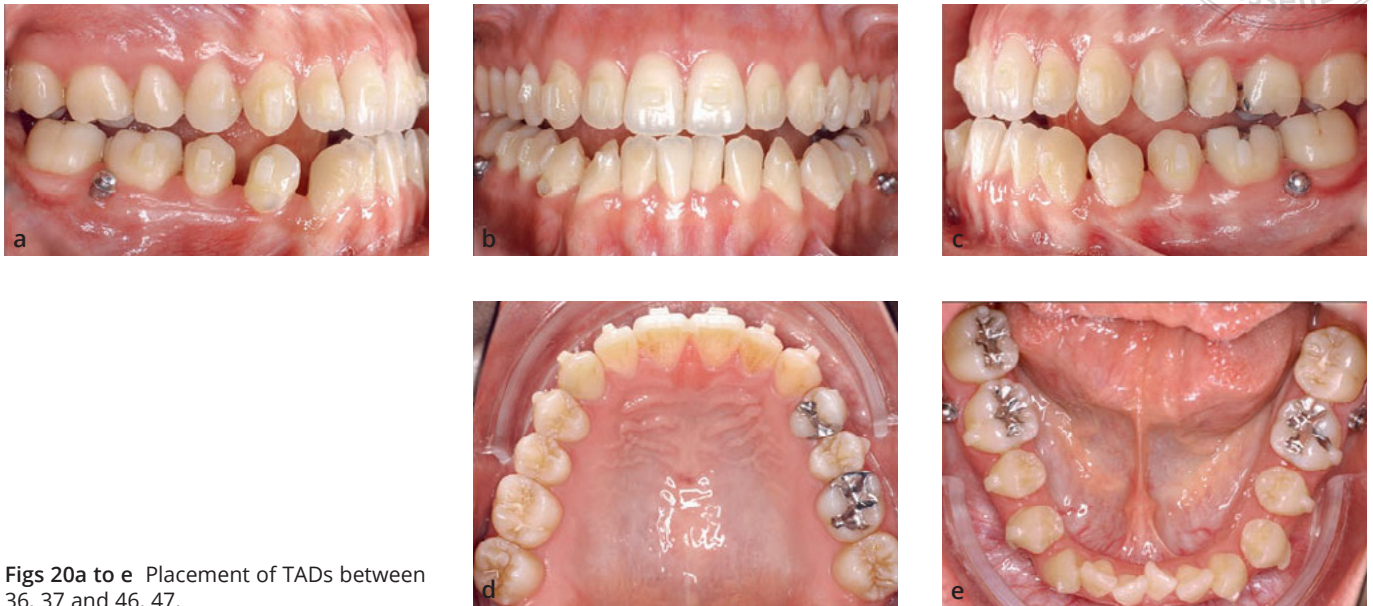Figs 19a to e Sequential distalization of mandibular molars.

After completion of the molar distalization, the distalization of the premolars began (Figs 18 and 19). To prevent mesial drift and create an anchor for the distalization of teeth from the canines forward, TADs were installed between the mandibular first molar and second molar and elastics were used (Figs 20 to 23). Following completion of both molar and premolar distalization, distalization of the canines and incisors began, ending with an optimal overbite of the anterior teeth. After the first 10 months of aligner

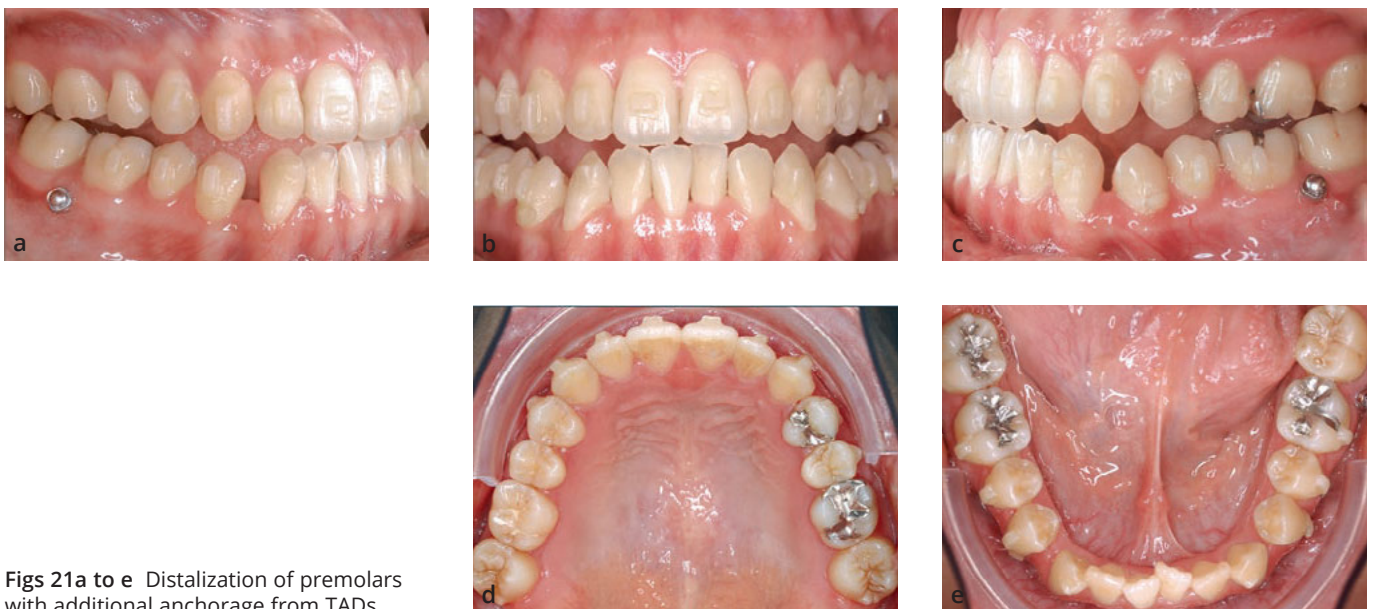use, minor imperfections were detected during treatment, such as a slight rotation of the mandibular canines and mandibular incisors, and we planned for extra aligners for refinement and finishing (Fig 24). Following completion of treatment, a Vivera retainer was used to retain the position.

Treatment results

Examination of the post-treatment facial profile photographs show that tension in the lips had improved and the lower lip



Figs 20a to e Placement of TADs between 36, 37 and 46, 47.

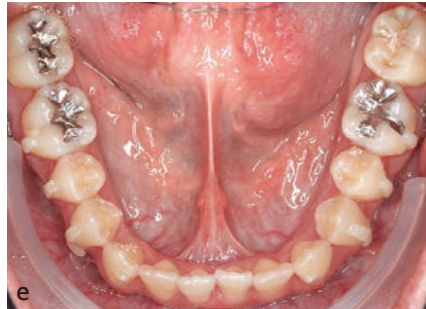
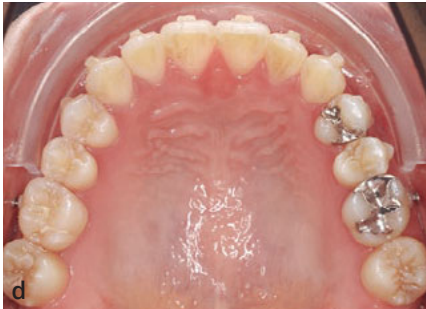
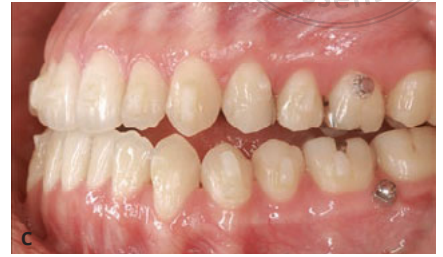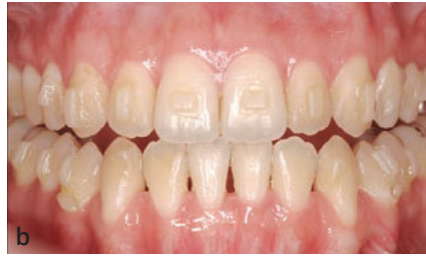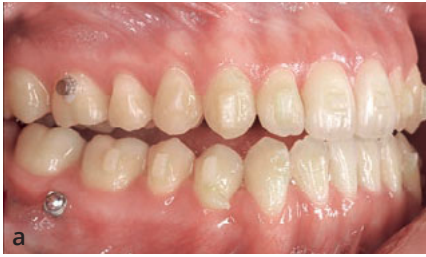Figs 21a to e Distalization of premolars with additional anchorage from TADs.

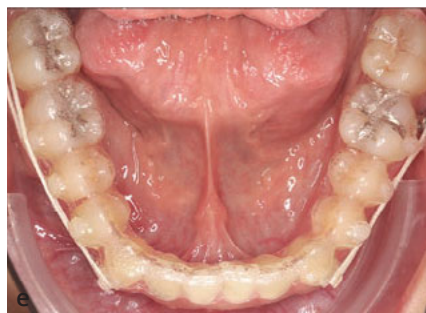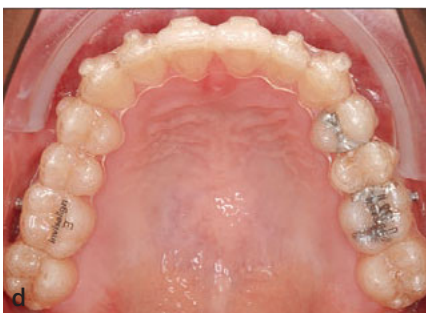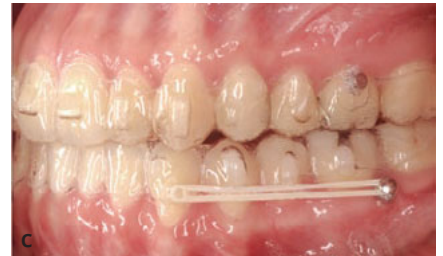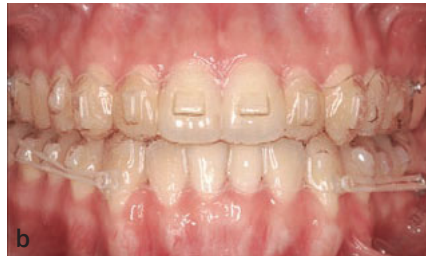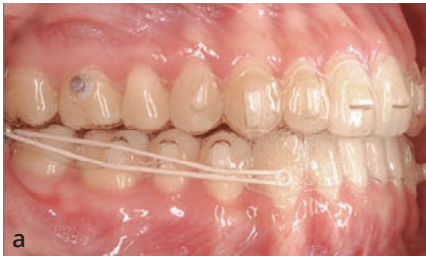had retracted slightly. The improvement of the initial tooth-to-tooth bite due to distalization in the mandibular arch had led to an increased overjet allowing the lips to follow the improved dental situation leading to a relaxed lip closure. The patient was satisfied with this result. Intraoral pictures showed that an appropriate overjet and overbite were achieved, maxillary and mandibular canines and molars showed a Class I relation and lateral open-bite had been perfectly improved. Post-treatment, dental arch width had

greatly increased, while molars achieved good occlusion. The final situation is in line with the final ClinCheck Software simulation results (Fig 25) and cephalometric analysis (Table 2).

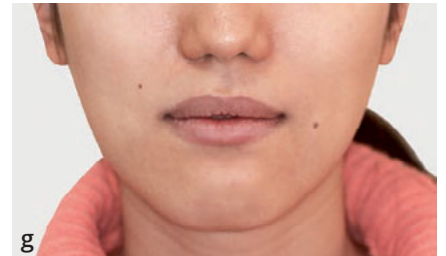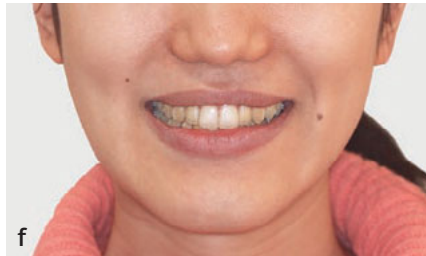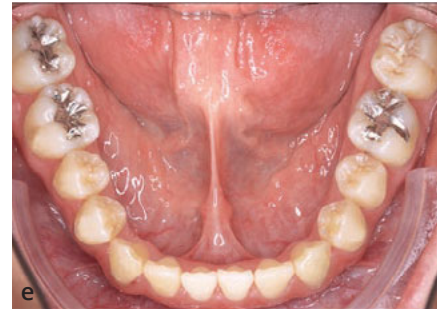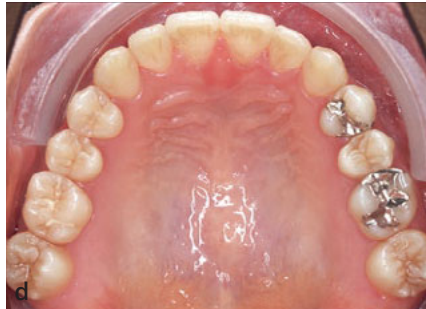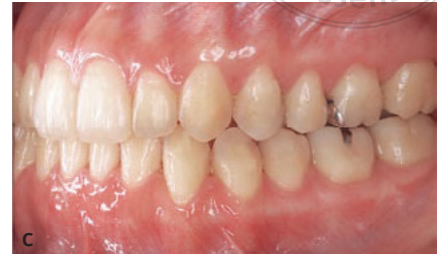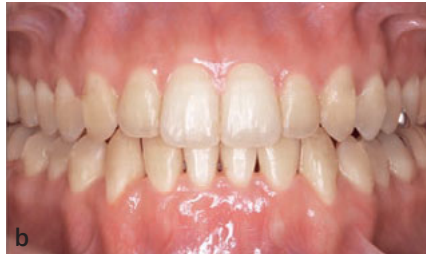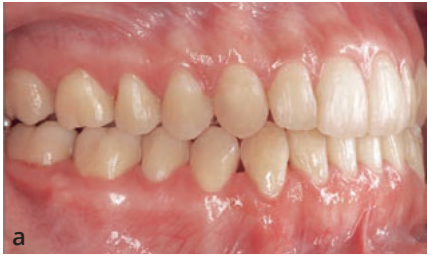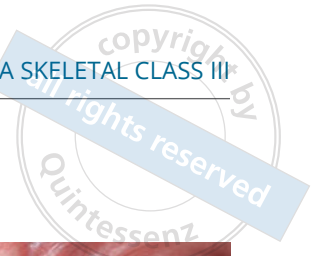Crowding in the mandibular anterior teeth had been relieved and, while there was slight retraction in the interdental papilla, it was barely noticeable and no periodontal pockets had formed. Post-treatment panoramic radiographs showed maintained dental parallelism, with no obvious root resorption in the alveolar bone (Fig 26).



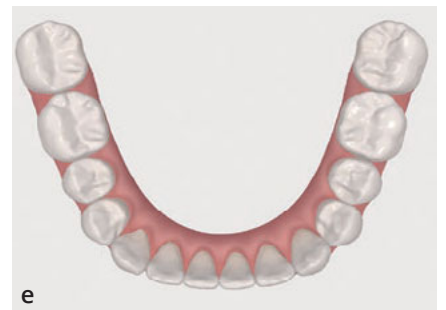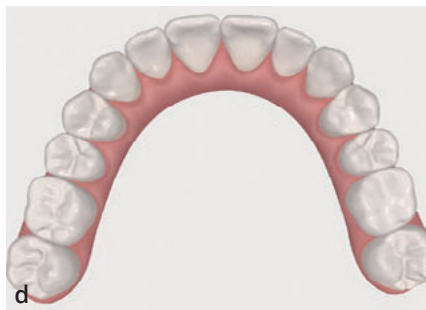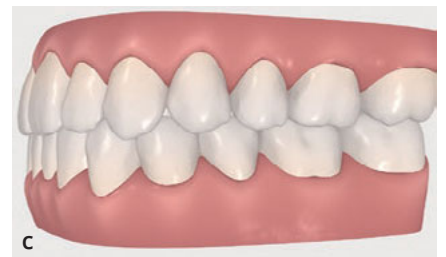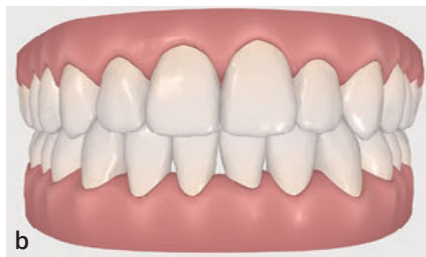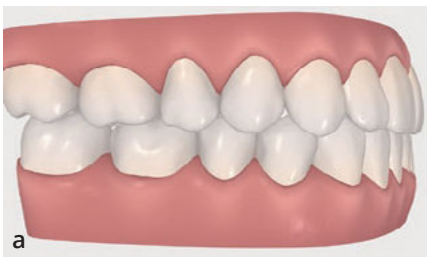Figs 22a to e Mandibular anterior retraction.



Figs 23a to e Intraoral situation with anterior retraction with Class III elastics to TADs.



Figs 24a to g Post-treatment facial and intraoral photographs.



Figs 25a to e Post-treatment ClinCheck Software simulation.



Table 2 Dentition with measurement

	Pre-treatment	Post-treatment	Difference
13–23	33 mm	35 mm	+2 mm
14–24	38 mm	45 mm	+7 mm
16–26	57 mm	58 mm	+1 mm
33–43	24 mm	28 mm	+4 mm
34–44	34 mm	37 mm	+3 mm
36–46	45 mm	49 mm	+4 mm

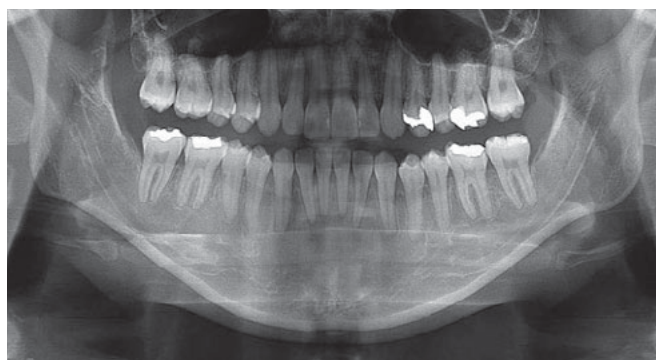


Fig 26 Post-treatment panoramic radiograph.

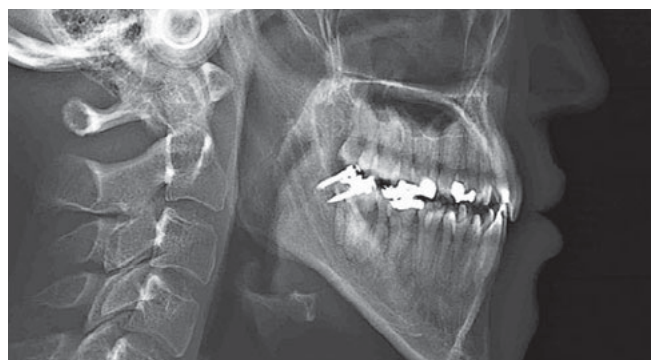

Fig 27 Post-treatment lateral cephalogram.

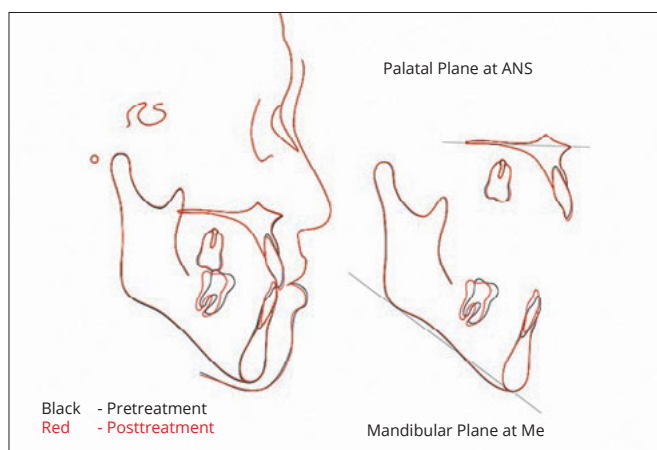


Fig 28 Cephalometric superimpositions between the pre-treatment and Post-treatment stages: overall, maxilla and mandible.

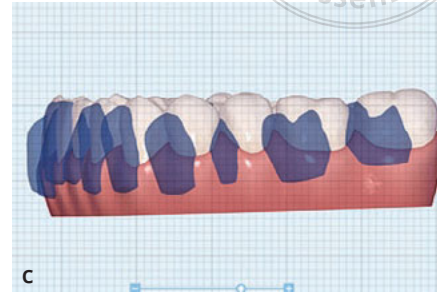
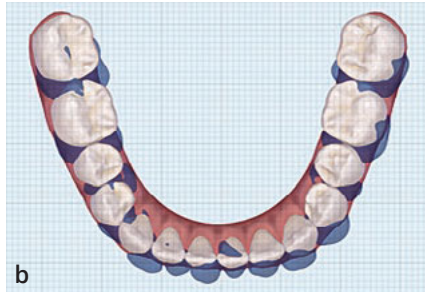
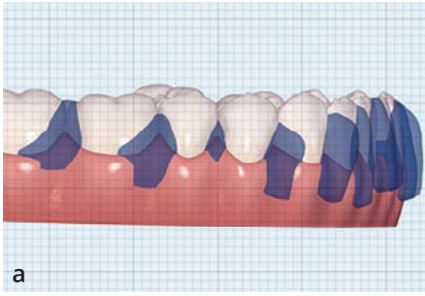
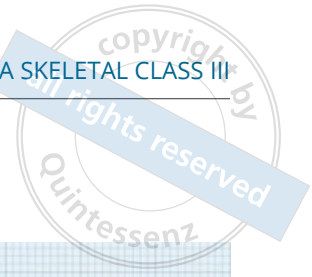Superimposed pre- and post-treatment cephalometric analyses showed no anterior-posterior shift of the mandible and a slight counter-clockwise rotation (Fig 27). Maxillary incisors exhibited a slight labial inclination and extrusion and mandibular incisors exhibited labial inclination

and extrusion. The maxillary first molars exhibited almost no change (Fig 28).

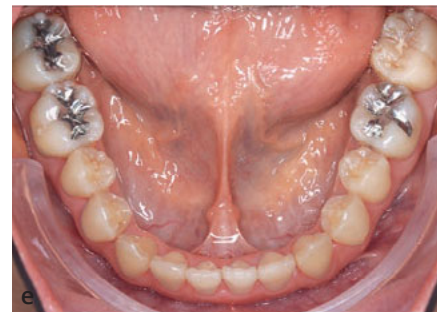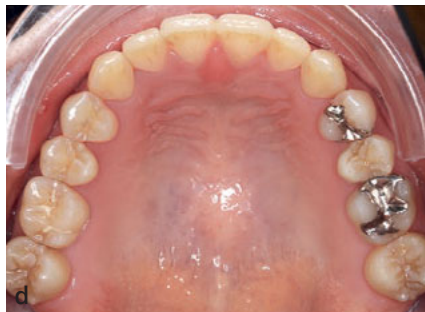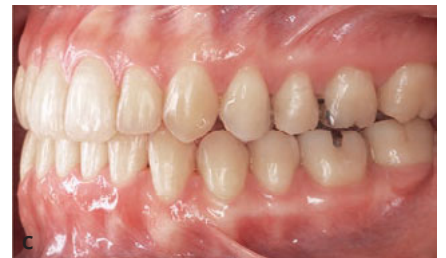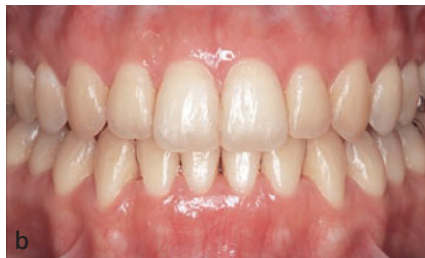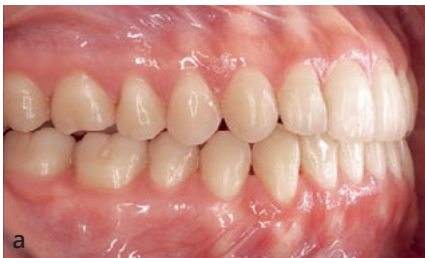By the end of treatment, 20 stages of maxillary aligners and 61 stages of mandibular aligners had been used over 10 months. A further 6 months were added to the treatment, with 10 additional maxillary stages and 34 lower stages, for 16 months of treatment time in total. One-year post treatment and occlusion was stable with no change (Figs 29 to 33).

Discussion – Patient 1

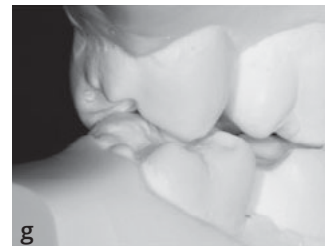
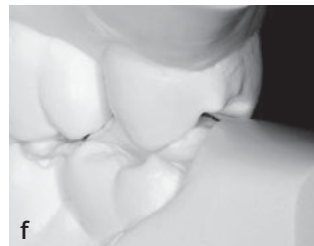
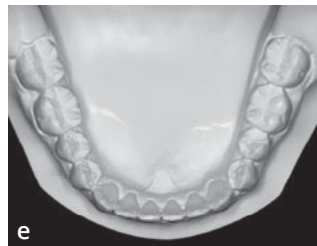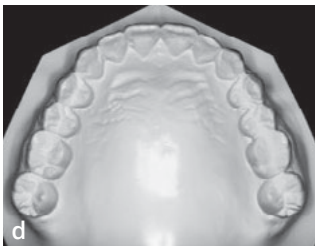
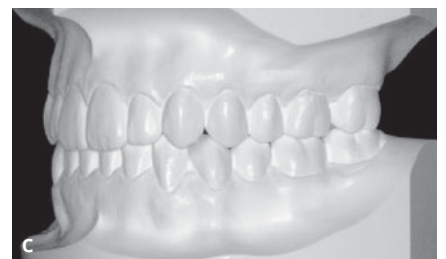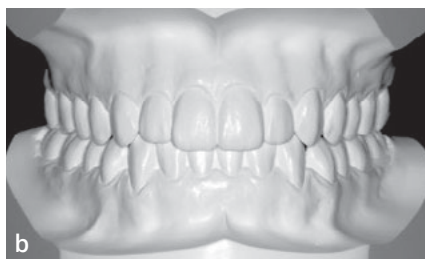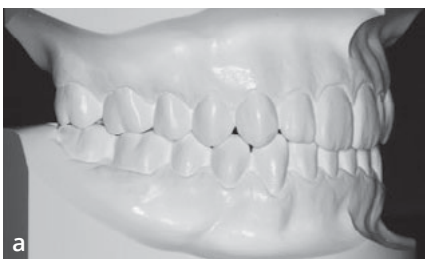As with all orthodontic treatments, several treatment alternatives were discussed in the treatment of this young patient. In order to select a medically meaningful treatment according to the criteria of evidence-based medicine and dentistry, the practitioner’s experience and the patient’s wishes should be taken into account. While planning this treatment, an orthognathic-surgical procedure was



Figs 29a to c ClinCheck Software superimposition.



Figs 30a to e Intraoral situation after 1-year retention.



Figs 31a to g Post-treatment dental casts. Good functional occlusion can be seen from the lingual aspect.

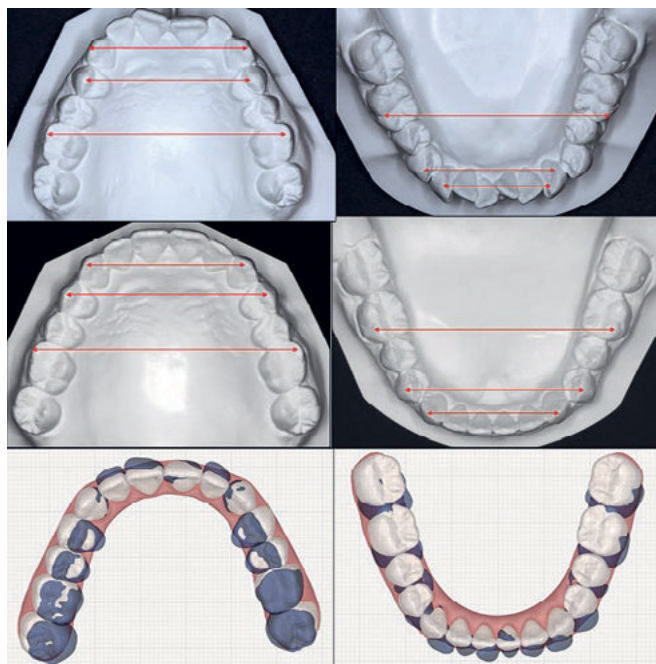


Fig 32 Dentition width measurement.

immediately negotiated by the patient. Although in some patients with a skeletal Class III a surgical procedure is imperative, the non-surgical procedure was a useful alternative for our patient, especially since she did not want to change her appearance.

When planning treatment, our first question is what goal do we want to achieve and how can we create it as minimally invasively as possible. As a professional singer, it was not possible for the patient to be treated with a fixed appliance due to the buccal – or, in the case of a lingual fixed appliance – lingual interference. Therefore, aligner therapy was the only alternative, especially as it is significantly less invasive than a fixed appliance therapy. The patient wore the aligners during singing without any impairment. An extraction therapy in the mandible was a possible alternative, but was also declined by the patient and did not seem a valuable alternative as experience has shown that distalization of mandibular posteriors with Class III elastics for anchorage is highly predictable with the Invisalign therapy. In addition, extraction therapy is again significantly more invasive than a non-extraction therapy.

In any case where anchorage with class II elastics (distalization in the maxillary arch) is needed, as well as in anchorage with class III elastics (distalization in the mandibular

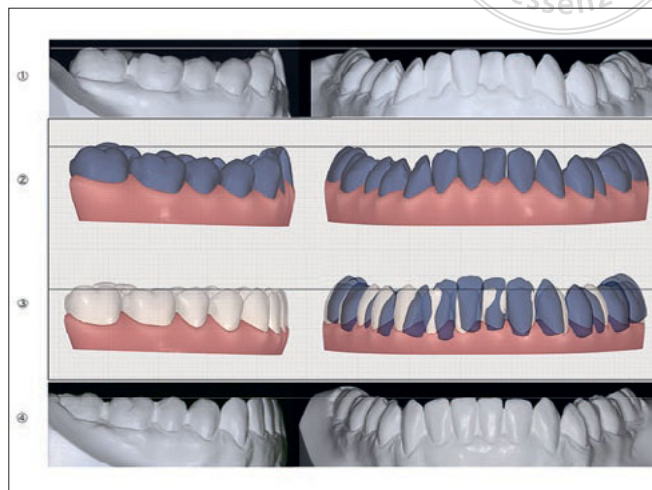
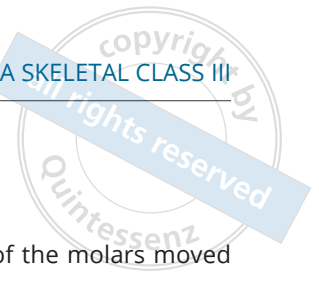


Fig 33 Correction of Curve of Spee.

arch), we bond hooks (Fig 3) to canines and molars to fix elastics securely and to avoid vertical pull on the aligner. In patients with pathology of the TMJ, Class III elastics should be anchored to TADs in the mandible in order to prevent any retral mandibular positioning due to the intermaxillary elastic pull. A further advantage is the fact that the elastics or coil springs can be inserted permanently to the TADs and therefore do not require patient compliance (see patient 2). Therefore, a manual examination of the TMJs before and during the treatment, specifically the palpation of the TMJs intra-auricular with the examiner's little fingers, is a *conditio sine qua non*⁷.

Discussion – Patient 2

Prior to treatment, we told the patient, after examining her facial profile and the state of her malocclusion, that she was a candidate for a surgical orthodontic procedure. The patient, however, refused treatment options with extraction or mandible surgery and strongly requested an inconspicuous corrective solution. With her desires in mind, we explored several different orthodontic treatment options in a thorough orthodontic examination. Results showed that



the maxillomandibular relationship exhibited a slightly recessed maxillary and a comparatively large mandible with an open mandibular plane, resulting in an elongated lower face. Furthermore, examination of the molar relation revealed that the maxillary first molar was making occlusal contact with the second mandibular molar. Examining ANB values showed that at -1.1 degrees, the anterior-posterior relationship was hardly drastic. However, considering the occlusal relationship of the maxilla and mandible, surgical treatment was clearly the primary option.

When considering non-surgical options, Kim's cephalometric analysis showed that the APDI was Class III and the ODI in open bite, and result of the CF suggested extraction²⁹. As the patient had refused extraction treatment, we moved forward with a maxillary-mandibular non-extraction treatment plan to relieve crowding in the mandibular anterior teeth and improve molar relation through distalization of the mandibular dentition. The treatment plan called for at least a 4 mm distalization of the mandibular molars. According to the literature we reviewed on both maxillary and mandibular molar distalization, this was an unprecedentedly large distance.

Since its release, the modern aligner system has gone through various improvements, evolving to expand the range of possible treatments to a wider variety of complicated malocclusion. However, compared with the long history of edgewise methods, it would be challenging to predict the safe and accurate completion of this treatment with a high degree of certainty. Furthermore, with molar distalization in cases of open bite, in order to avoid the molar raising wedge effect – considered by us to be the key to the success of this treatment – we decided that rather than an *en masse* movement using TADs and extraoral force, we would opt for a more time-consuming, but safer treatment plan, with individual tooth movements that would allow a greater degree of control. We explained to the patient that treatment with aligners could take up to 3 years and that she should not expect a drastic improvement in her facial profile. The patient agreed to use assistive TADs in order to prevent mesial movement of the distalized teeth. We were especially concerned with the distalization of the first and second mandibular molars and, after distalization of the second molar – half of the total movement distance – we began distalization of the first molar. When we began retraction of the premolars, in

order to prevent mesial movement of the molars moved thus far, we had implanted TADs between the first and second molars, which had unfortunately come loose mid-treatment on the right side. These were reattached to the distal side of the second molar.

No orthodontic treatment can allow unlimited movement of teeth. Studies have shown this to be especially true in the case of the mandibular incisors, due to the shape and thickness of the symphysis³⁰. In this case the symphysis was especially thin, and it was suggested that moving lower anteriors in this edge-to-edge bite lingually would be challenging and there was a limit to how much lingual movement was possible in the incisors. Actual treatment results show that even though mandibular incisors exhibit lingual inclination and that the alveolar bone displayed similar curvature, no root exposure or resorption was detected.

When treating overbite, our main goal is to increase the depth of the anterior occlusal bite. Schupp has reported that in his aligner treatments he has used attachments to achieve not relative, but absolute, extrusion. With Kim using the edgewise method (MEAW), he reported that it is necessary to change the occlusion plane^{31,32}. Results from the present study also indicate absolute extrusion of the anterior teeth and inclination of the occlusal plane.

In our plan to move teeth with aligners, movements can be roughly divided into distalization of the mandibular and the posterior teeth, followed by retraction of the incisors. During each clinical visit, we checked to see whether or not tooth movement was consistent with the ClinCheck Software simulation to ensure sufficient adaptation of each aligner³³⁻³⁸. As a result, the number of aligners and the overall treatment time naturally increased. The original treatment plan called for 61 stages, with maximum movement of a single stage of 0.25 mm over a 2-week period. This equated to treatment time exceeding 30 months. To reduce the period of treatment, we decided to use Ortho-Accel's AcceleDent, an accelerated orthodontic device, which we have used repeatedly to achieve effective results³⁹⁻⁴⁴.

There is controversy about the effectiveness of this device. It is thought that effectiveness with multi-bracket systems depends on a number of factors, including the type of brackets, wire size and shape, and the method of wire ligation. It is difficult to say that aligners, a wireless option that instead cover the teeth to move them, is not affected by



similar restrictions, and thus it is impossible to say that aligners are the best fit for the device.

Even so, by using an accelerated orthodontic device, not only is treatment time shorter and aligner fit improved, but the pain and discomfort that usually accompanies the initial insertion of a new aligner stage is also decreased. The benefits of accelerated orthodontics extend beyond the orthodontist to the patient as well.

Using AcceleDent, we were able to reduce the previous 2-week aligner change period to 5 days, reducing the initial treatment estimate of 36 months to a mere 16 months. Due to the lack of cases with identical conditions it is difficult to make a simple comparison, but comparing other cases treated with multi-bracket systems vs aligners with TADs, this reduction in treatment time seems significant. Furthermore, the ability to monitor tooth movement mid-treatment through comparison with the simulation in the ClinCheck Software, reduces lost motion due to insufficient adaptation between aligners and teeth. The results of the tooth movement in this study as planned are evidence of the validity of the treatment plan.

Examining the results of this treatment, we can see that tension has been relieved from the mentum region, creating a truly natural looking lip structure with a harmonious E-line. The patient was able to achieve favourable improvement in her facial profile without surgery and was quite satisfied.

Intraorally, edge-to-edge occlusion of the incisors and the lateral overbite has been completely improved. There is absolute extrusion of both the maxillary and mandibular incisors, the functional occlusal plane from the first molars is smaller in the direction of closure, and the use of the upright MEAW technique to achieve similar results as with a combination of vertical elastics is certainly interesting.

It can be surmised that the mechanism of the extrusion of the mandibular incisors was the traction of the aligner by the TADs, intrusion and uprighting of the mandibular molars led to a reduction of the occlusal plane angle, and the extrusion and rotation of the anterior teeth.

Moving forward, it is our plan to increase the number of treatments of similar cases to increase the predictability of tooth movement when using aligners and other additional devices.

Conclusion

In this study, favourable occlusion was achieved in Class III patients using aligners to perform a non-extraction and non-surgical treatment with distalization in the mandible with and without temporary anchorage devices. According to the first patient example, treatment time can be shortened by 50% with an aligner change every 7 days. Furthermore, the use of an accelerated orthodontic device enabled a further reduction to a 5-day change of aligner wear for the second patient.

References

1. Yazdani, AA. Transparent aligners: An invisible approach to correct mild skeletal Class III malocclusion. *J Pharm Bioallied Sci* 2015;7: 301–306.
2. Schupp, W, Haubrich J, Hermens E. Möglichkeiten und Grenzen der Schienentherapie in der Kieferorthopädie, *Zahnmed. Update* 2, 2013: 171–184.
3. Schupp W, Haubrich J, Neumann I. Class II correction with the Invisalign system. *J Clin Orthod* 2010;44:28–35.
4. Bowman SJ, Celenza F, Sparaga J, Papadopoulos MA, Ojima K, Lin JC. Creative adjuncts for clear aligners, part 3: extraction and interdisciplinary treatment. *J Clin Orthod* 2015;49:249–262.
5. Bowman SJ, Celenza F, Sparaga J, Papadopoulos MA, Ojima K, Lin JC. Creative adjuncts for clear aligners, part 2: intrusion, rotation, and extrusion. *J Clin Orthod* 2015;49:162–172.
6. Bowman SJ, Celenza F, Sparaga J, Papadopoulos MA, Ojima K, Lin JC. Creative adjuncts for clear aligners, Part 1: class II treatment. *J Clin Orthod* 2015;49:83–194.
7. Schupp W; Haubrich J. *Aligner Orthodontics 2015 Quintessence Publishing, Berlin.*
8. Lin JC, Tsai SJ, Liou EJ, Bowman SJ. Treatment of challenging malocclusions with Invisalign and miniscrew anchorage. *J Clin Orthod* 2014; 48:23–36.
9. Ojima K, Dan C, Nishiyama R, Ohtsuka S, Schupp W. Accelerated treatment with Invisalign. *J Clin Orthod* 2014;48:487–499.
10. Orton-Gibbs S, Kim NY. Clinical experience with the use of pulsatile forces to accelerate treatment. *J Clin Orthod* 2015;49:557–573.
11. Bowman SJ. The effect of vibration on the rate of leveling and alignment. *J Clin Orthod* 2014;48:678–688.
12. Nagasaka H, Sugawara J, Kawamura H, Nanda R. "Surgery first" Skeletal Class III correction using the Skeletal Anchorage System, *J Clin Orthod* 2009;43:97–105.
13. Vlaskalic V, Boyd R. Orthodontic treatment of a mildly crowded malocclusion using the Invisalign System. *Aust Orthod J* 2001;17:41–46.
14. Boyd RL, Miller RJ, Vlaskalic V. The Invisalign system in adult orthodontics: Mild crowding and space closure cases. *J Clin Orthod* 2000;34: 203–212.
15. Giancotti A, Di Girolamo R. Treatment of severe maxillary crowding using Invisalign and fixed appliances. *J Clin Orthod* 2009;43:583–589.
16. Schupp W, Haubrich J, Neumann. Treatment of anterior open bite with the Invisalign system. *J Clin Orthod* 2010;44:501–507.
17. Guarneri MP, Oliverio T, Silvestre I, Lombardo L, Siciliani G. Open bite treatment using clear aligners. *Angle Orthod* 2013;83:913–919.



18. Krieger E, Seiferth J, Marinello et al. Invisalign treatment in the anterior region. *J Orofac Orthop* 2012;73:365–376.
19. Fiorillo G, Festa F, Grassi C. Upper canine extraction in adult cases with unusual malocclusions. *J Clin Orthod* 2012;46:102–110.
20. Simon M, Keilig L, Schwarze J, Jung BA, Bourauel C. Treatment outcome and efficiency of an aligner technique – regarding incisor torque, pre-molar derotation and molar distalization. *BMC Oral Health* 2014;14:68–74.
21. Giancotti A, Farina A. Treatment of collapsed arches using the Invisalign system. *J Clin Orthod* 2010;44:416–425.
22. Boyd R.L. Esthetic orthodontic treatment using the Invisalign appliance for moderate to complex malocclusions. *J Dent Educ* 2008;72:948–967.
23. Castroflorio T, Garino F, Lazzaro A, Debernardi C. Upper-incisor root control with Invisalign appliances. *J Clin Orthod* 2013;47:346–351.
24. Schupp W, Haubrich J, Neumann I. Invisalign treatment of patients with craniomandibular disorders. *Int Orthod* 2010;8:253–267.
25. Womack WR. Four-premolar extraction treatment with Invisalign. *J Clin Orthod* 2006;40:493–500.
26. Boyd RL. Complex orthodontic treatment using a new protocol for the Invisalign appliance. *J Clin Orthod* 2007;41:525–547.
27. Lagravere MO, Flores-Mir C. The treatment effects of Invisalign orthodontic aligners: a systematic review. *J Am Dent Assoc* 2005;136:1724–1729.
28. Giancotti A, Germano F, Muzzi F, Greco M. A mini screw-supported intrusion auxiliary for open-bite treatment with Invisalign. *J Clin Orthod* 2014;48:348–358.
29. Kim YH. Anterior open bite and its treatment with multi-loop edgewise archwire. *Angle Orthod* 1987;57:290–321.
30. Handelman CS. The anterior alveolus: its importance in limiting orthodontic treatment and its influence on the occurrence of iatrogenic sequence. *Angle Orthod* 1996;66:95–109.
31. Yang WS, Kim BH, Kim YH. A study of the regional load deflection rate of multi-loop edgewise arch wire. *Angle Orthod* 2001;71:103–9.
32. Janson D, De Souza JE, Barros SE, Andrade Junior P, Nakamura AY. Orthodontic treatment alternative to a Class III subdivision malocclusion. *J Appl Oral Sci* 2009;17:354–63.
33. Oh YH, Park HS, Kwon TG. Treatment effects of micro implant-aided sliding mechanics on distal retraction of posterior teeth. *Am J Orthod Dentofacial Orthop* 2011;139:470–4481.
34. Chung K, Kim SH, Kook Y. Orthodontic micro implant for distalization of mandibular dentition in Class III correction. *Angle Orthod* 2005;75:119–128.
35. Baik UB, Chun YS, Jung MH, Sugawara J. Protraction of mandibular second and third molars into missing first molar spaces for a patient with an anterior open bite and anterior spacing. *Am J Orthod Dentofacial Orthop* 2012;141:783–795.
36. Safavi SM, Younessian F, Kohli S. Miniscrew-assisted mandibular molar distalization in a patient with skeletal class-III malocclusion: A clinical case report. *APOS Trends Orthod* 2013;3:83–88.
37. Belrão P: Class III high angle malocclusion treated with orthodontic camouflage (MEAW Therapy). *Issues in contemporary orthodontics, Intech*, 2015;11:219–241.
38. Ravera S, Castroflorio T, Garino F. Maxillary molar distalization in adult patients with Invisalign. *EJCO* 2014;2:3.
39. Yadav S, Assefina A, Gupta H, et al. The effect of low-frequency mechanical vibration on retention in an orthodontic relapse model. *Euro J Orthod* 2015;38:44–50.
40. Brugnami F, Caiazzo A, Dibart S. Lingual orthodontics: Accelerated realignment of the “social six” with piezocision. *Compend Contin Educ Dent* 2013;34:608–610.
41. Camacho AD, Velásquez Cujar SA. Dental movement acceleration: Literature review by an alternative scientific evidence method. *World J Methodol* 2014;4:151–162.
42. Kau CH, Nguyen JT, English JD. The clinical evaluation of a novel cyclical force-generating device in orthodontics. *Orthod Pract US* 2010:10–15.
43. Woodhouse N, DiBiase AT, Johnson N, et al. Supplemental vibrational force during orthodontic alignment: A randomized trial. *J Dent Res* 2015;94:682–689.
44. Orton-Gibbs S, Kim NY. Clinical experience with the use of pulsatile forces to accelerate treatment. *J Clin Orthod* 2015;49:557–573.