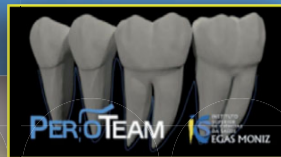



Guided tissue regeneration using membrane and bone of equine origin (Triagen®)



CASE DESCRIPTION

A female patient, healthy, non smoker, of 52 years olds, was referred to the periodontology department of I.U.E.M. to treat the bone defect on teeth 1.2. The **teeth 1.2 had a infrabony defect** with initial probing pocket depth of 9 mm, deep, wide with 2 walls. Non-surgical periodontal treatment was made and the patient had a 7% placa index. **A guided tissue regeneration** was performed using a collagen membrane and a bone substitute of equine origin. Before the procedure, a retainer was done because the teeth had grade 1 mobility. The patient didn't have any medical disease that counter-indicate the surgery.

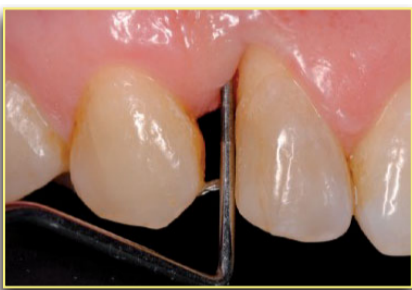

Fig. 1 - The infrabony defect had a inicial probing pocket depth of 9 mm, with bleeding on probing.

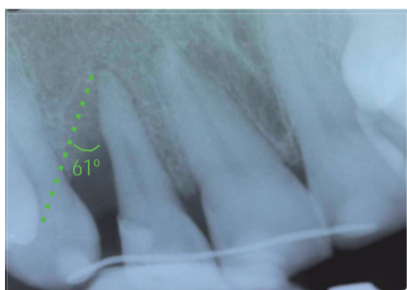


Fig. 2 - Inicial radiograph. The **radiographic defect angle** was superior to 37°.

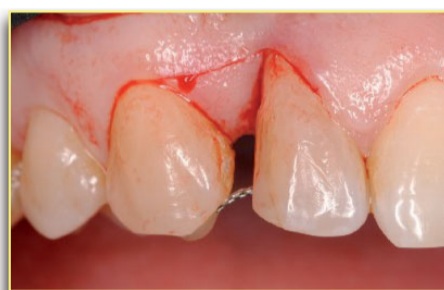

Fig. 3 - An horizontal incision on the bucal surface of the papilla was made and sulcular extended to teeth 1.2 and 1.3

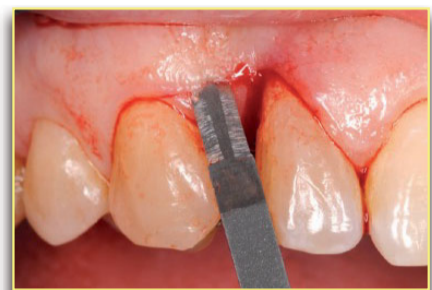

Fig. 4 - The papilla was elevated to the palatal site.

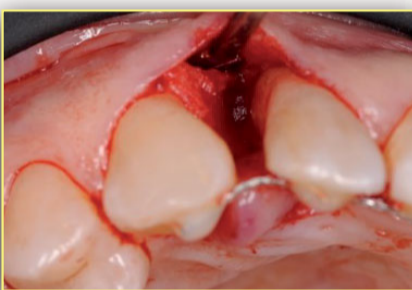

Fig. 5 - The defect was cleaned and had 2 walls. Root scaling was done and polished.

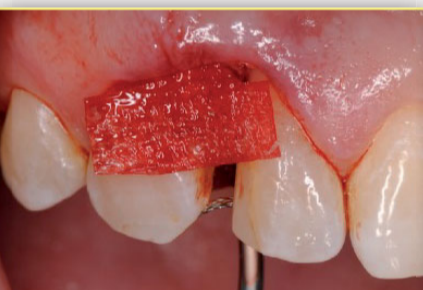

Fig. 6 - The collagen membrane was adapted to fit the defect configuration.

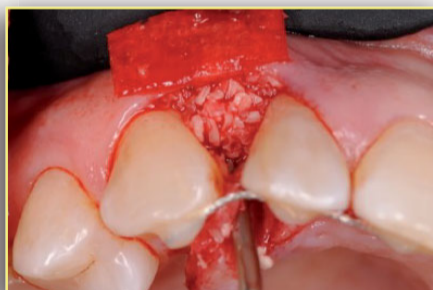

Fig. 7 - The defect was filled with the bone substitute.

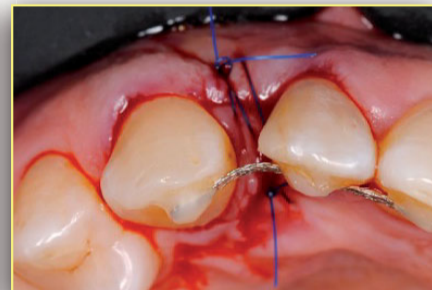


Fig. 8 - A **internal horizontal mattress suture** was made with nonabsorbable, sterile surgical monofilament 5/0 suture (occlusal view).

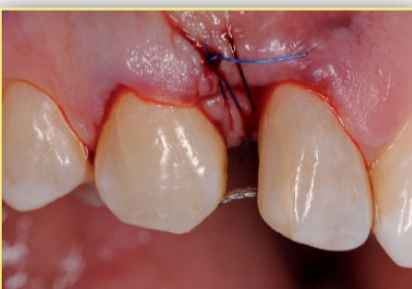

Fig. 9 - Suture (lateral view).

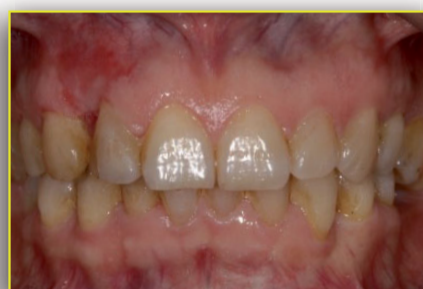

Fig. 10 - Follow-up after 2 weeks, after suture removal.

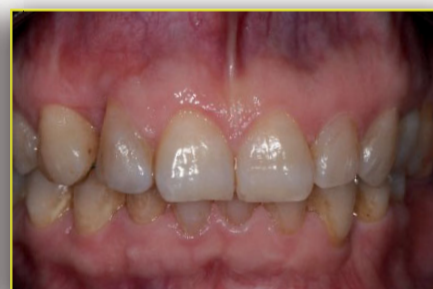

Fig. 11 - Follow-up after 6 months.

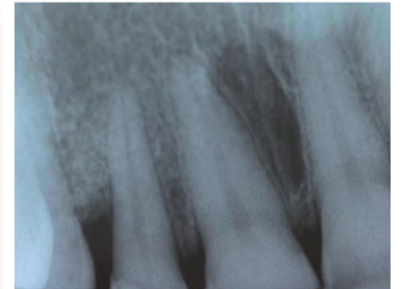


Fig. 12 - Radiographic after 6 months.

DISCUSSION

The guided tissue regeneration is a surgical procedure that uses a barrier membrane, on an infra bony defect to maintain a blood clot in a space, to allow the periodontal attachment cell's to grow. **The membranes of equine origin are three-dimensional estrutures of collagen**, that have their effectiveness for 3 or 4 months, which is the necessary time for periodontal regeneration. The use of cortical-spongy bone substitute of equine origin, plays an important role in maintaining space, preventing the collapse of the membrane. The infra-bony defect had a probing pocket depth superior to 5 mm and a **wide radiographic defect angle** (superior to 37 degrees). With wide defects, the use of bone substitute can help maintaining the space. A modified papilla preservation technique was made and used a crossed horizontal mattress suture. Follow-up appointments were made (2 weeks, 1 month, 3 months and 6 months) to evaluate plaque and gingival index, height of keratinized gingiva and gingival recession. Standardized periapical radiographs were obtained through the use of an individualized device (paralleliser). Total bone filling was observed after 6 months, which is the necessary time for the periodontal regeneration be considered. No complication were observed (such as infection and membrane exposure). The evaluation of the reduction of the defect depth was based on standardized periapical radiographs obtained through the use of an individualized device (paralleliser). **Almost total bone filling was observed** after 6 months and reduction of the pocket depth to 4 mm (with a clinical attachment gain level of 5 mm). The mobility of the tooth become physiological and height of keratinized gingiva was preserved.

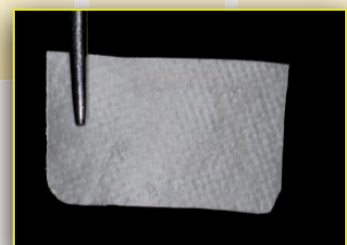

Fig. 13 - Membrane (above) and bone substitute (below).

CONCLUSION AND REFERENCES

Although a perfect periodontal regeneration can only be confirmed with histological biopsy, the use of collagen membranes and corticocellular bone substitute of equine origin seems to be a **viable alternative** in the regeneration of infra-bony periodontal defects.

1. Mueller VT, Welch K, Bralu D.C., Wang H-L. Early and late studies of EMD use in periodontal intrabony defects. J Periodont Res 2003. 48:117-125 / 2. Trombelli L. Which reconstructive procedures are effective for treating the periodontal intraosseous defect? Periodontol 2000 2005. 37:88-105. / 3. Nyman, S., Gottlow, J., Karring, T. & Lindhe, J. The regenerative potential of the periodontal ligament. An experimental study in the monkey. J Clin Periodontol 1982. 9:157-265. / 4. Becker, W. & Becker, B.E. Treatment of mandibular 3-wall intrabony defects by flap debridement and expanded polytetrafluorethylene barrier membranes. Long term evaluation of 32 treated patients. Journal of Periodontology. 1993. 64:1138-1144. / 5. Cortellini, P., Pini Prato, G. & Tonetti, M. Periodontal regeneration of human intrabony defects with titanium reinforced membranes. A controlled clinical trial. J Periodontol 1995. 66:797-803. / 6. Venezia E, Goldstein M, Boyan BD, Schwartz Z. The use of enamel matrix derivative in the treatment of periodontal defects: A literature review and metaanalysis. Crit Rev Oral Biol Med 2004.15:382-402. / 7. Karring T, Nyman S, Gottlow J, Laurell L. Development of the biological concept of guided tissue regeneration - Animal and human studies. Periodontol 2000: 1993.1:26-35. / 8. Nyman S, Lindhe J, Karring T, Rylander H. New attachment following surgical treatment of human periodontal disease. J Clin Periodontol 1982. 9:290-296. / 9. Gottlow J, Nyman S, Lindhe J, Karring T, Wennstrom J. New attachment formation in the human periodontium by guided tissue regeneration. Case reports. J Clin Periodontol 1986. 13:604-616. / 10. Buser D, Dula K, Belser U, Hirt HP, Berthold H. Localized ridge augmentation using guided bone regeneration. 1. Surgical procedure in the maxilla. Int J Periodontics Restorative Dent 1993. 13:29-45. / 11. Effie Tsitoura Richard Tucker Jean Suvan Lars Laurell Pierpaolo Cortellini Maurizio Tonetti. Baseline radiographic defect angle of the intrabony defect as a prognostic indicator in regenerative periodontal surgery with enamel matrix derivative. <https://doi.org/10.1111/j.1600-051X.2004.00555.x> (2004)