

# DENTAL REHABILITATION IN PATIENTS FOLLOWING BURN CONTRACTURES- A CASE REPORT.

Dr Sunil Keswani<sup>1</sup> Dr Nitin Mokal<sup>2</sup> Dr Urvashi Keswani<sup>3</sup> Dr Sonika Khimani<sup>4</sup>  
National Burns Centre, Mumbai, India.

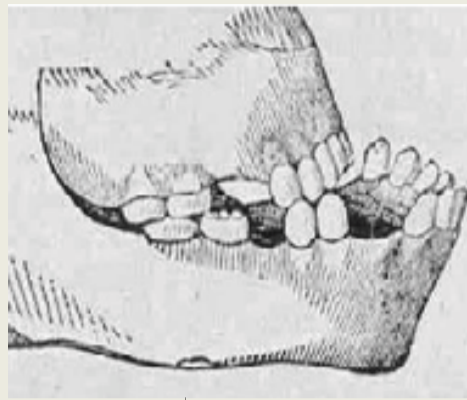
## INTRODUCTION:-

Facial deformity has been defined as a physiognomy form that is sufficiently negatively marked so as to set the individual apart from the general population.

A dentofacial deformity has adverse effect on individuals:-

- Self esteem
- Self confidence
- Undesirable social response.

Hullihen's case of severe burn contracture with dentofacial deformity



## HISTORY:-

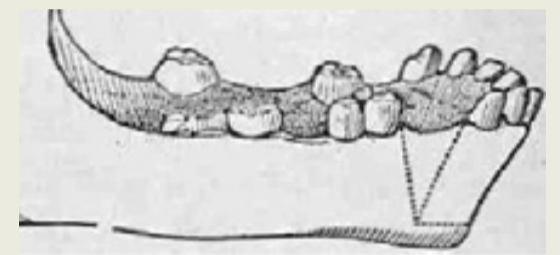
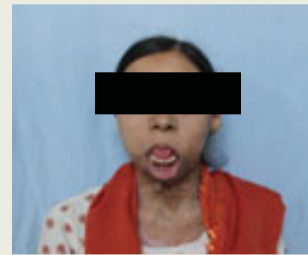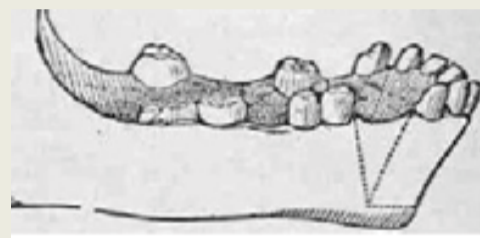
**Holien in 1849**-First orthognathic surgery: in a burns patient to correct mandibular protrusion following burn contracture.

**Wassmund in 1927**- Introduced total maxillary osteotomy & inverted L ramal osteotomy by extra-oral approach.

**Trauner & Obwegeser in 1959**- Introduced Sagittal split osteotomy, the beginning of a new era in orthognathic surgery.

**Epke**

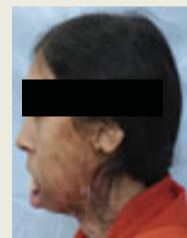
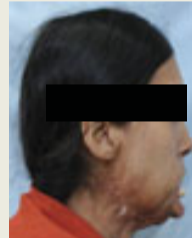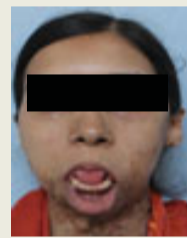Our 27-year-old patient with severe dento-facial deformity due to longstanding burn contractures of 10 years.



## PATIENT EVALUATION

### GENERAL EVALUATION

- General evaluation.
- Medical & dental history.
- Social & psychological evaluation.
- Frontal & aesthetic evaluation.
- Cephalometric evaluation.
  - Skeletal relation.
  - Soft tissue relation.
  - Dental relation.
- TMJ evaluation.



### CEPHALOMETRIC EVALUATION

- Maxilla - normal
- Increased lower facial ht.
- Increased ant & post mand ht.
- Increased gonial angle.

### PSYCHOLOGICAL EVALUATION

Psychological makeup of the patient is important because, despite an objectively favourable treatment result, certain patients will express dissatisfaction with their result due to unrealistic expectations regarding the treatment results.

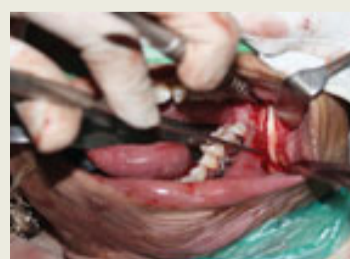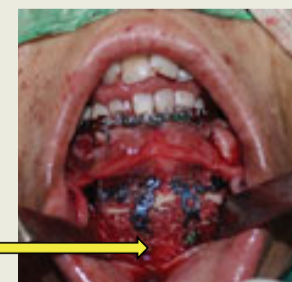
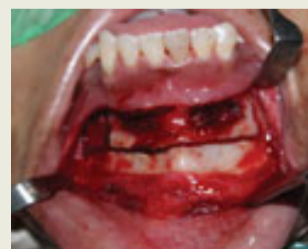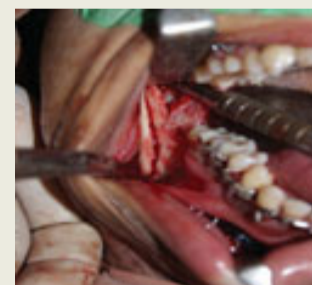## TREATMENT PLANNING

### Inference from COGS analysis

- In horizontal plane, pt B & Pg -more posteriorly placed.
- In vertical plane, increased lower facial height, (ANS-Gn)
- increased post mand divergence (MP-HP angle).
- increased ant. & post. mand height.
- In dental measurements, increased gonial angle.

Anterior sub-apical segmental osteotomy, extraction of 1<sup>st</sup> premolars with anterior setback

Total Mandibular setback with BSSO



DFDBA GRAFT

## RESULTS

### PRE OPERATIVE

### 1 MONTH POST OPERATIVE

