



# Seven years follow up after root fracture and immediate implantation



**Gurbanov S, Grizas E, Nentwig GH**

*Department of Oral Surgery and Implantology J.W. Goethe Universität Frankfurt*

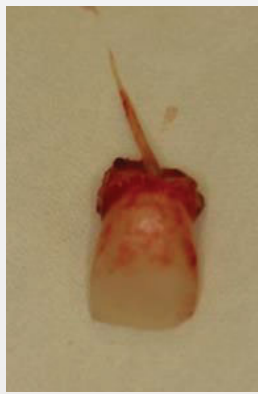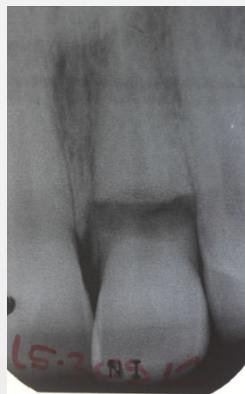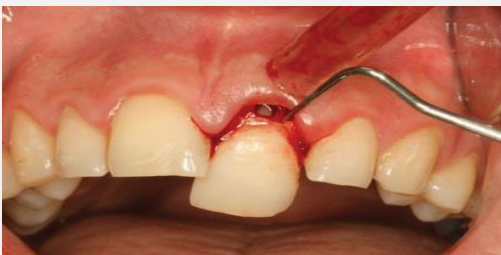## Introduction

A twenty seven years old male patient arrived in our clinic (dental emergency) in 2009 with a root fracture in cervical part with dislocation of the tooth 21 after an injury . A CBCT (Cone Beam Computed Tomography) was performed to identify the bone formation at this region. The patient was informed on different treatment options. As example orthodontic extrusion, Maryland bridge, surgical crown lengthening and immediate implantation. He chose an immediate implant insertion.

Schulte und d'Hoedt described in 1974 immediate implantation with Tübingen Implants in the upper jaw. Later 1977 Ledermann published about immediate loading of implant in lower jaw.

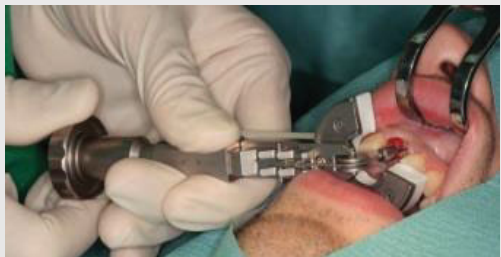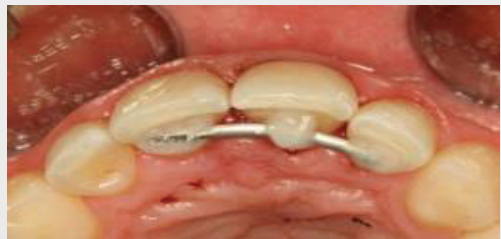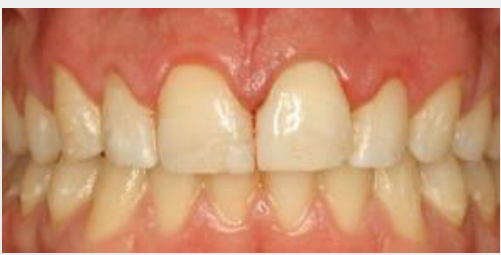## Discussion

The functional and aesthetic treatment was made 4 month later. In this patient a thick gingival biotype, thicker than 1,5 mm ensured the stability of the tissue. This leads to a good forecast of the late aesthetic outcome. Seven years after the surgery a stable soft tissue without any inflammation and recession was present. The peri-implant gingiva was rose and healthy with a textured surface like that seen on the surface of an Orange Peel which is called as Stippled.

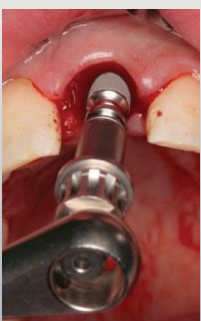

X Ray 11

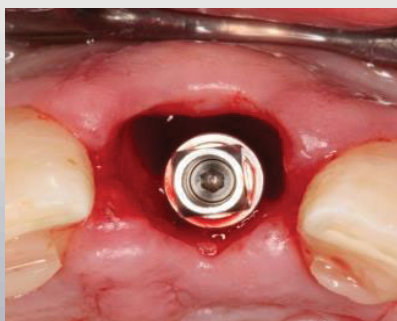
Root fracture 11



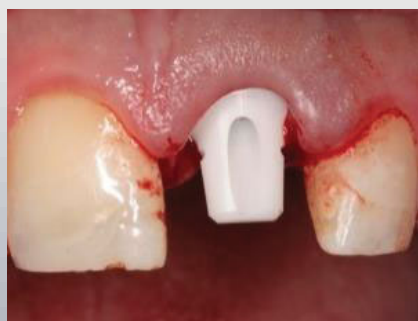Axial extraction with Benex system 21



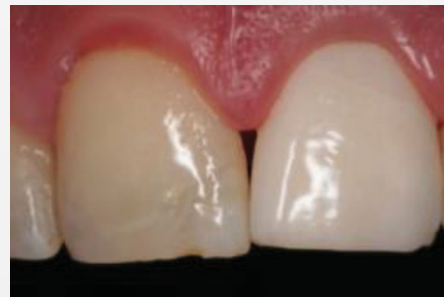Implant position 21



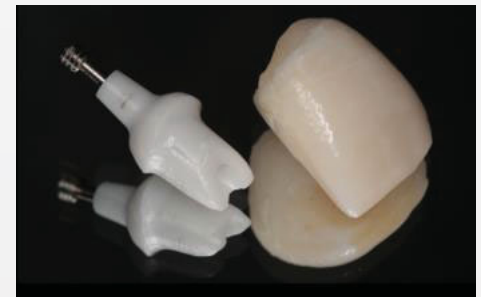Implantat position 21



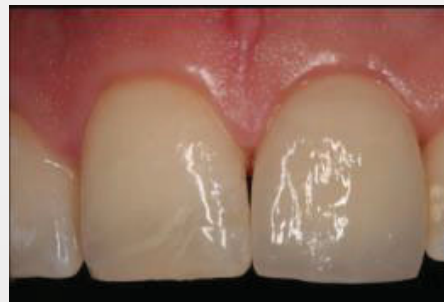Ceramik abutment regio 21



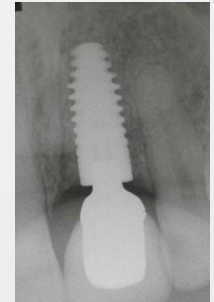Temporary Crown 21



Ceramik abutment



Definitely Crown 21



X Ray 21

## Treatment

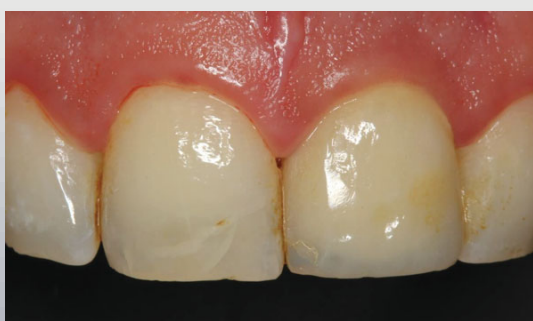Four days after the accident the immediate implant insertion took place. After the extraction with the Benex® extraction system, implant was inserted. The implant was inserted in the right dimensional position, because that is necessary for the aesthetic outcome . The torque of the implants was about 35 Ncm, so an immediate non-occlusal loading was performed.

## Conclusion

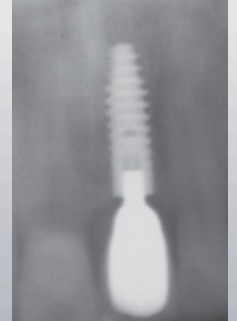
There are a lot of factors which can influence the success of implantation in the aesthetic zone.

High risks for aesthetic failure are patients with gummy smile and patients with thin gingiva type. Our patient had thick gingiva type and low smile line. Chen and Buser showed that immediate or early implantation with simultaneous bone augmentation is more successful than late implantation.

The three-dimensional (3D) position of the osseointegrated dental implants provides favorable esthetical results and preserves the surrounding soft and hard tissues architecture.



Follow up 7 years



Follow up 7 years X Raz

## Contact

Seymour Gurbanov Department of Oral Surgery and Implantology

J.W. Goethe-Universität Frankfurt am Main, Theodor-Stern-Kai 7, Haus 29, D-60590 Frankfurt am Main, dr.gurbanov@web.de

1. Botticelli D, Berglundh T, Lindhe J. Hard-tissue alterations following immediate implant placement in extraction sites. J Clin Periodontol 2004;31:820-828.

2. Evans CD, Chen ST. Esthetic outcomes of immediate implant placements. Clin Oral Implants Res 2008;19:73-80.

3. Grunder U. Crestal ridge width changes when placing implants at the time of tooth extraction with and without soft tissue augmentation after a healing period of 6 months: Report of 24 consecutive cases. Int J Periodontics Restorative Dent 2011;31:9-17.

4. Buser D, Martin W, Belser UC. Optimizing esthetics for implant restorations in the anterior maxilla: Anatomic and surgical considerations. Int J Oral Maxillofac Implants 2004;19(Suppl.):43-61.

5. Sullivan DY, Sherwood RL. Considerations for successful single tooth implant restorations. J Esthet Dent 1993;5(3):118-24.