

# Uncovering dental implants with simultaneous peri-implant soft tissue reconstruction: a case report

Chikany T.<sup>1</sup>, El-Hage JB.<sup>1</sup>, Kemper R.<sup>1</sup>, Gera I.<sup>1</sup>, Windisch P.<sup>1</sup>, Aroca S.<sup>2</sup>

<sup>1</sup> Department of Periodontology, Semmelweis University, Budapest, Hungary

<sup>2</sup> Department of Periodontology, School of Dental Medicine, University of Bern, Bern, Switzerland

## ABSTRACT

**Objectives:** The aim of this case presentation was to evaluate the effectiveness of a surgical technique combining vestibuloplasty, and free gingival graft (FGG) transplantation at the same time as uncovering dental implants.

**Methods:** The patient exhibited inadequate soft tissue condition at the buccal aspect of submerged dental implants (46, 47), 3 months after implant insertion: shallow vestibular fold and less than 1 mm, unstable keratinized mucosa (KM) were present. Following local anesthesia a crestal incision was made above submerged implants, continued in a paramarginal incision at the neighboring dentition. Split thickness flap was elevated, and fixed with resorbable sutures to the underlying periosteum 5-7 mm apically from the incision line. After uncovering the implants, temporary abutments were mounted. A FGG was harvested from the palate, adjusted to cover the exposed periosteal layer, and fixed with resorbable sutures to the underlying periosteum, and to the surrounding KM. Periodontal dressing was applied for 7 days at implant site, palatal donor site was covered with an absorbable collagen fleece with mattress sutures. Sutures were removed 14 days postoperatively.

**Results:** 2-3 mm keratinized mucosa was observed at the buccal aspect of 46, 47 dental implants, with no signs of inflammation. 3 months postoperatively, final restoration was cemented.

Reestablished soft tissue conditions helped to prevent bacterial irritation resulted from masticatory movements, and helped the patient in oral hygiene maintenance.

**Conclusion:** The presented combination of vestibuloplasty and FGG resulted in a stable, soft tissue environment around dental implants in the presented case. Further investigation needed to compare surgical modalities aiming to create KM around dental submerged implants.

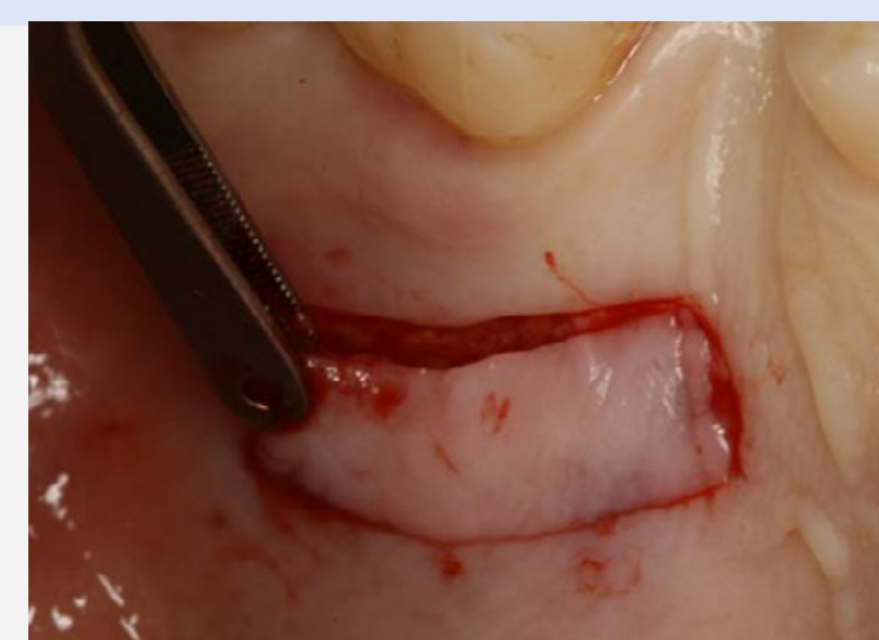

Fig. 6: Harvesting FGG

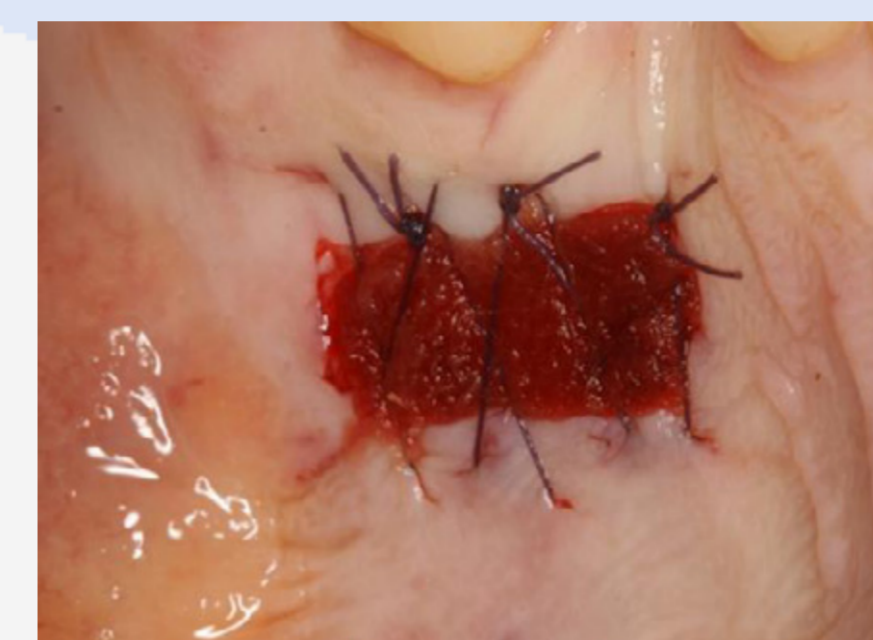

Fig. 7: Palatal donor site sutured

## MATERIAL AND METHODS

A 48-years-old male patient was referred to our clinic with two Denti Bone Level implants (Denti System® - Budapest, Hungary) inserted to site 46 and 47. The patient is non-smoker, he has no known systemic disease, and he has good oral hygiene. Implants had been inserted in a private practice in Budapest 3 months before the first visit in our clinic. There were no postoperative complications after implant insertion. Less than 1 mm keratinized mucosa was present, relocated to the lingual aspect of the mandible with shallow vestibular fold. Only a thin layer of moveable mucosa covered the healing caps of implants. (Fig. 1,2)

After radiographic examination (Fig.3) we could assume that bony healing had been achieved. We indicated mucogingival surgery to our patient with simultaneous uncovering of the healed implants to reestablish keratinized mucosa at the buccal aspect. Before surgery, patient was instructed to rinse his mouth with 0,2 % chlorhexidine-digluconate solution (Curasept®ADS 220, Curaden, Kriens CH) for 3 minutes.

Following local anesthesia a crestal incision was made above submerged implants along the mucogingival line, continued in a paramarginal incision at the neighboring dentition. Split thickness flap was elevated (Fig.4), and fixed with continuous resorbable sutures (Coated Vicryl 5/0, Etichon, East Brunswick NJ, USA) to the underlying periosteum 5-7 mm apically from the incision line (Fig.5). For implant uncovering, a minimally invasive crestal incision was made through the periosteum and the entire keratinized gingiva was attached toward the lingual. After uncovering the implants, temporary abutments were mounted.<sup>18-20</sup>

A 18X5 mm, free gingival graft was harvested from the palate<sup>21-23</sup> (Fig.6). The palatal donor site was covered with an absorbable collagen fleece (Lyostypt® - B.Braun Melsungen AG), and fixed with mattress sutures to enhance local hemostasis (Fig.7). The free gingival graft was adjusted to cover the exposed periosteal layer (Fig.8) and fixed with resorbable, interrupted sutures to the underlying periosteum, and the lingual keratinized mucosa (Fig.9). Wound was covered with periodontal dressing (COE-PAK, GC America Inc., Alsip Ill., USA) (Fig.10).

The patient was instructed to take antibiotics (amoxicillin/clavulanate 1000mg two times daily for one week), and analgesic medication (diclofenac, 50 mg every 6 hours) as needed. Postoperative care consisted of 0,2 % chlorhexidine-digluconate rinses (Curasept®ADS 220, Curaden, Kriens CH) twice a day for 2 weeks, and recall visits to our clinic for professional cleaning every second day, as brushing of the surgical area was not initiated until the beginning of the third postoperative week. Periodontal dressing and palatal sutures were removed at the end of the first postoperative week (Fig.11); sutures from the operated area were removed after 14 day postoperatively (Fig.12). Temporary abutments were replaced to healing abutments one month after the operation (Fig.13). The patient was observed regularly during the healing period of three months, supragingival scaling, oral hygiene instructions were repeated when needed.

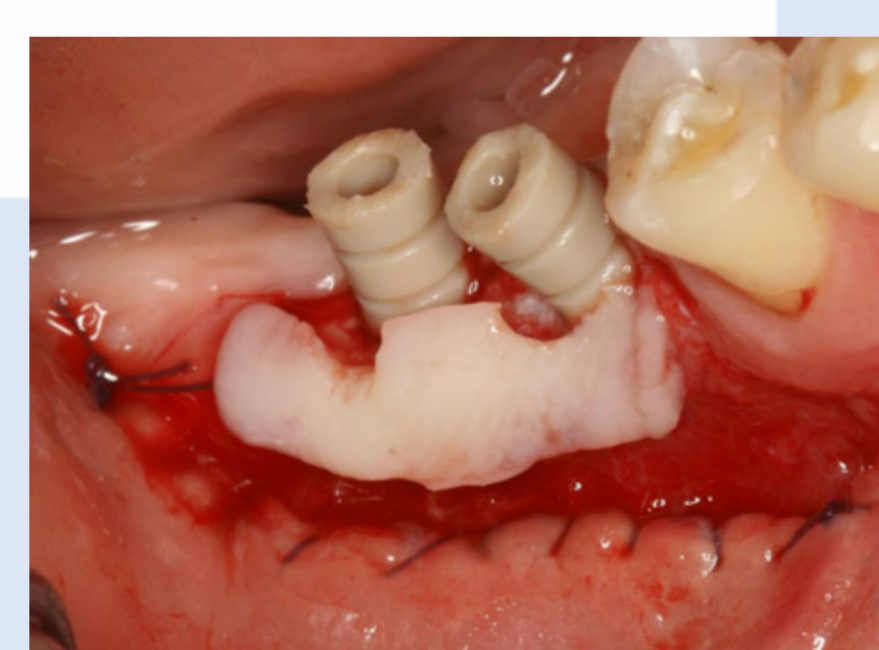


Fig. 8: FGG adaptation to implant sites

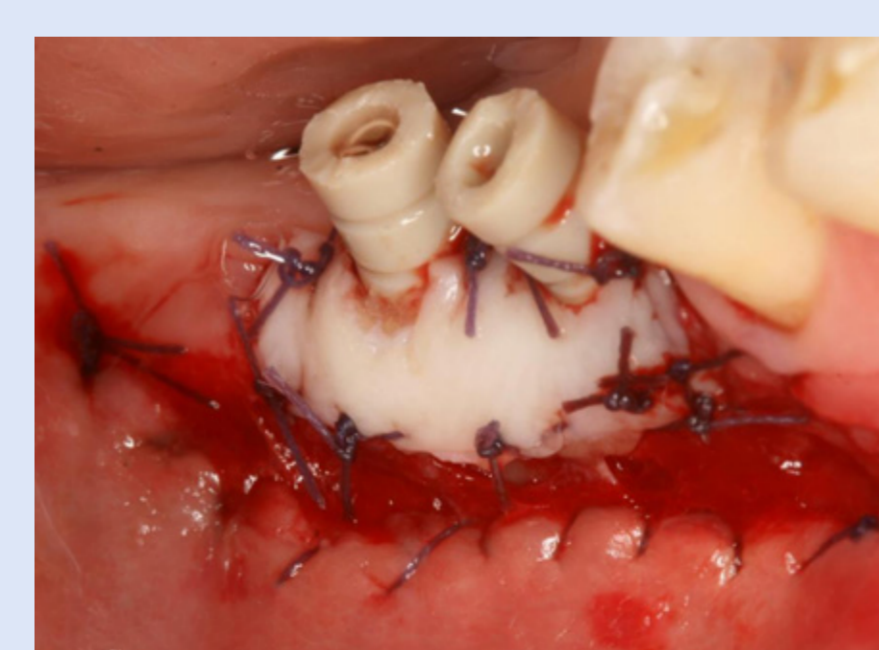


Fig. 9: FGG sutured to implant sites

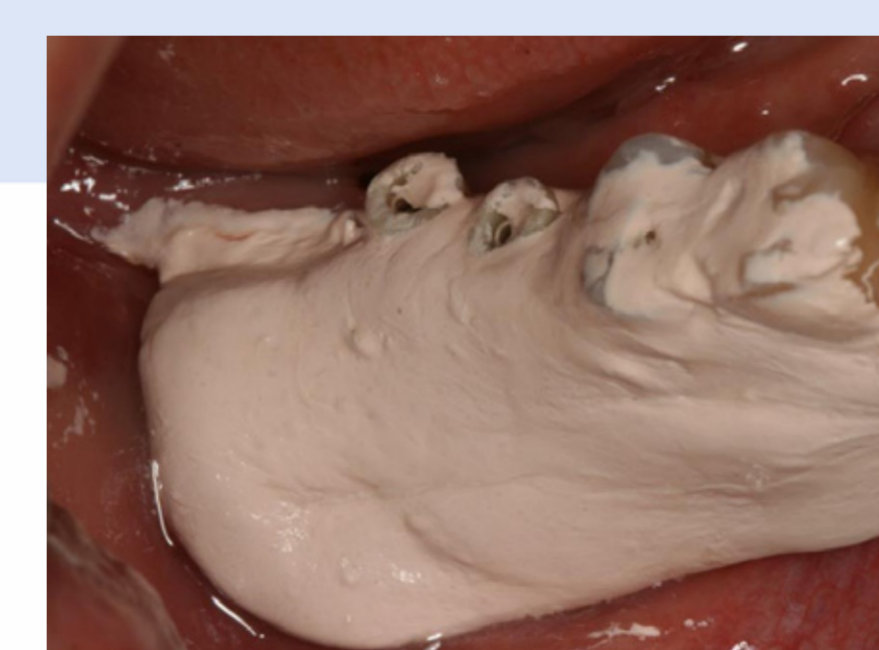


Fig. 10: Application of periodontal dressing

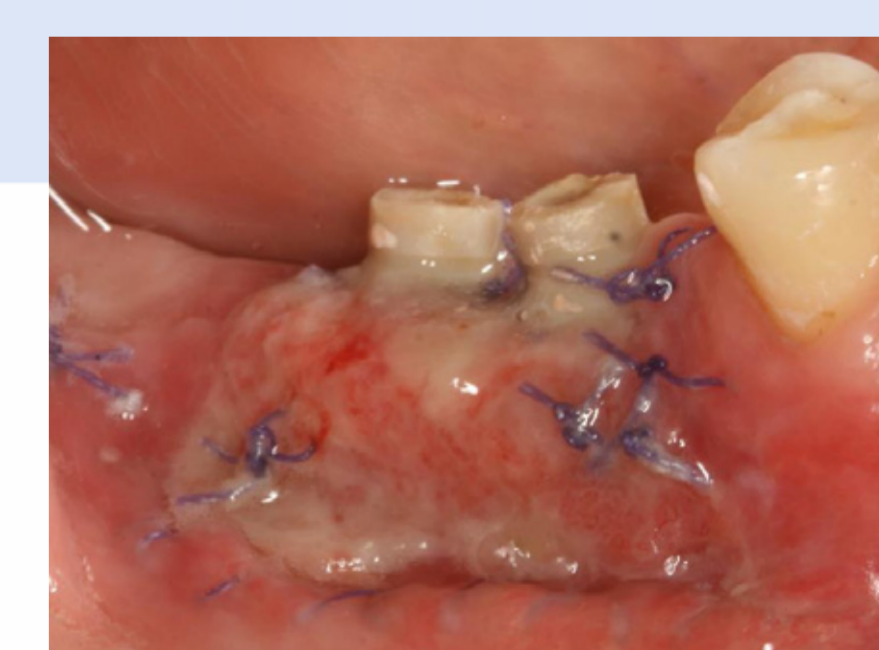

Fig. 11: Wound 7 days postoperatively

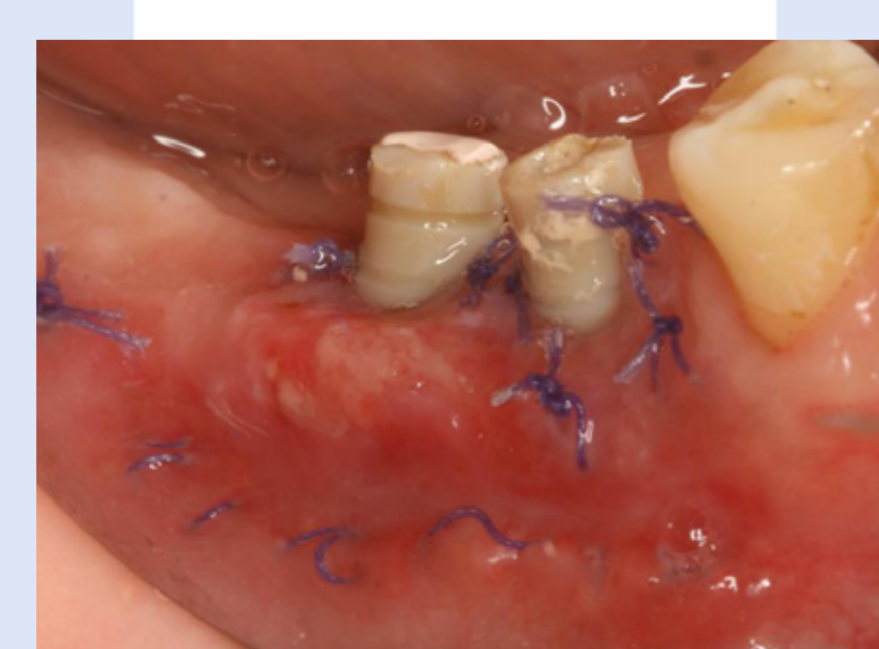

Fig. 12: Wound 14 days postoperatively

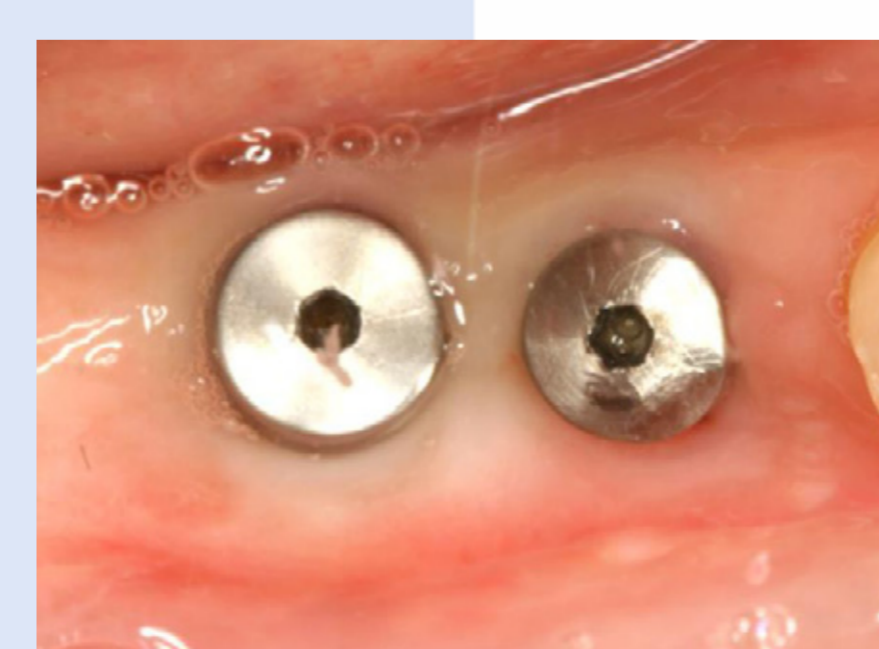

Fig. 13: Wound 1 month postoperatively

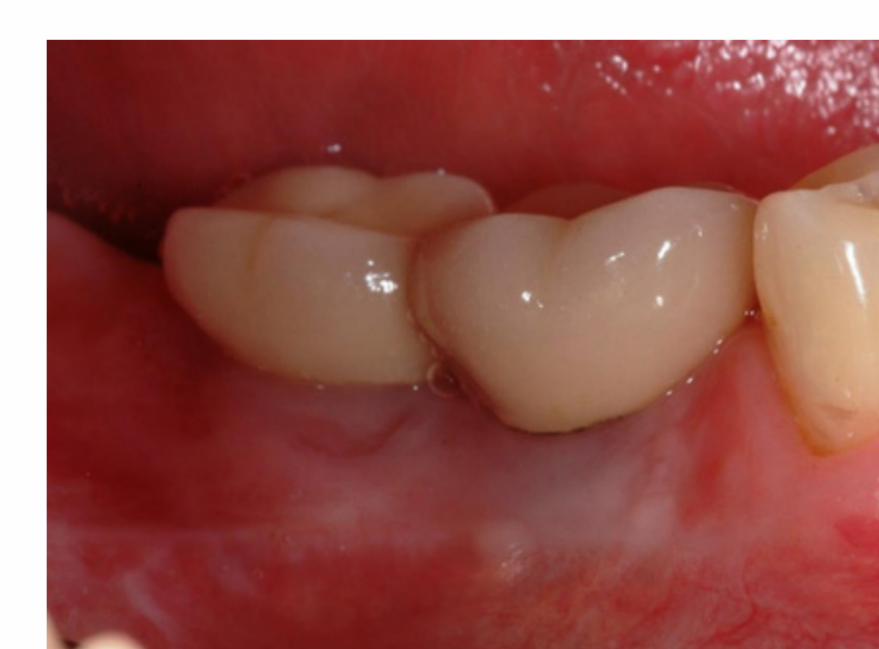

Fig. 14: Final result 6 months postoperatively

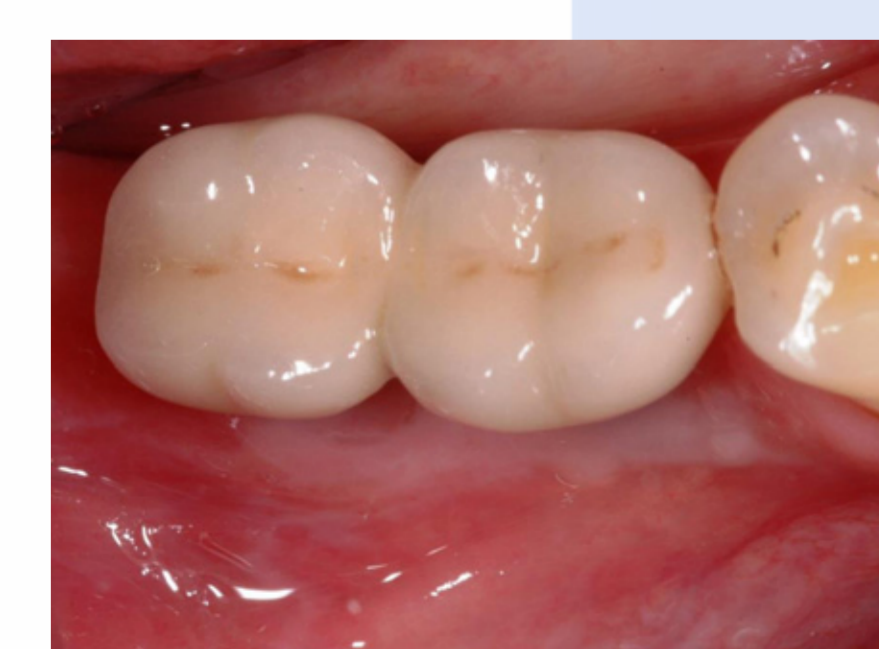

Fig. 15: Final result 6 months postoperatively

## RESULTS

After three months uneventful healing 2-3 mm keratinized mucosa was observed at the buccal aspect of 46, 47 dental implants, with no signs of inflammation. Patient underwent prosthetic phases, and received metal-ceramic crowns cemented to prefabricated titanium abutments.

At the recall visit six months after the surgical operation we could observe, that the width of keratinized tissues had not shrunk any more compared to the 3 months postoperative result (Fig.14,15)<sup>24, 25</sup>. Reestablished soft tissue conditions, such as deepened vestibular fold, and appropriate amount of non-moveable, attached mucosa helped to prevent bacterial irritation results from masticatory movements, and helped the patient to maintain proper home oral hygiene<sup>11,26</sup>. Although compromised esthetic result is general complain among patients treated with free gingival graft transposition, our patient was very satisfied with the result achieved.

## CONCLUSION

Implant treatment of edentulous sites of the posterior mandible is challenging to the clinicians. Tissue remodeling after tooth extraction, result in alterations of the alveolar bone, and the overlying soft tissues as well. Several grafting techniques were described in the dental literature to create appropriate amount of bone for implant placement.<sup>27</sup> More and more study focuses on peri-implant soft tissues in the literature. Integration of an implant necessitates the integration of all types of tissue: bone, connective tissue, and epithelium.<sup>28</sup> Morphology and importance of biological width is well described<sup>29, 30</sup>. Although conflicting data exist in the literature concerning the need for adequate keratinized tissue around endosseous implants, many researcher agree on the need of circular fibers of connective tissue in the supracrestal area, to create a barrier to protect bacterial seed from natural tooth pockets<sup>11</sup>. Some say, that these circular fibers are only present in keratinized tissue<sup>31</sup>.

Edentulous lateral mandibular sites often exhibit shallow vestibular fold, and moveable masticatory mucosa covers the buccal aspect of the alveolar ridge. Bone augmentation procedures require a tension free flap closure, which leads to an additional narrowing of the vestibule. Implant placement with paying no attention to soft tissues could result in moveable, non-stable peri-implant soft tissues on the buccal aspect of endosseous implants. Shallow vestibular fold cannot support proper oral hygiene maintenance, and the movements of masticatory mucosa may lead to bacterial irritation at the gingival closure of dental implants, resulting in periimplant mucositis, or even periimplantitis.

In our case presentation we managed to achieve stable, esthetic, keratinized mucosa at the buccal aspect of lateral mandibular implants. Reestablished vestibular fold resulted in appropriate environment for proper oral hygiene maintenance for the patient. The healing of our patient was uneventful, de reported minimal pain on the donor site, and at the recipient area. However, in the dental literature, complain is often reported about postoperative pain on the palatal area after harvesting free gingival grafts. Further investigation needed to compare surgical modalities aiming to create keratinized mucosa around submerged dental implants.

## INTRODUCTION

Several investigations in the dental literature describe the dimensional changes after tooth extraction.<sup>1-5</sup> Removal of teeth generally result in some alveolar bone loss, as well as structural and compositional changes in the overlying soft tissue, both horizontally and vertically. These changes of the alveolar ridge are more pronounced on the buccal aspect.<sup>4</sup> This resorption process often results in the relocation of the ridge to a more lingual position.<sup>6</sup> These alterations in hard tissues affect the overlying soft tissues of the alveolar ridge.<sup>3</sup> Submerged implant placement means a mucoperiosteal flap elevation. Healing of mucoperiosteal flaps, result in further remodeling of the alveolar bone and soft tissues.<sup>7-9</sup> Following 3 months of healing time we can often observe that the keratinized mucosa is decreased and relocated to a lingual position. Implants are often covered with moveable mucosa by the end of bony healing.<sup>10</sup> After second stage surgery only a thin layer or complete lack of keratinized mucosa can be present at the buccal aspect of healing abutments mounted to osseointegrated dental implants.

The need of adequate amount of keratinized tissues around endosseous implants is controversial in the dental literature.<sup>11, 12</sup> Some of the studies failed to support that the lack of an attached portion of masticatory mucosa may jeopardize the maintenance of soft tissue health around dental implants.<sup>13</sup> Other studies have revealed that the absence of keratinized mucosa around endosseous implant increases the susceptibility of the peri-implant tissues to a plaque-induced destruction.<sup>14, 15</sup> In a recent publication by Greenstein and Cavallero the authors have concluded, that when groups of patients with or without presence of keratinized mucosa were compared in various clinical parameters, a statistically significant better results could be achieved in cases where appropriate amount of keratinized mucosa were present at implant. Although quantitative differences between groups with or without keratinized mucosa were very small, they could indicate, that having keratinized mucosa is advantageous.<sup>16</sup> Simon et al. presented a clinical case, in which progressive recession, and persistent inflammation of the neighboring soft tissues of a dental implant was eliminated, when a free gingival graft was used to augment the attached mucosa.<sup>17</sup>

In our case we decided to increase the amount of keratinized mucosa in the time of uncovering dental implants for preventive reasons. Vestibuloplasty and simultaneous free gingival graft transposition to the buccal aspect of endosseous implants is reported in the literature as a possible treatment option for creating adequate amount of keratinized tissue environment in time of second stage surgery.<sup>17-20</sup>

## LITERATURE

1. Araújo MG, Lindhe J. Ridge alterations following tooth extraction with and without flap elevation: An experimental study in the dog. *Clinical Oral Implants Research* 2009;20:545-549.
2. Tan WL, Wong TLT, Wong MCM, Lang NP. A systematic review of post-extraction alveolar hard and soft tissue dimensional changes in humans. *Clinical Oral Implants Research* 2012;23:1-21.
3. Schropp L, Wenzel A, Kostopoulos L, Karring T. Bone healing and soft tissue contour changes following single-tooth extraction: A clinical and radiographic 12-month prospective study. *International Journal of Periodontics & Restorative Dentistry* 2003;23:133-132.
4. Araújo MG, Sukekava F, Wennström JL, Lindhe J. Tissue modeling following implant placement in fresh extraction sockets. *Clinical Oral Implants Research* 2006;17:615-624.
5. Araújo MG, Sukekava F, Wennström JL, Lindhe J. Ridge alterations following implant placement in the dog. *Journal of Clinical Periodontology* 2005;32:645-652.
6. Batticegli D, Berglundh T, Lindhe J. Hard tissue alterations following immediate implant placement in extraction sites. *Journal of Clinical Periodontology* 2004;31:820-828.
7. Yaffe A, Fine N, Binderman I. Regional accelerated phenomenon in the mandible following mucoperiosteal flap surgery. *Journal of Periodontology* 1994;65:79-83.
8. Kohler CA, Ramfjord SP. Healing of gingival mucoperiosteal flaps. *Oral Surgery, Oral Medicine, Oral Pathology* 1968;39:11-16.
9. Hiatt WH, Stallard RE, Butler ED, Baggett B. Repair following mucoperiosteal flap surgery with full gingival retention. *Journal of Periodontology* 1968;39:11-16.
10. Hakim SG, Driemel O, Jacobsen HG, Hermes D, Sieg P. Exposure of implants using a modified multiple-flap transposition vestibuloplasty. *British Journal of Oral & Maxillofacial Surgery* 2006;44:507-510.
11. Maksud MA. Manipulation of the peri-implant tissue for better maintenance: a periodontal perspective. *The Journal of Oral Implantology* 2003;29:120-123.
12. Chung DM, Oh TJ, Shotwell JL, Misch CE, Wang HL. Significance of keratinized mucosa in maintenance of dental implants with different surfaces. *Journal of Periodontology* 2006;77:1410-1420.
13. Wennström JL, Bengazi F, Lekholm U. THE INFLUENCE OF THE MASTICATORY MUCOSA ON THE PERI-IMPLANT SOFT-TISSUE CONDITION. *Clinical Oral Implants Research* 1994;5:1-8.
14. Warner K, Buser D, Lang NP, Karring T. PLAQUE-INDUCED PERI-IMPLANTITIS IN THE PRESENCE OR ABSENCE OF KERATINIZED MUCOSA - AN EXPERIMENTAL STUDY IN MONKEYS. *Clinical Oral Implants Research* 1995;6:131-138.

15. Kim BS, Kim YK, Yun PY, et al. Evaluation of peri-implant tissue response according to the presence of keratinized mucosa. *Oral Surgery, Oral Medicine, Oral Pathology, Oral Radiology and Endodontology* 2009;107:224-228.
16. Greenstein G, Cavallaro J. The clinical significance of keratinized gingiva around dental implants. *Compend Contin Educ Dent* 2011;32:24-31; quiz 32, 34.
17. Simons AM, Darany DG, Giordano JR. The use of free gingival grafts in the treatment of peri-implant soft tissue complications: clinical report. *Implant Dentistry* 1993;2:27-30.
18. Buser D. Vestibuloplasty with free mucosal grafts in implants in the edentulous mandible. Surgical method and preliminary results. *Schweiz Monatsschr Zahnmed* 1987;97:766-772.
19. Stimmelmayer M, Stangl M, Edelhoff D, Buefer F. Clinical Prospective Study of a Modified Technique to Extend the Keratinized Gingiva Around Implants in Combination with Ridge Augmentation: One-Year Results. *International Journal of Oral & Maxillofacial Implants* 2011;26.
20. Stimmelmayer M, Stangl M, Gerret W, Edelhoff D, Guth JF, Buefer F. Simultaneous implant placement and extension of the keratinized gingiva in the edentulous mandible - A case report. *Implantologie* 2012;20:45-51.
21. Björn H. Free transplantation of gingiva propria. *Odontolog Revy* 1963;14:523.
22. Nuhres JM. Free gingival grafts. *Periodontics* 1966;4:243-245.
23. Sullivan HC, Atkins JH. Free autogenous gingival grafts. I. Principles of successful grafting. *Periodontics* 1968;6:121-129.
24. Agudio G, Nieri M, Rotundo R, Cortellini P, Prato GP. Free gingival grafts to increase keratinized tissue: A retrospective long-term evaluation (10 to 25 years) of outcomes. *Journal of Periodontology* 2008;79:587-594.
25. Hattisoglu H, Koceli HG, Guncu GN, Sengun D, Tözüm TF. Vertical and horizontal dimensional evaluation of free gingival grafts in the anterior mandible: a case report series. *Clinical Oral Investigations* 2007;11:107-113.
26. Khoury F, Hoppe A. Soft tissue management in oral implantology: A review of surgical techniques for shaping an esthetic and functional peri-implant soft tissue structure. *Quintessence International* 2000;31.
27. Chiapasco M, Casertini P, Zaniboni M. Bone Augmentation Procedures in Implant Dentistry. *International Journal of Oral & Maxillofacial Implants* 2009;24:237-259.
28. Cochran DL, Hermann JS, Schenk RK, Higginbottom FL, Buser D. Biologic width around titanium implants. A histometric analysis of the implant-gingival junction around unloaded and loaded nonsubmerged implants in the canine mandible. *Journal of Periodontology* 1997;68:186-197.
29. Berglundh T, Lindhe J. Dimension of the periimplant mucosa - Biological width revisited. *Journal of Clinical Periodontology* 1996;23:971-973.
30. Hermann JS, Buser D, Schenk RK, Higginbottom FL, Cochran DL. Biologic width around titanium implants. A physiologically formed and stable dimension over time. *Clinical Oral Implants Research* 2000;11:1-11.
31. Babush CA, Hahn JA, Krauser JT, Rosenlicht JL. *Dental implants: the art and science*. Saunders; 2010.