

# REGENERATIVE PROCEDURES AND ORTHODONTICS IN THE TREATMENT OF SEVERE INTRABONY DEFECTS

249  
OSTEOLOGY  
MONACO 2013

## A RETROSPECTIVE CLINICAL COHORT STUDY

Christina Tietmann<sup>1</sup>, Frank Bröseler<sup>1</sup>, Tamar Axelrad<sup>2</sup>, Søren Jepsen<sup>2</sup>

<sup>1</sup> Private Practice for Periodontology, Aachen/Germany

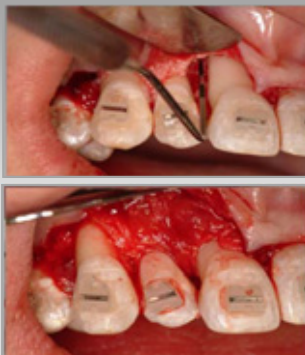<sup>2</sup> Department of Periodontology, Operative and Preventive Dentistry, Univ. Bonn/Germany

### Objectives:

The aim of this study was to evaluate the outcomes of regenerative treatment of intrabony defects in conjunction with orthodontic tooth movements in patients with severe periodontitis.

### Methods:

A total of 526 periodontally severely compromised teeth in 48 patients (age 29–66 years) were treated using bovine derived bone mineral with/without collagen membrane and/or enamel matrix derivative. Orthodontic tooth movements were initiated three months after surgery. Bone levels were measured at time of surgery (T<sub>0</sub>). Periodontal probing depths and digitized and calibrated periapical radiographs were assessed at T<sub>0</sub>, at 12 months (T<sub>1</sub>) and up to 36 months (T<sub>2</sub>). Changes in radiographic bone levels were the primary outcome.

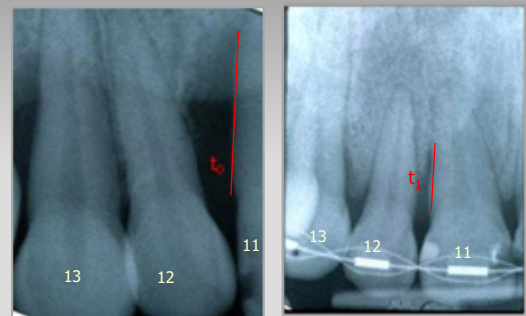

Baseline (t<sub>0</sub>) intrasurgical and radiographic measurement

Follow-up x-ray at 1 year (t<sub>1</sub>) and up to 4 yrs. (t<sub>2</sub>) X-ray standardization using Image-J®

Bone level measurement from standardized x-ray

Descriptive analysis of bone level change at t<sub>0</sub>/t<sub>1</sub> and t<sub>1</sub>/t<sub>2</sub>  
Comparison of Tx groups and subgroups


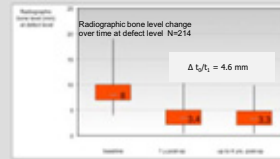
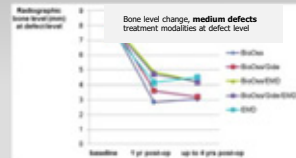
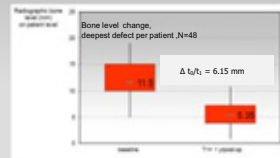
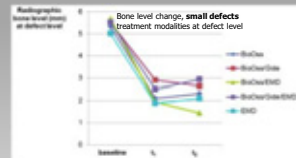
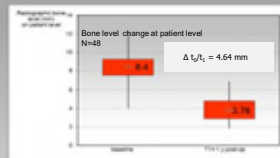


### Defect characteristics: N = 526

- 1-wall defects: 201 (38,2%)
- 2-wall defects: 325 (61,8%)
- Smokers' defects: 34 (13%)
- Males: 49%
- Mean bone level (to CEJ) at baseline 8.52mm

### Patient characteristics: N = 48

- men N=19 (39.6%) / women N=29 (60.4%)
- Mean age 45.2 (29-66yrs.)
- smokers N=6 (12.5%)
- average N of treated defects per patient: 10.5
- Patient inclusion criteria:
- Complete set of x-rays and data available
- Able to perform adequate OH
- Compliance with SPT regimen
- Smokers and systemic diseases not excluded
- Informed consent



**No differences in treatment modalities**

### Treatment variations

- Bovine derived mineral
- Bovine derived mineral and collagen membrane
- Bovine derived mineral and enamel matrix derivative (EMD)
- Bovine derived mineral, collagen membrane, EMD
- EMD

**Substantial radiographic bone gain**

### Results:

From baseline to 12 months the mean PPD reduction was 2.75 mm (from 5.87 mm to 3.12 mm). Radiographic analysis showed a mean mineralized tissue gain of 4.64 mm at 12 months (from 8.4 mm to 3.76 mm) and further clinical improvements up to 3 years. Only one tooth was lost during the observation period. No differences in treatment modalities of regenerative therapy were shown.

### Conclusions:

The results of this retrospective clinical cohort study in patients in need of orthodontic therapy as a consequence of advanced periodontal destruction indicate favorable clinical and radiographic outcomes after periodontal regenerative therapy followed by orthodontic tooth movements. Regenerative periodontal treatment of intrabony defects in conjunction with orthodontic tooth movement resulted in substantial radiographic bone gain up to 3 years.

Special thanks to Dr. M. Mayer, Bern/CH for statistical analyses. The authors declare: no dependency concerning this study.

