

Int Poster J Dent Oral Med 2006, Vol 8 No 04, Poster 337

# Apical seal in root canals filled with three different obturation techniques and two resin-based sealers

**Language:** English

**Authors:**

Dr. Katrin Bekes, Thomas Krüger, Dr. Christian Ralf Gernhardt, Prof. Dr. Hans-Günter Schaller, Department of Operative Dentistry and Periodontology, Martin-Luther-University Halle-Wittenberg

**Date/Event/Venue:**

February, 9th-11th  
The Third CONSEURO 2006  
Rome, Italy

**Introduction**

Complete obturation of the root canal is one of the main goals of endodontic treatment. Several techniques have been developed to improve the obturation quality. Recently, obturation techniques based on heated or preheated gutta-percha have been introduced in order to achieve three-dimensional filling of spaces and isthmuses (1). Two methods of obturation using warmed gutta-percha are the Therafil system (Dentsply Maillefer, Ballaigues, Switzerland) and the warm vertical condensation. A maximum volume of gutta-percha and a thin layer of sealer are preferred because sealer may shrink during setting and dissolve, thus causing leakage (2).

**Objectives**

The aim of the present in vitro study was to compare the apical sealing ability of a warm vertical condensation system (EndoTwin) with lateral condensation and Therafil using two resin-based sealers (AH Plus, EndoRez) (Fig. 1, 2).

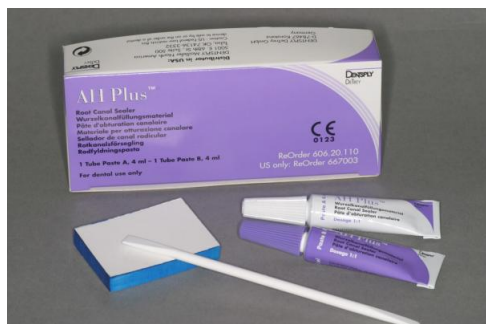

Fig. 1, 2: Root canal sealers used in the study: AH Plus (Dentsply Detrey) and EndoRez (Ultradent Products)

Fig. 1, 2: Root canal sealers used in the study: AH Plus (Dentsply Detrey) and EndoRez (Ultradent Products)

**Material and Methods**

Sixty extracted single rooted maxillary incisors, radiographed to check for a single canal, were selected and stored in saline. Access cavity was prepared and apical patency was confirmed with a #10 K-file. The root length was determined until the file appeared at the apex. Working length was recorded 1 mm shorter. The canal system was prepared using the Hero 642 (Micro-Mega, Besancon, France) system following a standard protocol to a maximum size of #40 under sodium hypochloride (1%) and chlorhexidine digluconate (0.1%) irrigation. The prepared teeth were randomly subdivided into six groups. Root canal fillings were performed using either warm vertical condensation (V), Therafil obturators (T) or cold lateral condensation (L) with EndoRez (E) or AH Plus (A) as sealer (Fig. 1-4).

	Vertical Condensation	Therafil	Lateral Condensation
AH Plus	VA	TA	LA
EndoRez	VE	TE	LE

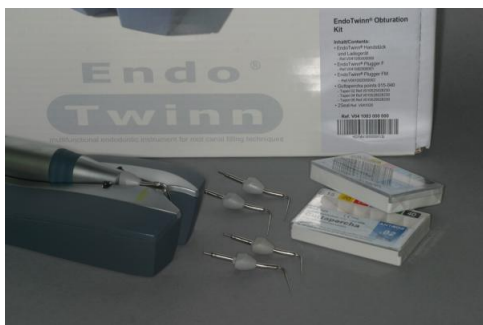

Fig. 3,4: Root canal filling systems used in the present study: Warm vertical condensation system EndoTwin (VDW) and Thermafil system (Dentsply Maillefer)

Fig. 3,4: Root canal filling systems used in the present study: Warm vertical condensation system EndoTwin (VDW) and Thermafil system (Dentsply Maillefer)

After root canal filling, a coronal filling of the endodontic access was done according to a common restorative procedure using dentin bonding agents (Excite; Vivadent, Ellwangen, Schaan, Liechtenstein) and composite material (Tetric Ceram, colour A2; Vivadent). The teeth were checked radiographically for complete obturation. For evaluation of penetration depth, the specimens were dried and coated with two layers of nail varnish, leaving the apical foramen exposed. Each tooth was subsequently immersed in a freshly prepared 5% aqueous methylene blue dye solution (pH 7.0) for seven days at 37°C. Teeth were rinsed in distilled water and sectioned horizontally in 1.0 mm increments using a diamond saw under continuous water cooling. Teeth were oriented so that the sections were perpendicular to their long axis. The first transverse section was made 1mm above working length, including the removal of 1 mm of root at the apical foramen to the limit of apical preparation. Four subsequent sections were made. After sectioning, each of the four sections was digitally viewed at 10x magnification with a stereomicroscope. The borders of gutta-percha, sealer and voids could be distinguished clearly because of their different colours (Fig. 5-9). The total area of each canal section and the areas of its contents (gutta-percha, sealer and voids) were measured in a metric system and converted to percentages using a software program (Fig.13). Statistical analysis was performed using SPSS 10.0. ANOVA and Tukey's test were used to determine significant differences among the groups.

**Results**

Recorded distributions (in %) are shown in Table 1. The total area of gutta-percha was not statistically different among the different obturation techniques ( $p < 0.05$ , Tukey's test). Warm vertical condensation and Thermafil showed significant fewer voids than lateral condensation ( $p < 0.05$ , Tukey's test). The use of either AH Plus or EndoRez was not significant ( $p < 0.05$ , Tukey's test).




Fig. 5-8: AH Plus / Thermafil (section 1-4 mm from the apex)

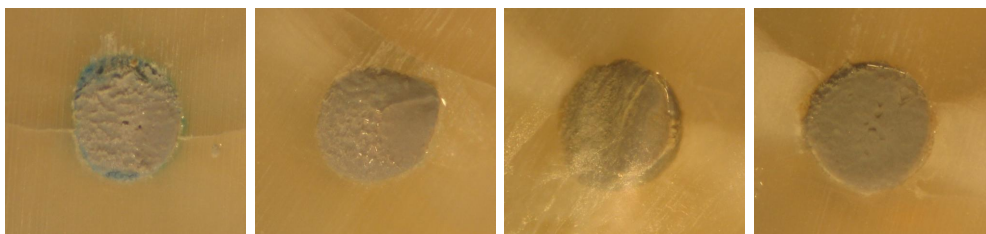
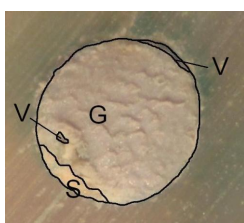


Fig. 9-12: EndoRez / lateral condensation (section 1-4 mm from the apex)



mm	Group VA			Group TA			Group LA			Group VE			Group TE			Group LE		
	G	S	V	G	S	V	G	S	V	G	S	V	G	S	V	G	S	V
1	92.6	7.3	0.1	95.9	3.6	0.5	83.0	14.3	2.7	94.1	5.94	0.0	94.7	5.0	0.3	89.9	9.3	0.8
2	95.1	4.9	0.0	96.1	3.1	0.8	84.1	12.9	3.0	95.3	4.1	0.6	97.1	2.9	0.0	91.4	7.7	0.9
3	96.4	3.3	0.3	94.8	4.4	0.8	84.2	14.2	1.6	96.4	3.3	0.3	98.2	1.8	0.0	93.6	4.7	1.7
4	97.1	2.8	0.0	98.2	4.3	0.4	85.5	11.4	3.1	97.5	2.2	0.2	98.4	1.5	0.1	93.6	4.6	1.8

Fig. 13: Borders of gutta-percha (G), sealer (S) and voids (V).

Tab. 1: Distribution of gutta-percha (G), sealer (S) and voids (V) within the different groups (in %).

## Conclusions

Within the limitations of an in vitro investigation it can be concluded that warm vertical condensation created a better apical seal compared to lateral condensation. The comparison between Thermafil and warm vertical condensation showed no significant differences. Therefore, the clinical use of these two techniques might be a good alternative to the proven cold lateral condensation. Further in vitro and clinical studies have to prove these findings.

## Literature

1. Pommel L, Camps J: In vitro apical leakage of system B compared with other filling techniques. J Endod 2001; 27:449-51
2. DuLac KA, Nielsen CJ, Tomazic TJ, Ferillo PJ Jr, Hatton JF. Comparison of the obturation of lateral canals by six techniques. J Endod 1999; 25: 376-380

*This Poster was submitted by Dr. Katrin Bekes.*

## Correspondence address:

*Dr. Katrin Bekes*

Department of Operative Dentistry and Periodontology  
School for Dental Medicine  
Martin-Luther-University Halle-Wittenberg  
Grosse Steinstrasse 19  
06108 Halle  
Germany

Martin-Luther-University Halle-Wittenberg



# Apical seal in root canals filled with three different obturation techniques and two resin-based sealers



K. BEKES\*, T. KRÜGER, C.R. GERNHARDT, H.-G. SCHALLER

Department of Operative Dentistry and Periodontology, Martin-Luther-University Halle-Wittenberg, Germany

### Introduction

Complete obturation of the root canal is one of the main goals of endodontic treatment. Several techniques have been developed to improve the obturation quality. Recently, obturation techniques based on heated or preheated gutta-percha have been introduced in order to achieve three-dimensional filling of spaces and isthmuses<sup>1</sup>. Two methods of obturation using warmed gutta-percha are the Thermafil system (Dentsply Maillefer, Ballaigues, Switzerland) and the warm vertical condensation. A maximum volume of gutta-percha and a thin layer of sealer are preferred because sealer may shrink during setting and dissolve, thus causing leakage<sup>2</sup>.

### Aim of the study

The aim of the present *in vitro* study was to compare the apical sealing ability of a warm vertical condensation system (EndoTwinn) with lateral condensation and Thermafil using two resin-based sealers (AH Plus, EndoRez) (Fig. 1,2).



Fig. 1: Root canal sealers used in the study: AH Plus (Dentsply Debuy) and EndoRez (Ultradent Products)

### Material and methods

Sixty extracted single rooted maxillary incisors, radiographed to check for a single canal, were selected and stored in saline. Access cavity was prepared and apical patency was confirmed with a #10 K-file. The root length was determined until the file appeared at the apex. Working length was recorded 1 mm shorter. The canal system was prepared using the Hero 642 (Micro-Mega, Besancon, France) system following a standard protocol to a maximum size of #40 under sodium hypochloride (1%) and chlorhexidine digluconate (0.1%) irrigation. The prepared teeth were randomly subdivided into six groups. Root canal fillings were performed using either warm vertical condensation (V), Thermafil obturators (T) or cold lateral condensation (L) with EndoRez (E) or AH Plus (A) as sealer (Fig. 1-4).

	Vertical Condensation	Thermafil	Lateral Condensation
AH Plus	VA	TA	LA
EndoRez	VE	TE	LE



Fig. 3: Root canal filling systems used in the present study: Warm vertical condensation system EndoTwinn (VDW) and Thermafil system (Dentsply Maillefer)

After root canal filling, a coronal filling of the endodontic access was done according to a common restorative procedure using dentin bonding agents (Excite, Vivadent, Ellwangen, Schaan, Liechtenstein) and composite material (Tetric Ceram, colour A2; Vivadent). The teeth were checked radiographically for complete obturation.

For evaluation of penetration depth, the specimens were dried and coated with two layers of nail varnish, leaving the apical foramen exposed. Each tooth was subsequently immersed in a freshly prepared 5% aqueous methylene blue dye solution (pH 7.0) for seven days at 37 °C. Teeth were rinsed in distilled water and sectioned horizontally in 1.0 mm increments using a diamond saw under continuous water cooling. Teeth were oriented so that the sections were perpendicular to their long axis. The first transverse section was made 1mm above working length, including the removal of 1 mm of root at the apical foramen to the limit of apical preparation. Four subsequent sections were made. After sectioning, each of the four sections was digitally viewed at 10x magnification with a stereomicroscope. The borders of gutta-percha, sealer and voids could be distinguished clearly because of their different colours (Fig. 5-12). The total area of each canal section and the areas of its contents (gutta-percha, sealer and voids) were measured in a metric system and converted to percentages using a software program (Fig. 13). Statistical analysis was performed using SPSS 10.0. ANOVA and Tukey's test were used to determine significant differences among the groups.

### Results

Recorded distributions (in %) are shown in Table 1. The total area of gutta-percha was not statistically different among the different obturation techniques ( $p < 0.05$ , Tukey's test). Warm vertical condensation and Thermafil showed significant fewer voids than lateral condensation ( $p < 0.05$ , Tukey's test). The use of either AH Plus or EndoRez was not significant ( $p < 0.05$ , Tukey's test).



Fig. 4-A: AH Plus / Thermafil (section 1-4 mm from the apex)



Fig. 4-B: EndoRez / lateral condensation (section 1-4 mm from the apex)

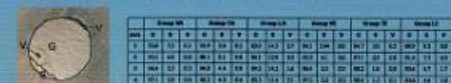


Fig. 13: Borders of gutta-percha (G), sealer (S) and voids (V) within the different groups (in %).

### Conclusions

Within the limitations of an *in vitro* investigation it can be concluded that warm vertical condensation created a better apical seal compared to lateral condensation. The comparison between Thermafil and warm vertical condensation showed no significant differences. Therefore, the clinical use of these two techniques might be a good alternative to the proven cold lateral condensation. Further *in vitro* and clinical studies have to prove these findings.

### References

\*Parvizi L, Camps J: In vitro apical leakage of system B compared with other filling techniques. J Endod 2001; 27:445-51  
 \*DuLee KA, Nelson CJ, Tompich TJ, Ferlie PJ Jr, Nelson JF: Comparison of the obturation of lateral canals by six techniques. J Endod 1989; 25:376-80

Correspondence: Dr. Kathrin Bekes  
 Martin-Luther-University Halle-Wittenberg, School of Dental Medicine, Department of Operative Dentistry and Periodontology, Große Steinstrasse 18, 06109 Halle, Germany; E-Mail: kathrin.bekes@med.uni-halle.de

