

## Differentiation of Cell Lines in Oral Hemangiomas by Surface Markers

**Language:** English

**Authors:** PD Dr.Dr. Johannes Kleinheinz<sup>1</sup>, Dr. Dr. Matthias Kelker<sup>1</sup>, Dr. Dr. Markus Martini<sup>1</sup>, PD Dr. Agnes Bankfalvi<sup>2</sup>, Univ.-Prof. Dr. Dr. Dr. h.c. Ulrich Joos<sup>1</sup>

<sup>1</sup> Department of Cranio-Maxillofacial Surgery,

<sup>2</sup> Department of Pathology,  
Westfälische Wilhelms University Münster

**Date/Event/Venue:**

05. - 07. October 2000

2nd Symposium on Vascular Biology  
Münster, Germany

### Abstract

The classification of hemangiomas and vascular malformations by Mulliken and Glowacki 1982, based on endothelial characterization, resulted in a systematized and standardized description and assessment of vascular lesions. The next step based on this classification, the development of a causal and differentiated therapy, has not been accomplished, as the various treatment protocols still applied show. The increased knowledge about endothelial changes, angiogenesis, anti-angiogenesis and hematopoiesis allows a more specific insight into the development. Nowadays it has been assumed that embryologic development of both hematopoietic and endothelial cell lines are based on the same progenitor cell, the hemangioblast, and that differentiation starts at that point.

The aim of this retrospective study was to analyze the distribution of hematopoietic and endothelial cells and progenitor cells of oral hemangiomas in a collective of children, and to conclude the formation and maturation of the lesions.

The specimens of 20 oral hemangiomas (12 cavernous and 8 capillary) were analyzed. The age of the children at the time of excision was one to eight years. The formalin-fixed and paraffin-embedded specimens were stained immunohistochemically for specific surface cell markers. Proliferation activity was demonstrated by using MIB-1. Antibodies used for this study were CD 31, FLK-1/KDR and VE-Cadherin as markers for endothelial cells, and CD 34, CD 45 and TER 119 as markers for hematopoietic cells. The staining activity was determined by semiquantitative analysis of five at random chosen hot spots of each lesion.

The results showed MIB-1+ staining in all cases demonstrating proliferation activity and excluding resting embryologic malformations. The analysis of cell specific constellations of markers showed 47% angioblasts (CD 31+, FLK-1/KDR+, VE-Cadherin+), 30% hemangioblasts (CD 31+, FLK-1/KDR+, VE-Cadherin+, CD 34+, CD 45-), 9% hematopoietic progenitor cells (FLK-1/KDR+, CD 45+, VE-Cadherin-), 1% non-defined cell line; 13% could not be assigned to one of this groups. The capillary group showed more hematopoietic progenitor cells than the cavernous group. Overall, the endothelial cells seem to be dominant over the hematopoietic cells in oral hemangiomas in infancy. Therefore an intralesional local antiangiogenic therapy in cases of growing and unoperable hemangiomas is conceivable.

### Introduction

The classification of hemangiomas and vascular malformations by Mulliken and Glowacki in 1982 (4) based on endothelial characteristics, led to systematized and standardized description and assessment. Although the knowledge of angiogenesis, vasculogenesis, hematopoiesis and endothelial changes in hemangiomas increased over the last years (1,3) no standardized therapy protocol for true vascular tumors has been developed (2).

### Objective

The aim of this study was to compare the distribution of surface markers for hematopoietic and endothelial cell lines in tissues of oral hemangiomas obtained from a collective of operated children and to conclude the formation and maturation of the lesions.

### Material and Methods

In this retrospective study specimens of 20 oral hemangiomas (12 cavernous and 8 capillary) were analyzed. All were positive for MIB-1/ KI 67 (proliferation marker) and categorized into true and active tumors excluding resting embryologic malformations. The age of the patients at the time of surgery was one to eight years. The formalin-fixed and paraffin-embedded specimens were cut and stained immunohistochemically using five different monoclonal antibodies for endothelial or hematopoietic surface markers (Table 1).

## endothelial markers

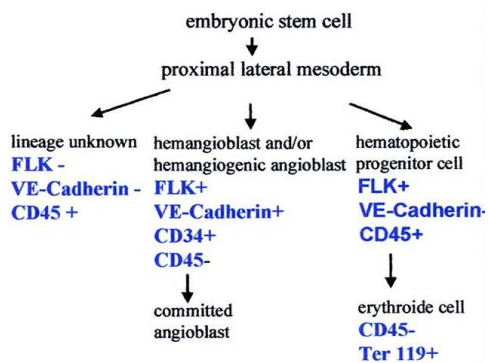
VE-Cadherin	endothelial cell adhesion molecule
CD 31 (PECAM-1)	endothelial cell adhesion molecule
FLK-1/KDR	VEGF receptor 1

## hematopoietic markers

CD 34	hematopoietic progenitor cells
CD 45	leucocyte common antigen
TER 119	erythroid cells

tab.1:List of antibodies used in the study

The staining activity was determined by semiquantitative analysis of five randomly chosen hot spots of each lesion. According to the table of Nishikawa (5) cells were assigned to one of the groups defined by the combination of their surface markers (Table2).



## Results

### cavernous hemangiomas capillary hemangiomas

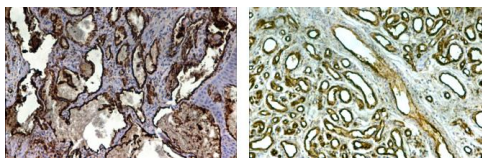


fig.1: CD 31 staining

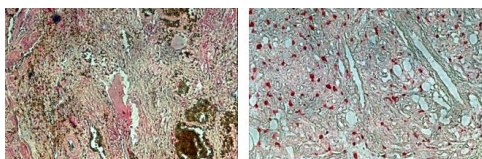


fig.2: FLK-1/KDR staining

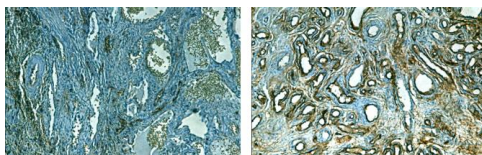


fig.3: CD 34 staining

The overall expression rate of the endothelial markers CD31 and FLK/KDR as well as VE-Cadherin and CD34 in the capillary group was higher than that of the hematopoietic markers. Analysis of cell- specific constellations of markers showed:

47% angioblasts

30% hemangioblasts and /or hemangiogenic angioblasts

- 9% hematopoietic progenitor cells
- 2% erythroide cells
- 1% cell lineage unknown
- 11% could not be assigned to one of these groups

The capillary group showed more hematopoietic progenitor cells than the cavernous group.

## Discussion and Conclusions

In this study the proof of endothelial markers was predominant and a large amount of precursor cells demonstrated. Hemangioblast, postulated by many authors (6, 7), could not be distinguished morphologically. It should be considered as a functional intermediate stage in cell differentiation which can be identified by its specific combination of surface markers. Using immunohistochemical staining other cell lines could also be recognized and assessed by the appearance or non-appearance of markers.

On the basis of this differentiation of hemangiomas in favour of endothelial cell lines a cell-specific therapy by local intralesional application of anti-angiogenic substances in cases of growing and inoperable hemangiomas in early childhood is conceivable.

## Bibliography

1. Chang Jet al.: Proliferative hemangiomas: analysis of cytokine gene expression and angiogenesis *Plast Reconstr Surg* 103:1-9, 1999
2. Kaban LB et al.: Vascular anomalies of the maxillofacial region *J Oral Maxillofac Surg* 44: 203-213, 1986
3. Martin-Padira I et al.: Expression of VE(vascular endothelial)-cadherin and other endothelial-specific markers in hemangiomas *J Pathol* 175: 51-57, 1995
4. Mulliken JB et al.: Hemangiomas and vascular malformations in infants and children: a classification based on endothelial characteristics *Plast Reconstr Surg*69:412-420, 1982
5. Nishikawa SI et al.: Progressive lineage analysis by cell sorting and culture identifies FLK+,VE-Cadherin+ cells at a diverging point of endothelial and hemopoietic lineages *Development* 125:1747-1757, 1995
6. Risau W: Mechanisms of angiogenesis *Nature* 386: 671-674, 1997
7. Takahashi K et al.: Cellular markers that distinguish the phases of hemangioma during infancy and childhood *J Clin Invest* 93: 2357-2364, 1994

*This Poster was submitted by PD Dr.Dr. Johannes Kleinheinz.*

### Correspondence address:

*PD Dr.Dr. Johannes Kleinheinz*

Klinik und Poliklinik für Mund-, und Kiefer-Gesichtschirurgie  
Westfälische Wilhelms-Universität Münster  
Waldeyerstr. 30  
48129 Münster





Department of  
Cranio-Maxillofacial Surgery  
Waldeyerstraße 30,  
48129 Münster, Germany



**P58**

## Differentiation of Cell Lines in Oral Hemangiomas by Surface Markers

J. Kleinheinz<sup>1</sup>, M. Kelker<sup>1</sup>, M. Martini<sup>1</sup>, A. Bankfalvi<sup>2</sup>, U. Joos<sup>1</sup>

<sup>1</sup> Department of Cranio-Maxillofacial Surgery

<sup>2</sup> Department of Pathology, Westfälische Wilhelms University Münster

### Introduction

The classification of hemangiomas and vascular malformations by Mulliken and Glowacki in 1982 (4) based on endothelial characteristics, led to systematized and standardized description and assessment. Although the knowledge of angiogenesis, vasculogenesis, hematopoiesis and endothelial changes in hemangiomas increased over the last years (1,3) no standardized therapy protocol for true vascular tumors has been developed (2). The aim of this study was to compare the distribution of surface markers for hematopoietic and endothelial cell lines in tissues of oral hemangiomas obtained from a collective of operated children and to conclude the formation and maturation of the lesions.

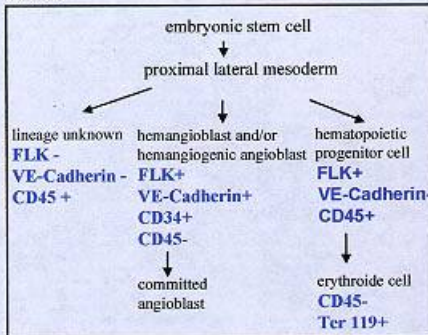
### Material and Methods

In this retrospective study specimens of 20 oral hemangiomas (12 cavernous and 8 capillary) were analyzed. All were positive for MIB-1/ Ki 67 (proliferation marker) and categorized into true and active tumors excluding resting embryologic malformations. The age of the patients at the time of surgery was one to eight years. The formalin-fixed and paraffin-embedded specimens were cut and stained immunohistochemically using five different monoclonal antibodies for endothelial or hematopoietic surface markers (Table1).

endothelial markers	
VE-Cadherin	endothelial cell adhesion molecule
CD 31 (PECAM-1)	endothelial cell adhesion molecule
FLK-1/KDR	VEGF receptor 1
hematopoietic markers	
CD 34	hematopoietic progenitor cells
CD 45	leucocyte common antigen
TER 119	erythroid cells

tab.1:List of antibodies used in the study

The staining activity was determined by semiquantitative analysis of five randomly chosen hot spots of each lesion. According to the table of Nishikawa (5) cells were assigned to one of the groups defined by the combination of their surface markers (Table2).



### Results

#### cavernous hemangiomas

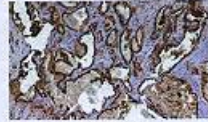


fig.1: CD 31 staining

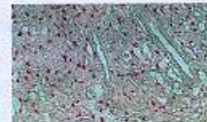
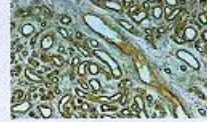


fig.2: FLK-1/KDR staining



fig.3: CD 34 staining

#### capillary hemangiomas



The overall expression rate of the endothelial markers CD31 and FLK/KDR as well as VE-Cadherin and CD34 in the capillary group was higher than that of the hematopoietic markers. Analysis of cell-specific constellations of markers showed:

47%	angioblasts
30%	hemangioblasts and /or hemangiogenic angioblasts
9%	hematopoietic progenitor cells
2%	erythroid cells
1%	cell lineage unknown
11%	could not be assigned to one of these groups

The capillary group showed more hematopoietic progenitor cells than the cavernous group.

### Discussion

In this study the proof of endothelial markers was predominant and a large amount of precursor cells demonstrated. Hemangioblast, postulated by many authors (6, 7), could not be distinguished morphologically. It should be considered as a functional intermediate stage in cell differentiation which can be identified by its specific combination of surface markers. Using immunohistochemical staining other cell lines could also be recognized and assessed by the appearance or non-appearance of markers.

On the basis of this differentiation of hemangiomas in favour of endothelial cell lines a cell-specific therapy by local intralesional application of anti-angiogenic substances in cases of growing and inoperable hemangiomas in early childhood is conceivable.

### References

1. Chang JH et al.: Proliferative hemangiomas: analysis of cyclin gene expression and angiogenesis. *Plast Reconstr Surg* 103:5:8, 1999
2. Kawan LB et al.: Vascular anomalies of the mesofacial region. *J Oral Maxillofac Surg* 61: 2020-2023, 1999
3. Martini M et al.: Expression of fibronectin, endothelial cadherin and other endothelial-specific markers in hemangiomas. *J Pediatr* 175: 61-67, 1999
4. Mulliken JB et al.: Hemangiomas and vascular malformations in infants and children: a classification based on endothelial characteristics. *Head Neck* 24:9:613-627, 2002
5. Nishikawa M et al.: Progressive freeze analysis by cell sorting and culture identifies CD34<sup>+</sup>VE-Cadherin<sup>+</sup> cells at a diverging point of endothelial and hematopoietic lineage. *Development* 125:1747-1757, 1998
6. Raza V: Hemangiomas of infancy. *Indian J Otolaryngol* 1987; 3: 150-154.
7. Takahashi K et al.: Cellular markers that distinguish the genesis of hemangiomas during infancy and childhood. *J Clin Invest* 93: 2557-2564, 1994