

Caroline Felipe Magalhães Girelli, Amanda Pereira dos Santos, Mariana Carvalho Marianelli, Mariane Floriano Lopes Santos Lacerda, Carolina Oliveira de Lima

## The importance of cone beam computed tomography in the management of internal root resorption: a case report



**Caroline Felipe Magalhães Girelli, MSc**

Department of Endodontics, Associação Brasileira de Odontologia Regional de Governador Valadares, MG, Brazil

**Amanda Pereira dos Santos, BDS**

Department of Endodontics, Associação Brasileira de Odontologia Regional de Governador Valadares, MG, Brazil

**Mariana Carvalho Marianelli, BDS**

Department of Endodontics, Associação Brasileira de Odontologia Regional de Governador Valadares, MG, Brazil

**Mariane Floriano Lopes Santos Lacerda, PhD**

Department of Dental Clinic, Federal University of Juiz de Fora, Campus Governador Valadares, MG, Brazil

**Carolina Oliveira de Lima, MSc**

Department of Endodontics, Federal University of Rio de Janeiro, RJ, Brazil

### Correspondence to:

Carolina Oliveira de Lima, Rua Rogério Karp 310, Recreio dos Bandeirantes, Rio de Janeiro, 22795-216 Brazil. E-mail: c.oliveiradelima@yahoo.com.br

**Key words** cone beam computed tomography, diagnostic radiograph, resorption

This case report aimed to demonstrate the importance of cone beam computed tomography (CBCT) for the diagnosis, follow-up and treatment planning of internal root resorption (IRR). A 10-year-old male patient was referred for clinical examination, which revealed a dental fusion in the mandibular right lateral incisor (tooth 42). One year after the sectioning of the fused teeth, a well demarcated radiolucency in tooth 42 was observed by radiography, similar to IRR. CBCT scanning was performed in order to distinguish between external and internal root resorption. After the IRR diagnosis, root canal treatment was performed and no progression of the lesion was observed after 2 years. Thus, CBCT images were useful to delimit the extent of the IRR lesion, being able to identify possible communication sites with the periodontal space, and should be applied in IRR cases.

### Introduction

Internal root resorption (IRR) is the consequence of a chronic inflammation of the dental pulp stimulated by traumatic injury, beginning in the pulpal space and extending into the surrounding dentine. According to the resorption stage, the affected tooth can, initially, be asymptomatic, preserving pulp vitality<sup>1</sup>. Nevertheless, over time, the coronary pulp becomes necrotic, presenting negative responses in pulp tests<sup>2</sup>. Traditionally, the “pink spot” has been thought to be pathognomonic of IRR on the crown, aiding in the diagnosis<sup>1</sup>.

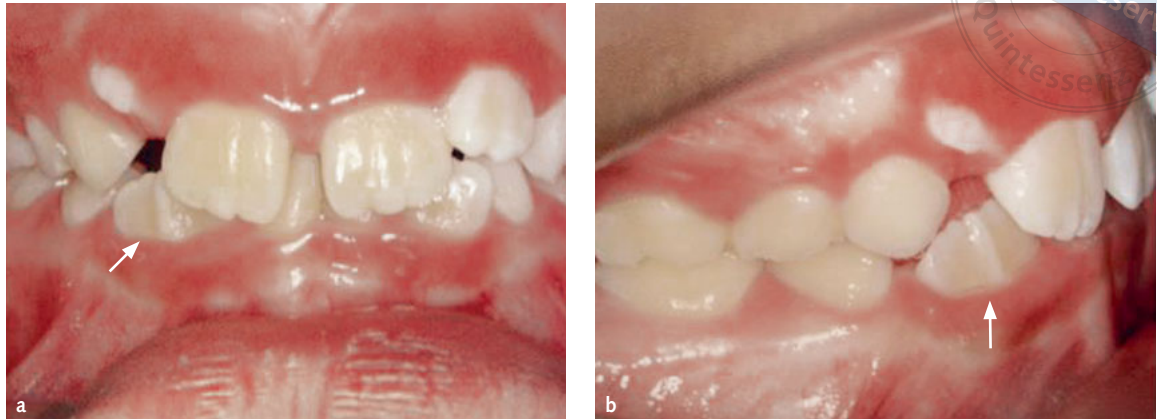Internal resorption is a rare, insidious process that can progress rapidly before detection and is currently incidentally revealed through routine radiographic examination, as a uniform radiolucent area with smooth contours of a rather oval shape, which widens the root canal, most commonly in the cervical region<sup>3</sup>.

Recent studies have indicated that resorption defects can be challenging to diagnose correctly, which may result in inappropriate treatment,

painful symptoms or root perforation, associated with a weakened tooth structure<sup>2-4</sup>. Furthermore, diagnostic accuracy based on conventional radiographic examination is limited by the fact that the images produced by these techniques provide only a two-dimensional (2D) representation, being inaccurate concerning internal resorption communication with periodontal ligaments, with the added disadvantage that the anatomical structures being imaged may be distorted<sup>5,6</sup>.

The diagnosis and evaluation of resorption by three-dimensional (3D) images are, thus, relevant in order to ascertain treatment complexity and referred results according to the resorption location and extent<sup>4,7,8</sup>.

To obtain auxiliary information in clinical endodontics, cone beam computed tomography (CBCT) imaging can be applied during all treatment phases, including diagnosis and treatment planning, as well as during the treatment phase and through both the post-treatment assessment and follow-up, to evaluate root canal preparation and obturation, as



**Fig 1** Frontal (a) and lateral (b) photographs showing the clinical situation of the child's dentition. The presence of fused teeth can be observed next to tooth 42 (arrow), which prevents the eruption of tooth 43.

well as for retreatment, surgical endodontics and experimental studies. CBCT allows for 3D inspection in the axial, sagittal and coronal views, in addition to the evaluation of IRR location and size, without anatomical overlaps<sup>3,6,9</sup>.

Therefore, the aim of the present case report was to demonstrate the importance of CBCT for the diagnosis, follow-up and treatment planning of IRR.

### ■ Case report

A healthy 10-year-old male patient was referred for clinical examination in a private dental office in 2014, complaining about aesthetics due to an unerupted mandibular tooth. Clinically, the presence of fused teeth was observed, suggesting a shape anomaly, presenting a groove between the distal area of the mandibular right lateral incisor (tooth 42) and the mesial area of the supernumerary tooth, which prevented the eruption of the mandibular right canine (tooth 43) (Fig 1).

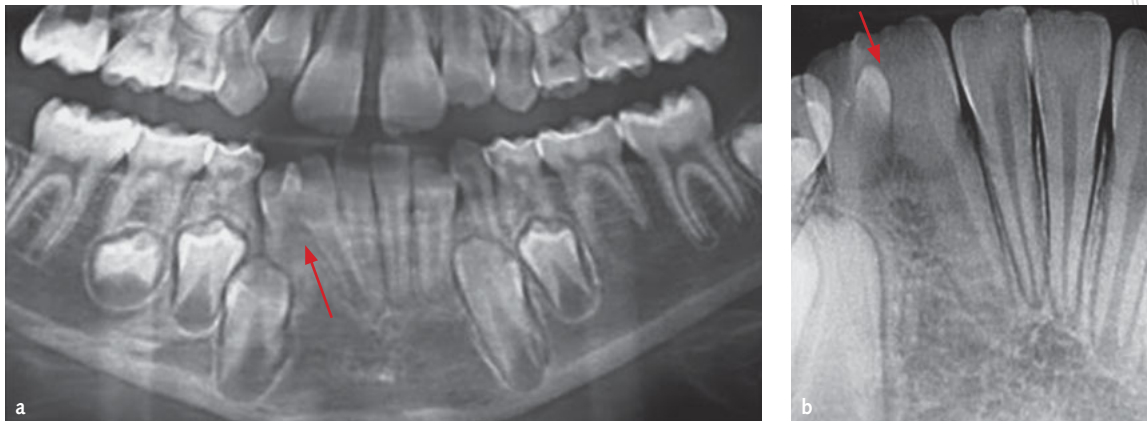
After radiographic evaluation, a diagnosis of dental fusion was made (Fig 2), due to the fusion between teeth dentine and enamel<sup>10</sup>, with no connection of the pulp spaces.

After signed parental consent, sectioning of the fused teeth was carried out with a high rotation conical trunk diamond drill, under water cooling. Subsequently, the fused tooth was extracted and tooth 42 was restored with a composite resin. The patient was submitted to an orthodontic treatment with a space maintainer (Fig 3a).

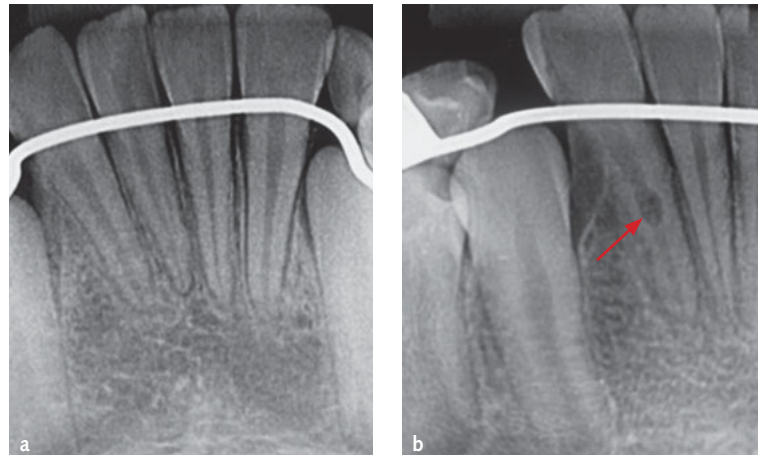
One year after treatment, in 2015, clinical and radiographic reviews were carried out, revealing ballooning outside the pulpal root canal, which was previously diagnosed as IRR, possibly associated with external resorption (Fig 3b). Before a definitive diagnosis, an iCAT (Imaging Sciences International, Hatfield, PA, USA) CBCT was requested to check the extent of the lesion. After evaluation of the axial, coronal and sagittal sections, the size of root dentine loss was evaluated and no communication between the root canal and the adjacent periodontium was detected, confirming the IRR diagnosis (Fig 4).

According to the diagnosis, root canal treatment was initiated. An absolute isolation of the access to the root canal was carried out at tooth 42, followed by irrigation with 5.25% sodium hypochlorite. The Ruddle technique was applied during the mechanical preparation, pre-extending the mid-cervical third with sizes 15 to 40 K-files (Dentsply Maillefer, Ballaigues, Switzerland) and sizes 1 to 4 Gates Glidden drills (Dentsply Maillefer). Subsequently, the working length (WL) was set to 1 mm short of the apex, by using the apex locator (Endex, Los Angeles, California, USA), and the apical stop was performed with a size 40 K-file. The root canal was constantly irrigated with 5.25% sodium hypochlorite (Fórmula e Ação, São Paulo, SP, Brazil) during instrumentation using a 5 mL syringe and a 27-G endodontic needle at 2 mm from the WL.

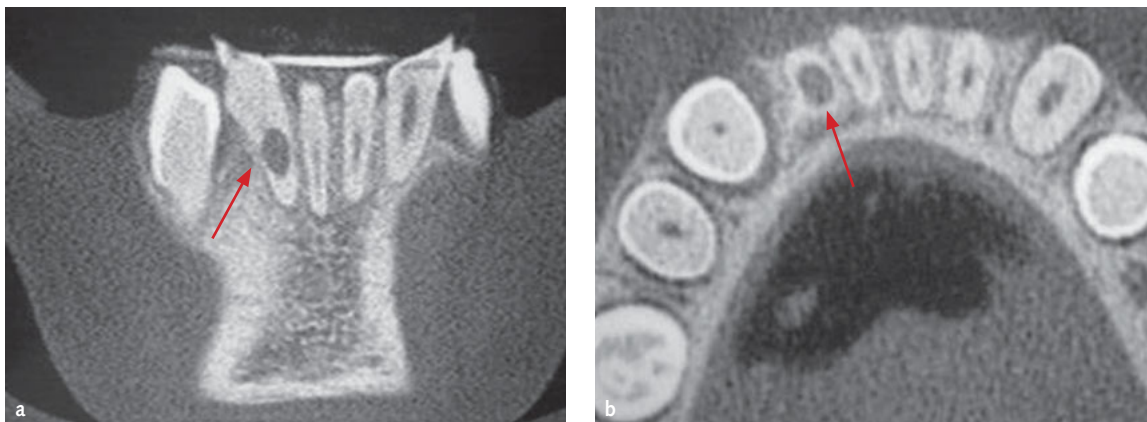Because of the IRR, intense bleeding during the chemical-mechanical preparation occurred. Thus, the final irrigation was conducted with 3 mL of 17% ethylenediaminetetraacetic acid (EDTA; Fórmula



**Fig 2** Panoramic image (a) and periapical image (b) showing dental fusion between tooth 42 and the supernumerary tooth (arrow), preventing the eruption of the canine (tooth 43) (arrow).



**Fig 3** (a) Periapical radiograph showing the result after fused teeth sectioning, extraction of the supernumerary tooth and restoration of tooth 42. (b) Periapical radiograph after placement of space maintainer, observing radio-lucent area suggestive of IRR in tooth 42 (arrow).

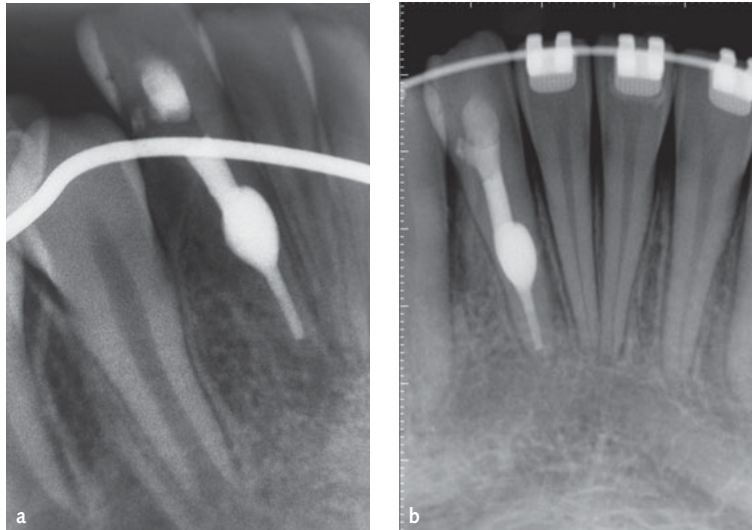
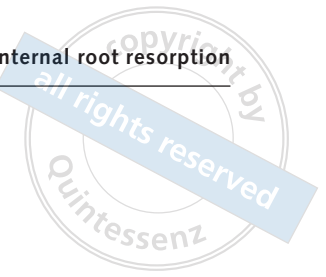


**Fig 4** (a) Coronal CBCT image section demonstrating that there was no perforation caused by evolution of internal resorption (arrow). (b) Axial CBCT image section showing dentinal tissue surrounding the lesion (arrow).

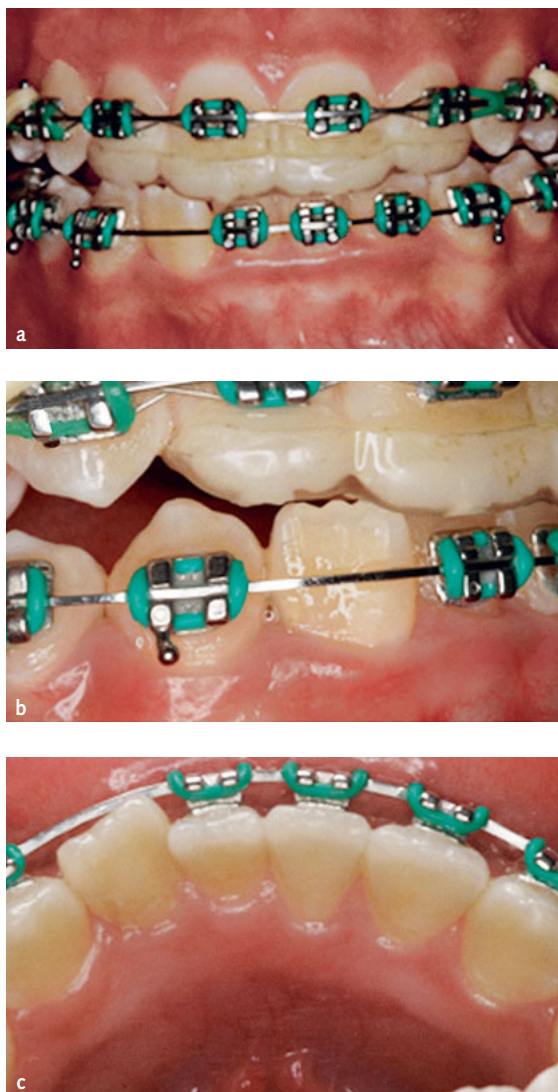
e Ação) for 3 minutes to remove the smear layer and medicinal paste was inserted in the canal. To this end, 1 mg of  $\text{Ca}(\text{OH})_2$  (Biodinâmica, Ibioporã, PR, Brazil) was mixed with 1 mL of saline solution

(Fórmula e Ação), to achieve a paste consistency. The mixture was inserted into the root canal with a size 40 K-file (Dentsply Maillefer) until WL and the access cavity was sealed with a temporary Cavit





**Fig 5** (a) Periapical radiographic image after root canal therapy. (b) Follow-up periapical radiographic image after 2 years of treatment.



**Fig 6** Photographs showing clinical aspect of the tooth 2 years after root canal treatment: (a) frontal, (b) lateral and (c) palatal views.

material (3M Espe, St Paul, MN, USA). Later, the root canal was obturated by the vertical compaction heated gutta-percha technique using Obtura (Sybron Endo, Orange, CA, USA) and Pulp Canal Sealer (Pulp Canal Sealer EWT; Kerr, Orange, CA, USA). The access cavity was sealed with composite resin Filtek Z250 (3M, Sumaré, SP, Brazil). After root canal treatment a postoperative radiograph was taken to verify the root canal filling (Fig 5).

Preservation was observed up to 2 years after treatment with clinical examination and periapical radiography, and no progression of the resorptive lesion occurred, with absence of changes in the periapical and periodontal tissues, evidencing the success of the treatment (Fig 6).

## ■ Discussion

IRR is usually asymptomatic and discovered by chance during routine examination. The extent of the progression is also determined by the intensity of stimuli and inflammatory progress, which depends on the viable blood supply of vital pulp tissue, as in cases of avulsion, dislocation and coronary fractures<sup>10</sup>. In this case report, sectioning of fused teeth was carried out with a high rotation conical trunk diamond drill under cooling, followed by extraction of the fused element and restoration of tooth 42 with a composite resin, which may have caused physical and chemical injury to the pulp tissue, stimulating inflammatory resorption.

When IRR is clinically detected, a pulpectomy is required to arrest the process. Therefore, root canal therapy is opted for evident internal resorption, and bleeding within the canal should cease quickly on pulp extirpation, as the source of blood supply originates from the granulation tissue<sup>2,3,5</sup>. When resorption progresses through the dentine, the dentist faces additional problems, such as periodontal inflammation, continuous bleeding of the root canal after pulp extirpation, and difficulty in sealing the root canals<sup>11</sup>, which were all observed in the present case.

A radiographic diagnosis is essential to ensure early discovery and correct treatment of the affected tooth. Conventional radiographs are frequently used to detect and follow root resorption, which appears as a well-demarcated, round-to-oval radiolucent widening or ballooning out of the root canal, continuous with the walls of the canal itself on the radiograph<sup>2</sup>. However, IRR radiolucencies are typically undetectable in radiographs at an early stage (due to their small size) or because of the limitations of this 2D method<sup>12</sup>.

In this case report, IRR was detected when a periapical radiograph was performed, and after continuous bleeding during instrumentation, doubts originated regarding the extent of the lesion and if communication existed between the root canal and the external root surface, which requires more care during irrigation and obturation. For this reason, a CBCT was requested.

Vasconcelos et al<sup>13</sup> showed that the 2D nature of conventional radiographs limits the obtained information, since the quality of radiographic images is affected by the angle of the x-ray spectrum, leading to anatomical superimpositions during image preparation steps, which leads to difficulties in determining what disease process has occurred, and whether internal or external resorption, or both, was the initiating factor.

Currently, CBCT is used in the diagnosis or during the endodontic treatment of selected cases, when conventional radiographs are not sufficient to solve clinician doubts<sup>4,14</sup>. Several authors<sup>4,13,15</sup> indicated that the main CBCT benefit over conventional radiography is the 3D image, which is more accurate and can elucidate the nature of the resorptive defect, thus enabling correct diagnoses,

which, in turn, lead to the selection of appropriate techniques and favourable prognoses. Furthermore, CBCT provides a cross-sectional 3D image with lower radiation doses, shorter scanning time, fewer artefacts and is less costly in comparison to conventional medical CT. In agreement, Friedland et al<sup>16</sup> indicated that cone beam computed tomographic imaging may overcome conventional radiographic imaging problems by producing 3D images of teeth and surrounding tissues.

In this case, no perforation by IRR was observed after CBCT. As expected, the images were highly advantageous in the diagnosis and confirmation of anatomical integrity of external surfaces of the root and adjacent alveolar bone<sup>2</sup>, useful in defining the type of care adopted during endodontic intervention, obtaining a better prognosis. Due to non-communication between IRR and the root surface, the treatment protocol was not modified during conventional irrigation and obturation with gutta-percha plus canal sealer. Filling of the root canal system was performed under vertical compaction by the heated gutta-percha technique, with no risk of material extrusion, thus not requiring mineral trioxide aggregate (MTA) to seal communications.

After 2 years of preservation, the patient did not present any painful symptoms and a regression of the lesion was radiographically observed, without lateral resorption, demonstrating success in the IRR treatment.

This case report emphasizes the valuable contribution of CBCT for correct IRR diagnosis and treatment. Nevertheless, CBCT is not recommended as the first choice in endodontic procedures, due to the high radiation dose received by the patient when compared to conventional periapical radiography<sup>2,14</sup>.

Recently, the European Society of Endodontology (ESE) has presented guidelines for the use of CBCT in the diagnosis and treatment of pulp diseases, to balance patient protection and the progress of the radiographic technique, decreasing radiation doses<sup>17</sup>. Through this case report, it is clear that CBCT should be considered a viable option for the diagnosis, localization and delimitation of the extent of the resorptive injury, being useful in the support of endodontic treatment.

## ■ Disclosure statement

The authors certify that they do not have any commercial or associated interest that represents a conflict of interest in connection with this paper.

## ■ References

1. Levin L, Trope M. Root resorption. In: Hargreaves KM, Goodies HE, Seltzer S. Seltzer and Bender's dental pulp. Chicago: Quintessence Publishing, 2002;425–448.
2. Perlea P, Nistor CC, Iliescu MG, Iliescu AA. The use of cone beam computed tomography in the diagnosis and management of internal root resorption associated with chronic apical periodontitis: a case report. *Rom J Morphol Embryol* 2015;56:223–227.
3. Patel S, Dawood A. The use of cone beam computed tomography in the management of external cervical resorption lesions. *Int Endod J* 2007;40:730–737.
4. Patel S, Dawood A, Whaites E, Pitt Ford T. New dimensions in endodontic imaging: part 1. Conventional and alternative radiographic systems. *Int Endod J* 2009;42:447–462.
5. Cohenca N, Simon JH, Mathur A, Malfaz JM. Clinical indications for digital imaging in dento-alveolar trauma. Part 2: root resorption. *Dent Traumatol* 2007;23:105–113.
6. Kamburoğlu K, Barenboim SF, Kaffe I. Comparison of conventional film with different digital and digitally filtered images in the detection of simulated internal resorption cavities: an ex vivo study in human cadaver jaws. *Oral Surg Oral Med Oral Pathol Oral Radiol Endod* 2008;105:790–797.
7. Marmulla R, Wörtche R, Mühling J, Hassfeld S. Geometric accuracy of the NewTom 9000 Cone Beam CT. *Dentomaxillofac Radiol* 2005;34:28–31.
8. Alqerban A, Jacobs R, Souza PC, Willems G. In-vitro comparison of 2 cone-beam computed tomography systems and panoramic imaging for detecting simulated canine impaction-induced external root resorption in maxillary lateral incisors. *Am J Orthod Dentofacial Orthop* 2009;136:1–11.
9. Shemesh H, Cristescu RC, Wesselink PR, Wu MK. The use of cone-beam computed tomography and digital periapical radiographs to diagnose root perforations. *J Endod* 2011;37:513–516.
10. Persic Bukmir R, Braut A, Brekalo Prso I. Conservative endodontic management of a fused tooth: a case report. *Gerodontology* 2017;34:398–400.
11. Gutmann JL, Dumsha T, Lovdahl PE. Problem solving in endodontics: prevention, identification, and management, 4th edition. St Louis: Mosby Elsevier, 2005;311–336.
12. Celikten B, Uzuntas CF, Kurt H. Multiple idiopathic external and internal resorption: case report with cone-beam computed tomography findings. *Imaging Sci Dent* 2014;44:315–320.
13. Vasconcelos Kde F, de-Azevedo-Vaz SL, Freitas DQ, Haiter-Neto F. CBCT post-processing tools to manage the progression of invasive cervical resorption: a case report. *Braz Dent J* 2016;27:476–480.
14. Celikten B, Tufenkci P, Aksoy U, et al. Cone beam CT evaluation of mandibular molar root canal morphology in a Turkish Cypriot population. *Clin Oral Investig* 2016;20:2221–2226.
15. Bhuvu B, Barnes JJ, Patel S. The use of limited cone beam computed tomography in the diagnosis and management of a case of perforating internal root resorption. *Int Endod J* 2011;44:777–786.
16. Friedland B, Faiella RA, Bianchi J. Use of rotational tomography for assessing internal resorption. *J Endod* 2001;27:797–799.
17. Patel S, Durack C, Abella F, et al. European Society of Endodontology position statement: The use of CBCT in Endodontics. *Int Endod J* 2014;47:502–504.