



The three-layer technique for immediate implants on teeth without a buccal bone wall: a case report

David González, DDS, PhD

Specialist in Periodontics, Clinica OrtoPerio, Murcia, Spain

Gustavo Cabello, DDS

Specialist in Periodontics, Clinica Nexus, Spain

Gema Olmos, DDS

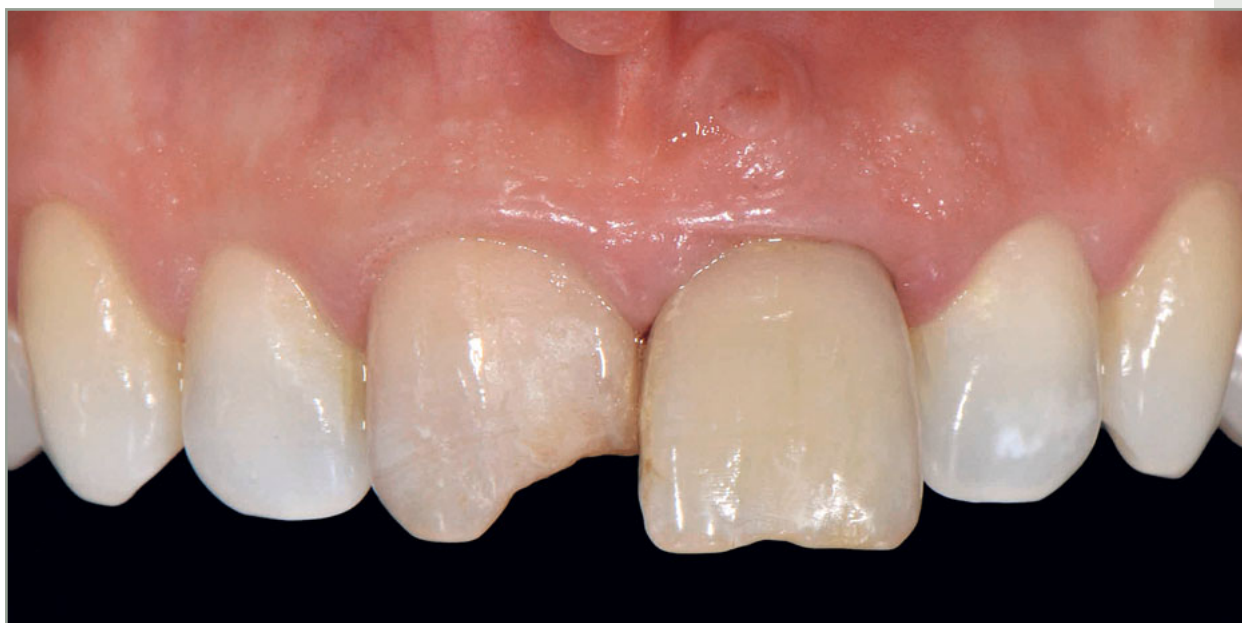Specialist in Orthodontics, Clinica OrtoPerio, Murcia, Spain

Emilia López Hernández, DDS

Postgraduate, Prosthetic Program, University Hospital Freiburg, Germany

Carlos L Niñoles, DDS

Specialist in Prosthodontics, Private Practice, Alicante, Spain



Correspondence to: Dr David González

Clinica OrtoPerio, C.C. Centrofama, 1st floor, 30008 Murcia, Spain; Fax: +34 968 205 433; Email: dr.gonzalez@ortoperio.net

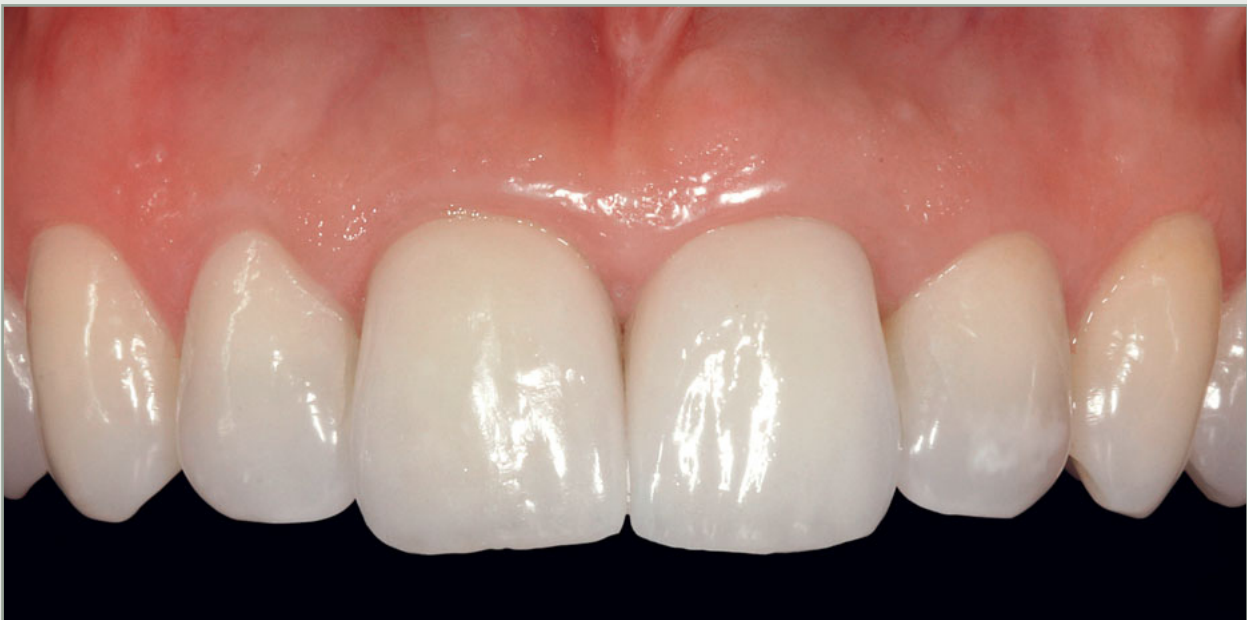

Abstract

The buccal bone wall is the part of the socket of an anterior tooth that is most susceptible to resorption. Immediate implants offer advantages in terms of time, comfort, and esthetics, especially regarding the maintenance of the papillae architecture. However, the loss of the buccal bone wall is often a limitation for such a therapy. This case report describes a clinical procedure designed to reconstruct the buccal bone wall to restore an anterior tooth where this wall was absent. The approach involved a flapless immediate implant based on the principles of guided bone regeneration

(GBR), and consisted of the preparation of a large, flapless recipient bed *ad modum* envelope, immediate implant placement, deposition of xenograft surrounding the implant surface, and coverage with a collagen membrane. Finally, a palatal connective tissue graft (CTG) was placed, and the natural tooth crown acting as a temporary restoration was delivered. One year later, a zirconia-ceramic crown was delivered. Two years after implant placement, the soft tissue level was stable. No signs of inflammation or bleeding were observed, and periapical radiographic examination revealed bone stability.

(*Int J Esthet Dent* 2018;13:358–376)





Introduction

Immediate implant placement is a therapy that usually obtains good esthetic, health, and functional results.^{1,3} One of the established requirements for a predictable outcome is the integrity of the socket walls, especially the buccal wall.⁴

The buccal wall is the part of the socket most susceptible to resorption.^{5,7} An integral buccal wall allows proper condensation of a bone graft inside the socket. It also permits the placement of a connective tissue graft (CTG) to prevent horizontal volume decrease.¹

Partial or total resorption of the buccal wall happens relatively frequently. It has been shown that such cases can be treated predictably by placing the implant with simultaneous guided bone regeneration (GBR) in a delayed protocol 6 to 8 weeks after tooth extraction.⁸ However, this approach (also known as early implant placement) presents some disadvantages such as partial mild recession of the papillae,⁹ increased morbidity, the need to wear a removable or adhesive temporary prosthesis, and a

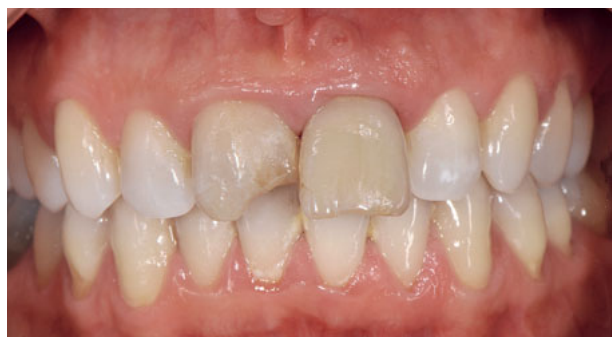
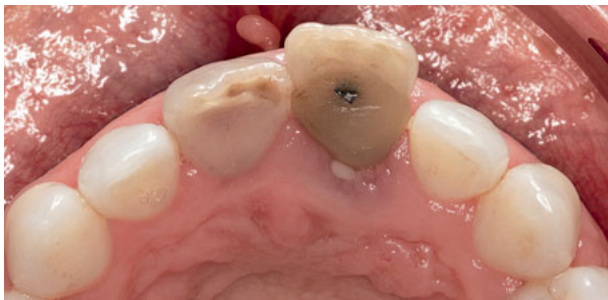
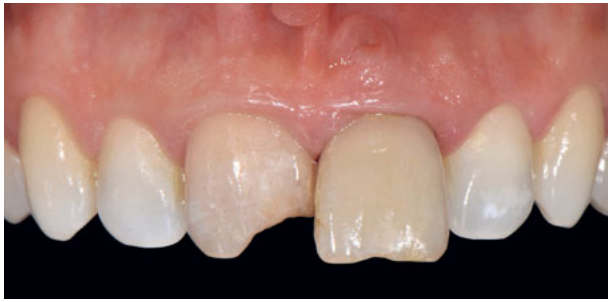Fig 1 Frontal view of the anterior zone during the first visit. Both central incisors are non-vital. Tooth 21 has a buccal fistula.

longer treatment period compared to immediate implant placement. Cosyn and De Rouck,¹⁰ in a study evaluating single-tooth implant restorations following early implant placement, found significant papilla loss compared to the contralateral natural tooth, especially at the distal aspect of the implants. Nevertheless, some advantages noted for early implant placement include easier three-dimensional (3D) implant positioning, low risk for mucosal recession, and a convex contour of the alveolar process.¹¹ Studies suggest that a flapless approach in cases with an integral buccal bone wall could result in reduced alteration of the soft tissue contour because the technique minimizes surgical trauma.¹²⁻¹⁴

In order to reduce the recession of the periimplant soft tissue, Araújo et al,¹⁵ in a study on beagle dogs, showed a minimization of bone resorption and mucosal margin recession in immediate implants when the alveolar gap between the implant and the buccal wall was filled with a biomaterial. As already mentioned, this approach can be easily performed if the buccal bone wall is integral.

Studies show that with proper 3D implant positioning and bone grafting into the implant socket, the facial soft tissue level can be maintained after the CTG has been performed with immediate single-tooth replacement.¹⁶⁻¹⁸ The placement of an immediate implant with a high degree of predictability in cases of partial or total loss of the buccal wall would be a desirable goal. However, the absence of the buccal wall hinders bone regeneration, and therefore a barrier membrane should be placed. The surgical approach for such cases should



Figs 2 and 3 Frontal and occlusal views of the maxillary anterior zone. The maxillary left central incisor shows suppuration and is pathologically proclined.

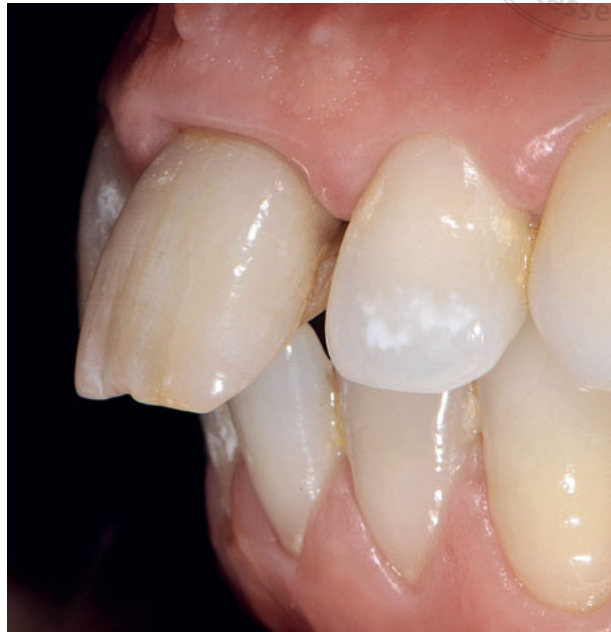

Fig 4 Left lateral view of the incisors. Tooth 21 presents a partial papilla recession at the distal level. Note the proclination of tooth 31.

fulfill the principles of GBR,¹⁹⁻²¹ even though a flap is not raised.

The objective of this article is to present a flapless surgical approach based on GBR principles using a bone xenograft and resorbable membranes to reconstruct the buccal bone wall on immediate implants in the anterior zone in cases of total loss of the buccal bone wall. Furthermore, in order to keep or increase the soft tissue buccal volume, a CTG is also placed over the membrane.

Materials and methods

The patient was a 32-year-old female ex-smoker with a history of dental trauma when she was 16 years old. She

presented a proclined hopeless maxillary left central incisor with a fistula at the buccal level and mild recession of the papillae, especially the distal one. The maxillary right central incisor showed obliteration of the pulp, a periapical lesion, a dark color, and a fracture on the mesial crown angle. The mandibular incisors showed crowding and some proclination, especially tooth 31 (Figs 1 to 4). A radiographic examination disclosed vertical bone defects at the mesial and distal levels of the maxillary left central incisor (Fig 5). Cone beam computed tomography (CBCT) showed the total loss of the buccal bone wall and a periapical lesion at tooth 21 (Fig 6) as well as pulp obliteration and a periapical lesion at tooth 11 (Fig 7).

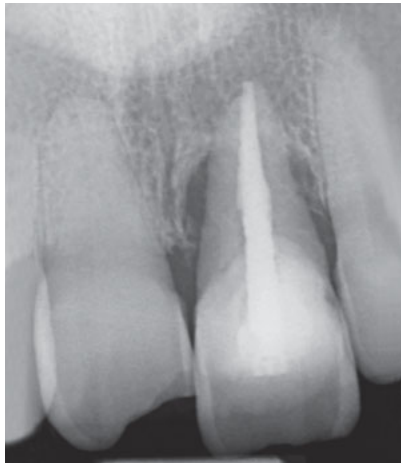

Fig 5 Radiograph showing mesial and distal vertical periodontal defects at tooth 21.

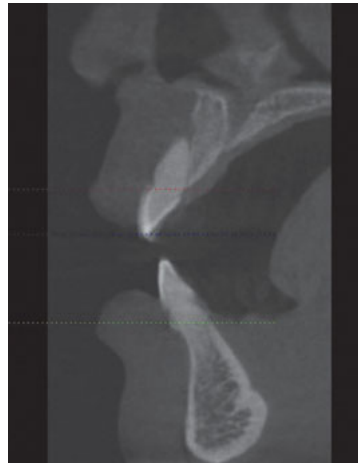


Fig 6 CBCT showing an absence of the buccal bone wall and a periapical lesion at tooth 21.

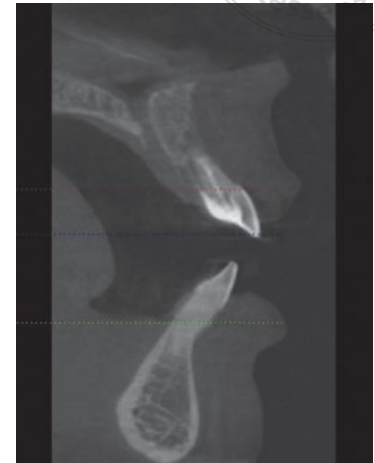


Fig 7 CBCT showing a periapical lesion at tooth 11.

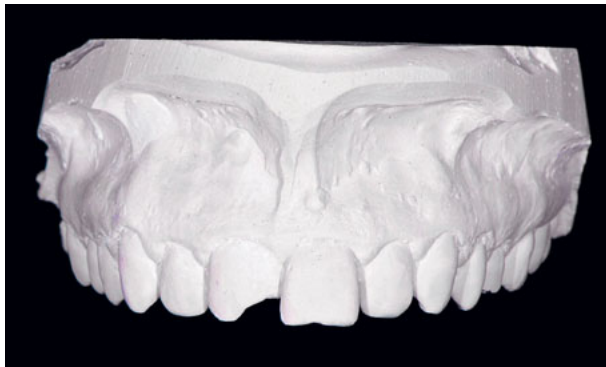


Fig 8 Plaster study cast of the maxilla.

Surgical planning and procedure

Since the hopeless maxillary left central incisor was proclined, a plaster cast was obtained to make an orthodontic setup (Fig 8). Tooth 21 was extracted from the cast and placed back in its correct position (Fig 9). Then, a positioning index was built using Triad VLC (Dentsply) as well as a conventional vacuum surgical guide to place the implant in the proper 3D position (Fig 10).

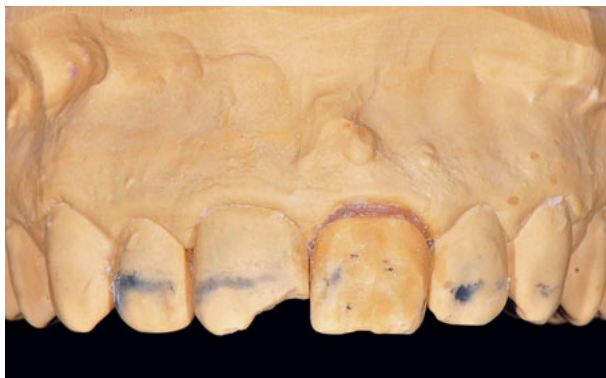

Fig 9 Orthodontic setup to place tooth 21 in the proper aligned position.

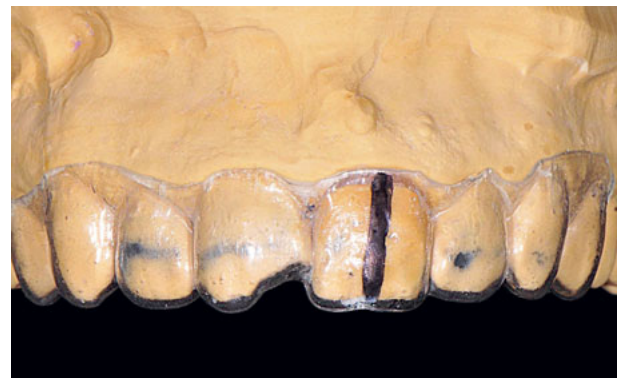

Fig 10 Conventional surgical guide to place the implant in the new correct position.

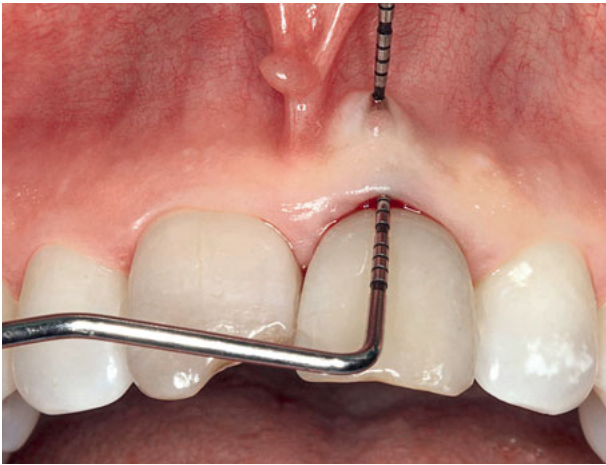

Fig 11 Probing of the fistula.

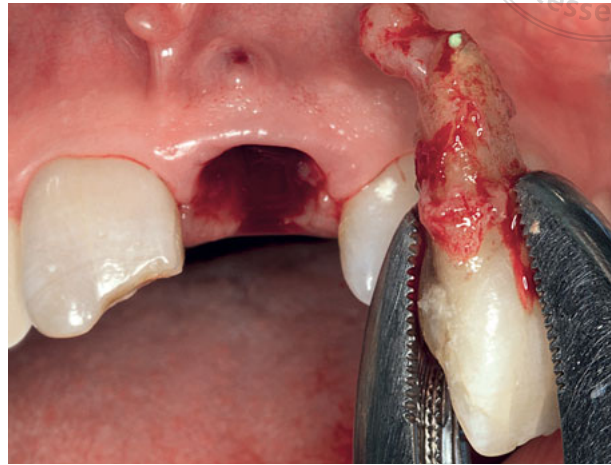

Fig 12 Extraction of the maxillary left central incisor. Note the fissures on the root and the periapical granuloma.

The patient was prescribed antibiotics (875 mg amoxicillin plus 125 mg clavulanic acid) every 8 h, 3 days before the surgery. After the local anesthesia, the fistula was probed, disclosing the absence of the buccal bone wall (Fig 11). Then, an atraumatic extraction was performed. The extracted tooth showed a vertical longitudinal fracture and an apical granuloma (Fig 12). After the extraction, the root was cut 2.5 mm apical to the cemento-enamel junction (CEJ), and both the remaining root and crown were hollowed out, leaving a 0.8- to 1-mm shell to be used as a temporary crown (Fig 13). After tooth extraction and careful debridement of the granulation tissue (Fig 14), the socket walls were probed to assess the bone loss and confirm the anatomic form of the defect. After copious irrigation of the socket with saline serum, a full-thickness recipient bed envelope was made using a non-cutting microsurgical instrument, without raising a flap. The envelope was extended at least 7 mm

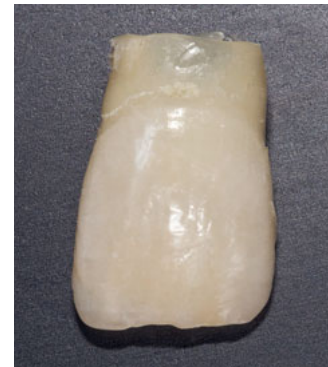

Fig 13 After extraction, the root is cut 2.5 mm from the CEJ and the crown is hollowed out, to be used as a temporary crown.

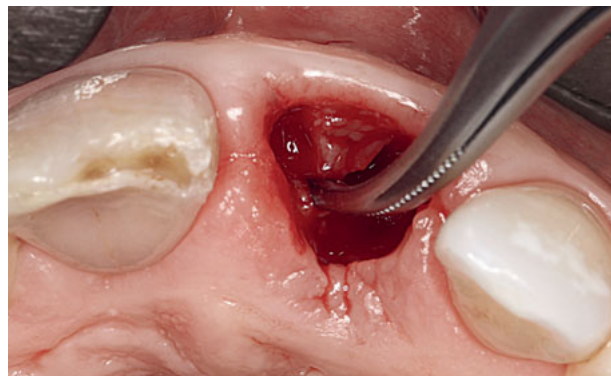
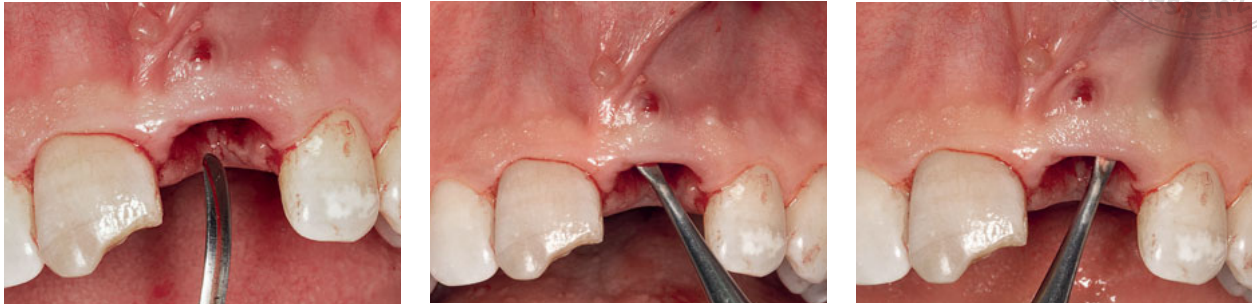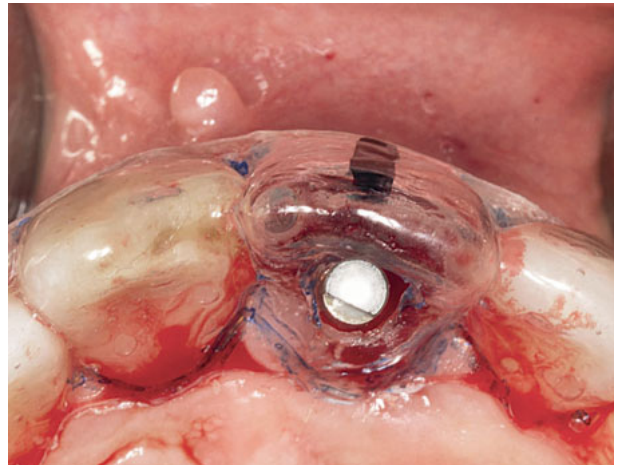
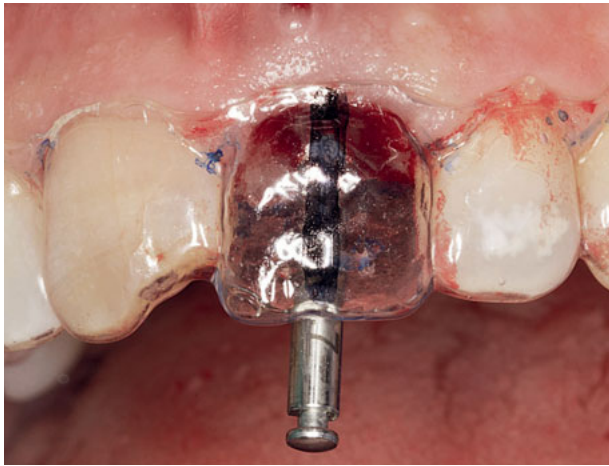


Fig 14 Elimination of the granulation tissue inside the socket.



Figs 15 to 17 A flapless, full-thickness recipient bed envelope is prepared 7 mm around the buccal dehiscence at zone 21.



Figs 18 and 19 Preparation of the socket using the surgical guide, with tooth 21 in the optimal position.

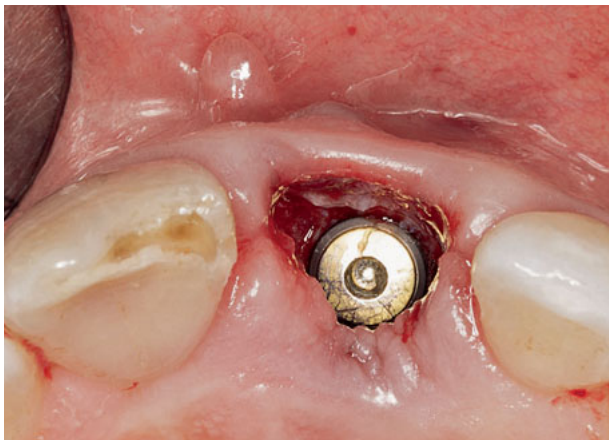

Fig 20 A 4.2-mm diameter x 15-mm length Astra Tech Evolution (Dentsply) implant is placed in the maxillary left central incisor area.



Fig 21 The natural crown is attached by composite to a temporary abutment that is screwed onto the implant. The emergence profile is constructed in the clinic.



copyright
all rights reserved
Quintessenz

around the perimeter of the buccal dehiscence and beyond the mucogingival line to ensure that no tension was present (Figs 15 to 17). Removal of the sulcus epithelium was carried out using a diamond bur. Then, using the conventional surgical guide (Figs 18 and 19), a 4-mm diameter x 15-mm length implant (Astra Tech Evolution, Dentsply) was placed in the proper 3D position (Fig 20), achieving primary stability (35 Ncm).

Construction of the temporary crown

A temporary abutment (Temp Abutment EV, Astra Tech, Dentsply) was reduced at shoulder and axial wall level and screwed into the implant. The hollow natural crown was etched and attached to the abutment in the correct position with a fluid composite (G-aenial Flo, GC Europe) using the positioning index built on the orthodontic setup (Fig 21).

Regenerative procedure

While the subgingival restoration profile was performed by the prosthodontist using Gradia (GC Europe), the regenerative procedure was carried out as follows:

Thin layers of xenograft (bovine hydroxylapatite with collagen; Bio-Oss, Geistlich) were introduced into the envelope and deposited over the implant. After the entire buccal surface of the implant was covered by the bone graft, it was condensed horizontally over the implant until it formed a grafted bone layer 3-mm thick at the buccal level (Fig 22). Since the recipient bed was tension-free,

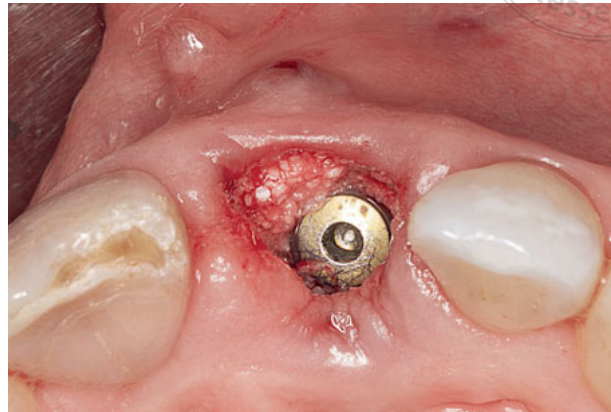
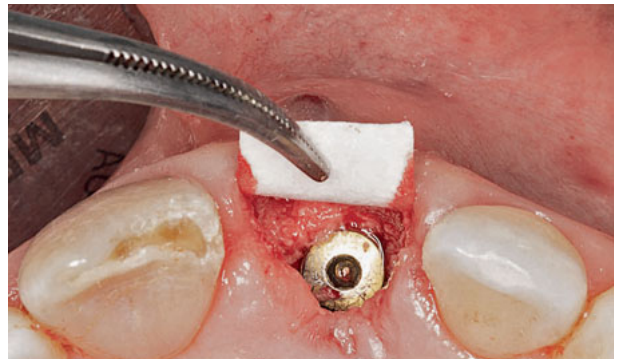
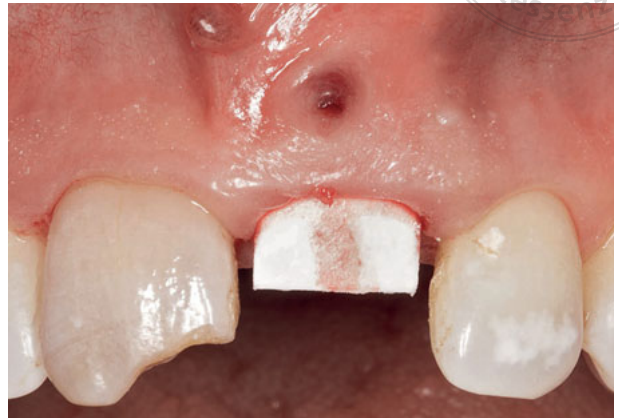
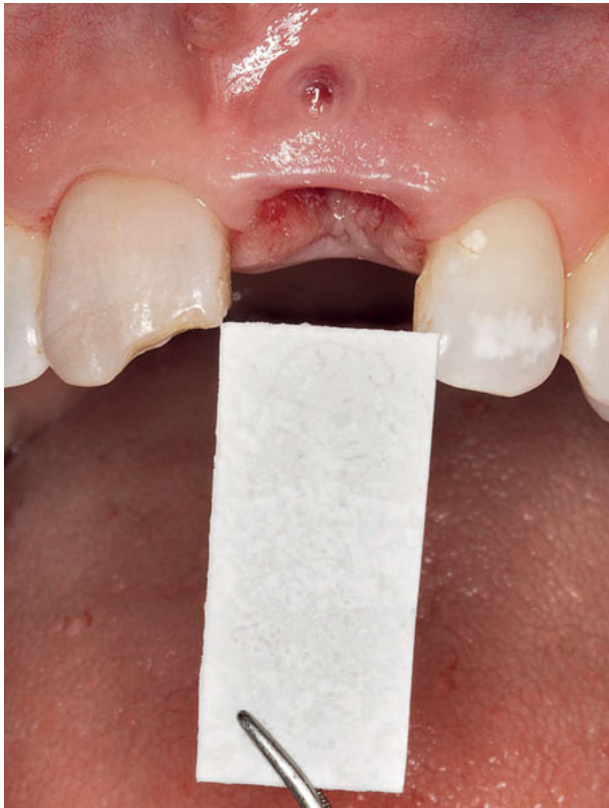Fig 22 Thin layers of hydroxylapatite with collagen are deposited over the implant and condensed vertically and horizontally to reconstruct the absent buccal bone wall.

a rigid, tailored collagen membrane (BioMend Extend, Zimmer Dental) could be prepared and introduced into the envelope (Fig 23) in such a way that the bone graft was fully covered. A part of the membrane (at least 7-mm long) was left outside the socket (Fig 24). After testing the stability of the membrane inside the sulcus (Fig 25), a fibrous CTG from the palate (Fig 26) was introduced between the tension-free buccal mucosa and the membrane using 6-0 mattress sutures, making sure the entire graft was subgingival (Fig 27). The remaining outside part of the membrane was cut with scissors (Fig 28), and the temporary crown placed in such a way that the grafted bone, the membrane, and the CTG were subgingival (Fig 29). The socket was then sealed with the screw-retained crown (Fig 30). To prevent excessive occlusal contact due to the proclination of the mandibular incisors, two posterior bite turbos were placed at zones 14 and 24 (Fig 31). Care was taken to ensure that the submucosal part of the restoration was concave so



Figs 23 to 25 A rigid collagen membrane is slipped inside the sulcus between the bone graft and the buccal soft tissues to completely cover the xenograft and fulfill the principles of GBR.

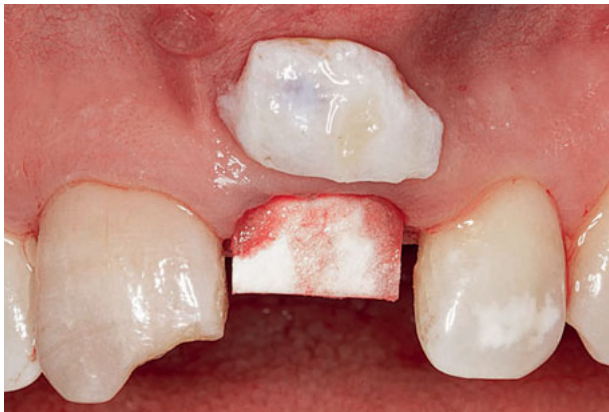

Fig 26 A fibrous CTG is harvested from the maxillary tuberosity area. Note that part of the membrane is left outside the socket to provide visual control of the membrane position during the placement and fixation of the graft.

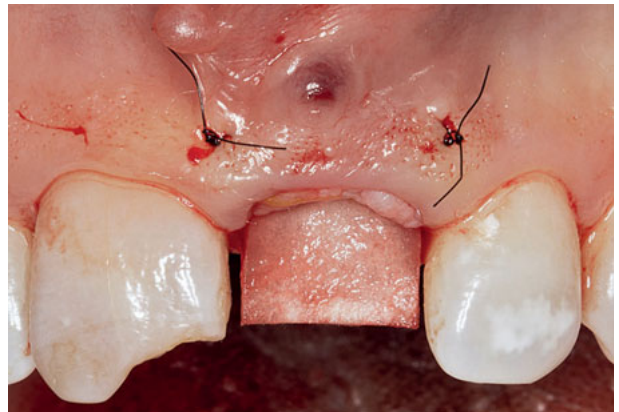


Fig 27 The CTG is introduced and fixated inside the socket using 6-0 mattress sutures. A part of the membrane is left outside the socket to control the position of the graft and avoid displacement of the membrane during graft suturing.

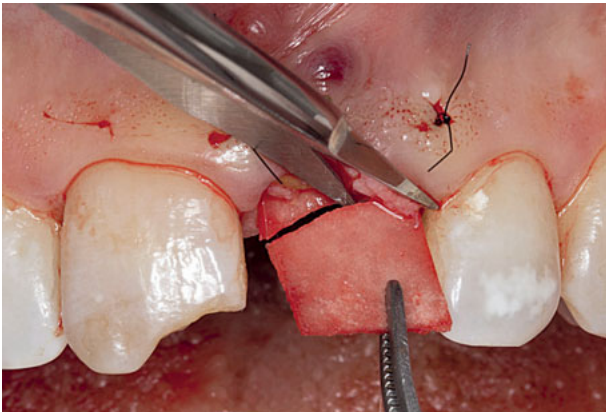

Fig 28 After testing the stability of the membrane and the bone graft during CTG placement, the remaining outside part of the membrane is cut.

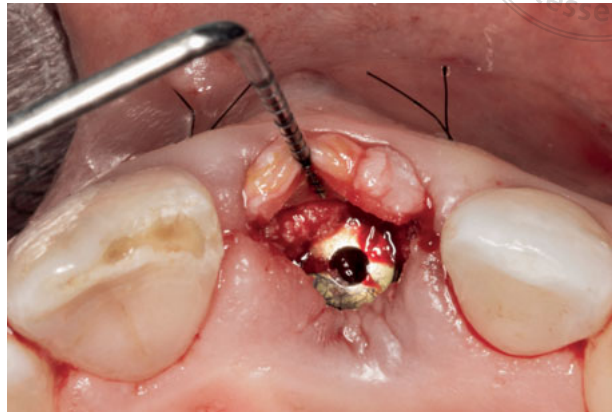


Fig 29 Occlusal view showing the three layers that reconstruct the absent buccal wall (xenograft, collagen membrane, and a CTG).

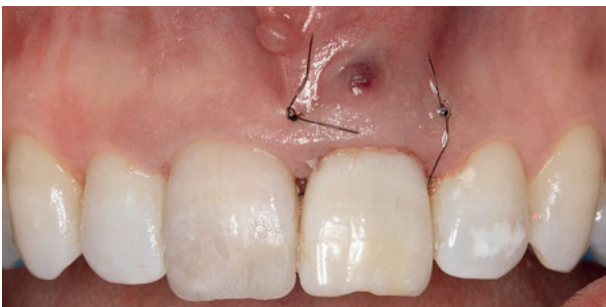


Fig 30 A temporary, natural, screw-retained crown is delivered to seal the grafted socket.

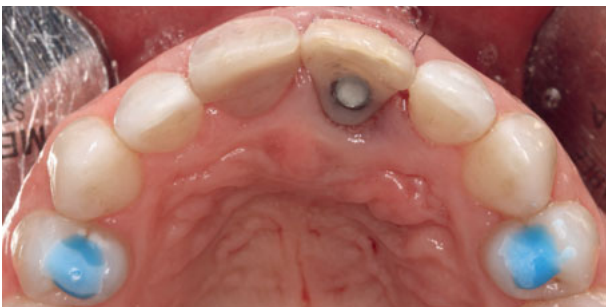

Fig 31 Occlusal view of the screw-retained crown showing optimal implant position. Occlusal lifts are placed on the premolars to avoid contact of the correctly positioned temporary crown with the proclined mandibular left central incisor.

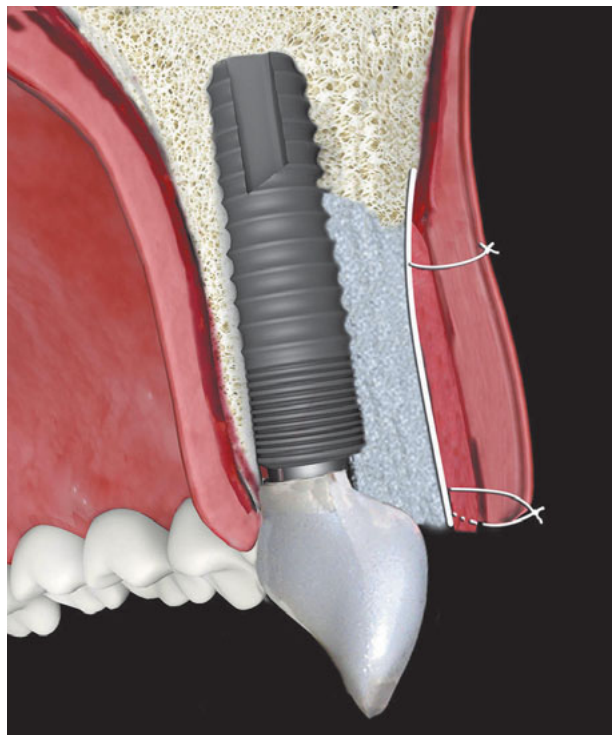
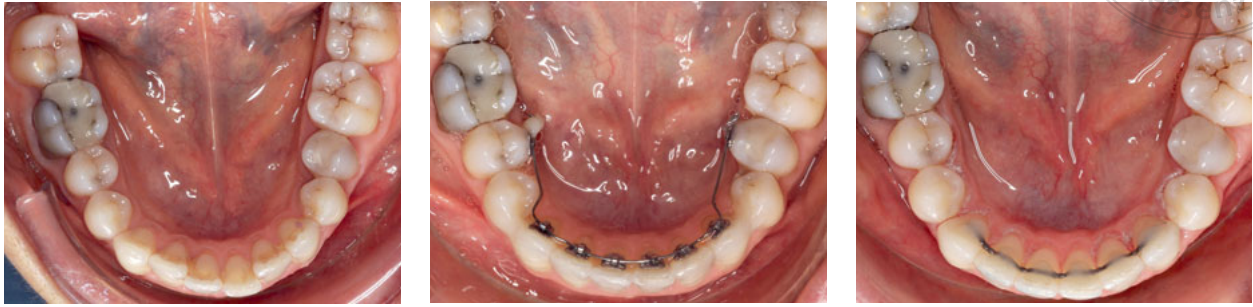


Fig 32 Illustration to represent the reconstruction of the buccal bone wall using xenograft, collagen membrane, and a CTG.



Figs 33 to 35 During the healing period, a partial lingual orthodontic treatment is performed to correctly align the mandibular incisors.

as to avoid pressure on the soft tissue, as can be seen on the transversal image of the immediate implant with the reconstruction of the buccal bone wall using xenograft, collagen membrane, and the CTG (Fig 32).

Postsurgical medication included antibiotics (875 mg amoxicillin plus 125 mg clavulanic acid) and anti-inflammatory (600 mg ibuprofen) three times a day for 7 days. Chlorhexidine rinse was also prescribed three times a day for 3 weeks.

The healing was uneventful. Peri-implant prophylaxis was enforced every month at incisor level. Three months after implant placement, endodontic treatment was performed on the maxillary right central incisor. Again, the healing

was uneventful. At the same time, a partial lingual orthodontic treatment was carried out on the mandibular incisors to align those teeth correctly and to provide the necessary occlusal space for the implant-supported crown (Figs 33 to 35). Orthodontic treatment time was 6 months.

Periodic sessions of internal whitening were carried out on tooth 11 using sodium perborate. Once the desired color was achieved, the pulp chamber was sealed using an opaque, high-value composite (IPS Empress Direct, Ivoclar Vivadent). Twelve months after delivery, the implant-supported temporary restoration presented healthy radiographic and clinical status (Fig 36).

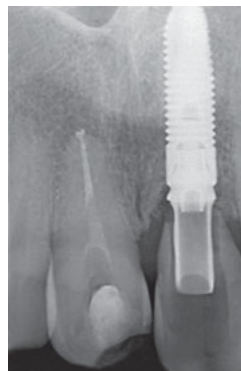
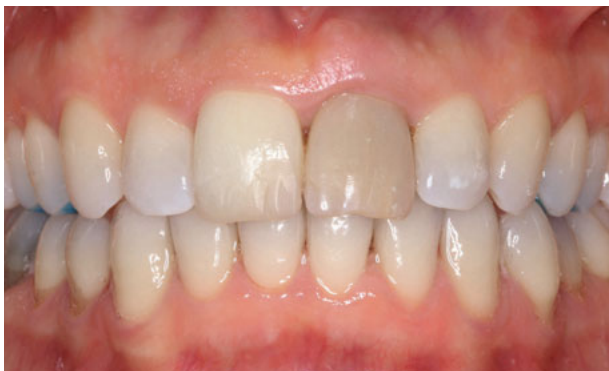
Fig 36 During the healing period, endodontic treatment of tooth 11 is performed. Clinical and radiological views of the central incisors 1 year after implant placement.



copyright
all rights reserved
Quintessenz

Figs 37 and 38 A final impression of the implant is taken using a coping that reproduces the emergence profile.

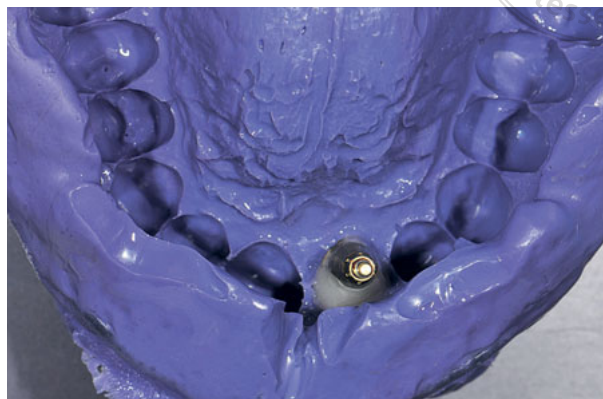
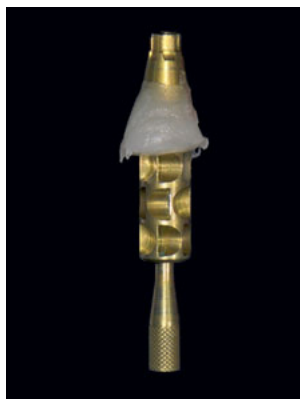
Fig 39 A lithium disilicate ceramic abutment is built over the new interphase of titanium at a 2-mm gingival height.

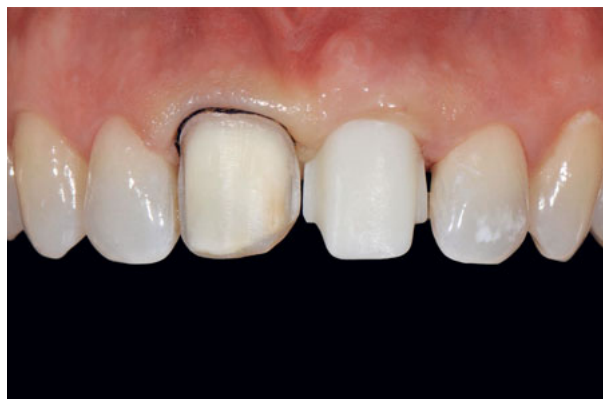

Fig 40 Preparation of tooth 11 for a ceramic veneer, and try out of the lithium disilicate ceramic abutment on tooth 21.

Final restoration

Using a customized coping reproducing the subgingival profile of the temporary crown (Fig 37), the final impression was taken at implant level (Fig 38). A lithium disilicate ceramic abutment (IPS e.max Press MO, Ivoclar Vivadent) was built over the new interphase of titanium (TitaniumBase EV, Astra Tech, Dentsply) at a 2-mm gingival height (Fig 39). The palatal aspect of the abutment had the anatomic form of a central incisor, and also contained the chimney for the prosthetic screw. On the other hand, the buccal aspect of the abutment had

the shape of a preparation to receive the ceramic veneer. In the laboratory, a silicone template was built to guide the preparation of a ceramic veneer on the maxillary right central incisor, based on a previous wax-up. An index of Pattern Resin LS (GC Europe) was made over the abutment for the pull impression (Fig 40). The color of the lateral incisors was registered using SpectroShade Micro (MHT Optic Research).

The abutment at tooth 21 was tried to check and adjust the pressure at subgingival level. At the same time, the veneer on tooth 11 was prepared using the silicone template to check the required

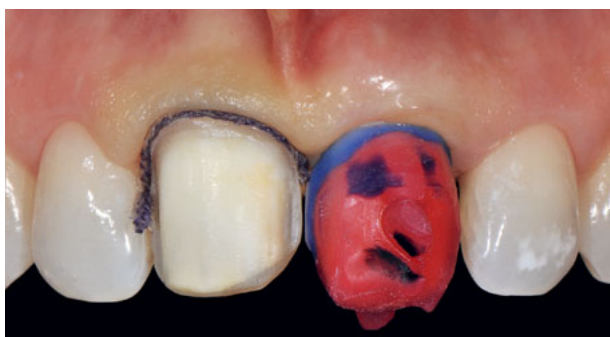


Fig 41 An index is made over the abutment for the pull impression.

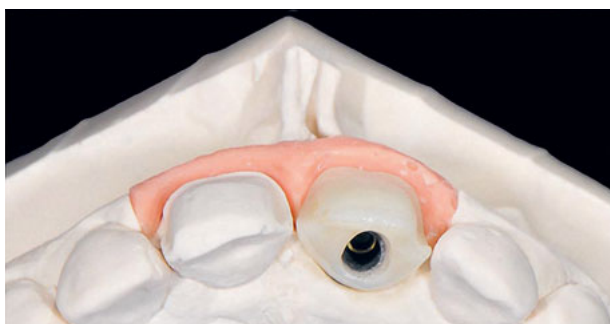
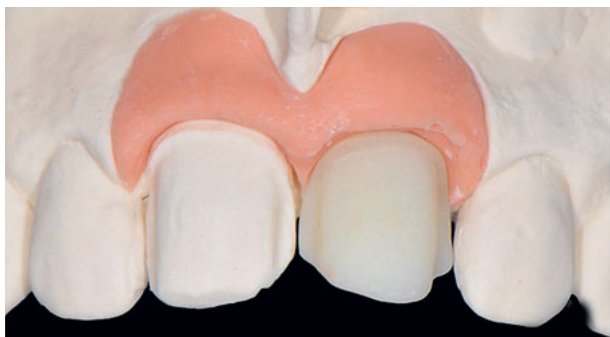
Fig 42 Frontal and occlusal views of the veneer preparation and the implant abutment.

space of 0.7 mm. A final impression was taken on tooth 11 as well as the pull impression of the ceramic abutment (Fig 41). The color of the veneer preparation and the ceramic abutment was registered one more time using Spectro-Shade Micro.

The abutment was finally cemented onto the titanium interphase in the laboratory using Multilink Hybrid Abutment (Ivoclar Vivadent) (Fig 42). Two feldspar ceramic Creation CC veneers (Willi Geller) were constructed as final restorations (Fig 43). After checking the form, color, and adjustment, the veneers were bonded using Variolink Esthetic (Ivoclar Vivadent). The final restorations were delivered 14 months after implant placement.

One year after final crown delivery (26 months after implant placement), the clinical periimplant status was healthy, and the restoration showed an adequate emergence profile (Figs 44 to 48). A periapical radiograph disclosed an optimal periimplant bone level (Fig 49). CBCT revealed a radiopaque image ≥ 2 mm at the buccal aspect of the implant (Fig 50).

Discussion

For reasons of esthetics and comfort, the substitution of a hopeless maxillary anterior tooth for an immediate implant was considered the best therapy in this case.

Wöhrle²³ reported bone and soft tissue stability in a case series at 6 to 36 months. Kan et al¹ state that the integrity of the buccal wall is a necessary requirement for performing an immediate implant. However, due to the documented thinness of the buccal bone wall on anterior teeth, its absence is a frequent finding in cases of hopeless teeth with fractures or fissures.

The lack of a buccal bone wall hinders proper bone-implant gap filling and condensation in a conventional flapless

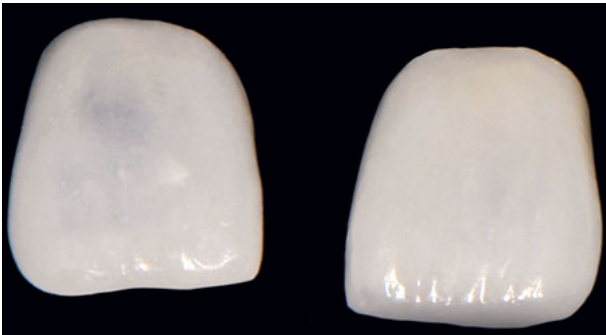

Fig 43 Feldspar ceramic veneers as final restorations.

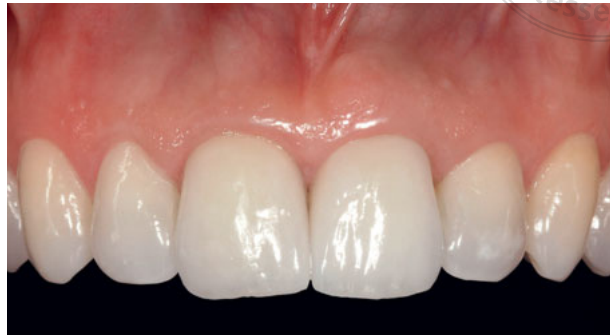
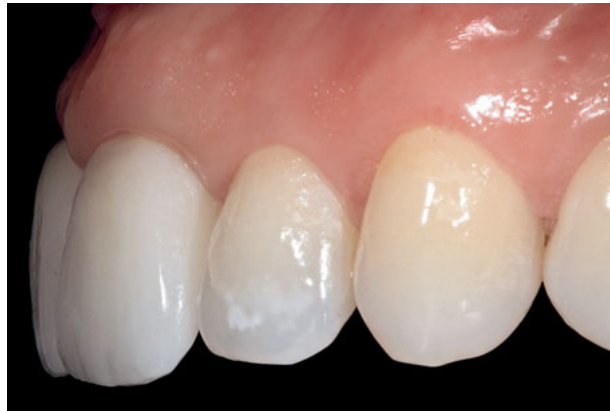
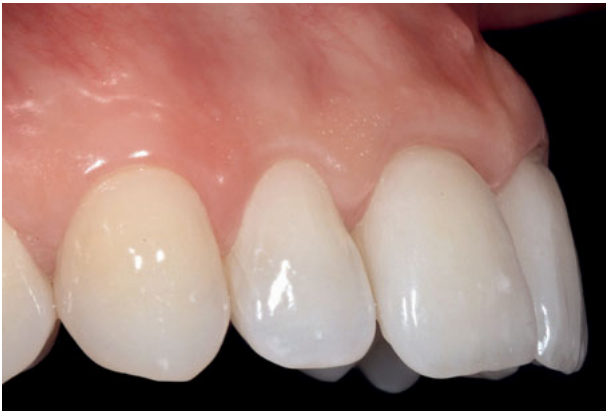Fig 44 Frontal view of the final restorations 1 year after delivery.



Figs 45 and 46 Right and left lateral views of the final restorations 1 year after delivery.

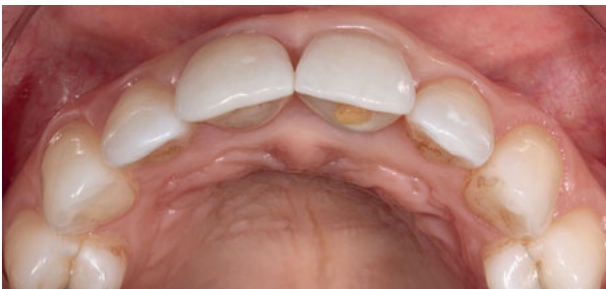

Fig 47 Occlusal view of the final restorations 1 year after delivery. Note the proper soft tissue contour on the implant-supported restoration, and the chimney for screw access at the palatal level.

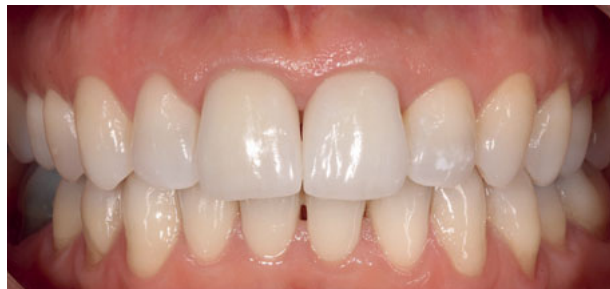

Fig 48 Final restorations 1 year after delivery: frontal view in maximum intercuspation.

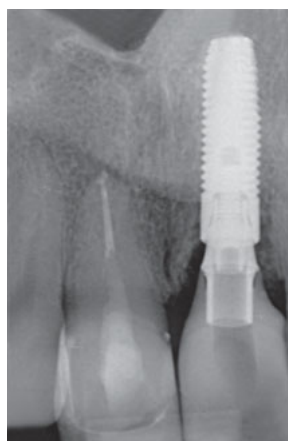


Fig 49 Radiograph of the final restorations 1 year after delivery.

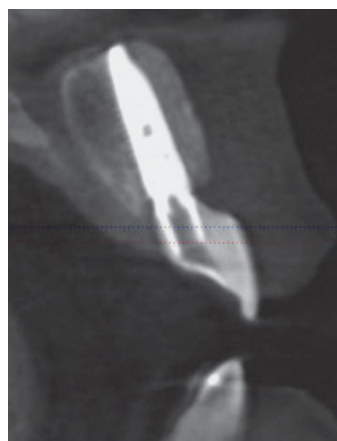

Fig 50 CBCT of the implant at the maxillary left central incisor 1 year after delivery. Note the radiopaque buccal image.

approach. This article describes a technique that aims to perform buccal bone wall reconstruction in an atraumatic way using a xenograft as filling material, a collagen membrane, and the addition of a fibrous CTG to retain the soft tissue volume and provide an esthetic emergence profile.

The workflow sequence was as follows: After immediate implant placement, the bone graft was placed and condensation carried out both vertically and horizontally. The membrane was then placed, leaving a remaining part of it outside the socket. Finally, a CTG was placed over the membrane. To the knowledge of the authors, this particular approach has not been described before.

A key factor of this approach is the over-extension of the envelope (at least 7 mm around the perimeter of the buccal dehiscence, and far beyond the mucogingival line) to eliminate tension. This large bed allows for the introduction of layers of hydroxylapatite with collagen, and their compaction over the buccal surface of the implant from a perpendicular (horizontal) angle. Afterwards,

the graft is covered with a rigid collagen membrane so that it can easily be slid into the tension-free envelope.

In our opinion, if the membrane is placed prior to the bone graft to act as a dam, bone condensation can be performed only vertically and might displace the membrane, preventing total bone graft coverage and resulting in a soft tissue encapsulation of the graft.

Another key factor of this approach is the extra-large size of the membrane, since a part of it must be left outside the socket to control its proper position during the placement of the CTG. If this part of the membrane is not left outside, membrane displacement could occur.

Elian et al²⁴ described a classification for alveolar sockets based on the status of the buccal bone wall and the mucosa. In that article, the authors describe cases similar to the present one (type II) where, to repair the socket, they placed a membrane inside it as a dam, and performed bone filling afterwards. No implant or CTG was placed, and the socket was sealed with the membrane. In all the cases treated with that approach,



the procedures were successful and implants could then be placed. However, in the case described in the present article, an implant was placed and a membrane was positioned over the perimeter of the buccal dehiscence after preparing a full-thickness recipient envelope. As the buccal wall was completely absent, even at periapical level, the approach described by Elian et al²⁴ could not have been applied because of the impossibility of fixing the membrane inside the socket.

Da Rosa et al²⁵ proposed a technique to treat cases without a buccal bone wall. This approach, which achieved excellent results, consisted of using cortical tuberosity and cancellous bone, with the CTG attached to the cortical tuberosity. In our opinion, this technique is highly sensitive and depends on the experience of the surgeon and the size of the tuberosity.

A predictable alternative to immediate implant placement in a case like the present one could have been an early implant placement.^{8,9} This protocol was not chosen because even before the extraction the patient presented a mild papilla recession, especially at the distal aspect, which might have increased during flap management.¹⁰ Another reason for not opting for early implant placement was the need for the patient to wear a removable or adhesive temporary prosthesis, which increased morbidity and made for a longer treatment period.

The choice of the final restoration was based on the principle of minimally invasive restorations in endodontic teeth.²⁶⁻²⁸ For this reason, it was decided to place a porcelain veneer on

the maxillary right central incisor. Three important decisions had to be made regarding the restoration on the maxillary left central incisor. Firstly, we had to choose whether to place a screw-retained or a cemented restoration. Although there is support for both options,²⁹⁻³¹ due to the risk of cement invasion of the periimplant sulcus, we decided from the outset that the access hole of the restoration should be in the palatal position. Secondly, we had to decide on the type of material to use. From an esthetic point of view, the various ceramic materials (such as feldspar porcelain, more natural ceramics, and others with a higher percentage of synthetic ceramic) behave differently in terms of light transmission and fluorescence. We decided on a ceramic abutment that had similar esthetics to the natural adjacent teeth, and to place a veneer that was similar to the natural tooth porcelain at tooth 11 (as described by Magne et al²⁸). The third decision was the choice of abutment. There were three factors to consider: the material of the inner connection to the implant, the ceramic material used to build the abutment, and whether or not to stratify the abutment with porcelain. There is now broad consensus that the connection should be made of metal, using an interface to prevent fractures to the titanium zirconium-level connection.³²⁻³⁴ Regarding the ceramic material to build the abutment,³⁵⁻⁴⁰ we considered veneering zirconium, monolithic zirconium, or lithium disilicate. Monolithic zirconium was ruled out due to the difficulty of adhesion to the porcelain veneer,³⁵⁻³⁸ and although higher bond strength is achieved nowadays using new adhesives, no long-term



guarantee is provided. In the end, we chose pressed lithium disilicate because it was easier to make, technically speaking; also, veneering is easier in order to obtain a more realistic abutment and a long-term, reliable adhesion.^{40,41}

Conclusion

Within the limitations of a case report, this article describes the treatment of a hopeless tooth lacking the buccal bone wall. The therapy consisted of a flapless approach for an immediate implant

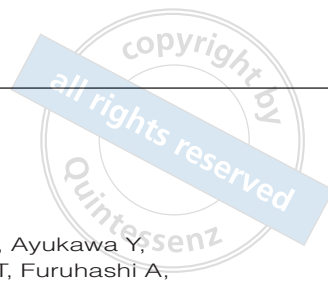
placement with simultaneous GBR using xenograft and a resorbable membrane, and adding a CTG. In this single case, 1 year after the final crown delivery (2 years after implant placement), the periapical radiography showed stability of the interproximal bone. CBCT disclosed a radiopaque image ≥ 2 mm at the buccal aspect of the implant. The periimplant mucosa showed a healthy status, without signs of inflammation and with no bleeding on probing. Long-term prospective studies should be carried out to assess the predictability of this approach.

References

1. Kan JY, Rungcharassaeng K, Morimoto T, Lozada J. Facial gingival tissue stability after connective tissue graft with single immediate tooth replacement in the esthetic zone: consecutive case report. *J Oral Maxillofac Surg* 2009;67(11 suppl):40–48.
2. Cornellini R, Barone A, Covani U. Connective tissue grafts in postextraction implants with immediate restoration: a prospective controlled clinical study. *Pract Proced Aesthet Dent* 2008;20:337–343.
3. Cornellini R, Cangini F, Covani U, Wilson TG Jr. Immediate restoration of implants placed into fresh extraction sockets for single-tooth replacement: a prospective clinical study. *Int J Periodontics Restorative Dent* 2005;25:439–447.
4. Roe P, Kan JY, Rungcharassaeng K, Caruso JM, Zimmerman G, Mesquida J. Horizontal and vertical dimensional changes of peri-implant facial bone following immediate placement and provisionalization of maxillary anterior single implants: a 1-year cone beam computed tomography study. *Int J Oral Maxillofac Implants* 2012;27:393–400.
5. Pietrovovski J, Massler M. Alveolar ridge resorption following tooth extraction. *J Prosthet Dent* 1967;17:21–27.
6. Schropp L, Wenzel A, Kostopoulos L, Karring T. Bone healing and soft tissue contour changes following single-tooth extraction: a clinical and radiographic 12-month prospective study. *Int J Periodontics Restorative Dent* 2003;23:313–323.
7. Araújo MG, Lindhe J. Dimensional ridge alterations following tooth extraction. An experimental study in the dog. *J Clin Periodontol* 2005;32:212–218.
8. Buser D, Halbritter S, Hart C, et al. Early placement with simultaneous guided bone regeneration following single-tooth extraction in the esthetic zone: 12-month results of a prospective study with 20 consecutive patients. *J Periodontol* 2009;80:152–162.
9. Belser UC, Grütter L, Vailati F, Bornstein MM, Weber HP, Buser D. Outcome evaluation of early placed anterior maxillary single-tooth implants using objective esthetic criteria: a cross-sectional, retrospective study in 45 patients with a 2- to 4-year follow-up using pink and whites esthetic scores. *J Periodontol* 2009;80:140–151.
10. Cosyn J, De Rouck T. Aesthetic outcome of single-tooth implant restorations following early implant placement and guided bone regeneration: crown and soft tissue dimensions compared with contralateral teeth. *Clin Oral Implants Res* 2009;20:1063–1069.
11. Wilson T, Buser D. Timing of anterior implant placement postextraction: immediate versus early placement. *Clinical Advances in Periodontics* 2011;1:61–67.



12. Cardaropoli D, Gaveglio L, Gherlone E, Cardaropoli G. Soft tissue contour changes at immediate implants: a randomized controlled clinical study. *Int J Periodontics Restorative Dent* 2014;34:631–637.
13. Blanco J, Liñares A, Pérez J, Muñoz F. Ridge alterations following flapless immediate implant placement with or without immediate loading. Part II: a histometric study in the Beagle dog. *J Clin Periodontol* 2011;38:762–770.
14. Blanco J, Carral C, Liñares A, Pérez J, Muñoz F. Soft tissue dimensions in flapless immediate implants with and without immediate loading: an experimental study in the beagle dog. *Clin Oral Implants Res* 2012;23:70–75.
15. Araújo MG, Linder E, Lindhe J. Bio-Oss collagen in the buccal gap at immediate implants: a 6-month study in the dog. *Clin Oral Implants Res* 2011;22:1–8.
16. Yoshino S, Kan JY, Rungcharassaeng K, Roe P, Lozada JL. Effects of connective tissue grafting on the facial gingival level following single immediate implant placement and provisionalization in the esthetic zone: a 1-year randomized controlled prospective study. *Int J Oral Maxillofac Implants* 2014;29:432–440.
17. Rungcharassaeng K, Kan JY, Yoshino S, Morimoto T, Zimmerman G. Immediate implant placement and provisionalization with and without a connective tissue graft: an analysis of facial gingival tissue thickness. *Int J Periodontics Restorative Dent* 2012;32:657–663.
18. Tsuda H, Rungcharassaeng K, Kan JY, Roe P, Lozada JL, Zimmerman G. Peri-implant tissue response following connective tissue and bone grafting in conjunction with immediate single-tooth replacement in the esthetic zone: a case series. *Int J Oral Maxillofac Implants* 2011;26:427–436.
19. Dahlin C, Sennerby L, Lekholm U, Linde A, Nyman S. Generation of new bone around titanium implants using a membrane technique: an experimental study in rabbits. *Int J Oral Maxillofac Implants* 1989;4:19–25.
20. Dahlin C, Gottlow J, Linde A, Nyman S. Healing of maxillary and mandibular bone defects using a membrane technique. An experimental study in monkeys. *Scand J Plast Reconstr Surg Hand Surg* 1990;24:13–19.
21. Hämmerle C, Karring T. Guided bone regeneration at oral implants sites. *Periodontol* 2000 1998;17:151–175.
22. Grunder U, Gracis S, Capelli M. Influence of the 3D bone-to-implant relationship on esthetics. *Int J Periodontics Restorative Dent* 2005;25:113–119.
23. Wöhrle PS. Single tooth replacement in the aesthetic zone with immediate provisionalization: fourteen consecutive case reports. *Pract Periodontics Aesthet Dent* 1998;10:1107–1114.
24. Elian N, Cho SC, From S, Smith RB, Tarnow DP. A simplified socket classification and repair technique. *Pract Proced Aesthet Dent* 2007;19:99–104.
25. da Rosa JC, Rosa AC, Fadanelli MA, Sotto-Maior BS. Immediate implant placement, reconstruction of compromised sockets, and repair of gingival recession with a triple graft from the maxillary tuberosity: a variation of the immediate dentoalveolar restoration technique. *J Prosthet Dent* 2014;112:717–722.
26. Meyenberg KH. Nonvital teeth and porcelain laminate veneers – a contradiction? *Eur J Esthet Dent* 2006;1:192–206.
27. Schlichting LH, Stanley K, Magne M, Magne P. The non-vital discolored central incisor dilemma. *Int J Esthet Dent* 2015;10:548–562.
28. Magne P, Magne M, Jovanovic SA. An esthetic solution for single-implant restorations – type III porcelain veneer bonded to a screw-retained custom abutment: a clinical report. *J Prosthet Dent* 2008;99:2–7.
29. Vigolo P, Givani A, Majzoub Z, Cordioli G. Cemented versus screw-retained implant-supported single-tooth crowns: a 4-year prospective clinical study. *Int J Oral Maxillofac Implants* 2004;19:260–265.
30. Sailer I, Mühlemann S, Zwahlen M, Hämmerle CH, Schneider D. Cemented and screw-retained implant reconstructions: a systematic review of the survival and complication rates. *Clin Oral Implants Res* 2012;23(suppl 6):163–201.
31. Fenner N, Hämmerle CH, Sailer I, Jung RE. Long-term clinical, technical, and esthetic outcomes of all-ceramic vs. titanium abutments on implant supporting single-tooth reconstructions after at least 5 years. *Clin Oral Implants Res* 2016;27:716–723.
32. Silva NR, Teixeira HS, Silveira LM, Bonfante EA, Coelho PG, Thompson VP. Reliability and Failure Modes of a Hybrid Ceramic Abutment Prototype. *J Prosthodont* 2018;27:83–87.
33. Hornbrook D. Case report using the “H” abutment: achieving esthetics, strength, and predictability for the anterior implant. *Compend Contin Educ Dent* 2015;36:192,194–198,200–211.
34. Kurbad A, Kurbad S. CAD/CAM-based implant abutments. *Int J Comput Dent* 2013;16:125–141.



35. Fenner N, Hämmerle CH, Sailer I, Jung RE. Long-term clinical, technical, and esthetic outcomes of all-ceramic vs. titanium abutments on implant supporting single-tooth reconstructions after at least 5 years. *Clin Oral Implants Res* 2016;27: 716–723.
36. Sailer I, Zembic A, Jung RE, Hämmerle CH, Mattiola A. Single-tooth implant reconstructions: esthetic factors influencing the decision between titanium and zirconia abutments in anterior regions. *Eur J Esthet Dent* 2007;2:296–310.
37. Linkevicius T, Apse P. Influence of abutment material on stability of peri-implant tissues: a systematic review. *Int J Oral Maxillofac Implants* 2008;23:449–456.
38. Welander M, Abrahamsson I, Berglundh T. The mucosal barrier at implant abutments of different materials. *Clin Oral Implants Res* 2008;19: 635–641.
39. Abrahamsson I, Berglundh T, Glantz PO, Lindhe J. The mucosal attachment at different abutments. An experimental study in dogs. *J Clin Periodontol* 1998;25: 721–727.
40. Yamane K, Ayukawa Y, Takeshita T, Furuhashi A, Yamashita Y, Koyano K. Bacterial adhesion affinities of various implant abutment materials. *Clin Oral Implants Res* 2013;24: 1310–1315.
41. Boudrias P, Shoghikian E, Morin E, Hutnik P. Esthetic option for the implant-supported single-tooth restoration – treatment sequence with a ceramic abutment. *J Can Dent Assoc* 2001;67: 508–514.