

## Periodontal-temporomandibular-aural connections

Connections between the periodontal ligament, the alveolar bone, and the ear ossicles do not immediately come to mind, but the physiology of bone, its turnover, dental emplacements, and hearing mechanisms provide such connections. The varying embryogenesis of these disparate elements interconnects their origins.

The issue of bone turnover and constant replacement constitutes the very essence of periodontology. The permanence of ossicular bone is in direct contrast to the fleeting permanence of periodontal bone.

The periodontal ligament is the *raison d'être* for the existence of the alveolar bone, for if there is no cementum of a tooth root to which the ligament fibers can attach, a former alveolar socket dissipates by osteoblast ingrowth and diminishment of the alveolar margin.

The rates of bone growth, disintegration, and replacement are factors dependent upon forces brought to bear upon bone tissue. Accordingly, these factors vary enormously in different locations in the body. The almost daily destruction of alveolar bone lining dental alveoli is determined by masticatory stresses occasioned by chewing or swallowing. This rapid turnover of bone tissue contrasts with the slow osteoblastic and osteoclastic ballet of intrinsic bone structure occurring in most of the skeleton.<sup>1</sup>

In sharp contrast to the above-detailed kinematic bone physiology is the permanent osteologic structure of ossicular bones that, once formed, remains essentially unchanged throughout life. The fetal formation of the cochlear structure within the temporal bone occurring during the 21st to 31st gestational weeks establishes the contained ear ossicles. The dimensions of the ear ossicles at the time of their formation are those of nearly their adult sizes, and they are the first bones to attain their fully mature status.<sup>2</sup>

The function of hearing attained in utero is in response to external vibrations delivered through the tympanic membrane to the cochlea. These extremely delicate and exquisitely miniscule movements occur at the first "hearing" of the fetus prior to birth. Sound perception occurs postnatally when the external acoustic meatus is cleared of a plug of mucus and debris soon after birth.

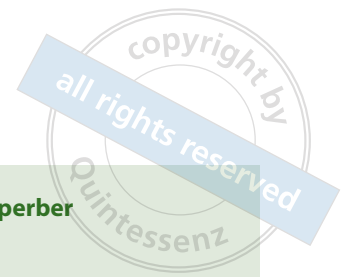The coincidental coupling of mastication and hearing has a long palaeontologic history. Integrated hearing and chewing modules decoupled in a Cretaceous stem therian mammal.<sup>3</sup> The separation of middle ear elements from the Meckel cartilage of the mandible allowed chewing and hearing to evolve independently.<sup>4</sup> A new genus of and species of stem therian mammal reveals a clear transitional stage between the two very different functions of the bones.<sup>5</sup>

Cochlear bone in the petrous pyramid preserves endogenous DNA by virtue of the near absence of bone remodeling following completion of ossification.<sup>6</sup> Thereby, human auditory ossicles provide an optimal source of ancient DNA, and can be an effective substrate for ancient DNA analysis.<sup>7</sup>

The relationship between the auditory ossicles and the temporomandibular joint is to be found in the newly described transient incudopetrosal joint between the short limb of incus and the otic capsule or petrous temporal bone.<sup>8</sup> There is evidence of an ontogenic transfer in humans of the incus to the middle ear.<sup>9</sup> Further, the discomalleolar ligament is a remnant of Meckel cartilage that connects the malleus ear ossicle to the retrodiscoidal tissue of the temporomandibular joint. Therein lies the clinical condition known as Costen syndrome, an affliction of symptoms involving hearing difficulties, facial pain, tinnitus, and dizziness.<sup>10,11</sup> Further, hypermobility of the temporomandibular joint results in "cracking" disorders driving sufferers to distraction.<sup>12</sup>


Arthritis, periodontitis, and temporomandibular joint disorders can be influenced by variation in the aquaporin (AQP) genes at the 12q13.12 locus.<sup>13</sup> Thereby, concomitant temporomandibular disorder and periodontitis inflammatory conditions can be attributed to an immune system dysfunction. ■

Geoffrey H. Sperber, BDS, MSc, PhD, Dr Med. Dent (HC)  
Faculty of Medicine & Dentistry, University of Alberta, Edmonton, Canada  
Email: gsperber@ualberta.ca



## References

1. Hernandez CJ, Majeska RJ, Schaffler MB. Osteocyte density in woven bone. *Bone* 2004;35:1095–1099.
2. Sperber GH, Sperber SM. *Craniofacial embryogenetics and development*, 3rd edn. PMPH USA 2018.
3. Mayo F, Hu Y, Li C, et al. Integrated hearing and chewing modules decoupled in a Cretaceous stem therian mammal. *Science* 2020;367:305–308.
4. Schultz JA. Eat and listen: how chewing and hearing evolved. *Science* 2020;367:244–245.
5. Vignieri S. Making a mammalian ear. *Science* 2020;367:260–261.
6. Hernandez CJ, Majeska RJ, Schaffler MB. Osteocyte density in woven bone. *Bone* 2004;35:1095–1099.
7. Sirak KA, Sedig JW. Balancing analytical goals and anthropological stewardship in the midst of the paleogenomic revolution. *World Archaeology* 2020;51:560–573.
8. Rodriguez-Vazquez JF, Yamamoto M, Kim JH, et al. The incudopetrosal joint of the human middle ear: a transient morphology in fetuses. *J Anat* 2020;237:176–187.
9. Rodriguez-Vazquez JF. The evidence in humans of ontogenic transfer of the incus to the middle ear. *Anales Ranm* 2020;136: 283–286.
10. Dean RM. TMD: Costen’s syndrome. *Br Dent J* 2016;220:280.
11. Costen JB. A syndrome of ear and sinus symptoms dependent upon disturbed function of the temporomandibular joint. *Ann Otol Rhinol Laryngol* 1934;43:1–15.
12. Ilgunas A, Wanman A, Stromback M. I was cracking more than everyone else: young adults’ daily life experience of hypermobility and jaw disorders. *Eur J Oral Sci* 2020;128:74–80.
13. Bezamat M, Cunha EJ, Modesto AM, Vieira AR, Taboas JM. Aquaporin locus (12q13.12) might contribute to susceptibility of temporomandibular joint disorder associated with periodontitis. *PLoS One* 2020;15:0229245.



Geoffrey H. Sperber