

Product information

Authors: Daniel Buser
Title: Surgical concepts to handle esthetic failures in implant patients

Short text:

The videos in this 5-DVD set present the surgical concepts used to treat the most common esthetic failures, such as malpositioned implants, facial bone defects, or a combination of both. Techniques shown include the reverse torque technique to remove osseointegrated implants without flap elevation, full-thickness mucosal grafts to reestablish missing keratinized mucosa, and bone augmentation using locally harvested autogenous bone chips combined with a xenogeneic low-substitution bone filler and covered by a resorbable collagen membrane. In addition, the videos depict patient retreatment with new implant therapy, with a focus on correct 3D implant positioning and local bone augmentation using GBR for successful, esthetic outcomes.

Contents

Volume 1. Implant removal technique in three patients

This volume shows how osseointegrated implants can be removed using the reverse torque technique in three patients. With this low-trauma technique—often done with a flapless procedure—osseointegration is fractured at the bone-implant interface using special instruments that are turned in a counterclockwise direction. Because esthetic failures are often characterized by a lack of keratinized mucosa, grafting with full-thickness mucosal grafts is performed for one patient with simultaneous implant removal.

27:27 min; ISBN 978-1-78698-012-0

Volume 2. Failure of single tooth implant

This volume depicts a small-diameter single-tooth implant that required removal after 18 years because of a chronic infection and a slight mucosal recession. Implant removal resulted in a fracture of the implant, and the implant remnant was left in place to achieve an intact mucosa for planned implant surgery. The open-flap implant surgery included implant removal using the reverse torque technique followed by implant placement with simultaneous contour augmentation using GBR.

20:32 min; ISBN 978-1-78698-013-7

Volume 3. Esthetic failure of two adjacent implants including a lateral incisor area

In this patient, two adjacent implants were in place for 14 years and developed a severe mucosal recession. Treatment included removal of the two osseointegrated implants, at which time one of the small-diameter implants fractured in the apical area. Simultaneously, a full-thickness mucosal graft was used to reestablish keratinized mucosa. The subsequent implant surgery included removal of the small implant remnant and implant placement in the canine position with simultaneous GBR. The implant prosthesis included a crown with a small mesial cantilever unit.

26:03 min; ISBN 978-1-78698-014-4

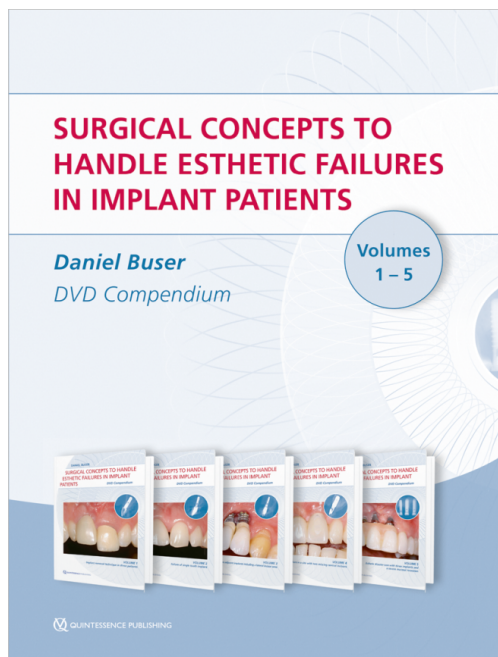
Volume 4. Esthetic implant failure in a site with two missing central incisors

The patient in this volume was referred with one osseointegrated implant in the position of the left central incisor in a site with two missing central incisors. The implant was heavily misangled and did not allow an esthetic restoration. Thus, the implant had to be removed and the site left to heal. Then, during an open-flap procedure, two implants were placed with correct 3D position and angulation using a surgical stent. Minor facial bone defects were augmented with GBR using autogenous bone chips, deproteinized bovine bone material particles, and a resorbable collagen membrane. Following healing, two single crowns were used to complete the treatment.

21:01 min; ISBN 978-1-78698-015-1

Volume 5. Esthetic disaster case with three implants and a severe mucosal recession

This volume depicts a female patient with three osseointegrated implants supporting a fixed dental prosthesis (FDP). All three implant sites had severe mucosal recessions caused by a vertical bone defect. First, the implants were removed, and mucosal



Edition: 1st Edition 2017
Cover: 5 DVDs in a box; NTSC/PAL; runtime 120 min
ISBN: 978-1-78698-011-3
Published: August 2017

QuintEd Pty Ltd

📍 Suite 2/38 Albany St
NSW 2065 St Leonards
Australia

☎ +61 434521025

✉ admin@quinted.com.au

🌐 <https://www.quintessence-publishing.com/anz/en>

grafting was performed to reestablish keratinized mucosa. Later, two implants were placed with simultaneous horizontal bone augmentation using GBR. Following healing, a provisional FDP was fabricated using pink acrylic to compensate for the vertical soft tissue defect.

25:17 min; ISBN 978-1-78698-016-8

Categories: Esthetic Dentistry, Implantology, Oral Surgery