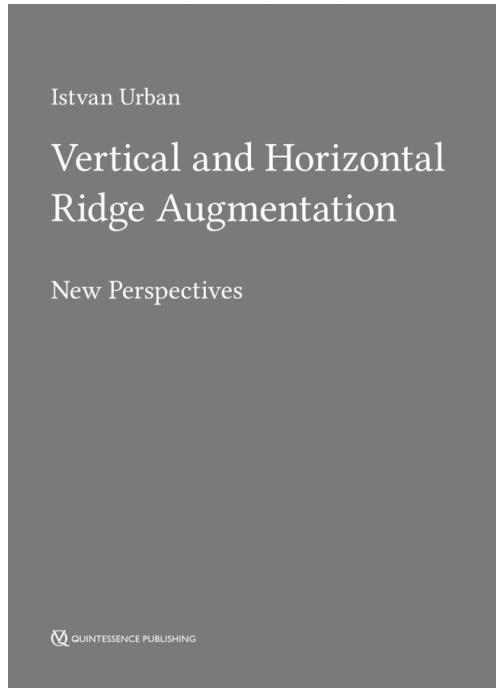


Edition: 1st Edition 2017
pages: 400
Images: 1252
Cover: Hardcover, 21 x 28 cm
ISBN: 978-1-78698-000-7
Published: January 2017

QuintEd Pty Ltd

 Suite 2/38 Albany St
NSW 2065 St Leonards
Australia

 +61 434521025

 admin@quinted.com.au

 <https://www.quintessence-publishing.com/anz/en>

Book information

Authors: Istvan Urban
Title: Vertical and Horizontal Ridge Augmentation
Subtitle: New Perspectives

Short text:

This book expertly describes the key features of vertical and horizontal ridge augmentation, such as the surgical anatomy of the floor of the mouth, papilla reconstruction, the modified lingual flap and the preservation of the mental nerve during flap advancement, growth factor applications used in conjunction with perforated membranes, managing complications of membrane exposure and graft infections, and a step-by-step description of complete reconstruction of the severely resorbed maxillary ridge using GBR with simultaneous sinus augmentation. Almost all cases described include a retrospective section with suggestions on what could have been done differently to achieve even better results, making this book a frank, ambitious, and immensely informative text on the clinical practice of ridge augmentation with GBR.

Contents

Chapter 01. Introduction

- Acknowledgments

Chapter 02. Surgical setup and patient preparation

- Patient selection • Patient preparation for surgery • Medications • The surgical room • Postsurgical care and suture removal • References

Chapter 03. Membranes and graft materials

- Scientific documentation of horizontal GBR using different membranes • Scientific documentation of vertical GBR using different membranes • Grafting materials used for GBR • References

Chapter 04. The intraoral harvesting of autogenous bone

- Bone harvesting from the mandibular symphysis • Bone harvesting from the mandibular ramus • Reference

Chapter 05. The surgical anatomy of the floor of the mouth

- Musculature of the floor of the mouth and the tongue • Arterial supply • Anatomical variations of floor of the mouth vascularization • Nerves • Salivary glands • Conclusion • References

Chapter 06. Principles of vertical and horizontal ridge augmentation in the posterior mandible

- Flap design • Preparation of the recipient site • Membrane adaptation • Mobilization of the lingual flap: the modified lingual flap advancement • Buccal flap advancement • Flap closure • Expected healing after posterior mandibular surgery • Treatment of more advanced defects • Conclusion • References

Chapter 07. Vertical ridge augmentation

- Distraction osteogenesis • Onlay bone grafting • Scientific documentation of vertical GBR with different grafting materials • Conclusion • References

Chapter 08. Vertical ridge augmentation in the posterior mandible

- Important clinical factors for consideration • Conclusion • References

Chapter 09. Anterior mandibular ridge augmentation

- The buccal flap • The lingual flap • Preparation of the recipient site • Membrane adaptation and stabilization • Buccal flap advancement • Mobilization of the lingual flap • Flap closure • Conclusions • Reference

Chapter 10. Combined posterior maxillary and ridge augmentation for partially

edentulous patients

• Flap design • Sinus augmentation • References

Chapter 11. Horizontal ridge augmentation: the sausage technique

• Case series and representative case using polyglycolic acid-trimethylene carbonate membranes • The use of a natural collagen membrane • Case series and representative cases using a natural collagen membrane • Representative cases with long-term follow-up in different regions using the sausage technique • Learning curve versus the well-developed sausage technique 2.0 • Conclusion • References

Chapter 12. Ridge augmentation in the anterior maxilla

• References

Chapter 13. Papilla reconstruction in conjunction with vertical augmentation in single tooth defects

• Case examples and lessons learned • Conclusions • References • Suggested additional reading

Chapter 14. Surgical management of significant anterior maxillary vertical ridge defects: the classification of anterior maxillary vertical defects

• Anterior maxillary vertical ridge augmentation (AMVRA) flap design classification • References

Chapter 15. Lateralization of the nasopalatine nerve: the palatal flap

• The palatal flap • Clinical evaluation • References

Chapter 16. Mucogingival surgery after bone augmentation

• Representative case • The adapted soft tissue surgery • Representative case • Long-term results • Conclusion • References

Chapter 17. New perspectives in mucogingival surgery after ridge augmentation

• Representative cases and clinical data • References

Chapter 18. New perspectives in crestal bone preservation after ridge augmentation

• Case series: long-term results • Representative case and lessons learned • Conclusion • Reference

Chapter 19. The development and maintenance of a positive gingival architecture using single implants in multiple missing teeth

• References

Chapter 20. Reconstruction of the edentulous resorbed maxilla

• Conclusions • References

Chapter 21. Complications of bone ridge augmentation

• Complications of healing • Postoperative infection • Nerve injury • Complications during implant placement into the newly formed ridge • Long-term biological complications of implants • Conclusion • References

Chapter 22. The use of growth factors

• Recombinant human platelet-derived growth factor • Bone morphogenetic proteins • Conclusions • References

Index

Permissions from books and journals

Categories: Implantology