

## INTRODUCTION

Teeth with incomplete root formation, thin dentin walls, and extensive apical lesions associated with dental traumatismes are often a clinical problem for the dentists.<sup>1</sup>

Nowadays there are several techniques of apexification using calcium hydroxide, aggregate mineral trioxide (MTA) or other compounds based on calcium silicate. There are also regenerative endodontic treatments (RET). The objective of this work is to report a clinical case in which the regenerative endodontic treatment uses L-PRF® as a scaffold.

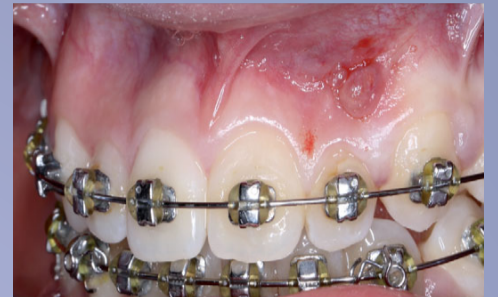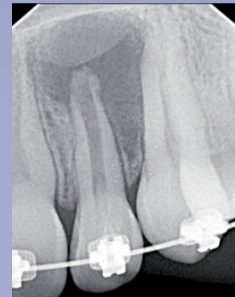## CASE - PRESENTATION

**PATIENT:** Female, 14 years refers to the dentist due to the presence of fistula at the level of tooth 22. Radiographically, tooth 22 shown immature apex and radiolucency.

**ANAMNESIS:** Healthy, no relevant background, dental trauma related by the patient parents.

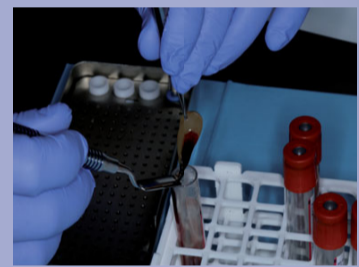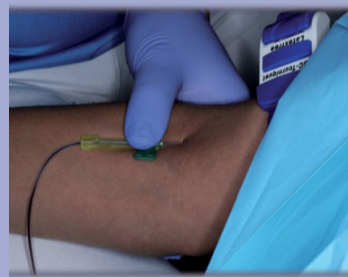
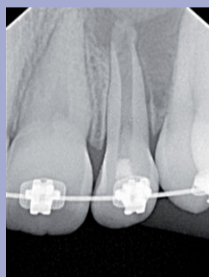
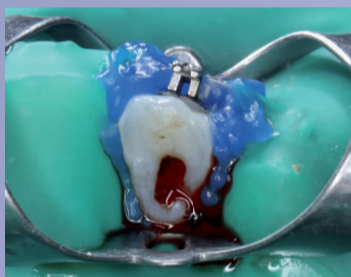**DIAGNOSIS:** Pulp Necrosis and chronic apical abscess, incomplete root formation.

**TREATMENT PLAN:** Regenerative endodontic treatment with the use of L-PRF®.



The radiograph shows circumscribed radiolucency associated with immature open apex tooth. The intra-oral photography shows the clinical image of fistula.

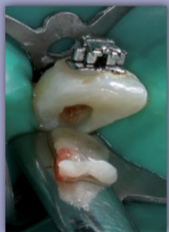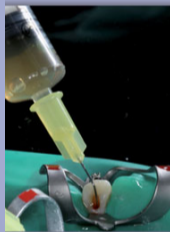
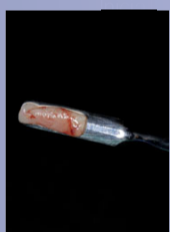
## CLINICAL PROCEDURE



1st session- Cavity access, drainage of purulent contents, debridement of necrotic tissue with manual k-files without major tooth instrumentation + irrigation with NaOCl 3% + EDTA 17% + intra-canal placement of calcium hydroxide

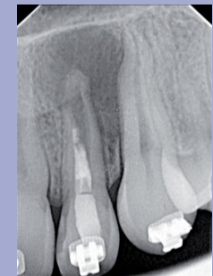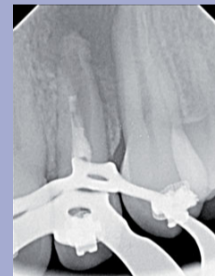2nd session- Blood collection to obtain L-PRF® (fibrin rich in platelets and leukocytes). L-PRF® belongs to a new generation of immune and platelet concentrates with simplified processing and without biochemical manipulation of blood.

After centrifugation of the blood collection, 3 portions are formed. In the lower part the red cells are deposited, in the middle a PRF clot and in the upper part acellular plasma and platelet-poor plasma.



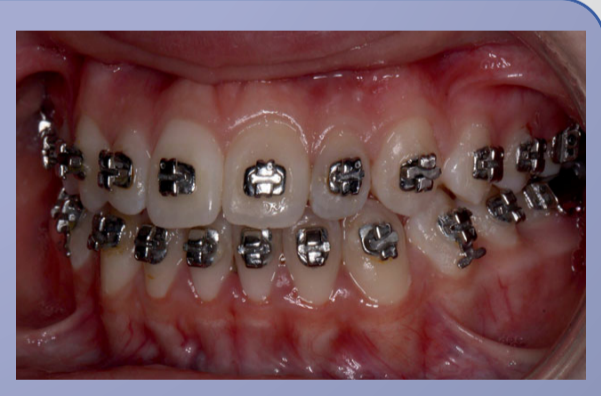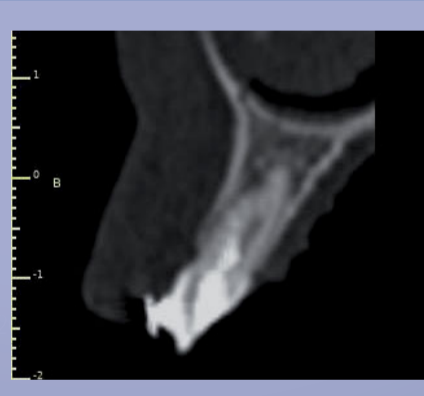
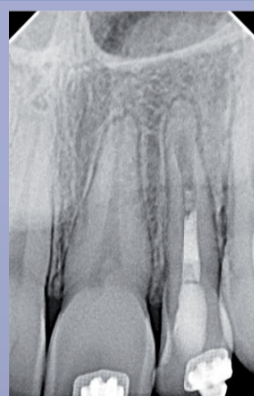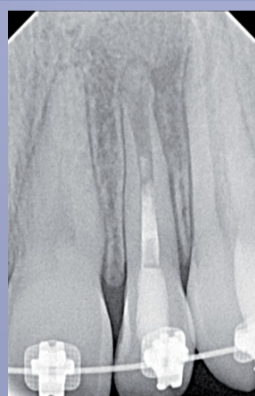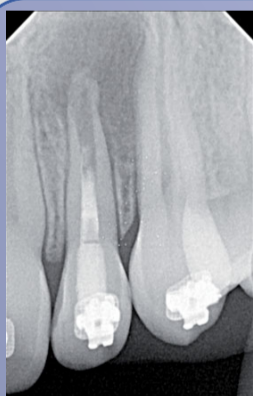(1) L-PRF® Membrane  
(2) Intra-canal cleaning of calcium hydroxide paste and irrigation with 17% EDTA + stimulation of apical bleeding with k 20 file curved by over-instrumentation and injection of L-PRF® (liquid phase – unpolymerized fibrin)

(3) Introduction of the L-PRF® membrane



Final radiography after placement of L-PRF® liquid phase + L-PRF® membrane + coronal barrier with MTA + sealing with Ionoseal® and composite restoration

## FOLLOW-UP (12 months)



2 months

6 months

9 months

CBCT 12 months

12 months – absence of fistula

## DISCUSSION / CLINICAL RELEVANCE / CONCLUSION

Apexification uses Ca(OH)<sub>2</sub>, mineral trioxide aggregate (MTA) or other bioceramic products. Regenerative endodontic treatments (RET) appear as a therapeutic alternative.<sup>2,3,4</sup> Studies show that prolonged use of Ca(OH)<sub>2</sub> in immature teeth weakens the root structure.<sup>2</sup> Placement of an apical MTA barrier facilitates obtaining an apical sealing, but doesn't promote root development.<sup>3</sup> There are several RET protocols. An alternative RET protocol to the conventional protocol was chosen. A matrix of L-PRF® rich in fibrin, platelets and leukocytes was used. This matrix prevents empty spaces within the root canal allowing the correct position and proliferation of stem cells with growth factors in order to transport them to the site to be regenerated, unlike blood clot induction revitalization.<sup>5</sup>

The clinical result after the use of L-PRF® demonstrates increase of the root size, increase of the thickness of dentin and closure of the apex. Thus, L-PRF® clinically demonstrates to be effective. Studies with enlarged samples and longer follow-up are necessary.

## REFERENCES

- 1 - Trope, M., Endodontic Considerations in Dental Trauma, in Ingle's Endodontics 6, Ingle, J. I., Bakland, L. K., and Baumgartner, J., Editors. 2008, BC Decker. p. 1330-1357.
- 2 - B. Rosenberg, P. E. Murray, and K. Namerow, The effect of calcium hydroxide root filling on dentin fracture strength, Dental Traumatology 23, 26-29 (2007)
- 3 - Felipe WT, Felipe MC, Rocha MJ. The effect of mineral trioxide aggregate on the apexification and periapical healing of teeth with incomplete root formation. Int Endod J. 2006;39:2–9
- 4 - Murray, P. E., et al. (2007). "Regenerative endodontics: a review of current status and a call for action." J Endod 33(4): 377-390.
- 5- Kontakiotis, E. G., et al. (2015). "Regenerative endodontic therapy: a data analysis of clinical protocols." J Endod 41(2): 146-154